

# $^{133}\text{Xe}$ VENTILATORY STUDIES IN

## $\alpha_1$ -ANTITRYPSIN DEFICIENCY

R. J. Fallat, M. R. Powell, F. Kueppers, and E. Lilker

Cardiovascular Research Institute,  
and University of California, San Francisco, California

*Fifty subjects with  $\alpha_1$ -antitrypsin deficiency were studied with  $^{133}\text{Xe}$  and  $^{131}\text{I}$ -macroaggregated albumin to evaluate ventilatory function and perfusion. Delayed clearance of  $^{133}\text{Xe}$  was seen in eight of nine homozygotes, two of whom did not have chronic obstructive pulmonary disease. Similar but less severe abnormalities of  $^{133}\text{Xe}$  were seen in all 11 heterozygotes over age 34, none of whom had clinical chronic obstructive pulmonary disease. Perfusion studies showed diffuse, mild defects in all of five heterozygotes without previously known chronic obstructive lung disease. These data indicate that radioisotope studies may be useful in detecting pulmonary abnormalities in  $\alpha_1$ -antitrypsin deficiency prior to its clinical manifestations.*

Severe deficiency of  $\alpha_1$ -antitrypsin, a rare inherited disorder, has been shown to be associated with panlobular emphysema with characteristic radiolucency and decrease in ventilation and perfusion at the lung bases (1-3). Intermediate deficiency of this protein, as found in heterozygotes for the deficiency gene, is quite a common disorder; the incidence in a normal population has been reported between 2 and 14% (1-5). Heterozygous  $\alpha_1$ -antitrypsin deficiency has also been suggested to be associated with chronic obstructive pulmonary disease (COPD) (3-5). Others dispute this (6,7).

The  $^{133}\text{Xe}$  ventilatory studies and  $^{131}\text{I}$ -macroaggregated albumin perfusion studies reported here indicate that heterozygotes with and without previously suspected lung disease develop ventilatory and perfusion abnormalities similar to but less severe than those found in homozygotes. Radioisotope studies appear to be sensitive indicators of pulmonary abnormalities in heterozygotes and provide further evidence for an association between the inter-

mediate deficiency of  $\alpha_1$ -antitrypsin protein and COPD.

### MATERIALS AND METHODS

Studies were performed using a Nuclear-Chicago Pho/Gamma III Anger scintillation camera with a divergent collimator for simultaneous viewing of both lung fields. The total counts from the posterior aspect of each lung were recorded at 0.5- and 5.0-sec intervals, using a Franklin rapid digital printer. Digital data were further processed to a limited extent to determine total radioactivity in smaller regions of interest in the lung as a function of time.\*

Approximately 1.0 mCi  $^{133}\text{Xe}$ /liter of air was administered in a single, slow inspiration from residual volume to total lung capacity (TLC). The subject next maintained the lungs at full inspiration (TLC) for 10 sec while a scintiphotograph and a maximum count of radioactivity were obtained. During this breath holding, the subject was switched from the xenon-filled bag to an air-filled 13.5-liter Collins spirometer which was used to measure the inspired volume as a function of time (cumulative minute ventilation). Sequential 30-sec scintiphotographs were obtained during normal tidal ventilation with room air from the spirometer. The spirometer was refilled during expirations. The expired radioxenon was conveyed to a roof-vented flue through a one-way Sierra valve which was open to the flue only during expiration and allowed the patient to inspire only from the line connected to the spirometer or the xenon-filled bag.

Clearance of xenon can be related to time, to the cumulative number of breaths, or to cumulative vol-

Received June 10, 1971; revision accepted Aug. 8, 1972.

For reprints contact: Robert Fallat, Nuclear Medicine, 455 Science Bldg., University of California, San Francisco, Calif. 94122.

\* "CCA-EDS 700" scintillation camera computer system available from Computer Corp. of America, Houston, Tex.

ume in order to obtain clearance curves. The curves were normalized by expressing counts as a percentage of the maximum count of radioactivity during the 10-sec breath holding at total lung capacity and further by dividing the cumulative volume inspired ( $V_1$ ) by the patient's TLC. The ratio of  $V_1$ /TLC is similar to the lung clearance index (LCI) which is commonly used to characterize nitrogen clearance during pure  $O_2$  breathing (8). For example, the radioxenon  $LCI_{2.5\%}$  is the cumulative inspired volume divided by TLC ( $V_1$ /TLC) to reach 2.5% of the maximum counts of radioactivity obtained during the initial 10-sec breath-holding period at TLC.

A 13.5-liter Collins spirometer was used to measure the timed vital capacity on each subject in the sitting position. The xenon study was performed on the same day and was also done in the sitting position. Total lung volume was routinely obtained by  $N_2$  washout (9), and by neon dilution during the 10-sec breath-holding procedure used for the single-breath carbon monoxide diffusing capacity by a method modified from Ogilvie, et al (10). This neon dilution TLC was assumed to have a distribution in the lung most similar to the inspired  $^{133}Xe$  volume, which was similarly held at full inspiration for 10 sec. Therefore, the neon dilution TLC was used in determining the xenon LCI.

Patients were also evaluated by conventional  $^{131}I$ -MAA scintiphoto studies.

Serum  $\alpha_1$ -antitrypsin was measured by radial immunoelectrophoresis (11) and by crossed immuno-

electrophoresis as described by Kueppers (12).

The subjects were divided into five groups (Table 1). Group 1 consisted of seven normal subjects without deficiency of serum  $\alpha_1$ -antitrypsin (serum levels greater than 150 mg%). There were six males and one female, age 24–65 (mean = 36.0 years). Only one subject was over 37 years of age. They had no history of cardiorespiratory disease, and their physical examinations, chest roentgenograms, and pulmonary function studies were normal. Lung volumes varied from 3.5 to 8.4 liters (mean =  $6.8 \pm 1.8$  liters). Subjects 3, 5, and 7 were cigarette smokers.

Group 2 consisted of 12 homozygotes for the  $\alpha_1$ -antitrypsin deficiency gene (serum  $\alpha_1$ -antitrypsin less than 50 mg%). There were seven probands with severe obstructive lung disease, five of whom had xenon studies. Evaluation of their families identified an additional three homozygotic siblings and two homozygotic children; radioxenon studies were not done in one of the children.

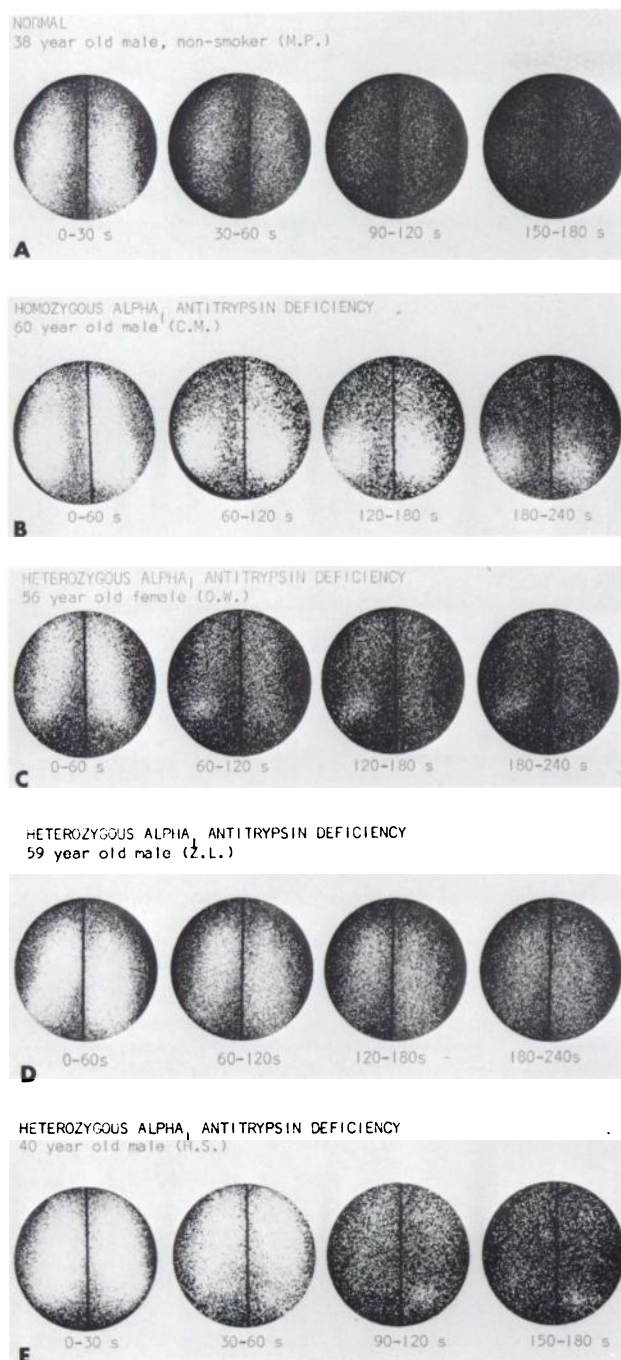
Group 3 consisted of 34 heterozygotes with intermediate deficiency of serum  $\alpha_1$ -antitrypsin (serum levels between 50 and 150 mg%). A survey of the seven families of the homozygotes disclosed 20 heterozygotes: 2 mothers, 2 siblings, and 16 children. Radioxenon studies were not done in nine of the children. An additional 14 heterozygotes were identified from a survey of healthy individuals without known lung disease, seven of whom had radioxenon studies.

Group 4 consisted of seven heterozygotes found

TABLE 1. SUMMARY OF RADIOISOTOPE STUDIES

Group	No. of subjects studied	Age range, years (mean)	Airway obstruction*	Abnormal scintillation camera studies†			Radioisotope studies only (abnormal finding)
				Ventilation ( $^{133}Xe$ )		Perfusion ( $^{131}I$ -MAA)	
				Basilar retention	Slow clearance		
1, normal	7	24–65 (36)	0	0/7	0/7	—	0
2, homozygotes	12	17–60 (40)	9	7/9	8/9	7/7	1
3, heterozygotes (no prior diagnosis of lung disease)							
Over 34 years	17	34–90 (64)	9	7/11	10/11	2/2	6
Under 27 years	17	16–27 (21)	1	0/7	1/7	3/3	2
4, heterozygotes (referred for lung disease)	7	37–64 (51)	6	4/7	7/7	11/11	1
5, nondeficient	11	44–79 (55)	6	2/11	11/11	10/10	0

\* FEV<sub>1</sub> less than 71% of vital capacity.  
† Denominator indicates total number studied.



**FIG. 1.** Serial scintiphotos representative of each group. (A) normal Subject 4 has uniform distribution and rapid clearance from both lung fields. (B) homozygote Patient CM has marked retention of xenon at both lung bases. Xenon persisted in bases even after 30-sec periods of hyperventilation. (C) heterozygote from Group 3, Patient OW, shows slow clearance with bilateral basilar retention. (D) heterozygote from Group 3, Patient ZL, shows uniform but delayed clearance, as confirmed in quantitative clearance curve shown in Fig. 6B. (E) heterozygote from Group 3, Patient HS, who had normal rate of clearance (Fig. 6C) but definite basilar retention on right shown by scintiphotos.

among patients referred to the Cardiovascular Research Institute at the University of California for evaluation of known or presumed lung disease.

Group 5 consisted of 11 nondeficient patients who

had known obstructive lung disease. Six had bullous emphysema and five had nonspecific COPD.

## RESULTS

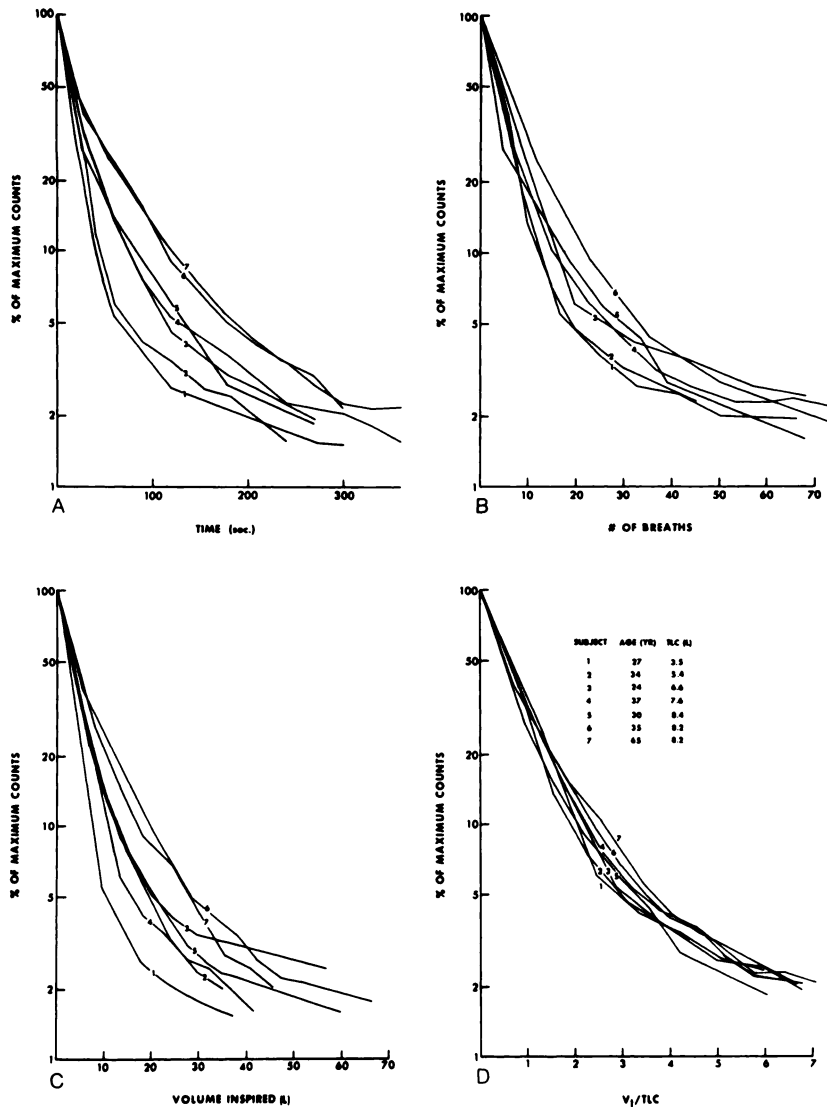
### Group 1—nondeficient and without lung disease.

The seven normal subjects showed rapid and uniform clearance of  $^{133}\text{Xe}$  in the scintiphotos, as seen in Subject 4 (Fig. 1A). No localized retention of xenon was observed in any of these seven normal subjects. The clearance curves are shown in Fig. 2. When the clearance is related to time, breaths, or cumulative inspired volume, there is considerable variation. It appears from Fig. 2A, B, and C that a smaller individual with small lung volume (Subjects 1 or 2) requires less time and less inspired volume ( $V_I$ ) to clear the  $^{133}\text{Xe}$  from the lungs. When the  $V_I$  was divided by the TLC, the clearance curves showed the least variation (Fig. 2D). Therefore, this ratio of  $V_I/\text{TLC}$ , defined as a lung clearance index (LCI), is used in all the subsequent clearance graphs. On the basis of this limited experience with normal subjects, we define normal ranges for  $\text{LCI}_{10\%}$  as 1.8–2.6 and for  $\text{LCI}_{2.5\%}$  as 4.7–6.0.

Duplicate studies were done in three normal subjects and in three subjects with deficiency of serum  $\alpha_1$ -antitrypsin and indicated very reproducible clearance patterns. Clearance from the right lung was slightly slower than the left lung in six of the seven subjects. Further studies will be required to determine if these differences are significant. In three subjects, clearance from the upper lung fields was slower than from the lower lung fields, consistent with the known preferential distribution of ventilation to the lower lung fields during normal tidal breathing (13).

**Group 2—homozygotes.** Scintiphotos of all nine homozygotes studied are shown in Fig. 5 and their clearance curves are shown in Fig. 4. The six patients with severe COPD [defined by a forced expiratory volume in 1 sec ( $\text{FEV}_1$ ) of less than 50% vital capacity] had distinct retention of xenon at the lung bases (Fig. 3). The overall clearance in these six cases was also slow, as shown by the clearance curves in Fig. 4. Clearance curves are not shown on three of the patients with severe COPD because they did not have volume measurements during their  $^{133}\text{Xe}$  study.

Two of the homozygotic siblings and one child were asymptomatic and had no past history of lung disease. Patient PC, a 39-year-old woman who had been a mild smoker (less than 12 pack years), was found to have minimal obstructive lung disease ( $\text{FEV}_1 = 70\%$ ) and slight basilar retention of xenon (Fig. 3). Her xenon clearance was slightly slow with a  $\text{LCI}_{2.5\%} = 7.1$  (Fig. 4A). The other two homozygotes did not have basilar retention of



**FIG. 2.** Clearance of xenon in seven normal subjects (Group 1) shown in semi-log plot of percent of maximum counts obtained during 10-sec breath-holding period on vertical axis as compared with four different time-related variables on horizontal axis: (A) time in seconds, (B) cumulative number of breaths, (C) cumulative inspired volume ( $V_I$ ), and (D)  $V_I$  divided by TLC measured during separate maneuver. Wide variation of curves in A, B, and C is markedly reduced when curves are normalized for TLC in D.

xenon. However, the clearance curves indicated all of these subjects may have abnormalities of distribution of ventilation (Fig. 4A). Patient DM, a healthy, vigorous, 44-year-old non-cigarette smoker, had no evidence of pulmonary abnormalities by any criteria, including extensive pulmonary function studies. The xenon scintiphotos showed no basilar retention (Fig. 3), but the overall clearance was definitely slowed (Fig. 4A). Delayed clearance appeared to be predominantly from the right lung (Fig. 3). Two repeat studies in this subject confirmed this slow and nonuniform clearance. Of particular interest was the 17-year-old homozygote (Patient KK). She had no respiratory symptoms, insignificant smoking history, and normal pulmonary function studies. Her clearance curve differed from the normal in that it was faster initially but slower later in the washout (Fig. 4A). This two-phase distribution of ventilation between "slow" and "fast" spaces may indicate very early emphysematous changes (14).

Basilar abnormality was also observed as radiolucency of roentgenograms in all of eight subjects with symptomatic disease, as irregular decreased distribution of macroaggregated albumin particles in all of the five perfusion studies performed, and as decreased vascularity in three pulmonary angiograms. Abnormalities of perfusion were also evident in lung areas other than the bases in all seven patients who had airway obstruction. Perfusion studies were not done in the four subjects without airway disease.

**Group 3—heterozygotes.** Of the 20 heterozygotes found among the seven homozygote kindreds, four adults and seven children had xenon ventilatory studies. Though none of these subjects were known to have lung disease, the two mothers, aged 56 and 67, had basilar retention of xenon (Fig. 1C). Neither of the two siblings, aged 50 and 59, showed basilar retention on the xenon scintiphotos although the older (Patient ZL) had definitely delayed clearance (Fig. 4B). Scintiphotos of Patient ZL

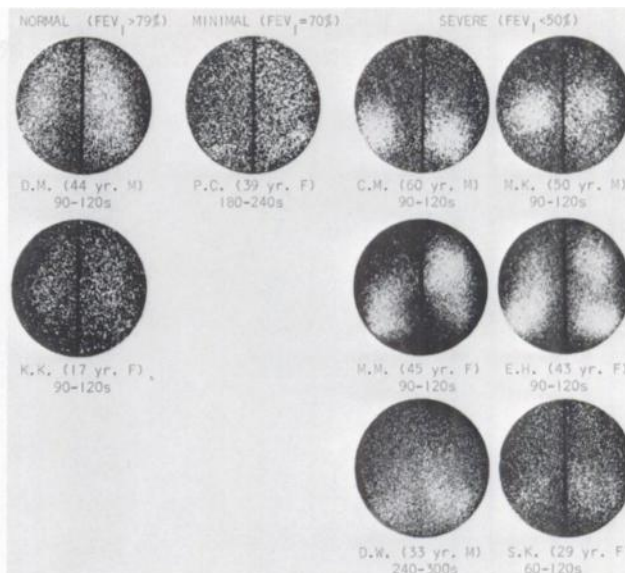


showed the retained  $^{133}\text{Xe}$  was rather uniformly distributed (Fig. 1D). Of these four older heterozygotes, three had spirometric evidence of COPD ( $\text{FEV}_1 = 57\text{--}68\%$ ). The other sibling heterozygote (AW) had no airway obstruction ( $\text{FEV}_1 = 76\%$ ) but had a clearance curve with a fast early phase and a slow late phase similar to clearance data in the young homozygote, KK; the  $\text{LCI}_{10\%}$  is at the lower limit of normal at 1.6, but the  $\text{LCI}_{2.5\%}$  is abnormally prolonged at greater than 10 (Fig. 4B). Of the seven heterozygote children, one 18-year-old boy (Patient PM) had a history of wheezing and was found to have mild increase in airway resistance and reduced  $\text{FEV}_1$  (70%) which improved with bronchodilators. He had no basilar retention of xenon in scintiphotos but had a two-phase clearance curve similar to one of the sibling heterozygotes (Patient AW) showing late  $^{133}\text{Xe}$  retention,  $\text{LCI}_{2.5\%} = 7.6$  (Fig. 4B). The remaining five children studied with xenon have suggestive two-phase clearance curves with an early rapid clearance and a slower later clearance, but not beyond the normal range.

An additional seven heterozygotes from a survey of individuals not known to have lung disease were studied with  $^{133}\text{Xe}$ . Though none complained of respiratory symptoms, all seven subjects appeared to be abnormal by the xenon study. Six had slow clearance (Fig. 4C). The one with normal clearance (Patient HS) had definite basilar retention (Fig. 1E). Basilar retention was seen in five of these seven subjects. The four subjects with distinctly slow clearance (Patients FA, OJ, HW, and MH) were over 70 years of age and may not be comparable to our control group. Three had  $\text{FEV}_1$  below 70% (Fig. 4C) but only in one (Patient FA) was the  $\text{FEV}_1$  low enough (58%) to be considered a definite indication of COPD at this age.

Perfusion studies with  $^{131}\text{I}$ -MAA were abnormal in all of five heterozygotes studied. The defects were not predominantly at the lung bases but were scattered, as seen in a 24-year-old, asymptomatic subject (Fig. 5). Two of these five were studied with  $^{133}\text{Xe}$  and distinct retention at the bases was present in one, though the prominent perfusion defect was in the midlung field. Mild airway obstruction was present in two, but the remaining three were normal by pulmonary function tests. All five were asymptomatic, had normal chest roentgenograms, and were without previously suspected lung disease.

**Group 4—heterozygotes referred for lung disease.** Radioxenon ventilatory studies were done in 7 of 22 heterozygotic patients referred for pulmonary function tests for known or presumed lung disease. Six had COPD and one was asymptomatic with nor-

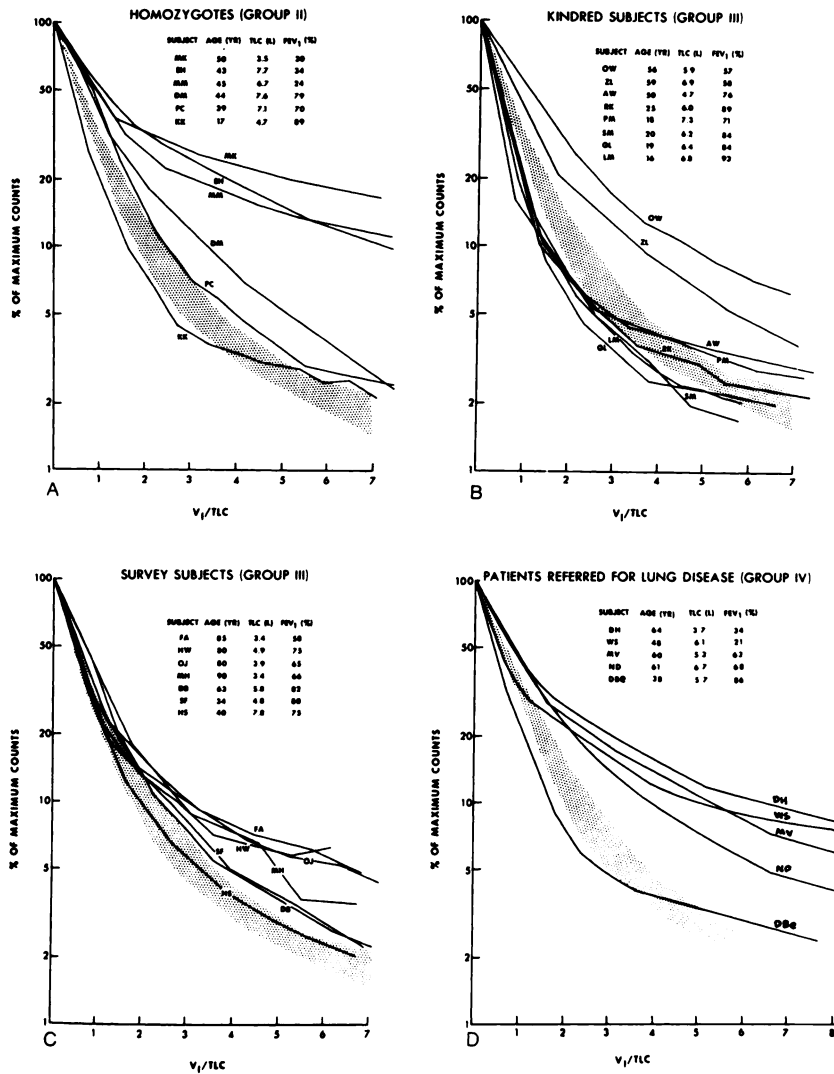


**FIG. 3.** Scintiphotos of all nine homozygotes studied with  $^{133}\text{Xe}$ . They are grouped according to degree of airway obstruction, as indicated by percent of vital capacity expired in 1 sec ( $\text{FEV}_1$ ). Age, time in seconds of scintiphoto after single-breath  $^{133}\text{Xe}$  inhalation, and pack years of cigarette smoking are shown below each scintiphoto. Six with severe airway obstruction ( $\text{FEV}_1$  less than 50%) show marked retention of  $^{133}\text{Xe}$  in lung bases, even after period of hyperventilation. One of sibling homozygotes, Patient PC, had mild obstruction ( $\text{FEV}_1 = 70\%$ ) and minimal retention. Two with no cigarette smoking history (Patients KK and DM) had no basilar retention but slow clearance from right lung is seen in Patient DM.

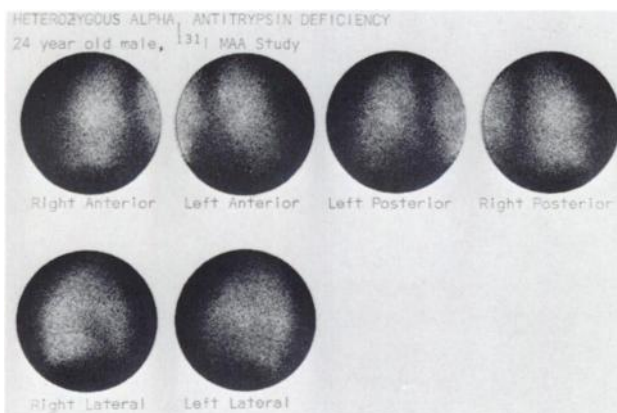mal chest x-ray and normal pulmonary function. He was referred for evaluation of progressive clubbing of fingers. Of the six with definite obstructive airway disease, four had basilar retention of xenon and all six had slow clearance. Figure 4 shows only four of them since the other two did not have volume measurements during the xenon study.

The patient with normal pulmonary function studies (Patient DBE) had rapid clearance and no localized retention of xenon, but his clearance curve (Fig. 4D) shows the two-phase pattern similar to the young, asymptomatic homozygote and heterozygotes (Fig. 4A and B). The  $\text{LCI}_{10\%}$  is low at 1.7 and  $\text{LCI}_{2.5\%}$  is slightly prolonged at 7.3. Of further interest in this patient were the diffuse, small defects of labeling seen on the  $^{131}\text{I}$ -MAA scintiphotos consistent with early emphysema.

**Group 5—nondeficient patients with obstructive lung disease.** An additional 11 patients were studied who had chronic lung disease but who did not have deficiency of serum  $\alpha_1$ -antitrypsin. In this group, five patients had COPD and six had bullous emphysema diagnosed from chest x-rays. Radioxenon retention was seen at the lung bases in two of the five patients with COPD: One patient was selected for radioxenon studies specifically because of roentgenographic lucency at the lung bases. Of the



**FIG. 4.** Clearance curves shown as log percent of maximum counts as compared with  $V_1/TLC$  of all patients who had xenon studies with inspired volume measurements. Shaded areas indicate ranges of seven normals. Homozygotes, Group 2. Note that Patient DM has definitely delayed clearance though no basilar retention was seen (Fig. 3).

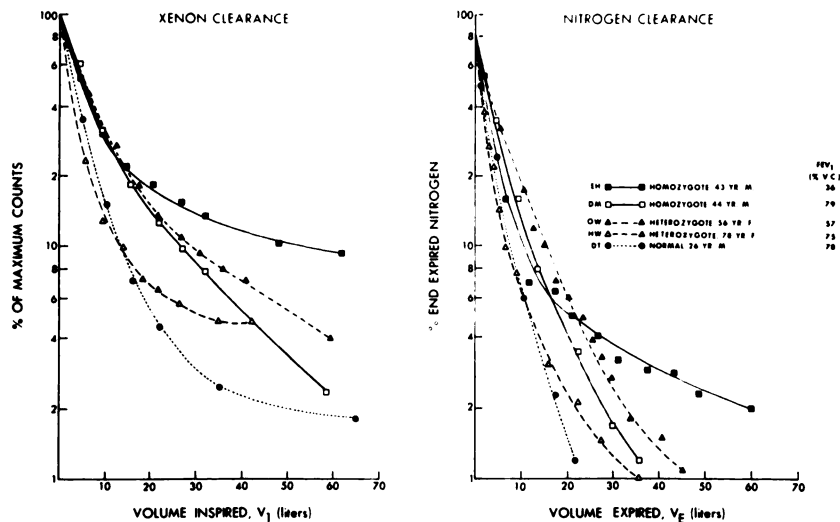


**FIG. 5.** Perfusion images of asymptomatic heterozygote who had normal pulmonary function ( $FEV_1 = 90\%$  of FVC) and chest x-rays. Irregular labeling is seen throughout both lung fields, suggesting generalized changes in small pulmonary vessels.

six patients with bullous disease, the prominent regional abnormalities in radioxenon studies were in the upper lung fields, confirming roentgenographic findings. Additional small basilar bullae were found

in two cases. All of these patients were found to have slow overall clearance of radioxenon from the lungs, including five patients who had no airway obstruction by standard pulmonary function tests but who did have high residual volumes and reduced vital capacities consistent with bullous disease.

The results are summarized in Table 1. Pulmonary abnormalities detected by radioisotope studies in heterozygotes are similar to those found in homozygotes. Basilar retention of xenon was present in seven of nine homozygotes and seven of eleven heterozygotes in Group 3 over 34 years of age. It should be emphasized that none of the heterozygotes in Group 3 had previously suspected lung disease yet all eleven of those over 34 years of age had abnormalities by xenon testing, as did one of seven younger heterozygotes. Abnormalities by  $^{131}I$ -MAA perfusion studies were also present in all five of the Group 3 heterozygotes tested, but the defects were diffuse and not characteristically basilar as in the radioxenon studies. Basilar retention of xenon is not



**FIG. 6.** Comparison of <sup>133</sup>Xe and N<sub>2</sub> clearance curves in subjects from each group. Though qualitatively similar, there is more pronounced differentiation from normal in radioxenon study. Only Patient EH is clearly abnormal by N<sub>2</sub> washout which has an early rapid clearance and later slow clearance, as seen with xenon in young asymptomatic heterozygotes (see Fig. 4).

limited to subjects with antitrypsin deficiency, however, as two of eleven subjects in Group 5 had similar findings.

Additional evidence for susceptibility of heterozygotes to obstructive lung disease and emphysema is found in their pulmonary function studies and pathological findings. In Group 3, nine of seventeen older heterozygotes and one of seventeen younger heterozygotes were found to have some airway obstruction which had not been previously suspected (Table 1). Pathological studies in five of the heterozygotes in Group 4 all showed emphysematous changes (15).

It appears that the radioisotope studies reported here are a highly sensitive test for detecting abnormality of pulmonary ventilatory function. The one older homozygote (Patient DM) who was normal by all other studies, including extensive pulmonary physiologic studies, clearly had abnormalities by the <sup>133</sup>Xe tests. In Group 3, five of the eleven heterozygotes over 34 years of age had no airway obstruction by spirometry, but all of them did have abnormal <sup>133</sup>Xe studies (Table 1). Perfusion studies were abnormal in all of five subjects in Group 3 including three younger heterozygotes without other evidence of lung disease (Table 1). In Group 4 the one patient without airway obstruction (Patient DBe) had uniform but slightly delayed <sup>133</sup>Xe clearance (Fig. 4D) and the <sup>131</sup>I-MAA perfusion study showed diffuse, irregular decreases of labeling consistent with small vessel abnormality or early emphysema. Thus, radioisotope studies appeared to be the earliest and most sensitive indication of pulmonary abnormalities in one homozygote and nine heterozygotes (Table 1).

Comparison of the results of <sup>133</sup>Xe clearance with standard N<sub>2</sub> washout studies further indicates the sensitivity of the radioxenon technique. Figure 6

shows N<sub>2</sub> and <sup>133</sup>Xe clearance studies in several subjects. The two methods appear to agree in assessing the relative clearance rates, but the radioxenon technique demonstrates a greater disparity among the subjects than was suggested by the N<sub>2</sub> washout. Only the homozygote with severe chronic obstructive disease (Patient EH) has greater than the normal limit of 2.5% N<sub>2</sub> at the end of a forced expiration following 7 min of O<sub>2</sub> breathing. (This is a commonly used test for ventilation abnormality.) The differences in clearance are much greater and more evident by radioxenon technique. Of particular interest is the two-phase pattern of N<sub>2</sub> clearance in homozygote Patient EH. This is similar to the pattern seen with xenon in the young asymptomatic homozygote (Patient KK) and in the heterozygotes without airway obstruction (Patients AW, RK, PM, and DBe). The xenon clearance for Patient EH fails to show the "fast space" ventilation seen during his N<sub>2</sub> washout study. This is because N<sub>2</sub> studies measure only the expired gas at the mouth, which, in the early washout period, is made up predominantly of the "fast space". During the xenon study the "slow space" retaining the xenon within the lung obscures the "fast space" changes observable by an external radiation detector. Whether this two-phase clearance is related to early emphysematous changes in the lung is a question of prime importance and will require evaluation by correlations of compartmental analysis of <sup>133</sup>Xe clearance with other function studies, particularly lung compliance, lung tissue changes, and serial studies in larger populations.

DISCUSSION

Clearance of N<sub>2</sub> from the lungs by breathing pure O<sub>2</sub> has been intensively studied and used as a sensitive indicator of uneven ventilation of the lung

(6). These studies have been limited to measuring decrease of  $N_2$  concentration in the expired gas, rather than within the lung, as is possible with radioxenon. Farhi has shown that xenon is more sensitive than  $N_2$  as an indicator of ventilation-perfusion abnormalities because it has a higher partition coefficient between gas and dissolved phases (16). With these advantages the radioxenon technique can be expected to be a more sensitive means of studying abnormalities of ventilation and perfusion in the lung. In addition, the use of radioactive gas methods allows regional ventilation studies which are not possible with conventional pulmonary function tests depending on expired gas measurements. The radioxenon technique is simple, requires minimal cooperation from the patient, and can be done easily in any nuclear medicine laboratory equipped with a gamma camera and spirometer.

Though only seven control subjects were studied, there was a wide range of lung volumes (3.5–8.4 liters). The age range of these normal subjects was 24–65 years, but there was only one subject over 37 years of age. Previous studies of  $N_2$  clearance indicate more nonuniformity of ventilation in older groups, particularly in subjects who are smokers (17). Therefore, a larger group of subjects without deficiency of serum  $\alpha_1$ -antitrypsin, with better representation of older subjects and cigarette smokers, must be studied to establish the range of normal subjects more precisely.

The radioxenon ventilation studies described here show that there is often a slowed clearance of radioxenon from the lungs of both heterozygotes and homozygotes. This delayed clearance is often predominantly a basilar retention of radioxenon. In his original description of  $\alpha_1$ -antitrypsin deficiency, Erikson emphasized that radiolucency at the lung bases, indicating decreased vascularity, was "invariably" seen on chest roentgenograms (1). The radioxenon studies in six of these eight cases showed that ventilation is also markedly abnormal in the lung bases. In addition, slight basilar retention of radioxenon was found in one of the asymptomatic homozygous siblings and a slower lung clearance, particularly on the right, was found in another homozygote who was normal by all other studies.

The significance of this basilar retention is not yet clear. Previous radioxenon studies in patients with COPD frequently demonstrated that ventilation at the bases of the lungs was severely affected (18,19). Whether many of these patients had deficiency of serum  $\alpha_1$ -antitrypsin was not determined. The basilar retention seen in two cases without deficiency of serum  $\alpha_1$ -antitrypsin in Group 5 indicates such abnormalities are not limited to those with this defi-

ciency. Basilar xenon retention may indicate the type of obstructive lung disease that is present. Thurlbeck (20) showed that panacinar emphysema is more common in the lower lobes while bullous and centrilobular emphysema are more pronounced in the upper lung fields. Several pathologic studies in homozygotes with deficiency of serum  $\alpha_1$ -antitrypsin have shown panacinar emphysema (21–23). The delayed clearance of xenon from the lung bases in all homozygotes with airway obstruction and in several of the older heterozygotes may be taken as further suggestion that panacinar emphysema is present.

The frequent finding of basilar retention in the heterozygotes suggests that they may be predisposed to a form of lung disease similar to that in homozygotes. This is particularly emphasized by the Group 3 heterozygotes in whom lung disease was not suspected prior to these studies. As seen in Table 1 and Fig. 4B and C, all eleven of those over 34 years of age had either basilar retention (seven subjects) or delayed clearance (ten subjects). However, four of these eleven subjects are over 70 years of age and are not comparable to our control group with respect to age range. Certainly a slower clearance rate might be expected and perhaps also basilar retention of xenon. Of the remaining seven, aged 34–67, only two were not cigarette smokers (Patients DB and AW). These two had the best clearance curves and did not have basilar retention of xenon. It is conceivable that the abnormalities noted in this study are more related to cigarette smoking than to the antitrypsin deficiency. However, no abnormalities were seen in the three normal subjects who were cigarette smokers, including the 65-year-old normal subject. A more likely hypothesis is that subjects with antitrypsin deficiency are more susceptible to the inflammatory effects of cigarette smoke because of the lack of antiproteolytic activity. A large-scale comparison of sensitive lung function studies in cigarette smokers with and without antitrypsin deficiency will be needed to answer this important public health problem.

#### SUMMARY

Deficiency of serum  $\alpha_1$ -antitrypsin (ATD) is an inherited disorder associated with COPD. Nine subjects with severe deficiency (homozygotes, less than 50 mg/100 ml) and 41 subjects with intermediate deficiency (heterozygotes, 50–150 mg/100 ml) were studied. Iodine-131-MAA perfusion studies and single-breath  $^{133}\text{Xe}$  were correlated with cumulative ventilation ( $V_1$ ) and TLC to define a lung clearance index for  $^{133}\text{Xe} = V_1/\text{TLC}$ . Delayed ventilatory clearance of  $^{133}\text{Xe}$  was seen in eight of nine homozygotes, including two without COPD. Retention of



xenon appeared to be most pronounced at the lung bases. Similarly, all of eleven heterozygotes over age 34 and not known to have COPD were found to have delayed <sup>133</sup>Xe clearance. Retention of xenon was most prominent at the lung bases in seven of the eleven. Two of eleven subjects with COPD but without ATD had basilar retention of <sup>133</sup>Xe and all eleven had delayed clearance. Perfusion scans showed bilateral diffuse defects in five of five heterozygotes without previously known COPD. Radioisotope studies were the only abnormality in one homozygote and nine heterozygotes.

We conclude first that radioisotope studies are a sensitive and valuable tool for detecting and defining pulmonary abnormalities in subjects with ATD and second that heterozygotes with intermediate ATD may be predisposed to develop COPD similar to but less severe than that found in homozygotes with severe ATD.

#### ACKNOWLEDGMENTS

Fallat and Lilker were supported by U.S. Public Health Service Training Grant No. HL-5705. Technical assistance by Eileen Carlin and editorial assistance by Kathryn Hahn and Hildegard Braun are gratefully acknowledged.

#### REFERENCES

1. ERIKSON S: Studies in alpha<sub>1</sub>-antitrypsin deficiency. *Acta Med Scand* 177 (Suppl 432): 1-80, 1965
2. GUENTER CA, WELCH MH, RUSSELL TR, et al: The pattern of lung disease associated with alpha<sub>1</sub>-antitrypsin deficiency. *Arch Intern Med (Chicago)* 122: 254-257, 1968
3. KUEPPERS F: Alpha<sub>1</sub>-antitrypsin: physiology, genetics, pathology. *Hum Genetics* 11: 177-189, 1971
4. KUEPPERS F, FALLAT RJ, LARSON RK: Obstructive lung disease and alpha<sub>1</sub>-antitrypsin deficiency gene heterozygosity. *Science* 165: 899-901, 1969
5. LIEBERMAN J: Heterozygous and homozygous alpha<sub>1</sub>-antitrypsin deficiency in patients with pulmonary emphysema. *New Eng J Med* 281: 279-284, 1969
6. WELCH MH, REINECKE ME, HAMMARSTEN JF, et al: Antitrypsin deficiency in pulmonary disease: the significance of intermediate levels. *Ann Intern Med* 71: 533-542, 1969
7. MAXWELL KW, RENZETTI AD, SCHMIDT CD, et al: Alpha<sub>1</sub> antitrypsin heterozygosity and chronic obstructive pulmonary disease. *Amer Rev Resp Dis* 103: 874-875, 1971
8. Respiration. In *Handbook of Physiology*, vol 2, Fenn

WO, Rahn H, eds, Washington D C, American Physiological Society, 1964, pp 715-733

9. DARLING RC, Cournand A, Richards DW: Studies on the intrapulmonary mixture of gases. III. An open circuit method for measuring residual air. *J Clin Invest* 19: 609-618, 1940

10. OGILVIE CM, FORSTER RE, BLAKEMORE WS, et al: A standardized breath holding technique for the clinical measurement of the diffusing capacity of the lung for carbon monoxide. *J Clin Invest* 36: 1-17, 1957

11. MANCINI G, VAERMAN JP, CARBONARA AO, et al: A single-radial-diffusion method for immunological quantitation of proteins. In *Protides of the Biological Fluids*, Peeters H, ed, Amsterdam, Elsevier, 1964, pp 370-373

12. KUEPPERS F: Identification of the heterozygous state for alpha<sub>1</sub>-antitrypsin deficiency gene in man. *Biochem Genet* 3: 283-288, 1969

13. MILIC-EMILI J, HENDERSON JAM, KANEKO K: Distribution of ventilation as investigated with radioactive gases. *J Biol Nucl Med* 11: 63, 1967

14. Cournand A, Baldwin E de F, Darling RC, et al: Studies on intrapulmonary mixture of gases. IV. The significance of the pulmonary emptying rate and a simplified open circuit measurement of residual air. *J Clin Invest* 20: 681-689, 1941

15. FALLAT RJ, KUEPPERS F, POWELL MR, et al: Chronic obstructive pulmonary disease with intermediate alpha<sub>1</sub>-antitrypsin deficiency. *Chest* 59 (Suppl): 20S-22S, 1971

16. FARHI LE, YOKOYAMA T: Effects of ventilation-perfusion inequality on elimination of inert gases. *Resp Physiol* 3: 12-20, 1967

17. BOUHUYS A: Pulmonary nitrogen clearance in relation to age in healthy males. *J Appl Physiol* 18: 297-300, 1963

18. BENTIVOGLIO LG, BEEREL F, STEWART PB, et al: Studies of regional ventilation and perfusion in pulmonary emphysema using xenon<sup>133</sup>. *Amer Rev Resp Dis* 88: 315-329, 1963

19. PAIN MCF, GLAZIER JB, SIMON H, et al: Regional and overall inequality of ventilation and blood flow in patients with chronic airflow obstruction. *Thorax* 22: 453-461, 1967

20. THURLBECK WM: The incidence of pulmonary emphysema. *Amer Rev Resp Dis* 87: 206-215, 1963

21. TALAMO RC, BLENNERHASSET JB, AUSTEN KF: Familial emphysema and alpha<sub>1</sub>-antitrypsin deficiency. *New Eng J Med* 275: 1301-1304, 1966

22. SCHLEUSENER A, TALAMO RC, PARE JAP, et al: Familial emphysema. *Amer Rev Resp Dis* 98: 692-696, 1968

23. MILLER F, KUSCHNER M: Alpha<sub>1</sub>-antitrypsin deficiency, emphysema, necrotizing angitis and glomerulonephritis. *Amer J Med* 46: 615-623, 1969

### Society of Nuclear Medicine Symposium on Cardiac Imaging in Nuclear Medicine

A critical appraisal of Needs, Agents, and Instruments.  
Sunday, January 21, 1973

O'Hare Regency Hyatt House Chicago, Illinois

For registration information contact:

The Society of Nuclear Medicine, 211 East 43 Street, New York, New York 10017