

## STEREO CISTERNOGRAPHY

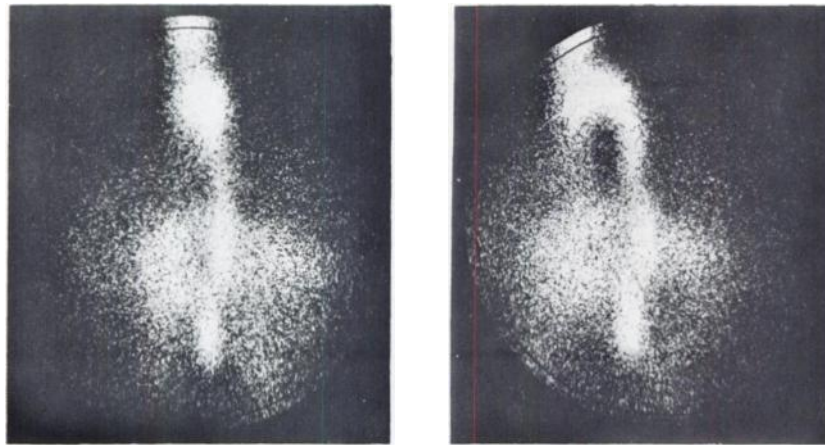
Cisternography has been used to evaluate cerebrospinal fluid (CSF) dynamics in a variety of neurologic disorders (1). One of the earliest and still most common applications of this procedure is the diagnosis of normal pressure hydrocephalus. Among the cisternographic hallmarks of this syndrome is the pattern of retrograde CSF flow into the lateral ventricles.

Usually, ventricular filling is easily recognized from its typical appearance on the anterior and lateral views; but on occasion it is difficult to differentiate

ventricular activity from that due to normal filling of the ambient and quadrigeminal cisterns (2). When this situation occurs, correct interpretation, which is of great clinical importance, may be virtually impossible without special views.

In cases when routine views remain ambiguous, one may conveniently obtain additional localizing information by stereo cisternography.

The technique is similar to that described by Charkes (3,4). Any standard scintillation camera may be used for this procedure. Two scintiphoto



**FIG. 1.** Left lateral stereo cisternogram view showing ventricular filling in patient with normal pressure hydrocephalus. (Note: Eyes must be crossed to obtain stereoscopic image).

views are obtained with the detector head tilted 5 deg to either side of a normal straight-on view. The resulting Polaroid pictures form a stereo pair which produces a three-dimensional image when viewed either with a stereoscope or by crossing the eyes. When  $^{131}\text{I}$ -IHSA is used, 50,000 counts per picture are adequate. A radioactive marker, such as that described by Williams (5), outlines the skull and serves as a three-dimensional reference source.

The left lateral stereo cisternogram view shown in Fig. 1 was performed 24 hr after injecting 100  $\mu\text{Ci}$   $^{131}\text{I}$ -IHSA into the lumbar subarachnoid space of a patient with normal pressure hydrocephalus. The skull marker in this case was standard intravenous tubing filled with 1 mCi  $^{99\text{m}}\text{TcO}_4^-$ . Retrograde filling of the lateral ventricle is noted and this cavity is seen to be enlarged and deep within the cerebral substance.

Stereo cisternography is a simple, rapid, and useful technique available to any laboratory possessing

a scintillation camera. No camera modifications are necessary. The three dimensional images produced allow more exact localization of ventricular activity and may prove helpful in differentiating abnormal ventricular filling from normal activity in the surrounding cisterns.

ROBERT J. LULL

William Beaumont General Hospital  
El Paso, Texas

### REFERENCES

1. HARBERT JC: Radionuclide cisternography. *Seminars in Nuclear Medicine* 1: 90-106, 1971
2. JAMES AE, DELAND FH, HODGES FJ, WAGNER HN: Cerebrospinal fluid (CSF) scanning: cisternography. *Amer J Roentgen* 110: 74-87, 1970
3. CHARKES ND, SOMBURANASIN R: Stereoscintiphotography. *J Nucl Med* 9: 494-496, 1968
4. CHARKES ND: Three dimensional radionuclide imaging: stereoscintiphotography. *Radiology* 98: 335-339, 1971
5. WILLIAMS JP: A simple marking device for use with the gamma camera. *J Nucl Med* 12: 300-301, 1971

## SCAN REPRODUCTION MADE EASIER AND SIMPLER

Many ways have been devised to reproduce scan films. We have further improved on the method described by Trites (1). Our method also uses Pola-

roid film but in the new "Big Shot" camera since the "Big Swinger" is no longer available. The "Big Shot" was made for color only as the directions will