

OPTIMIZATION OF DATA IN LUNG AND BRAIN SCANS

Suresh M. Brahmavar, Robert B. Groves, Edward V. Staab, Jon J. Erickson, and A. Bertrand Brill
Vanderbilt University Hospital and Veterans Administration Hospital, Nashville, Tennessee

The counting time required to obtain an optimal image of the emission distribution from a patient using an Anger scintillation camera is determined by the amount of the radioactivity administered, sensor sensitivity, lesion uptake and contrast ratio, and the ability of the patient to remain still. The longer the time required for the study, the greater is the probability that significant motion artifacts will occur. This report summarizes systematic studies we have conducted to determine the optimum counting time for scintillation camera studies of the brain and lung following the administration to the patients of 10 mCi of $^{99m}\text{TcO}_4^-$, and 300 μCi of ^{131}I -MAA, respectively. A Pho/Gamma III scintillation camera and a prototype Intertechnique sequential event data recording system were used.

MATERIALS AND METHODS

Experimental technique and analysis. Routine brain and lung scan data were continuously recorded on a 15-track magnetic tape for the duration of the study. The address of each event was encoded by levels written on 12 tracks, 6 each for x and y coordinates. Five minutes per view brain scan data were collected at the end of a 30-min "waiting period" after the pertechnetate was administered intravenously to the patient. The lung study data were collected for 10 min/view starting shortly after the ^{131}I -MAA was administered. In each case, four views—anterior, posterior, and both laterals—were recorded. For each view of every brain study, the data were played back into the digital memory and the images collected during the *first* 30 sec and 1-, 2-, 3-, 4-, and 5-min periods were reconstructed. For each of these time durations, Polaroid film records were made from the oscilloscope display using variable intensity and contrast settings to produce

the best visual image. The total number of counts collected in each of these scans was also recorded with the help of the digital integrator. Twelve patients were included in these studies. Four of the six brain scan patients had supratentorial lesions. Two patients were found to have malignant tumors and two were diagnosed as cerebral vascular accidents. Four of the six lung scan patients had diagnosed emboli. Two had multiple emboli (two lesions each), and two patients had single perfusion defects. Two normals were included in each group.

The brain studies involved analysis of the images obtained for six different lengths of time of collection and four different views, i.e., 24 pictures were analyzed for each patient in the study. These were mounted so that all four views obtained at the same integration time were presented to the physicians simultaneously. The mounted groups from all six patients were randomly arranged and scored independently by four physicians trained in nuclear medicine. These physicians had no previous knowledge of the patient's history or other details of the technical factors such as time durations, total counts, etc., of each of these film records. Their evaluations were then compared with the final clinical and radiographic diagnosis made on each patient in the study. The final evaluation was read as "correct reading" (i.e., positive or negative) and "wrong reading" (i.e., false positive and false negative). Average scores for each time interval were determined from the readings of the four physicians. A total of 144 evaluations ($4 \text{ views} \times 6 \text{ patients} \times 6 \text{ time inter-}$

Received Sept. 17, 1971; revision accepted June 26, 1972.
For reprints contact: A. Bertrand Brill, Div. of Nuclear Medicine, Vanderbilt University Hospital, Nashville, Tenn. 37203.

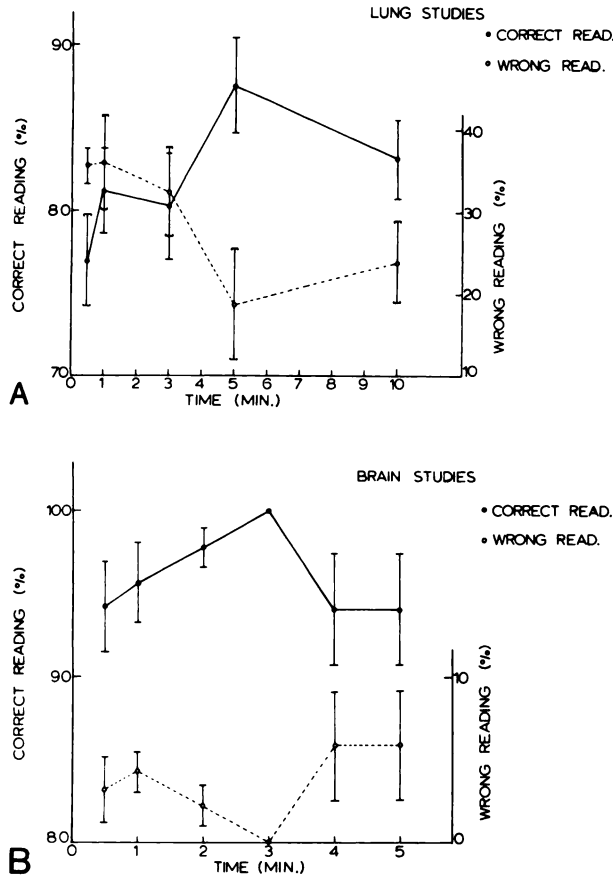


FIG. 1. Plots of percent correct and wrong readings as function of total imaging time show maximum percentage of scans are read correctly at 5 min for lung scans (A) and 3 min for brain scans (B).

vals) were included in this analysis. A similar analysis was done for lung studies with the time sequence of 30 sec and 1, 3, 5, and 10 min. A set of 20 Polaroid records for all views of each study were analyzed. A total of 120 evaluations were scored for this study.

The average scores obtained in each case are plotted as percentage "correct reading" and "wrong reading" against the time duration of the study. The results of the lung studies are shown in Fig. 1A. The solid line connecting the dark circles represents the frequency of the correct readings. The degree of correctness improves with the length of imaging times up to 5 min and then falls off at longer time durations. The dotted line connecting the open circles represents the trend of wrong evaluations. This also indicates that the chance of making a wrong evaluation is minimum at 5 min. The results of the brain studies are shown in Fig. 1B. In brain scans the quality of the picture improves up to 3 min time and then deteriorates at longer time periods. Statistical analysis indicates that improved frequency of

the successful reading at 3 min/view for brain scan and 5 min/view for lung scan are of borderline statistical significance; i.e., the p value is 0.10. The fact that the trend in physician performance was the same for each observer gives added confidence in the validity of these results.

Evidence for motion artifacts. In order to investigate the source of erroneous readings in the longer duration studies, the anterior and posterior views of each scan were replayed into the digital memory. The method of analysis is illustrated pictorially in Fig. 2A. The first illustration is a representation of a 1-min image collected on the oscilloscope. The numbers on the right-hand top corner indicate the horizontal and vertical array markers of the 64×64 digital array. The x-y coordinates, i.e., 10, 10, for the 1-min picture, give the position of the head during the first minute. This point is represented on the diagram below. The successive representations show the position of the head during the second, third, fourth, and fifth minutes of the scan and illustrate

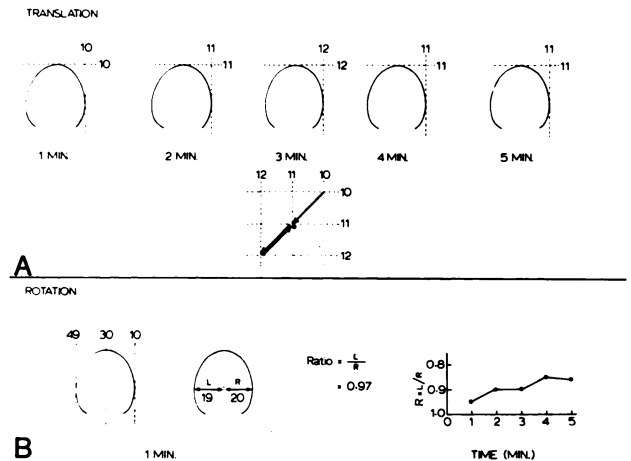


FIG. 2. A illustrates method used to measure translation of image of head during brain scan procedure. Orthogonal lines represent vertical and horizontal array markers of 64×64 digital array and show total motion of 0.5 in. B shows rotational analysis as performed by calculation of ratio of left to right hemisphere width.

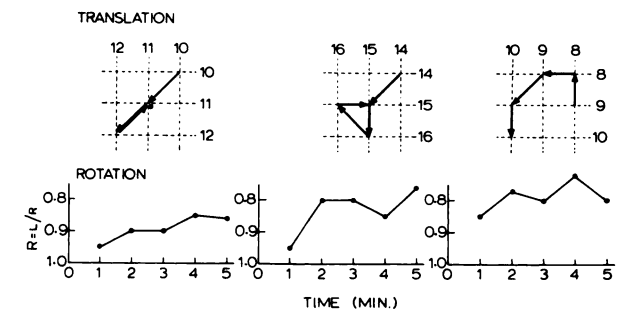


FIG. 3. Results of translational and rotational motion analysis for three brain scan views showing translational motion of 0.5 in. and maximum change in left to right ratio of 20%.




FIG. 4. Shows head restraint used by authors which permits adjustment in all three directions for optimum positioning.

the motion of the head during the entire 5 min of the scan. The arrows indicate the path followed by the head during its motion. Each array element is separated by 0.17 in., so the translational motion in this study is 0.5 in.

The illustration in Fig. 2B shows the rotation artifacts. The digital array markers can be used to get the distance of the midline structures from the left and right margin of the head. The midline structure used on the anterior view was the superior sagittal sinus, while on the posterior the torcula was used. The rotation is represented by the ratio of the left (L) margin distance to the right (R) margin distance. These ratios are obtained for each minute of the study. This analysis followed for each minute of the study is shown on the right portion of Fig. 2B. In this study, the rotation is between 5 and 15%. Figure 3 shows a similar analysis of the anterior and the posterior views of a patient.

Patient restraint and design of the headholder.

These studies show that in the brain scans the motion artifacts contribute to the deterioration of the quality of the image after a certain interval of time. In this particular study, the image quality is good up to 3 min of the scan and thereafter motion artifacts reduce the useful information that can be obtained from increased counting rate. Thus, in order to retain high diagnostic image quality in the longer duration studies, it is necessary to devise improved patient restraining techniques. For the imaging time evaluation studies we used two types of patient restraint procedures that are most commonly employed. Ambulatory patients sat in front of the camera. Bed patients were studied in the horizontal position. The patient's head was taped to the gamma-

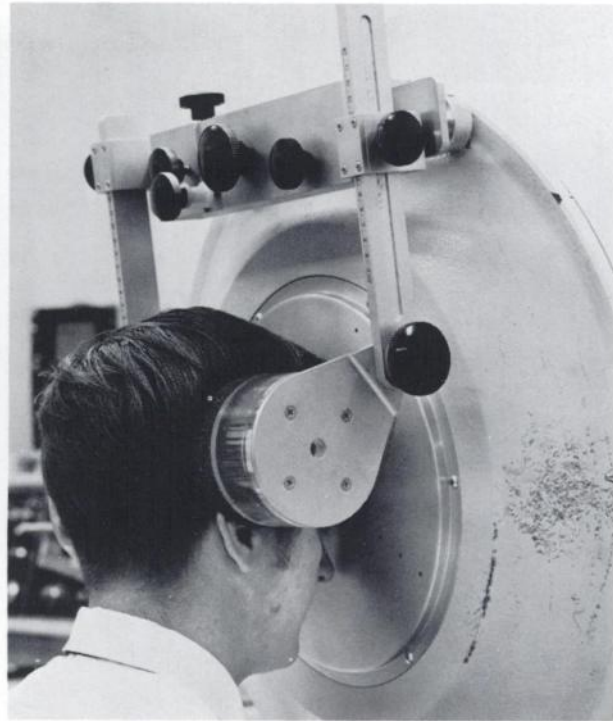


FIG. 5. Use of head restraint for positioning for anterior brain view.

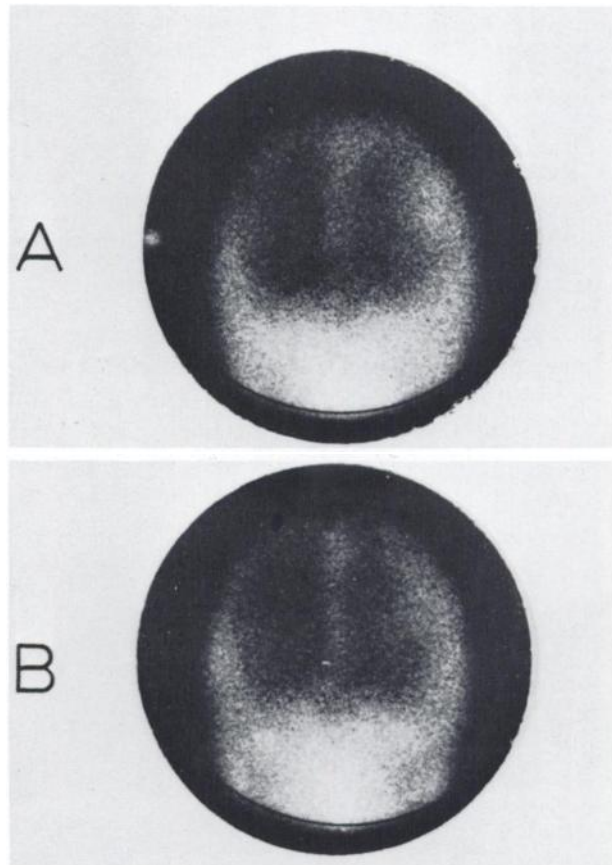


FIG. 6. Comparison of two scintillation images: (A) without restraint and (B) with restraint, showing improved quality and resolution of overall head image obtainable with restraint.

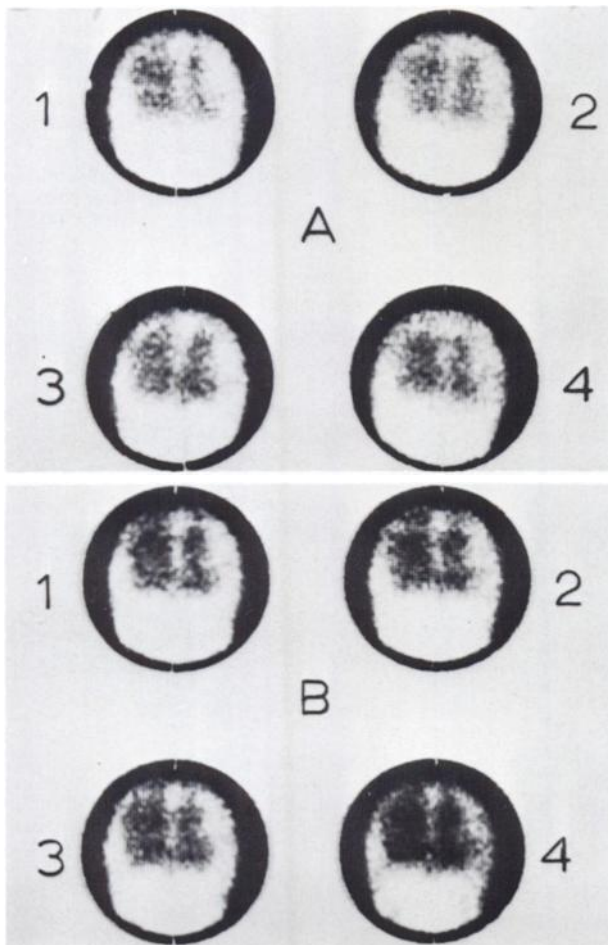


FIG. 7. Photograph of images obtained by summing data in 1-min intervals for studies of Fig. 6. Variations in positioning from minute to minute without headholder are evident in A as well as degraded quality due to motion. Images in B show no motion between images and improved resolution.

detector assembly once the desired orientation was obtained or the patient's head was restrained manually till the end of the study. As a more efficient and improved technique of restraining the patient, we then constructed a headholder which is convenient to use with the Pho/Gamma camera for

brain scans. Figure 4 shows the headholder which has horizontal, vertical, and lateral adjustments. This is designed so that it can be fixed on the detector in a few minutes. A horizontal railing is mounted on the detector assembly through the existing collimator bolts and the headholder slides on this railing. The three-dimensional adjustments are used to position a patient for a particular view of the brain scan. Once a correct orientation is obtained, the adjustments can be locked to restrain the patient during the study. Such a positioning for an anterior view is shown in Fig. 5.

RESULTS AND CONCLUSIONS

In order to evaluate the improvement in the quality of the image using the headholder, images were taken *with* and *without* the headholder for the images obtained from the Pho/Gamma display. The upper picture in Fig. 6 is the image obtained *without* the headholder (with manual patient restraint) while the lower is that obtained with the headholder. The improvement in diagnostic quality with use of the headholder is significant. Figure 7 shows the images obtained by summing the data in 1-min intervals for the studies shown in Fig. 6. The result of not using an instrumental head restraint is shown in the upper portion of this figure. The variations in head position from minute to minute are seen and the image quality in the unrestrained images is not as good as in the corresponding image obtained with the headholder as shown in the lower portion of the figure.

In summary, our studies indicate that the significant motion artifacts cause a deterioration of the image quality when brain studies are conducted without adequate patient restraint. In these circumstances, better diagnostic information is obtained at 3 min/view and 5 min/view for brain and lung scans, respectively, than with longer imaging times. Improved statistics should provide increased diagnostic accuracy only if proper patient restraints are used.