

RADIONUCLIDES IN RENAL TRANSPLANTATION

G. Hör, H. W. Pabst, K. J. Pfeifer, P. Heidenreich, H. Langhammer, and H. G. Heinze

*Nuklearmedizinische Klinik und Poliklinik der Technischen Universität
and Klinik und Poliklinik für Radiologie der Universität München, Munich, Germany*

In the terminal stages of renal failure, renal transplantation has become an effective means of treatment (1,2). Although survival rates have improved since the availability of adequate immunotherapy, present means of diagnosing the various forms of renal complications leave much to be desired.

Since 1966 180 kidney transplantations have been performed at the university clinics in Munich (2). Encouraged by communications of other authors (3-9) we have begun to use procedures involving radioisotopes, and results were compared with nephrological testing procedures (10-15).

Clinical diagnosis was based on the clinical course, palpation of the transplant, urine volume, serum creatinine, creatinine clearance, sodium excretion, urinary osmolarity, and biopsy.

Radiological procedures were usually confined to abdominal x-ray when kidney size was of interest. Drip infusion urography was used when extravasation of urine (urinary fistula) was suspected, and arteriography was performed to exclude arterial stenosis or thrombosis.

METHODS

Several radionuclide procedures were chosen for the evaluation of function and morphological disorders of the renal transplants. These are summarized in Table 1.

Renography. One hundred fifty-three followup studies were carried out with ^{131}I -o-hippuric acid (OIH) to estimate glomerular and tubular function. (Since OIH measures effective renal plasma flow, it is listed as tubular function in the tables and referred to as such in the test that follows.) Thirty-two patients were additionally investigated using $^{113\text{m}}\text{In}$ -Fe-EDTA (In) to study glomerular function alone.

^{133}Xe clearance. During preservation of an extracorporeal cadaver kidney transplant in a perfusion chamber (16), 200-500 μCi of radioxenon dissolved in 3-5 ml of sterile saline were injected selectively

TABLE 1. RADIONUCLIDES IN RENAL TRANSPLANTATION

Radiopharmaceutical	Procedure	
^{131}I -hippuric acid	Isotope renography Effective renal plasma flow	Tubular function
$^{113\text{m}}\text{In}$, $^{99\text{m}}\text{Tc}$ -, ^{169}Yb -EDTA, -DTPA	Isotope renography Renal clearance	Glomerular function
^{203}Hg -mersalyl	Scanning	Localization
^{197}Hg -chlormerodrin	Scanning	Localization
^{131}I -fibrinogen	Scanning	Localization
^{133}Xe	^{133}Xe clearance	Renal blood flow
$^{99\text{m}}\text{TcO}_4^-$	Scintillation camera	Vascular perfusion

into the arterial branch of the exteriorized kidney which was mounted to the forearm of the patient.

Renal cortical blood flow (RCBF) was determined by externally monitoring the ^{133}Xe washout from the exteriorized kidney. Graphical analysis of the radioxenon disappearance curve was performed using rapid component 1, its half-time, and lambda as the partition coefficient of radioxenon between kidney blood and parenchyma, dependent on the hematocrit. RCBF was related to kidney weight.

Renal scanning. Renal scanning was performed in 62 patients using ^{203}Hg -mersalyl, ^{197}Hg -chlormerodrin, and $^{113\text{m}}\text{In}$ -Fe-EDTA, with a Picker Magnascanner 500.

Sequential scintigraphy. Sequential scintigraphy was carried out in another 16 patients using 250 μCi of ^{169}Yb -EDTA and a Picker Anger scintillation camera.

Renal clearance studies. Renal clearance studies were performed in 30 followup examinations. One

Received Jan. 10, 1972; original accepted May 11, 1972.

For reprints contact: G. Hör, Nuklearmed. Klin. d. TU, Ismaningerstrasse, 8 München 80, Germany.




FIG. 1. (A) OIH renogram in acute rejection: OIH accumulation. (B) Photoscan (²⁰³Hg-mersalyl) in anuric rejection crisis (same patient): radioactivity in periphery (cortical area) reduced, no bladder activity.

hundred fifty microcuries of OIH were given intravenously, followed by 250 μ Ci of ¹⁶⁹Yb-EDTA 20 min later for combined investigation of renal plasma flow (RPF), and glomerular filtration (GFR). The filtration fraction (GFR/RPF) was estimated (17). Renal clearance was calculated according to the whole-body principle (18) by externally monitoring

the decline of radioactivity in the whole body, with the exception of kidney and bladder which were shielded by lead. Several plasma samples were drawn, and radioactivity (C_{plasma}) was determined in the well counter. Clearance (Cl) was calculated according to the formula of Oberhausen (18) separately for OIH and ¹⁶⁹Yb-EDTA:

$$Cl = \frac{-dm/dt}{C_{\text{plasma}}}$$

RESULTS

In acute rejection crises the following criteria were found (Fig. 1A):

1. OIH accumulation (lack of excretory segment) or prolonged secretory maximum (T_{max}), fall in urinary osmolarity, lack of bladder activity, and marginal filling defects in the scan (Fig. 1B).

2. There is a decrease in endogenous C-CR. Correlation between parameters of radionuclide renography and the level of serum creatinine is presented in Table 2. There is a positive correlation between serum creatinine and the elimination index of the OIH and In-Fe-EDTA renograms, and a negative correlation between serum creatinine and accumulation index of renography.

3. Different behavior between tubular and glomerular function was found in acute tubular necrosis of transplanted cadaver kidneys that were subject to prolonged ischemia time before transplantation.

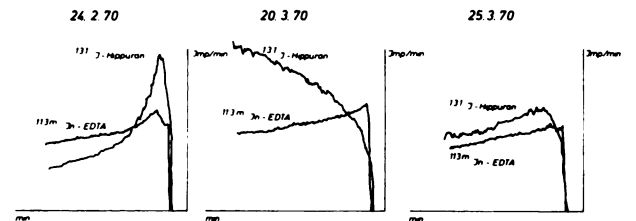


FIG. 2. Followup study with OIH- and ^{113m}In-EDTA renography in kidney transplant: rejection crisis on March 20, 1970.

TABLE 2. CORRELATION BETWEEN SERUM-CREATININE (MG%) AND ISOTOPE RENOGRAPHY (KIDNEY TRANSPLANTS)

Renography	Tubular function			Glomerular function		
	Accum. ratio	¹²⁵ I-o-Hippuran Elim. ratio	Secret. max.	Accum. ratio	^{113m} In-EDTA Elim. ratio	Filtrat. max.
n	41	35	25	38	33	38
r	-0.662	+0.763	+0.595	-0.502	+0.530	+0.572
b _{y/x}	0.11	0.037	0.267	0.164	0.0678	0.950
p	<0.001	<0.001	<0.01	<0.01	<0.01	<0.01

Accumulation ratio (1.5/0.5 min-activity).
Elimination ratio (20.0/0.5 min-activity).

TABLE 3. RENOGRAPHIC FOLLOWUP STUDIES OF CADAVER KIDNEY TRANSPLANTS WITH TUBULAR NECROSIS

Total ischaemia time (min)	Normalization of renogram (days after)
239	19
203	16
159	5
155	8
115	5
109	3

As an example of differences in glomerular and tubular function in acute rejection crises see Fig. 2, second panel. Note the continuous OIH accumulation without excretion but excellent excretion of $^{113m}\text{In-Fe-EDTA}$. The OIH renogram became normal on March 25, 1970.

4. In acute tubular necrosis delayed transit time of OIH seems to depend on the duration of ischemia time of the cadaver kidney before transplantation (Table 3).

5. The $^{113m}\text{In-EDTA}$ was found to be rapidly excreted by normally functioning transplant kidneys so that this radiopharmaceutical is more suitable for tests by the scintillation camera (Fig. 3). Arterial thrombosis or complete occlusion results in total loss of accumulation of radioactivity.

6. Rectilinear scans using $^{203}\text{Hg-mersalyl}$ or $^{197}\text{Hg-chlormerodrin}$ were characterized by filling defects in the center, in the upper, or in the lower pole of the rejected kidney as has been reported by us previously (11).

7. Sequential scanning after injection of $^{169}\text{Yb-EDTA}$ and/or OIH presented no characteristic pattern in rejection of the kidney transplant and was of no predictive value (Fig. 4).

8. Renal clearance studies, however, gave additional information concerning the functional state of the rejected transplant (Fig. 4). Simultaneous determination of the clearances of OIH and $^{169}\text{Yb-EDTA}$ showed disproportionate reduction of RPF compared with GFR, so that filtration in rejection crises was elevated (Fig. 5).

9. In some cases determination of the washout of ^{133}Xe in the kidney before transplantation, while preserved in a perfusion chamber, proved to be of prognostic value when RCBF has been found normal (Fig. 6).

DISCUSSION

Radionuclide renography is now an acknowledged and easily performed diagnostic tool for elucidating complications following renal transplantation.

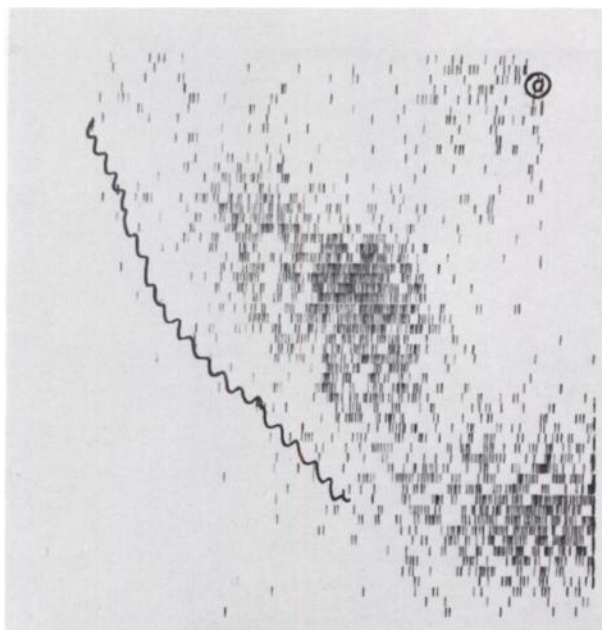


FIG. 3. Colorescan ($^{113m}\text{In-EDTA}$) in kidney transplant with doubled renal artery: obstruction of upper branch. Note retention of radioactivity in area of renal pelvis.

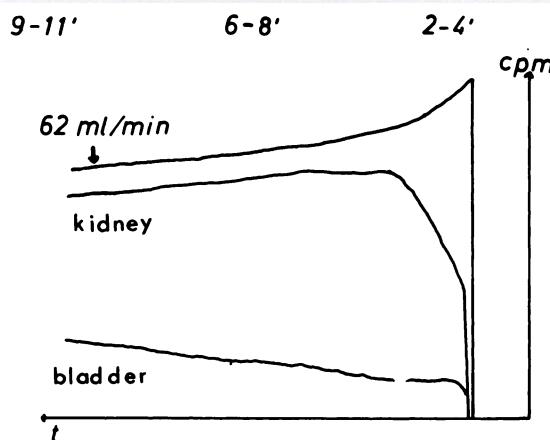
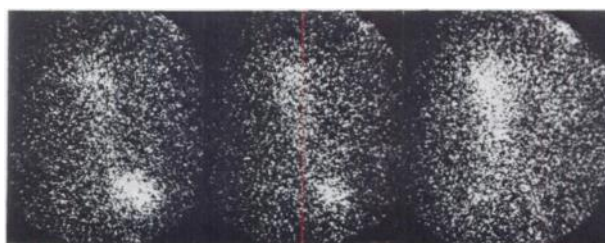


FIG. 4. Serial scintiphotography (sequential scintigraphy) and OIH-single shot clearance in acute rejection.

From our followup studies we conclude that parameters of OIH as well as of the $^{113m}\text{In-Fe-EDTA}$ renogram are generally in accordance with the level of serum creatinine.

Collins, et al (3), Sharpe, et al (8), and Staab, et al (9) have also reported on the prognostic value

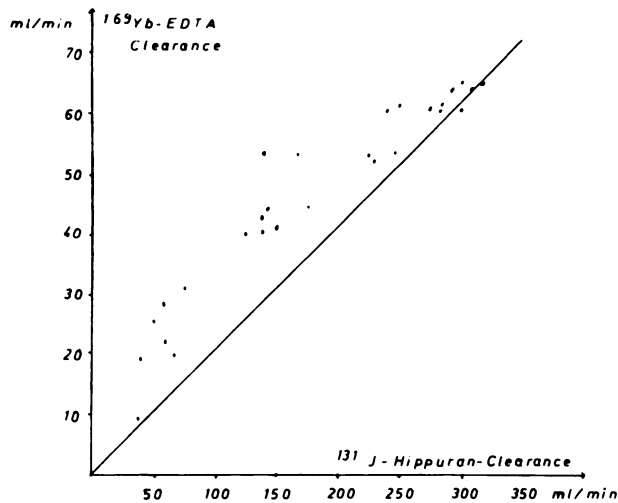


FIG. 5. Comparative glomerular and tubular clearance in transplanted kidneys.

of radionuclide renography which may show pathological changes before clinical alterations.

The most common pathologic type is the continuous OIH accumulation with the lack of the excretory phase. This type of renogram was described as a sign of rejection by Mobley, et al (6). Continuous OIH accumulation, however, is not pathognomonic for rejection of kidney transplants. It may be due to rejection crisis as well as to disorders of excretion on account of a necrosis of the ureter at the level of the anastomosis.

Lubin, et al (19) demonstrated kidney scanning with OIH as a complementary test to renography to locate sites of abnormal accumulation. In ureteral obstruction, for instance, most of the abnormally pooled radiopharmaceutical is found in the renal pelvis, whereas in rejection it is principally cortically reduced. Furthermore renal scanning by itself may help in the differential diagnosis of oliguria. In necrotic renal allografts obtained from cadaver donors no uptake of ^{203}Hg -chlormerodrin is observed (4). In total obstruction of the renal artery due to complete stenosis or to thrombosis we regularly observed a nephrectomy-type of renogram. Immediately after intravenous injection of OIH, radioactivity disappears over the kidney transplant similar to the blood disappearance curve which is externally registered over the heart. Acute tubular necrosis may be associated with accumulation as well as with nephrectomy type. In our hands, simultaneous performance of radionuclide renography using OIH and $^{113\text{m}}\text{In}$ -Fe-EDTA was valuable in differentiating between the onset of glomerular and tubular function in cadaver kidneys. Similar observations were reported by zum Winkel, et al (20,21) using sequential scintigraphy with the Anger camera. This

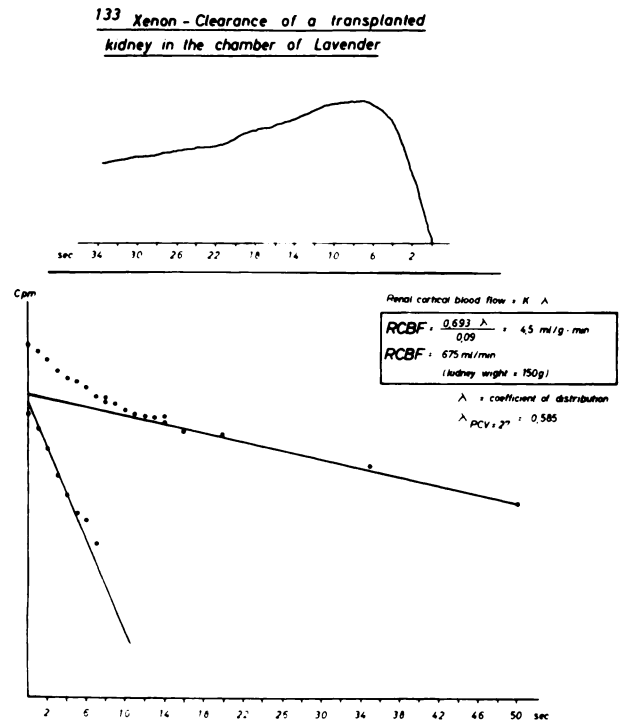


FIG. 6. RCBF study using ^{133}Xe clearance (cadaver kidney, preserved in perfusion chamber).

technique is superior to conventional scanning, especially when used in conjunction with a computer, because it supplies both functional and morphological data (20–23).

The following criteria were described in rejection crises (20): (A) reduced initial uptake of OIH, (B) delay in intrarenal transport of OIH, and (C) decreased renal excretion.

There are also differences in the radioactivity pattern associated with acute tubular necrosis (reduced accumulation) and renal artery thrombosis (lack of accumulation).

Clearance procedures represent another step forward in expanding diagnostic possibilities after renal transplantation (7,17,24–26,31). The superiority of these methods over scanning procedures is evident because renal functional impairment may be quantitated. Comparative studies including the estimation of GFR and RPF, as carried out by us, demonstrated that in rejection crisis RPF is more severely reduced than glomerular function. Similar observations were published by Rosen, et al (27).

Renal ^{133}Xe clearance supplies information concerning cortical blood flow of the kidney transplant (14,15,27–29). The practicability of this method, however, is very limited. Radioxenon has to be injected selectively into each renal artery, so this clearance technique is applicable only to the Seldinger technique or during surgery (intraoperative xenon

clearance) (29), in cases of inevitable arteriography (in arterial stenosis, thrombosis), or, in accordance with our practice, in extracorporeal kidney transplants preserved in a perfusion chamber (14,15). This procedure offers the possibility of preserving cadaver kidneys prior to transplantation until function and histocompatibility are tested (16). RCBF may be determined using the most rapid component (Fig. 6), and progressive redistribution of blood flow is seen in rejection because of hypoperfusion of the renal cortex as has been shown by autoradiography (27). This reduction in RCBF is considered to be caused by immunological mechanisms and may play a role in the ensuing renal failure.

Single injection clearance of OIH has been promoted by Rösler (7), Blaufox, et al (24), and Gott, et al (25). The volume of distribution (V) of the injected OIH, calculated from the injected dose divided by the zero intercept of blood disappearance curve times the slope ($k = 0.693/\text{half-time}$) enables one to evaluate the clearance (Cl) of the kidney transplant: $Cl = V \times K$ (one-compartment concept). Renal clearances are reduced early in rejection crises, where, on account of the oliguria, urinary sodium excretion and urinary osmolarity are unobtainable. According to Rösler (7) simultaneous application of radionuclide renography with OIH and single-injection clearance gives quantitative information concerning the total clearance of the kidney transplant.

Simplified clearance techniques based only on the determinations of half-time of the blood disappearance curve (30) or on the one-compartment concept did not correlate with standard clearance procedures (31). At the present time we believe one cannot decide whether the single-injection clearance calculated according to one-compartment, two-compartment, or multicompartment models is best suited for replacing conventional clearance procedures (14). A really new idea obviating the compartment idea was developed by Oberhausen (18) in measuring the total-body clearance of renal clearance substances. Up to the present time, however, experiences with this technique in kidney transplants are limited.

Reviewing our own results and those reported in the literature it seems justifiable to use radioisotopic procedures to determine function and morphology of kidney transplants. Exact and comparable interpretation of the results obtained so far will depend however on standardizing examination procedures to be performed by nuclear medicine personnel.

REFERENCES

1. STARZL TE, VANHOUTTE JJ, BROWN DW, et al: Radiology and organ transplantation. *Radiology* 95: 3-18, 1970
2. ZENKER R, PICHLMAIER H, ERPENBECK R, et al: Erste Erfahrungen mit der Transplantation von Leichennieren beim Menschen. *München Med Wschr* 109: 613, 1967
3. COLLINS JJ, WILSON RE: Functional evaluation of human kidney transplants with renograms. *Ann Surg* 161: 428-440, 1965
4. FIGUEROA JE, MAXFIELD WS, BATSON HM, et al: Radioisotope renal function studies in human renal allografts: Value in the differential diagnosis of oliguria in the presence of obstructive disease with and without urinary extravasation. *J Urol* 100: 104-108, 1968
5. LOKEN MK, STAAB EV, VERNIER RL, et al: Radioisotope renogram in kidney transplants. *J Nucl Med* 5: 807-810, 1964
6. MOBLEY JE, SCHLEGEL JU: Radiohippuran accumulation in the transplanted kidney as a signal of rejection. *Surgery* 58: 815-818, 1965
7. RÖSLER H: Radionephrographische Funktionsstudien nach Nierentransplantationen. *Z Ges Exp Med* 143: 345, 1967
8. SHARPE AR, KING ER, HUME DM, et al: Sequential response of the iodine-131 Hippuran renogram in renal homotransplantation. *J Nucl Med* 7: 556-563, 1966
9. STAAB EV, KELLY WD, LOKEN MK: Prognostic value of radioisotope renograms in kidney transplantation. *J Nucl Med* 10: 133-135, 1969
10. HEIDENREICH P, HÖR G, PABST HW, et al: Funktions- und Lokalisationsdiagnostik mit dem ^{113m}Indium-Eisen-Athylendiamin-triacetat-Komplex (EDTA) nach Nierentransplantationen. *Langenbecks Arch Chir* 328: 91, 1970
11. HÖR G, PABST HW, HAUBOLD U: Studies of localization after renal transplantation. In *Medical Radioisotope Scintigraphy*, vol 2, Vienna, IAEA, 1969, pp 209-217
12. HÖR G, PABST HW, EDEL HH: Möglichkeiten nuklearmedizinischer Diagnostik nach Nierentransplantationen. *München Med Wschr* 111: 1190, 1969
13. HÖR G, FREY KW, BÖSSNER O, et al: *Nuklearmedizinische und nephrologische Verlaufskontrollen nach Nierentransplantation*. Deutscher Röntgenkongress, Stuttgart, G Thieme, 1972, pp 121-122
14. PABST HW, HÖR G: Nephrologie. In *Nuklearmedizin-Funktionsdiagnostik*, Emrich D, ed, Stuttgart, G Thieme, 1971, pp 275-312
15. PABST HW, HÖR G: Radionuclides in renal transplantation. Paper presented at the International Symposium on Radionuclides in Nephrology, New York, Jan 25-27, 1971, p 418
16. DOBBELSTEIN H, EDEL HH: Diureticwirkung an der extrakorporalen transplantierten Niere. In *Renal Transport*, Thureau K, Jahrmärker H, eds, Berlin-Heidelberg-New York, Springer Verlag, 1969, pp 413-418
17. PFEIFER KJ, ROTHE R, RICHERT J, et al: Tubuläre und glomeruläre Clearance und Sequenzsintigraphie bei transplantierten Nieren. In *Radioisotope in Klinik und Forschung*, München, Berlin, Schwarzenberg
18. OBERHAUSEN E, ROMAHN A: Bestimmung der Nieren-clearance durch externe Gamma-strahlenmessung. In *Radionuklide in Kreislaufforschung und Kreislaufdiagnostik*, Stuttgart-New York, FK Schattauer Verlag, 1968, pp 323-326
19. LUBIN E, LEWITUS Z, ROSENFELD J, et al: Kidney scanning with Hippuran, a necessary complement for correct interpretation of renography in the transplanted kidney. In *Medical Radioisotope Scintigraphy*, vol 2, Vienna, IAEA, 1969, pp 219-222
20. ZUM WINKEL K, HARBST H, SCHENCK P, et al: Se-

quential scintigraphy in renal transplantation. In *Medical Radioisotope Scintigraphy*, vol 2, Vienna, IAEA, 1969, pp 197-208

21. ZUM WINKEL K, KLINKE JD: *Radioisotopenuntersuchungen bei der Nierentransplantation*. Wiederbelebung, Organersatz, Intensivmedizin (Darmstadt) 6: 121, 1969

22. FREEDMAN GS, TREVES S, LANGE RC, et al: Renal transplant evaluation using technetium-DTPA, a gamma camera, and a small computer. *J Nucl Med* 11: 320, 1970

23. WEISS ER, BLAHD WH, WINSTON MA, et al: Scintillation camera in the evaluation of renal transplants. *J Nucl Med* 11: 69-77, 1970

24. BLAUFox MD, MERRILL JP: Evaluation of renal transplant function by iodohippurate sodium I 131. *JAMA* 202: 575-581, 1967

25. GOTT FS, PRITCHARD WH, YOUNG WR et al: Renal blood flow measurement from the disappearance of intravenously injected Hippuran. *J Nucl Med* 3: 480-486, 1962

26. TAUXE WN, MAHER FT, TAYLOR W: Effective renal plasma flow: estimation from theoretical volumes of distri-

bution of intravenously injected ^{131}I -orthoiodohippurate. *Mayo Clin Proc* 46: 524-531, 1971

27. ROSEN SM, TRUNIGER BP, KRIEK HR, et al: Intrarenal distribution of blood flow in transplanted dog kidney: effect of denervation and rejection. *J Clin Invest* 46: 1239-1253, 1967

28. LADEFOGED J: Measurements of the renal blood flow in man with the Xenon-133 wash-out technique. *Scand J Clin Lab Invest* 18: 299-315, 1966

29. LEWIS DH, BERGENTZ SE, BRUNIUS U, et al: Value of renal blood flow measurement with xenon-133 at the time of kidney transplantation. *Ann Surg* 166: 65-74, 1967

30. EGGLESTON TA, ACCHIARDO S, RODRIGUEZ-ANTUNEZ A, et al: ^{131}I Hippuran in the evaluation of transplanted kidneys. *Radiology* 93: 1145-1148, 1969

31. HÖR G, PABST H, STEINHOFF H, et al: Untersuchungen zur Clearance von ^{131}I -Hippuran, ^{203}Hg -Salyrgan, ^{51}Cr -EDTA und ^{51}Cr -Inulin. In *Radioisotope in der Kreislauforschung und Kreislaufdiagnostik*, Stuttgart-New York, FK Schattauer Verlag, 1968, pp 327-334

Accepted Articles To Appear in Upcoming Issues

Optimization of Data in Lung and Brain Scans. Accepted 6/26/72.

Suresh M. Brahmavar, Robert B. Groves, Edward V. Staab, Jon J. Erickson, and A. Bertrand Brill
Graves' Disease with Functioning Nodules (Marine-Lenhart Syndrome). Accepted 6/26/72.

N. David Charke
Serum Tri Iodothyronine Uptake Using Albumin Microspheres in the Assessment of Thyroid Function. Accepted 6/27/72.

E. Rolleri, G. Buzzigoli, and G. Plassio
Macroaggregation of an Albumin-Stabilized Technetium-Tin (II) Colloid (Concise Communication). Accepted 6/28/72.

Max S. Lin and H. Saul Winchell
Whole Body Imaging and Count Profiling with a Modified Anger Camera. I. Principles and Application. Accepted 6/28/72.

Michael Cooke and Ervin Kaplan
Whole Body Imaging and Count Profiling with a Modified Anger Camera. II. Implementation and Evaluation. Accepted 6/28/72.

Michael Cooke and Ervin Kaplan
Splenic Displacement and Changes of Splenic Size (Letter to the Editor). Accepted 7/6/72.

Bruno Schober
Reply to the Letter to the Editor. Accepted 7/6/72.

Richard P. Spencer
 ^{99m}Tc -EHDP: A Potential Radiopharmaceutical for Skeletal Imaging (Preliminary Note). Accepted 7/7/72.

G. Subramanian, J. G. McAfee, R. J. Blair, E. G. Bell, A. Mehter, and T. Connor
Hepatic Scintigraphy in Clinical Decision Making. Accepted 7/7/72.

David E. Drum and Julia Sdougou Christopoulos
Regional Cerebral Blood Flow with the Anger Camera. Accepted 7/20/72.

B. Leonard Holman, Rex Hill, David O. Davis, and E. James Potchen
Accelerated Clearance of Radioactive Chelate from Cerebrospinal Fluid in Experimental Meningitis. Accepted 7/20/72.

Prantika Som, Fazle Hosain and Henry N. Wagner, Jr.
False-Positive Liver Scan Due to Lung Abscess (Case Report). Accepted 7/20/72.

Harry K. Genant and Paul B. Hoffer
Gating Mechanism for Motion-Free Liver and Lung Scintigraphy (Concise Communication). Accepted 7/20/72.

Frank H. DeLand and Walter Mauderli
Diagnostic and Therapeutic Implications of Long Term Radioisotope Scanning in the Management of Thyroid Cancer. Accepted 7/27/72.

G. T. Krishnamurthy and W. H. Blahd

Radiation Dose to a Breast Feeding Child After Mother Has ^{99m}Tc MAA Lung Scan. Accepted 8/1/72.

R. A. Berke, E. C. Hoops, J. C. Kereiakes, and E. L. Saenger
Study of Availability of Iodine from Calcium Iodate Employing ^{131}I -Labeled Salt. Accepted 8/1/72.

I. S. Shenolkar and B. S. Narasinga Rao
Performing ^{18}F Bone Scans on the Gamma Camera (Letter to the Editor). Accepted 8/4/72.

M. V. Merrick
Synthesis of 5-Fluorouracil- ^{18}F . VII (Preliminary Note). Accepted 8/4/72.

J. S. Fowler, R. D. Finn, R. M. Lambrecht, and A. P. Wolf
Calculating the Radiation Dose to an Organ (Concise Communication). Accepted 8/8/72.

Roger J. Cloutier and Evelyn E. Watson
Xenon-133 Ventilatory Studies in Alpha $_1$ -Antitrypsin Deficiency. Accepted 8/8/72.

R. F. Fallat, M. R. Powell, F. Kueppers, and E. Lilker
Serendipity in Cisternography (Case Report). Accepted 8/8/72.

P. Kirchner and K. A. McKusick
Arachnoid Cyst of the Posterior Fossa Demonstrated by Isotope Cisternography (Case Report). Accepted 8/11/72.

Lanny G. Goluboff
Increased Resolving Power from Scintillation Cameras Using Electronic Signal Processing and a Movable Filter Plate. Accepted 8/21/72.

Ronald J. Jaszczak
Functional Pulmonary Imaging (Concise Communication). Accepted 8/21/72.

John A. Burdine, and Paul H. Murphy, Veerasamy Alagarsamy, Linda A. Ryder, and William N. Carr
Correlation of Ultrasound and Colloid Scintiscan Studies of the Normal and Diseased Liver. Accepted 8/23/72.

B. Leyton, S. Halpern, G. Leopold and S. Hagen
Gamma Camera Study of the Hepato-Biliary Excretion of ^{131}I -Thyroxine Glucuronide and ^{131}I -Rose Bengal in the Rat. Accepted 8/23/72.

C. H. Bastomsky, P. W. Horton, and J. Shimmins
Body Potassium Measurements by Whole Body Counting: Screening of Patient Populations. Accepted 8/23/72.

Pierre A. Delwaide
System for Handling and Dispensing Xenon-133 (Concise Communication). Accepted 8/23/72.

R. E. Snyder and T. R. Overton.
Collimator Performance for Scintillation Camera Systems. Accepted 8/23/72.

Valerie A. Brookeman and Thomas J. Bauer