

LOCALIZATION OF ^{87m}Sr IN EXTRA-OSSEOUS TUMORS

C. Papavasiliou, P. Kostamis, P. Angelakis, and C. Constantinides

Alexandra Hospital, University of Athens Medical School, Athens, Greece

Strontium isotopes mimic calcium in their preferential localization (1-3). Thus ^{87m}Sr has been successfully used for the detection of bone abnormalities, particularly in the early detection of bone-forming tumors or bone metastases (4-6).

The following case reports demonstrate localization of this isotope in extra-osseous tumors of various histological types. To the best of our knowledge this phenomenon has not been adequately emphasized, although it has been mentioned in the literature (1,7).

TECHNIQUE

One millicurie of ^{87m}Sr from an ^{87}Y - ^{87m}Sr generator was given to the patient intravenously. About 1 hr after the injection, the scan was performed using a Picker Magnascanner equipped with a NaI(Tl) 3×2 -in. crystal.

CASE REPORTS

Case 1. PP was a 35-year-old female. Gravida I, Para I. In January 1968 she noticed a 2-cm lump in her left breast. This was excised, but the histological report showed "no evidence of cancer". In November 1969 she was admitted to the hospital

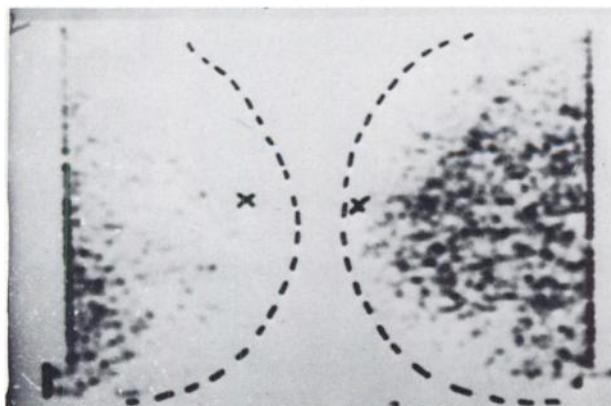


FIG. 1. Case 1. Uptake of ^{87m}Sr by tumor of left breast. Right breast was scanned for comparison.

with an advanced tumor in the left breast. Biopsy of a left supraclavicular lymph node showed "complete replacement by adenocarcinoma". Scanning of both breasts with ^{87m}Sr showed excessive uptake by the tumor (Fig. 1).

Case 2. HD was a 63-year-old male. In August 1968 he had a Miles resection for a Stage C (Dukes) adenocarcinoma of the rectum. In April 1969 he developed severe pain at the left hip joint radiating to the inner and anterior surface of the thigh. A mass was palpated in the left iliac fossa. Radiological examination of the pelvis was negative. A ^{87m}Sr scintigraphy showed an area of increased uptake on the left side of the pelvis (Fig. 2A). Cobalt-60 teletherapy (4,000 R in 20 days) resulted in relief of the pain and diminution of the size of the mass (Fig. 2B).

Case 3. FT was a 41-year-old female who had been treated by us 2 years before the present admission for an anaplastic carcinoma of the nasopharynx. The primary tumor and its neck lymph node metastases received 6,100 rads in 38 days. The tumor was quiescent for 2 years until present admission when the patient presented with bilateral nodes in the neck, the largest being 6-7 cm in diam, relatively fixed at the right side of the neck. A ^{87m}Sr scintigraphy showed uptake of the radionuclide by the node (Fig. 3).

Case 4. SH was a 60-year-old female. Her illness started 2 months before admission when the patient developed constipation, frequency in urination, and pain in the pelvis. By bimanual vaginal examination, a mass about 8 cm in diam was found in the left pelvis. Edema of the left leg was evident. A barium enema showed stenosis of the sigmoid thought to be due to extrinsic pressure. At exploratory laparotomy the mass was found to be inoperable because there was fixation with adjacent organs. Histological examination showed "solid anaplastic carcinoma". The origin of the tumor was not determined. Radiographic

Received Jan. 1, 1970; revision accepted Dec. 16, 1970.

For reprints contact: C. Papavasiliou, Alexandra Hospital, Athens, Greece.

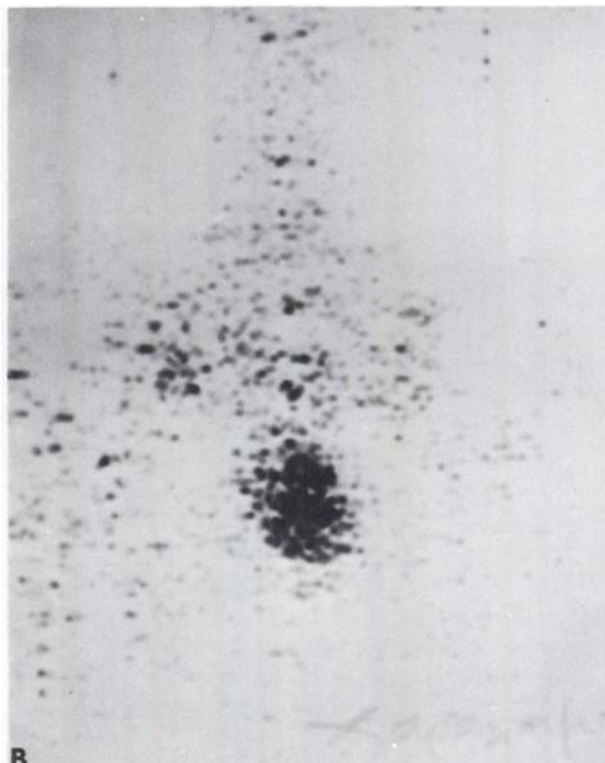



FIG. 2. Case 2. A shows uptake of ^{87m}Sr by mass in left half of pelvis and iliac fossa before radiotherapy. B shows patient after

^{60}Co teletherapy (4,000 R in 20 days) which resulted in relief of pain and diminution of mass size.

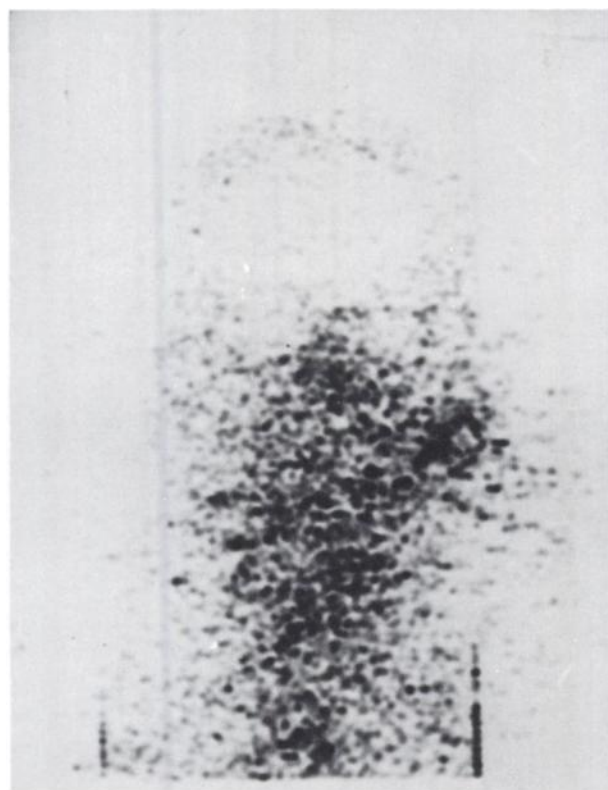


FIG. 3. Case 3. Concentration of ^{87m}Sr in large node at right side of neck.

examination of the bones of the pelvis was negative. The mass was clearly visualized by ^{87m}Sr scintigraphy (Fig. 4).

Case 5. EK was a 48-year-old female who noticed a 3-cm lump located in the lower outer quadrant of her left breast in January 1969. Within a month, the lump grew rapidly in size, and she was admitted to the hospital. Upon admission she was found to have a mass 8 cm in diam in the left breast. There was retraction of the nipple and skin infiltration. A node, about 2 cm in diam, was found in the axilla. The node was excised, and histological examination showed "metastatic adenocarcinoma". A ^{87m}Sr scintigraphy showed considerable uptake by the tumor (Fig. 5).

Case 6. MK was a 43-year-old female who underwent excision of an adenocarcinoma of the cecum in 1964. From January 1968 she started having pain at the right half of the pelvis which occasionally radiated to the right leg. She was then re-explored, and a recurrent tumor was removed with difficulty from the right half of the minor pelvis. Unfortunately pain reappeared shortly thereafter, and the patient was referred to us for radiotherapy in January 1970. Pelvis and spine x-rays were normal. Barium enema and excretory urography were not contributory. A lymphangiogram was normal. Venogram revealed a

constriction of the right iliac artery caused by the mass, which was also demonstrated by ^{87m}Sr scintigraphy (Fig. 6).

DISCUSSION

These case reports show that ^{87m}Sr was preferentially accumulated by extra-osseous tumors. The histological diagnoses were Hodgkin's granuloma, recurrent undifferentiated rectal carcinoma, metastatic nasopharyngeal anaplastic carcinoma, primary breast adenocarcinoma, recurrent adenocarcinoma of the cecum, and anaplastic tumor of the pelvis of undetermined origin. Tow and Wagner (7) have described cases in which there was visualization of brain tumors by ionic strontium although the bones of the skull were not involved. The same authors state that strontium and pertechnetate appear to be equally effective in demonstrating intracranial vascular abnormalities. This ability of strontium to concentrate in tumor masses has been attributed to an increased blood pool in the tumor.

Charkes (1) reported a case of a falsely positive ^{87m}Sr scan, which apparently was due to increased vascularity. He considered this phenomenon a source of confusion, particularly in brain scintigraphy, since it is uncertain whether the radionuclide localizes in intracranial tumor or skull metastases. Although that may be the case on many occasions, we think that sometimes ^{87m}Sr visualization of extra-osseous tumors may be diagnostically useful. In our hands, ^{87m}Sr scintigraphy has been particularly helpful in demonstrating recurrent colorectal cancer. In these cases the detection of tumor recurrence by conventional means has been usually unsatisfactory. Other more sophisticated methods, such as lymphangiography and venography, are also of unpredictable efficacy.

Another mechanism explaining localization of strontium in extra-osseous tumors is the presence of calcium in necrotic parts of the tumors. Other tumors may contain foci of osseous metaplasia. These foci may accumulate ^{87m}Sr . The frequent visualization of recurrent colorectal cancer by ^{87m}Sr may be explained by the following hypothesis: Denonvillier's fascia and the bladder wall constitute a barrier to the forward spread of the tumor (8). The tumor therefore extends posteriorly to the presacral space and the sacrum. Periosteal reaction of this bone may result in increased ^{87m}Sr localization without actual bone involvement.

In all our cases there was no radiological evidence of bone disease, but the absence of x-ray findings does not rule out bone invasion. However, we feel that bone disease is not probable for the following reasons. In Cases 1 and 5, breast scans were taken

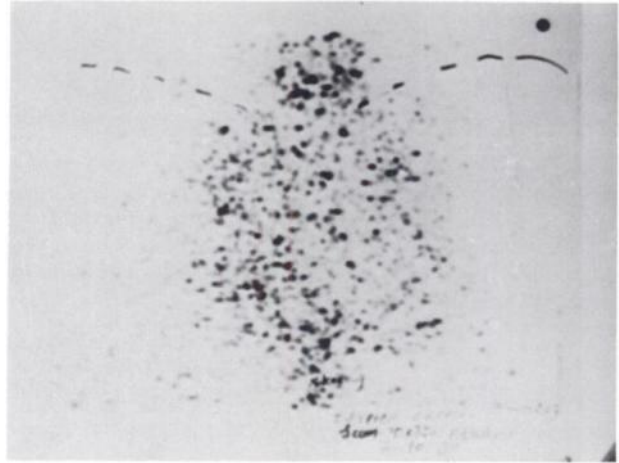


FIG. 4. Case 4. Uptake of ^{87m}Sr by tumor mass located in left half of pelvis.

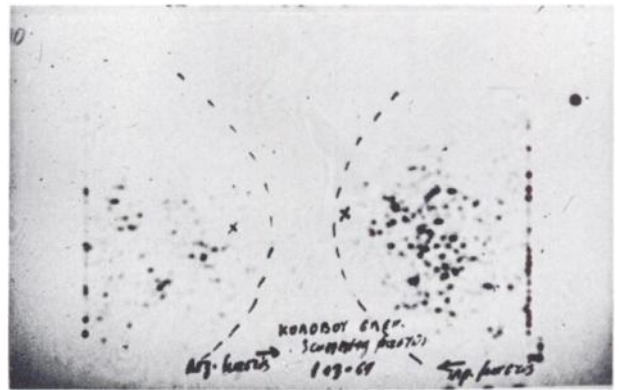


FIG. 5. Case 5. ^{87m}Sr concentration in left breast compared with right one.

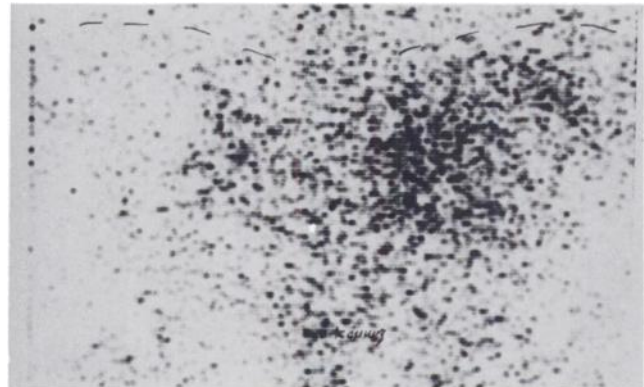


FIG. 6. Case 6. ^{87m}Sr scintigram clearly visualizes tumor.

tangentially to the patients' bodies, and therefore the tumor mass could not be superimposed on bones. Cases 2 and 4 have been followed up by subsequent radiographic examinations for considerable time, and no bone lesions developed. In the posteroanterior scintigram of the neck of Case 3, the radioactivity of the laterally located node was distinctly separate

from the radioactivity of midline structures and the spine. In Case 6, clinical symptomatology had started 2 years before scintigraphy and, although the patient had been repeatedly x-rayed, no bone lesions could be demonstrated.

SUMMARY

Six patients with extra-osseous tumors of various histological types which were visualized by ^{87m}Sr scintigraphy are presented.

REFERENCES

1. CHARKES ND: Some differences between bone scans made with ^{87m}Sr and ^{86}Sr . *J Nucl Med* 10: 491-495, 1969

2. CHARKES ND, SKLAROFF DM: Early diagnosis of metastatic bone cancer by photoscanning with Strontium 85. *J Nucl Med* 5: 168-179, 1964

3. DENARDO GL, VOLPE JA: Detection of bone lesions with Sr 85 scintiscan. *J Nucl Med* 7: 219-223, 1966

4. MECHELENBURG RL: Clinical value of generator produced ^{87m}Sr . *J Nucl Med* 5: 929-935, 1964

5. ROSENTHALL L: Role of strontium 85 in detection of bone disease. *Radiology* 84: 75-82, 1965

6. SAMUELS LD: Lung scanning with ^{87m}Sr in metastatic osteosarcoma. *Amer J Roentgen* 104: 766-769, 1968

7. TOW D, WAGNER HN: Scanning for tumors of brain and bone. *JAMA* 199: 610-614, 1967

8. WELCH C, BURKE J: Carcinoma of the colon and rectum. *New Eng J Med* 266: 211-219, 1962