

**<sup>113m</sup>In SCANNING FOR VISUALIZING AND EVALUATING****GIANT INTRACRANIAL ANEURYSM POSTOPERATIVELY**

E. Lubin, M. Dujovny, J. Israeli, H. Askenasy and Z. Lewitus

*Beilinson Medical Center, Tel Aviv University Medical School, Petah Tiqua, Israel*

Indium-113m is a broad-spectrum scanning agent. When injected intravenously at pH 1.7, it binds to serum transferrin and serves as an excellent blood-pool label (1). Because of this property, it has been useful for studying the blood pool of different organs (2). This report describes a new use of labeled <sup>113m</sup>In-transferrin for visualizing giant intracranial aneurysms in vivo and, more specifically, for evaluating the result of treatment after common carotid ligation. The persistence, reduction, or disappearance of the aneurysmal blood pool can be determined by this nontraumatic scanning method.

**CASE REPORT**

The patient was a 58-year-old mother of two. For the past 15 years she had a persisting abducens palsy and pain over the left eye. For 3 days before admission there had been an increase in pain, and ptosis of the left eyelid appeared.

Physical examination showed a lucid woman in good general condition. She presented ptosis, exophthalmus, internal deviation and palsy of voluntary movements of the left eye. On fundoscopy, temporal pallor of the optic disk of the left eye was found. Electroencephalography showed bilateral slow waves, more accentuated in the left temporal region. Skull plain x-ray showed erosion of the left superior orbital fissure. Angiography of the two carotids and

vertebral arteries was performed, and a huge infraclinoidal aneurysm of the left carotid artery was found (Fig. 1).

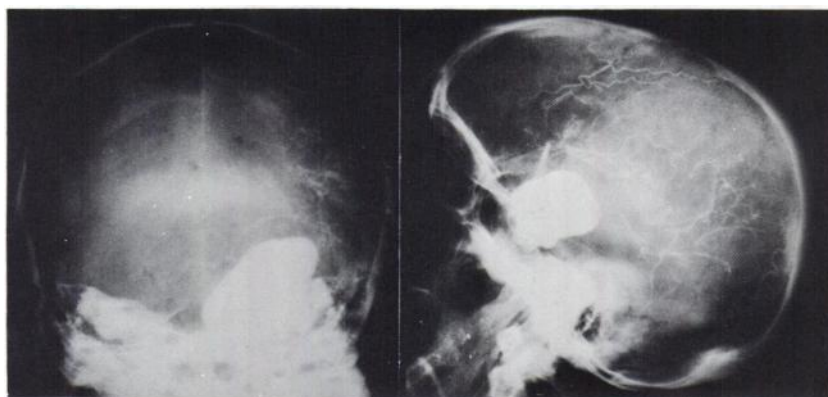
A scan was then performed after the intravenous injection of 4 mCi of <sup>113m</sup>In (pH 1.7) that confirmed the presence of the huge, intracranial, well-limited aneurysmal blood pool (Fig. 2A).

With the aim of reducing blood flow and eventually inducing intra-aneurysmal thrombosis, a Selverstone clamp was applied to the left common carotid artery, and the external carotid was ligated. The clamp was progressively closed during the next 4 days. No neurological complication appeared. By the tenth day after operation there was an apparent reduction in the exophthalmus and an amelioration of the ptosis. A control scan performed under the same technical conditions of the preoperative one showed unequivocal evidence of the disappearance of the intracranial aneurysmal blood pool (Fig. 2B).

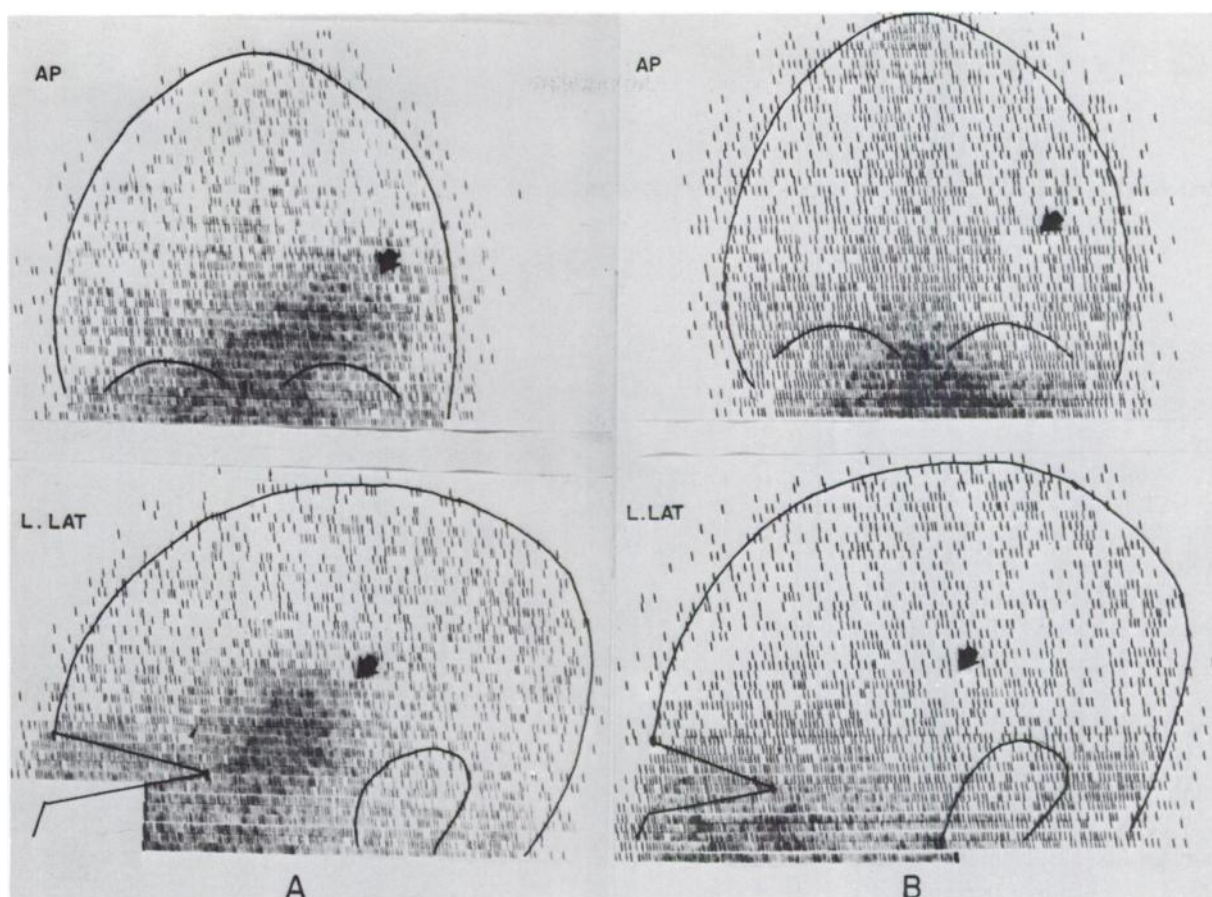
Carotid ligation is an accepted method for treating intracranial aneurysms (3). This is due to the changes that occur distal to the ligation. The mean and pulsatile pressure are reduced simultaneously with a diminished arterial blood flow. A relative

Received Sept. 9, 1970; original accepted Sept. 22, 1970.

For reprints contact: E. Lubin, Dept. of Nuclear Medicine, Beilinson Hospital, Petah Tiqua, Israel.



**FIG. 1.** Left carotid percutaneous arteriogram shows 6 × 4 cm aneurysm in AP view that spreads from midline to middle cranial fossa. In lateral view, giant aneurysm is seen which is oval-shaped and measures 4 × 3 cm, involving carotid siphon and spreading towards sella turcica, upwards and backwards.



**FIG. 2.** A shows AP and left lateral views of brain scan performed after intravenous injection of 4 mCi  $^{113m}\text{In}$ , pH 1.7. Huge blood pool pointed to by arrows corresponds exactly to carotid

aneurysm diagnosed by angiography. B shows postclamping scan, performed under similar technical conditions; scan shows almost complete disappearance of abnormal aneurysmal blood pool.

stasis occurs that favors the formation of an intra-aneurysmal thrombus, this being the aim of the treatment. Nevertheless, there is an incidence of 2–8% of recurrent hemorrhage from a carotid aneurysm after ligation of the carotid artery. This incidence is much higher when the aneurysm is located in the anterior communicating or middle cerebral artery.

The effectiveness of the therapy, and therefore the prognosis, has been uncertain because of the risks and serious difficulties inherent in post-clamping angiography (4).

The use of the  $^{113m}\text{In}$  scan described here provides a nontraumatic means of directly controlling the changes occurring in the blood pool of the aneurysm as a result of clamping. This is a perfectly tolerated, informative, repeatable, and safe method.

Its reliability depends on the clear visualization of the giant aneurysm before ligation. This finding should be used as a basis for comparison when post-operative studies are later performed.

#### REFERENCES

1. ADATEPE MH, WELCH M, ARCHER E, et al: The laboratory preparation of indium-labeled compounds. *J Nucl Med* 9: 426–427, 1968
2. LUBIN E, LAOR J, SHIMEONI A, et al: Two-stage scintiscanning in the differential diagnosis of vascularized and nonvascularized intrahepatic space occupying lesions. *Nuclearmedizin* 9: 17–24, 1970
3. TINDALL GT, ODOM GL: Treatment of intracranial aneurysms by proximal carotid ligation. *Progr Neurol Surg* 3: 66–144, 1969
4. ROSSI P, ROSENBAUM AE, ZINGESSER LH: The fate of the carotid artery after occlusion for treatment of aneurysm. *Radiology* 95: 567–575, 1970