

ELIMINATION OF SALIVARY GLAND UPTAKE BY LEMON (IN VERTEX VIEW OF BRAIN IMAGE)

The vertex view is valuable in brain imaging. However, with the most widely used imaging agent, ^{99m}Tc -pertechnetate, mucosal and salivary activity

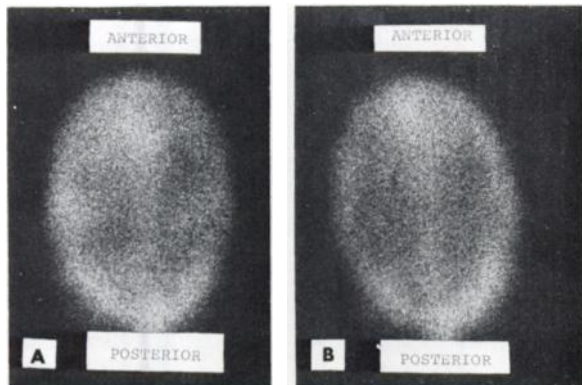


FIG. 1. A shows vertex view taken 1 hr after injection of ^{99m}Tc -pertechnetate without atropine. B shows repeat image immediately after chewing small slice of lemon and washing mouth with water.

obscures the frontal and temporal regions. Atropine may be administered to prevent uptake before imaging. However, in some patients atropine is contraindicated. Also the vertex view can be considered only after uptake by the salivary glands has occurred. Lemon can eliminate this uptake.

A small slice of fresh lemon, given to the patient to chew for a few minutes is followed by water to wash the mouth. A vertex view may be taken immediately afterward. The response to the lemon varies from one patient to another. In some there may be little response. Also, mucosal activity is not affected by lemon. However, it is so simple and safe that it may be worthwhile to try. Figure 1 shows a frequent response.

EN-LIN YEH

Veterans Administration Center
Wood, Wisconsin

INTRANASAL PLEDGETS AND CEREBRAL SPINAL FLUID LEAKS

The use of radioiodinated serum human albumin (IHSA) in lumbar cisternography in the diagnosis of communicating hydrocephalus and cerebral spinal fluid (CSF) rhinorrhea has been clearly established. CSF has been localized with the use of imaging methods, but little emphasis has been placed on the use of intranasal and auricular pledgets to localize the exact region of the cerebral spinal fluid leak.

We recently saw an eight-year-old white male who sustained a severe head injury from a fall at the age of three. His eyes were quite ecchymotic for several weeks following the injury. Since that time he has had three documented episodes of meningitis. At no time was a history of CSF rhinorrhea elicited. On April 26, 1971, a IHSA lumbar cisternography was done. At the 6-hr time frame there was good evidence of a cerebral spinal fluid leak in the nasal region, but it could not be precisely localized as to side. Following the scan the patient was taken to the ENT Clinic where pledgets were placed in the middle meatus and cribriform plate area on both sides. Following removal of the pledgets counts were quite high from the region of the right middle meatus. Two days later the patient was taken to surgery and a 12-mm rent was noted in the dura with a small communication into the anterior ethmoidal area on the right side. This was surgically repaired and the postoperative course has been unremarkable.

The method of IHSA lumbar cisternography consists of administering 50–100 μCi into the lumbar subarachnoid space. Gamma camera scintiphotos are taken at the 2, 6, and 24-hr time frames in the lateral and anterior projections. Since pledgets are quite uncomfortable we have elected to place them intermittently for 20 min after the scans are performed. In this way the discomfort is minimized. The head was placed downward, and mild venous obstruction was used to enhance CSF leak. The short time the pledgets were in was sufficient to give appropriate counting rate differences to determine the area of the cerebral spinal fluid leak. At the time of the placing of the pledgets no fluid was noted from the right middle meatus. The count over the right middle meatus from the pledgets was 1,000 cpm whereas the other areas were essentially background.

We feel that the placement of pledgets at appropriate time frames is useful in determining the precise location of a cerebral spinal fluid leak. This case clearly shows this point.

EUGENE T. MORITA

DAVID L. FORE

ANTHONY TRIPPI

RICHARD W. SEAMAN

Fitzsimmons General Hospital
Denver, Colorado