

TRANSMISSION TECHNIQUE USED FOR POSITIONING FOR CEREBRAL BLOOD FLOW

Using the Nuclear-Chicago Pho/Gamma Scintillation Camera, the rapid-sequential cerebral blood-flow study is easy for us to perform. Correct positioning, however, is extremely important; but, because the patient's head is not yet radioactive, the positioning is difficult. To obtain exact centering, we have devised a positioning technique, adapting the idea from Anger and McRae (1).

The patient's head is placed with the anterior against the collimator, and after careful positioning, his head is taped in place. Six feet behind the patient, a partially shielded syringe of ^{99m}Tc (to be injected later) is waved about so that it passes over the entire area of the crystal face. A scintiphoto can be taken at this time, but this is not necessary if the image is made on the persistence oscilloscope. The patient's head and neck will not transmit the gamma rays and will be black on the scintiphoto. The background will be white since the air and distance will not stop the gamma rays from the active, close-range source. This head and neck "shadow" of the patient will show the technologist if the centering is correct and is especially helpful in getting

the vertex as close to the top of the picture as possible to get the entire neck in the view. Although most of the time the positioning will be correct initially, this is one way of making certain and insuring that this part of the procedure will be correct.

Figure 1 shows improper positioning of the patient's head for a cerebral blood flow study. Cerebral vasculature will be visualized, but the head should be moved up to fill the field of view.

Figure 2 shows the position as it has been corrected, allowing visualization of major neck arteries as well as cerebral vasculature. Note that the vertex comes close to, but does not touch, the top.

BARBARA J. JUMP
North Charles General Hospital
Baltimore, Maryland

REFERENCE

1. ANGER, H. O. AND MCRAE, J.: Transmission scintiphotography. *J. Nucl. Med.* 9:267, 1968.

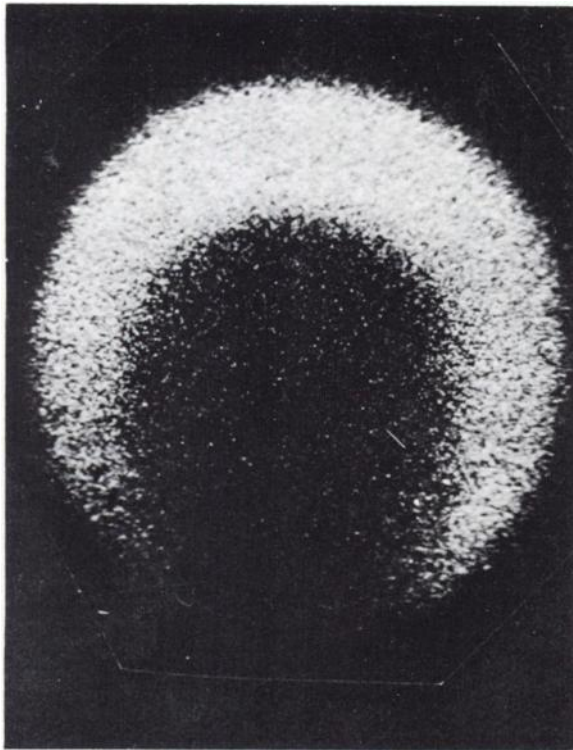


FIG. 1. Improper positioning with head not filling field of view. Major neck arteries will not be seen on cerebral blood flow.

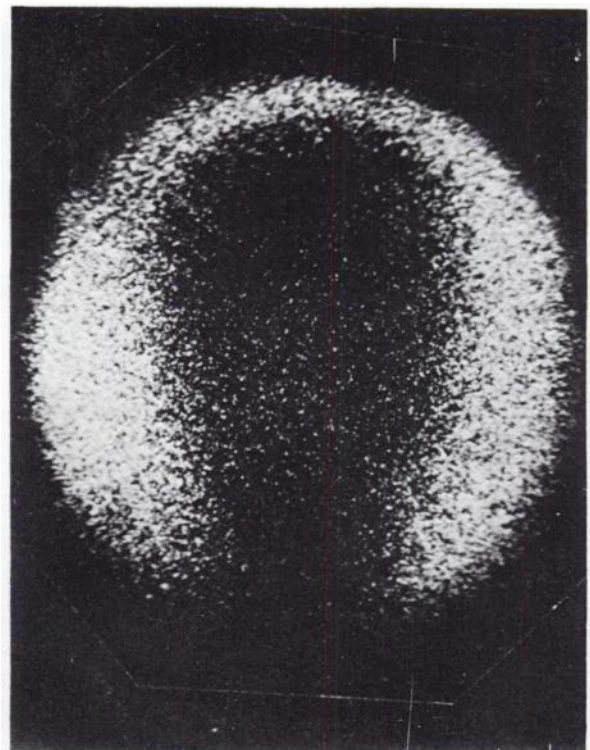


FIG. 2. Correct positioning with entire head and neck in field of view.