

# Does $^{18}\text{F}$ -FDG PET/CT Improve the Detection of Posttreatment Recurrence of Head and Neck Squamous Cell Carcinoma in Patients Negative for Disease on Clinical Follow-up?

Ronan Abgral<sup>1</sup>, Solène Querellou<sup>1</sup>, Gaël Potard<sup>2</sup>, Pierre-Yves Le Roux<sup>1</sup>, Alexandra Le Duc-Pennec<sup>1</sup>, Remi Marianovski<sup>2</sup>, Olivier Pradier<sup>3</sup>, Yves Bizais<sup>1</sup>, Françoise Kraeber-Bodéré<sup>4</sup>, and Pierre Y. Salaun<sup>1</sup>

<sup>1</sup>Nuclear Medicine Department, University Hospital of Brest, Brest, France; <sup>2</sup>Department of Head and Neck Surgery, University Hospital of Brest, Brest, France; <sup>3</sup>Department of Radiotherapy, University Hospital of Brest, Brest, France; and <sup>4</sup>Nuclear Medicine Department, University Hospital of Nantes, Nantes, France

Posttreatment surveillance for the recurrence of head and neck squamous cell carcinoma (HNSCC) is a diagnostic challenge. Tissue distortion from radiation and surgery can obscure early detection of recurrence by conventional follow-up approaches such as physical examination, CT, and MRI. Several studies have shown that  $^{18}\text{F}$ -FDG PET may be an effective technique for the detection of persistent, recurrent, and distant metastatic HNSCC after treatment. The aim of this prospective study was to determine the benefits of hybrid  $^{18}\text{F}$ -FDG PET/CT in detecting a subclinical locoregional recurrence of HNSCC and distant metastases. The study patients were considered cured of HNSCC on the basis of 12 mo of negative findings on conventional follow-up. We also assessed the diagnostic accuracy of  $^{18}\text{F}$ -FDG PET/CT in these patients. **Methods:** Ninety-one patients cured of HNSCC without any clinical evidence of recurrence were included. Whole-body  $^{18}\text{F}$ -FDG PET/CT examination was performed  $11.6 \pm 4.4$  mo after the end of the treatment. The gold standard was histopathology or 6 mo of imaging follow-up. **Results:** The whole-body  $^{18}\text{F}$ -FDG PET/CT examinations had negative results in 52 patients and positive results in 39. Nine of these patients who exhibited abnormal  $^{18}\text{F}$ -FDG uptake in the head and neck area did not have recurrent HNSCC (false-positive). Thirty had proven recurrence. The sensitivity and specificity of  $^{18}\text{F}$ -FDG PET/CT in this study for the diagnosis of HNSCC recurrence were 100% (30/30) and 85% (52/61), respectively. The positive predictive value was 77% (30/39). The negative predictive value was 100% (52/52). The overall accuracy was 90% (82/91). **Conclusion:** The results of our study confirm the high effectiveness of  $^{18}\text{F}$ -FDG PET/CT in the assessment of HNSCC recurrence and suggest that  $^{18}\text{F}$ -FDG PET/CT is more accurate than conventional follow-up physical examination alone in the assessment of recurrence after previous curative treatment for HNSCC and could be proposed systematically at 12 mo of the usual follow-up.

**Key Words:** squamous cell carcinoma; head and neck cancer; positron emission tomography; fluorodeoxyglucose

**J Nucl Med 2009; 50:24–29**

DOI: 10.2967/jnumed.108.055806

**H**ead and neck squamous cell carcinoma (HNSCC) is the eighth most common malignancy worldwide and refers to a group of malignancies involving the upper aerodigestive tract including the oral cavity, oropharynx, nasopharynx, hypopharynx, and larynx. Patients with head and neck tumors raise many diagnostic and therapeutic challenges. Their disease course is often complicated by recurrent disease, regional lymphatic spread, synchronous primary tumors, and distant metastases. Despite aggressive combined-modality treatment regimens, there remains a high rate (up to 40%) of locoregional recurrences (1). Moreover, two thirds of locoregional recurrences and lymph node metastases occur within the first 2 y (2).

Posttreatment surveillance of HNSCC recurrence is a diagnostic challenge. Tissue distortion from radiation and surgery can obscure early detection of residual tumor and recurrence by the conventional follow-up approaches such as physical examination, CT, and MRI (3).

The usual follow-up consists of periodic standard examinations of the head and neck during the 5 y after treatment, including inspection and palpation of all anatomic subsites of the head and neck (oral cavity, nasopharynx, oropharynx, hypopharynx, and larynx) and examination of internal structures by a mirror and a flexible endoscope (4).

$^{18}\text{F}$ -FDG PET may be an effective technique for the detection of residual tumor recurrence and distant metastases after treatment. Through the identification of metabolic changes, clinicians may be able to overcome the limitations that posttreatment tissue changes bring to conventional anatomy-oriented surveillance.

Received Jul. 9, 2008; revision accepted Sep. 16, 2008.

For correspondence or reprints contact: Pierre Y. Salaun, Nuclear Medicine Department, University Hospital of Brest, Boulevard Tanguy Prigent, 29200 Brest, France.

E-mail: pierre-yves.salaun@chu-brest.fr

COPYRIGHT © 2009 by the Society of Nuclear Medicine, Inc.

Several retrospective (5–8) and prospective (9–11) studies have shown that <sup>18</sup>F-FDG PET may be useful in detecting posttreatment recurrent HNSCC and be more effective than physical examination, CT, or MRI in doing so. However, in prior tumor recurrence studies, patients were commonly enrolled if recurrence was suspected. The advantage of a test that can detect subclinical recurrence was thereby unlikely to be demonstrated. We previously reported in a retrospective study (12) that <sup>18</sup>F-FDG PET truly found unsuspected recurrence in 8 of 30 patients considered cured of HNSCC with negative findings on the usual follow-up.

The aim of this prospective study was to determine the benefits of hybrid <sup>18</sup>F-FDG PET/CT in detecting a subclinical locoregional recurrence of HNSCC and distant metastases. The study patients were considered cured of HNSCC on the basis of 12 mo of negative findings on conventional follow-up. We also assessed the diagnostic accuracy of <sup>18</sup>F-FDG PET/CT in these patients.

## MATERIALS AND METHODS

### Inclusion Criteria

All patients treated for histologically proven HNSCC from September 2005 to January 2008 at the University Hospital of Brest and at the Regional Hospital of Quimper and who did not show any findings suggestive of recurrence at 12 mo of their usual follow-up (consisting of a standard whole-body examination including inspection and palpation of all anatomic subsites of the head and neck [oral cavity, nasopharynx, oropharynx, hypopharynx and larynx] and an examination of internal structures by a mirror and a flexible endoscope) were included in the study. Patients with distant metastasis at the initial staging and with a previous history of recurrence were excluded.

### Whole-Body <sup>18</sup>F-FDG PET/CT

Scans were performed on a Gemini GXLi PET/CT scanner (Philips). Patients fasted 4 h before PET acquisitions, and the blood glucose level had to be less than 7 mmol/L before injection of 370 MBq (5 MBq/kg) of <sup>18</sup>F-FDG. Intravenous injection was followed by a period of approximately 60 min when the patients remained in a quiet room. No muscle relaxants were administered. The patients were allowed to breathe normally during the PET and CT acquisitions. PET data were acquired in the 3-dimensional mode and, for attenuation correction, were reconstructed using CT data and a row-action maximum-likelihood iterative algorithm. The Gemini scanner consists of a 6-slice multi-detector-row spiral CT scanner with a transverse field of view of 600 mm. The CT parameters—a collimation of 6 × 5 mm, tube voltage of 120 kV, and effective tube current of 100 mAs—are standard for PET/CT studies and permit differentiation between tissues with good spatial resolution while ensuring that the patient does not receive a high radiation dose.

### Image Interpretation

All <sup>18</sup>F-FDG PET/CT images were interpreted qualitatively by 2 nuclear medicine physicians without prior knowledge of the follow-up status of these patients. Any initial difference of interpretation was resolved by consensus. For each <sup>18</sup>F-FDG

PET/CT scan report, the results were divided into 3 regions: primary, neck, and distant. The primary region included any sites along the aerodigestive tract from the nasal cavity and oral cavity to the trachea. The neck included the lymph node areas, soft tissues of the neck surrounding (but not including) the trachea, larynx cartilages, hyoid bone, and cervical spine. The distant regions included the brain, skeleton, thorax, mediastinum, and abdomen.

### Outcome Determination and Data Analysis

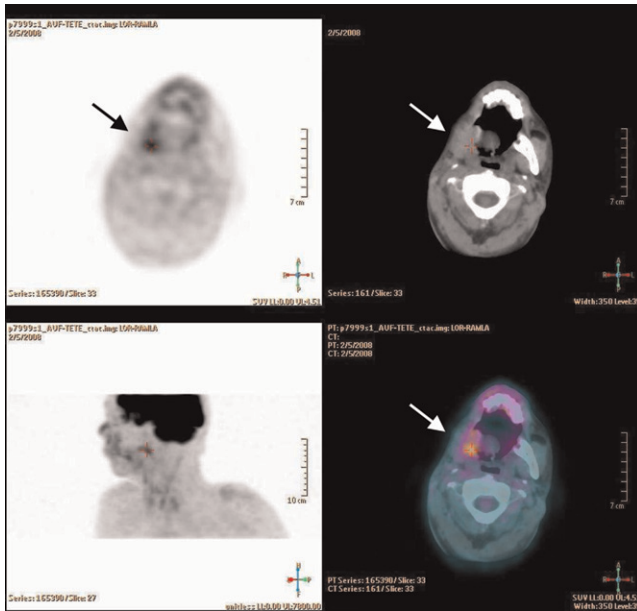
<sup>18</sup>F-FDG PET/CT image findings were correlated with histopathology for locoregional findings and with radiography, CT, or MRI for distant findings. PET/CT findings of disease were considered true-positive if they correlated with histopathology findings positive for locoregional recurrence or with follow-up morphologic imaging findings positive for progression or distant metastasis. Each patient with negative <sup>18</sup>F-FDG PET/CT results was seen clinically 6 mo after the PET/CT examination for the usual follow-up. Absence of evidence of recurrence at that time was considered a reference for determining that no true disease was present at the time of the <sup>18</sup>F-FDG PET/CT examination.

The sensitivity, specificity, positive predictive value, negative predictive value, and overall accuracy of <sup>18</sup>F-FDG PET/CT and the prevalence of malignancy in the asymptomatic patient sample were determined. The calculations were performed separately for each of the 3 anatomic regions (primary, neck, and distant), the head and neck region (primary and neck regions together), and the whole body (primary, neck, and distant regions together).

**TABLE 1. Patient and Disease Characteristics According to <sup>18</sup>F-FDG PET/CT Results**

Characteristic	PET/CT	
	Negative (n = 52)	Positive (n = 39)
Mean age ± SD (y)	58.2 ± 10.2	57.2 ± 9.1
Sex (n)		
Male	45	33
Female	7	6
Original tumor site (n)		
Oral cavity	11	14
Oropharynx	15	11
Hypopharynx	7	5
Larynx	18	9
Nasopharynx	1	0
Initial stage (n)		
I	4	1
II	11	7
III	9	9
IV	28	22
Primary treatment		
Surgery alone	7	6
Surgery and radiotherapy	28	15
Radiotherapy alone	4	0
Concurrent chemotherapy	10	14
Induction chemotherapy followed by radiotherapy or surgery	3	4
Mean duration (±SD) after therapy (mo)	12.3 ± 4.1	10.7 ± 4.7

RGB



**FIGURE 1.** Transaxial <sup>18</sup>F-FDG PET/CT images demonstrate true-positive focus (arrow) representing recurrent oral cavity carcinoma 12 mo after surgery.

**RESULTS**

Ninety-one patients, 13 women and 78 men, with a mean age of 57.4 ± 9.4 y were included in the study. Patient characteristics and pathologic status are summarized in

[Table 1] Table 1.

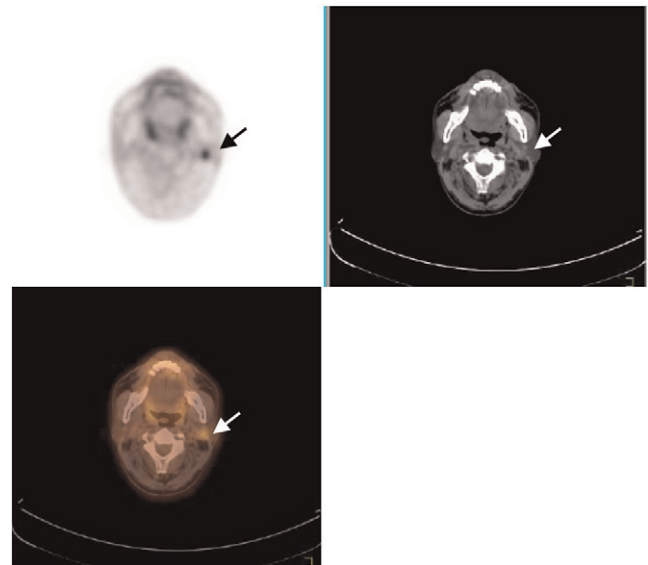
The whole-body <sup>18</sup>F-FDG PET/CT results were negative in 52 patients and positive in 39. For 30 of 39 patients with positive findings, recurrence was confirmed. Fourteen patients had only local recurrence (Fig. 1) (6 in the oral cavity, 1 in the hypopharynx, 6 in the oropharynx, and 1 in the laryngeal area); for 2, an associated cervical lymph node extension was confirmed by biopsy. Twelve had distant metastasis confirmed on the basis of progression seen on CT or histologically. Among them, 2 had both local recurrence confirmed by biopsy and distant metastases (1 in the oral cavity and 2 in the larynx, both with a lung metastasis) confirmed by CT, and 1 had local recurrence, a neck lymph node extension, and distant metastasis. For 17 patients, salvage surgery was performed; 10 patients underwent chemotherapy or palliative treatment; 2 patients refused therapy; and for 1 patient nothing was done. Nine of the 39 patients who exhibited abnormal <sup>18</sup>F-FDG uptake in the laryngeal area did not have recurrent HNSCC despite many biopsies

[Fig. 2] (false-positive; Figs. 2 and 3). The detailed results of these patients are shown in Table 2.

All 52 patients with negative findings on <sup>18</sup>F-FDG PET/CT remained free of disease at 3 mo after each PET/CT examination, and for no one was evidence of malignancy on physical examination found during this period.

[Table 3] As shown in Table 3, the sensitivity and specificity of <sup>18</sup>F-FDG PET/CT in this study for the diagnosis of HNSCC recurrence were 100% (30/30) and 85% (52/61), respec-

RGB



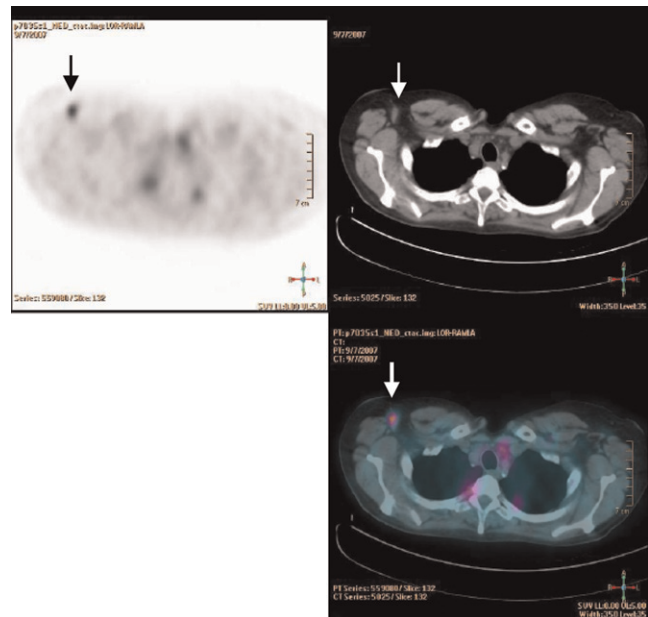
**FIGURE 2.** Transaxial <sup>18</sup>F-FDG PET/CT images demonstrate false-positive focus (arrow) not confirmed by ultrasonography and follow-up of oral cavity carcinoma 12 mo after surgery.

tively. The positive predictive value was 77% (30/39). The negative predictive value was 100% (52/52). The overall accuracy was 90% (82/91).

**DISCUSSION**

A delay in the detection of recurrent HNSCC has been shown to be deleterious to clinical outcome after treatment. Patients with recurrent, early-stage HNSCC who undergo

RGB



**FIGURE 3.** Transaxial <sup>18</sup>F-FDG PET/CT images demonstrate false-positive focus (arrow) corresponding after biopsy to *Bartonella henselae* infection 12 mo after surgery and radiochemotherapy of oral cavity carcinoma.

**TABLE 2. Patients with Positive <sup>18</sup>F-FDG PET/CT Data**

Patient no.	Original tumor site	Initial stage	PET/CT finding	Confirmatory recurrence	
				Pathology	Correlative imaging
1	Hypopharynx	IV	Local Distant (lung)	Negative —	— Positive
2	Larynx	IV	Distant (lung, bone, liver)	—	Positive
3	Oral cavity	IV	Local Regional (lymph nodes)	Positive Positive	— —
4	Oropharynx	III	Distant (lung)	—	Positive
5	Oropharynx	III	Local	Positive	—
6	Oropharynx	IV	Regional (lymph nodes)	Positive	—
7	Oropharynx	IV	Local	Positive	—
8	Larynx	II	Regional (lymph nodes)	—	Negative
9	Larynx	IV	Regional (lymph nodes)	Positive	—
10	Larynx	IV	Local	Positive	—
11	Oral cavity	II	Local	Positive	—
12	Larynx	III	Local Distant (lung)	Positive —	— Positive
13	Oropharynx	IV	Local	Positive	—
14	Hypopharynx	IV	Local	Negative	—
15	Oropharynx	IV	Distant (lung)	—	Negative
16	Oropharynx	IV	Distant (lung)	Positive	—
17	Oral cavity	IV	Distant (bone)	—	Positive
18	Oropharynx	III	Local	Positive	—
19	Hypopharynx	II	Local	Positive	—
20	Larynx	IV	Local Distant (lung)	Negative —	Positive —
21	Hypopharynx	IV	Distant (liver)	Negative	—
22	Oral cavity	II	Distant (lung)	—	Positive
23	Hypopharynx	IV	Local Regional (lymph nodes)	Positive Positive	— —
24	Oral cavity	II	Distant (lung, bone, liver)	—	Positive
25	Oropharynx	IV	Local	Positive	—
26	Oral cavity	II	Local	Positive	—
27	Larynx	IV	Local	Negative	—
28	Larynx	III	Local	Negative	—
29	Oral cavity	IV	Local	Positive	—
30	Oropharynx	II	Local	Positive	—
31	Oral cavity	III	Local Distant (lung)	Positive —	— Positive
32	Oropharynx	IV	Local	Negative	—
33	Oral cavity	I	Regional (lymph nodes)	—	Negative
34	Oral cavity	IV	Local	Positive	—
35	Larynx	IV	Local Regional (lymph nodes) Distant (lung)	Positive Positive —	— — Positive
36	Oral cavity	III	Distant (lymph nodes)	Negative	—
37	Oral cavity	III	Local	Positive	—
38	Oral cavity	IV	Distant (lung)	Positive	—
39	Oral cavity	III	Local	Positive	—

Patients 1 and 20: true-positive for one localization and false-positive for the other.  
 Patient 37: true-positive for one localization and false-negative for the other (regional lymph nodes).

salvage surgery have a 70% 2-y relapse-free survival, whereas those with recurrent, advanced-stage HNSCC undergoing surgical salvage have just a 22% 2-y relapse-free survival (13). Early diagnosis and accurate identification of recurrent HNSCC are therefore critically important for successful treatment. Sequential physical examinations are generally

accepted for posttherapy follow-up of patients with head and neck cancer. The National Comprehensive Cancer Network panel suggests a general consensus surveillance schedule: physical examination every 1–3 mo during the first year, every 2–4 mo during the second year, every 4–6 mo during the next 3 y, and every 6–12 mo thereafter (14,15). However, physical

**TABLE 3.** Diagnostic Value of  $^{18}\text{F}$ -FDG PET/CT in Detection of Recurrence for 91 HNSCC Asymptomatic Patients

	PET/CT result		
	Positive	Negative	Total
Confirmatory recurrence			
Positive recurrence	30	0	30
Negative recurrence	9	52	61
Total	39	52	91

examination can be compromised by granulation, fibrosis, tissue edema, and necrosis.  $^{18}\text{F}$ -FDG PET can identify viable tumor on the basis of higher glycolytic rates in neoplasm than in necrotic or reactive tissues (16).

Our study showed that  $^{18}\text{F}$ -FDG PET/CT is a useful tool in detecting recurrent HNSCC during posttreatment surveillance despite negative findings on follow-up physical examinations. In addition to its ability to detect the presence of locoregional disease in these patients,  $^{18}\text{F}$ -FDG PET/CT provided significant additional information. Thirty of 91 patients had a proven recurrence that was not discovered by the usual sequential physical examinations. This high level of recurrence agrees with the usual recurrence rates (>30% during the first 3 y (4,17), even in asymptomatic patients (18)). The study suggests an earlier detection of the recurrence that probably will be found later during the usual follow-up. For 9 patients,  $^{18}\text{F}$ -FDG PET/CT had positive results despite the absence of recurrent disease. These patients probably had local inflammation, and one had mandibular osteoradionecrosis, which is known to cause false-positive results. This is in agreement with many studies that have proven the need to delay imaging after the end of radiotherapy to minimize persistent inflammatory changes (19,20). Moreover, false-positive results may occur with  $^{18}\text{F}$ -FDG PET because of infections; physiologically increased uptake in structures such as the palatine tonsils and salivary glands (salivary gland cancers are typically not  $^{18}\text{F}$ -FDG-avid) and the masticator, oral cavity, neck, and laryngeal muscles; uptake in reactive nonneoplastic lymph nodes; uptake after surgery; and uptake in noninfectious inflammation and granulation at the surgical site (flare phenomenon). Uptake in muscles may be asymmetric and is usually due to anxiety, with laryngeal and masticator activity after  $^{18}\text{F}$ -FDG injection. Coregistered images with  $^{18}\text{F}$ -FDG PET/CT allow a direct correlation between  $^{18}\text{F}$ -FDG uptake and anatomic structures, thus reducing false-positive results. Attenuation-correction artifacts result from erroneous overcorrection of PET emission data by software that uses CT transmission data for attenuation correction. These artifacts occur in areas that have a high attenuation on corresponding CT images (e.g., metallic implants) but can usually be detected by evaluating the uncorrected emission  $^{18}\text{F}$ -FDG PET data (21).

When the results of  $^{18}\text{F}$ -FDG PET are negative, the likelihood of recurrent malignancy is low (at least at 6 mo of follow-up), but it should not underestimate a possible false-negative, as when malignancy is present in structures

with a physiologically elevated metabolism (e.g., tonsillar carcinoma), when the tumor is smaller than the resolution of current PET/CT scanners (typically 10 mm for PET scanners), or when the tumor is not  $^{18}\text{F}$ -FDG-avid. Therefore, careful surveillance and continued follow-up are still probably needed in those patients with a high risk of recurrence (21). A negative predictive value of 100% gives clinical confidence that a false-negative result is unlikely. Moreover, with a sensitivity of 100%, if malignancy is present,  $^{18}\text{F}$ -FDG PET will produce positive findings. Nevertheless, with a specificity of 85%, unnecessary explorations are performed in less than 15%.

Few other studies have evaluated other imaging modalities such as CT and MRI in such treated and asymptomatic patients. However, in a recent review of trials evaluating PET for detecting residual or recurrent HNSCC in undifferentiated patients treated by radiotherapy or chemoradiotherapy, among 27 of 1,871 identified studies the pooled sensitivity and specificity of PET for detecting residual or recurrent HNSCC were 94% and 82%, respectively, whereas the CT mean pooled sensitivity and specificity were lower (67% and 78%, respectively), as were the sensitivity and specificity of MRI (81% and 46%, respectively) (22). In another recent review of 21 articles comparing  $^{18}\text{F}$ -FDG PET, CT, and MRI for the diagnosis of local residual or recurrent nasopharyngeal carcinoma, the pooled sensitivity estimates for PET (95%) were significantly higher than those for CT (76%) ( $P < 0.001$ ) or MRI (78%) ( $P < 0.001$ ) and the pooled specificity estimates for PET (90%) were significantly higher than those for CT (59%) ( $P < 0.001$ ) or MRI (76%) ( $P < 0.001$ ) (23). Moreover, in a prospective study comparing  $^{18}\text{F}$ -FDG PET, CT, and MRI for the initial evaluation of 134 oral SCC patients with a palpably negative neck, Ng et al. found  $^{18}\text{F}$ -FDG PET to have a sensitivity 2-fold higher than CT or MRI in the detection of nodal metastases (41.2% vs. 21.6%, respectively;  $P = 0.021$ ) (24). These data confirm the possible superiority of PET in detecting asymptomatic recurrences.

Several posttreatment studies found  $^{18}\text{F}$ -FDG PET to have a similar accuracy for the detection of locoregional and distant recurrence of HNSCC. In these studies, sensitivities ranged from 92% to 100%, specificities from 64% to 100%, PPVs from 64% to 100%, NPVs from 92% to 100%, and overall accuracy from 88% to 91% (5–11). The lowest specificities are explained by false-positive findings in irradiated regions within 6 mo after therapy. Radiotherapy-induced inflammatory processes may lead to a transient increase in  $^{18}\text{F}$ -FDG uptake (25). In our study, the specificity was high because we performed, as proposed by Greven et al., the  $^{18}\text{F}$ -FDG PET at least 3 mo after the completion of treatment (26). However, in the recurrence studies, patients were commonly enrolled if recurrence was suspected. Lowe et al. and Ryan et al. have shown that  $^{18}\text{F}$ -FDG PET may be useful, too, in asymptomatic patients (18,27). Our results confirmed these data and the conclusion of our preliminary study (12).

## CONCLUSION

The results of our study confirmed the high effectiveness of  $^{18}\text{F}$ -FDG PET/CT in assessing for recurrence of HNSCC in patients who have been considered cured of the disease. Our findings suggest that  $^{18}\text{F}$ -FDG PET/CT is more accurate than conventional follow-up physical examinations alone in such patients. The systematic use of PET/CT at 12 mo of the usual follow-up could be proposed, but cost-effectiveness and survival impact remain to be evaluated.

## REFERENCES

1. Ang KK, Trotti A, Brown BW, et al. Randomized trial addressing risk features and time factors of surgery plus radiotherapy in advanced head-and-neck cancer. *Int J Radiat Oncol Biol Phys*. 2001;51:571–578.
2. Leemans CR, Tiwari R, Nauta JJP, van der Waal DDS, Snow GB. Recurrence at the primary site in head and neck cancer and the significance of neck lymph node metastases as a prognostic factor. *Cancer*. 1994;73:187–190.
3. Lell M, Baum U, Greess H, et al. Head and neck tumors: imaging recurrent tumor and post-therapeutic changes with CT and MRI. *Eur J Radiol*. 2000;33:239–247.
4. Haas I, Hauser U, Ganzner U. The dilemma of follow-up in head and neck cancer patients. *Eur Arch Otorhinolaryngol*. 2001;258:177–183.
5. Hanasono MM, Kunda LD, Segall GM, et al. Uses and limitations of FDG positron emission tomography in patients with head and neck cancer. *Laryngoscope*. 1999;109:880–885.
6. Fischbein NJ, AAssar OS, Caputo GR, et al. Clinical utility of positron emission tomography with  $^{18}\text{F}$ -fluorodeoxyglucose in detecting residual/recurrent squamous cell carcinoma of the head and neck. *Am J Neuroradiol*. 1998;19:1189–1196.
7. Wong RJ, Lin DT, Schoder H, et al. Diagnostic and prognostic value of [ $^{18}\text{F}$ ]fluorodeoxyglucose positron emission tomography for recurrent head and neck squamous cell carcinoma. *J Clin Oncol*. 2002;20:4199–4208.
8. Kunkel M, Forster GJ, Reichert TE, et al. Detection of recurrent oral squamous cell carcinoma by [ $^{18}\text{F}$ ]-2-fluorodeoxyglucose-positron emission tomography: implications for prognosis and patient management. *Cancer*. 2003;98:2257–2265.
9. Kitagawa Y, Nishizawa S, Sano K, et al. Prospective comparison of FDG PET with conventional imaging modalities (MRI, CT, and  $^{67}\text{Ga}$  scintigraphy) in assessment of combined intraarterial chemotherapy and radiotherapy for head and neck carcinoma. *J Nucl Med*. 2003;44:198–206.
10. Stokkel MP, Terhaard CH, Hordijk GJ, van Rijk PP. The detection of local recurrent head and neck cancer with fluorine-18 fluorodeoxyglucose dual-head positron emission tomography. *Eur J Nucl Med*. 1999;26:767–773.
11. Terhaard CH, Bongers V, van Rijk PP, Hordijk GJ. F-18-fluoro-deoxy-glucose positron-emission tomography scanning in detection of local recurrence after radiotherapy for laryngeal/pharyngeal cancer. *Head Neck*. 2001;23:933–941.
12. Salaun PY, Abgral R, Querellou S, et al. Does  $^{18}\text{F}$ -fluoro-fluorodeoxyglucose positron emission tomography improve recurrence detection in patients cured of head and neck squamous cell carcinoma with negative clinical follow up? *Head Neck*. 2007;29:1115–1120.
13. Goodwin WJ. Salvage surgery for patients with recurrent squamous cell carcinoma of the upper aerodigestive tract: When do the ends justify the means? *Laryngoscope*. 2000;110:1–18.
14. National Comprehensive Cancer Network. NCCN Clinical Practice Guidelines in Oncology: Head and Neck Cancers, V.2.2008. Available at: [http://www.nccn.org/professionals/physician\\_gls/PDF/head-and-neck.pdf](http://www.nccn.org/professionals/physician_gls/PDF/head-and-neck.pdf). Accessed November 20, 2008.
15. Schwartz DL, Barker J Jr, Chansky K, et al. Postradiotherapy surveillance practice for head and neck squamous cell carcinoma: too much for too little? *Head Neck*. 2003;25:990–999.
16. Wahl RL. Targeting glucose transporters for tumor imaging: “sweet” idea, “sour” result. *J Nucl Med*. 1996;37:1038–1041.
17. Ritoe SC, Krabbe PF, Kaanders JH, van den Hoogeb FJ, Verbeek AL, Marres HA. Value of routine follow up for patients cured of laryngeal carcinoma. *Cancer*. 2004;101:1382–1389.
18. Lowe VJ, Boyd JH, Dunphy FR, et al. Surveillance for recurrent head and neck cancer using positron emission tomography. *J Clin Oncol*. 2000;18:651–658.
19. Bombardieri E, Crippa F. The increasing impact of PET in the diagnostic work-up of cancer patients. In: Freeman L, ed. *Nuclear Medicine Annual 2002*. Philadelphia, PA: Lippincott Williams and Wilkins; 2002:75–121.
20. Kubota K, Yokoyama J, Yamaguchi K, et al. FDG-PET delayed imaging for the detection of head and neck cancer recurrence after radio-chemotherapy: comparison with MRI/CT. *Eur J Nucl Med Mol Imaging*. 2004;31:590–595.
21. Kapoor V, Fukui MB, McCook BM. Role of  $^{18}\text{F}$ FDG PET/CT in the treatment of head and neck cancers: posttherapy evaluation and pitfalls. *AJR*. 2005;184:589–597.
22. Isles MG, McConkey C, Mehanna HM. A systematic review and meta-analysis of the role of positron emission tomography in the follow up of head and neck squamous cell carcinoma following radiotherapy or chemoradiotherapy. *Clin Otolaryngol*. 2008;33:210–222.
23. Liu T, Xu W, Yan WL, Ye M, Bai YR, Huang G. FDG-PET, CT, MRI for diagnosis of local residual or recurrent nasopharyngeal carcinoma, which one is the best? A systematic review. *Radiother Oncol*. 2007;85:327–335.
24. Ng SH, Yen TC, Chang JT, et al. Prospective study of [ $^{18}\text{F}$ ]fluorodeoxyglucose positron emission tomography and computed tomography and magnetic resonance imaging in oral cavity squamous cell carcinoma with palpably negative neck. *J Clin Oncol*. 2006;24:4367–4368.
25. Mitsuhashi N, Hayakawa K, Hasegawa M, et al. Clinical FDG-PET in diagnosis and evaluation of radiation response of patients with nasopharyngeal tumor. *Anticancer Res*. 1998;18:2827–2832.
26. Greven KM, Williams DW III, Keyes JW Jr, et al. Positron emission tomography of patients with head and neck carcinoma before and after high dose irradiation. *Cancer*. 1994;74:1355–1359.
27. Ryan WR, Willard EF, Quynh-Thu L, Harlan AP. Positron-emission tomography for surveillance of head and neck cancer. *Laryngoscope*. 2005;115:645–650.