

CEREBROSPINAL FLUID RHINORRHEA STUDIED WITH THE GAMMA SCINTILLATION CAMERA

William L. Ashburn, John C. Harbert, William H. Briner and Giovanni Di Chiro

National Institutes of Health, Bethesda, Maryland

Although relatively uncommon, cerebrospinal fluid rhinorrhea poses one of the most difficult diagnostic problems in neurosurgery. Occasionally it is difficult to establish whether or not a rhinorrhea is of spinal-fluid origin, and identifying the exact site of the leak is frequently impossible before an exploratory craniotomy. Many patients must be placed on prophylactic doses of antibiotics for extended periods to prevent repeated bouts of meningitis, which are the usual result of CSF rhinorrhea.

Most cases of CSF rhinorrhea occur as a result of head trauma although nontraumatic (spontaneous) CSF rhinorrhea has been reported (1). The usual sites of leak are shown in Fig. 1.

A number of diagnostic procedures have been tried in the past to demonstrate the site of a CSF leak. These procedures have included radiographic (2,3) and radioisotopic (4,5) techniques as well as methods using dyes (6) and fluorescent substances (7,8). However, these methods have seldom provided a clear correlation between the site of leak and the anatomy of the intracranial cisternal

spaces. For example, even if a basal skull fracture can be demonstrated by x-ray tomography, there is no assurance that this area is the one associated with the discontinuity in the dura and arachnoid membrane responsible for the CSF leakage. Pneumoencephalography is rarely capable of demonstrating the site of leak because it is usually impossible to cause air to pass through the meningeal-bony disruption. Radiographic techniques using iodinated contrast agents such as Pantopaque have been only rarely successful (9-12).

The technique of radioisotope cisternography was first described by one of us (Di Chiro, 13); in this method 100 μ c of high-specific-activity ^{131}I -labeled human serum albumin was injected into the lumbar subarachnoid space. Serial rectilinear scanning of the head provided an opportunity to visualize the normal flow of spinal fluid in areas never before observed without significantly altering the hydrodynamics of the CSF. With this technique it has been possible to demonstrate the site of leak in a number of cases of CSF rhinorrhea (14,15). These studies are all performed with the patient's head either in the supine or prone position. While studies in this position are easily accomplished with the NIH-developed four-detector "Tetrascanner" (16) which provides simultaneous anterior, posterior and lateral scan views, it is, as yet, impossible to perform lateral rectilinear scans of the head in the prone position with currently available commercial scanners.

The recent availability of the Anger-type gamma scintillation camera and the use of $^{99\text{m}}\text{Tc}$ -labeled albumin have appreciably extended the diagnostic capabilities of radioisotope cisternography especially where used for demonstrating the site of CSF leakage. Many of these patients must be examined in rather awkward positions, such as extreme neck




FIG. 1. Usual sites of CSF leakage into nasopharynx are through frontal sinus, cribriform plate, sphenoid roof and petrous bone by way of middle ear and eustachian tube.

Received Oct. 10, 1967; revision accepted Jan. 22, 1968.

For reprints contact: W. L. Ashburn, Univ. of California San Diego Hospital, 225 W. Dickinson St., San Diego, Calif. 92103.

flexion, to elicit the maximum flow of CSF through the site of leak, and it is here that the scintillation camera excels in speed and versatility in positioning. Our experience in studying over 30 cases of CSF rhinorrhea using the technique of radioisotope cisternography will be reported in detail elsewhere (17). The present report is limited to our experience using the gamma scintillation camera.

Although the cases reported here were studied using the specially prepared ^{99m}Tc -albumin described below, a commercially available high-specific-activity ^{131}I -albumin* (1% albumin) may be used for cisternography with a usual dose of 100 μC for adults and 50 μC for children. The physical characteristics of the ^{99m}Tc (6-hr half-life and single 140-kev gamma photon) make ^{99m}Tc -albumin the preferred tracer when the scintillation camera is used. This is due to the greater detection efficiency of the camera's thin NaI(Tl) crystal for low gamma-ray energies and because a higher resolution collimator (4,000 hole) may be used. In addition, high counting rates are assured with the 2-mc dose without excessive radiation to the patient. The short half-life of ^{99m}Tc -albumin precludes extending the period of examination much beyond 24 hr following the intrathecal injection, but a much longer period of study is possible when ^{131}I -albumin is used. Regardless of which albumin tracer is used for the study, the amount of albumin for each intrathecal administration should not exceed 4 mg (18) because there appears to be an association of aseptic meningitis with intrathecal injections which exceed this amount of albumin (19,20).

PREPARATION OF HIGH-SPECIFIC-ACTIVITY ^{99m}Tc -ALBUMIN

For the preparation of high-specific-activity ^{99m}Tc -albumin, slight modifications were introduced into a method originally suggested by P. Richards, Brookhaven National Laboratory (21). The procedure consists essentially of an acid reduction of pertechnetate ion at pH 1.2 in the presence of a small amount of ferric chloride and ascorbic acid prior to the addition of the human serum albumin. The amount of iron must be kept to the barest minimum if the formation of excessive amounts of technetium-iron-ascorbate complex (with resultant kidney localization) is to be avoided. Our usual procedure consists of labeling 5 mg of human serum albumin with 5 ml of the $\text{Na } ^{99m}\text{TcO}_4$ eluate (3–13 mc/ml), using 4 mg of $\text{FeCl}_3 \cdot 6\text{H}_2\text{O}$ and 10 mg of ascorbic acid. The specific activity of individual batches of

labeled albumin have ranged from 3–12 mc of ^{99m}Tc per mg of protein. The labeling efficiencies exceeding 80%.

Excessive amounts of nonorganically bound ^{99m}Tc are easily removed by passing the product through an anion exchange resin (Bio-Rad AG1 \times 8-chloride form, 50–100 mesh) packed in a 130 \times 5-mm column before sterile filtration of the product. In no case has the "free" pertechnetate level been greater than 3% as determined by paper or thin-layer chromatography (TLC) using 85% methanol as a solvent. The TLC method offers the decided advantage of extreme rapidity, allowing the determination of radiochemical purity before administration of the product. If the "free" pertechnetate level exceeds 10%, the blood and salivary-gland background activity may become too intense to permit a satisfactory study due to the rapid resorption of the pertechnetate ion from the CSF into the blood.

The use of this product in human subjects was begun only after there was adequate assurance that the procedure would yield a biologically safe material. Ten pilot batches were prepared and subjected to pyrogen testing in amounts at least 20 times that which would ever be used in patients. Sterility tests and determinations of radiochemical purity were also performed on these batches.

CISTERNOGRAPHY METHOD

Whenever possible the radioisotope cisternogram is performed while the patient is leaking actively. Potential sites of leak may be occasionally seen as abnormal intracranial collections of the tracer in those patients who are not leaking at the time of the study. However, the actual "track" will not be seen.

We prefer to place the patient on penicillin or broad spectrum antibiotics at least 1 day prior to cisternography and continue the administration for approximately 1 week since the results of pyrogen and sterility testing are not available until after completion of the examination. To date our ^{99m}Tc -albumin preparations have always been shown to be sterile and pyrogen free. In addition, the patients are occasionally manipulated in various ways to elicit maximum CSF flow during the examination. This, we feel, may predispose the patient to an added risk of meningitis due to the possible retrograde ascent of bacteria through the dural tear.

Adult patients receive a maximum intrathecal dose of 2 mc of the low-protein (< 1 mg/ml) ^{99m}Tc -albumin in 0.5–1.5 ml depending on the specific activity prepared and the amount of physical decay of the isotope. Children are given approximately 50 μC /kg body weight. A well-performed

* Abbott Laboratories: RISA (1% solution).

lumbar puncture is essential for a satisfactory study. A 20 or 22 G needle is preferred. As soon as clear spinal fluid is seen to flow, the syringe containing the tracer is carefully attached to the needle and a small withdrawal of CSF is made into the syringe to again ascertain continuity with the subarachnoid space. We do not allow the patient to straighten his legs while the needle is in place nor do we measure the spinal-fluid pressure with a manometer. Following the slow injection of the tracer into the subarachnoid space, the needle with the syringe attached is withdrawn and the patient is instructed to remain recumbent for approximately 30 min after which he may sit or walk about as desired. Since the tracer is essentially isobaric with respect to the CSF, excessive trauma to the arachnoid membrane in the area of the puncture may allow most of the tracer to extravasate into the extra-arachnoid tissues. If a traumatic tap is associated with tearing of any of the numerous veins in this area, much of the tracer may enter the blood and the characteristic appearance of a conventional brain scan will be seen on the scintigram. While this does the patient no harm, it usually necessitates a repeat examination.

The first scintiphoto is obtained 30 min following the injection of the tracer. The patient is usually examined in the sitting position with the head placed against the scintillation camera as shown in Fig. 2. The rate of ascent of the tracer in the spinal subarachnoid space is somewhat variable, but its flow in the endocranial spinal-fluid space follows a consistent time-sequential pattern (22-25) (Fig. 3). In most cases a sufficient amount of tracer will have entered the basal cisterns within 1-2 hr to let one confine the views to those which will have the greatest chance of demonstrating the site of leak. Each patient must be positioned somewhat accord-

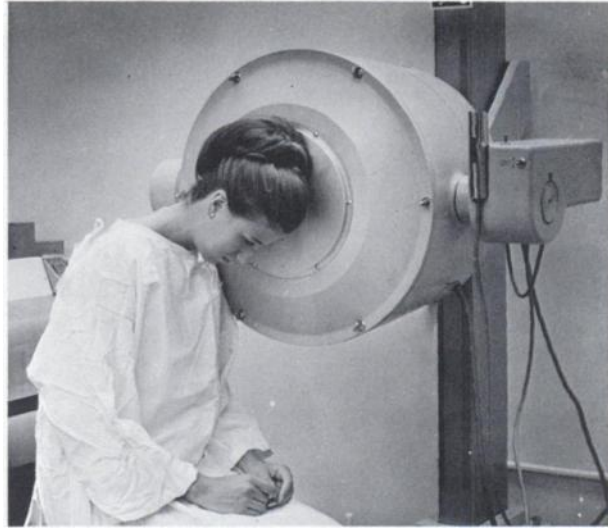


FIG. 2. Patients are examined with head bent forward to elicit maximum CSF leakage. Lateral scintigram is most informative with anterior leak sites.

ing to the history and his ability to cooperate. Generally, active leaking can be elicited by bending the patient forward. If the leak is predominately from one nostril, that side is placed next to the detector. Occasionally it is necessary to place the patient in a prone Trendelenburg position with the shoulders at the edge of the litter so that the head may be flexed at the neck. The posterior scintigram is usually most informative when the leak comes from the middle ear through a defect in the petrous bone.

Appropriate views are taken at 30-min intervals until the leak is demonstrated. After visualizing the site of leak, repeated views are obtained to delineate the entire track which may be visualized only for a relatively short time during the entire study. If, after diligent searching, the leak cannot be demonstrated 5 hr after injection, a posterior and lateral

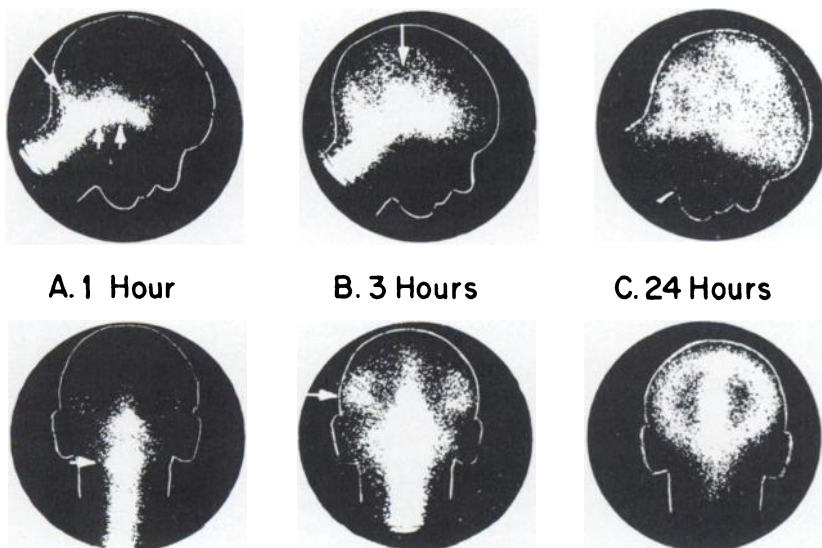


FIG. 3. Normal sequential cisternogram. (A) 1 hr: tracer is seen in cisterna magna (arrow) and basal cisterns (double arrow). (B) 3 hr: the tracer has entered sylvian fissures (arrows) and has begun to flow over cerebral convexities. Note that flow is symmetrical as viewed posteriorly and that tracer does not enter ventricular system. (C) 24 hr: tracer has now reached most superior regions of subarachnoid space. By 48 hr most of tracer will be resorbed through Pacchionian granulations in parasagittal area.

TABLE 1. SUSPECTED CASES OF CSF RHINORRHEA STUDIED WITH SCINTILLATION CAMERA AND ^{99m}Tc -ALBUMIN

Case	History of trauma	Date of cisternography	Visibly leaking at time of cisternography	Leak demonstrated by cisternography	Surgical exploration	Agreement of site by surgery and cisternography	Location of leak
C.W. 58 F	No	2/14/67 2/20/67 7/31/67	No No Yes	No No Yes	No No Yes	Yes	Cribriform plate
R.G. 39 M	Yes	2/17/67 3/17/67	Yes No	Yes No	No No		Cribriform plate
A.K. 3 F	No	3/7/67	No	No*	No		
M.G. 38 F	Yes (Surgical)	3/8/67	No	No	No		
F.F. 49 M	No	3/14/67	No	Yes	Yes	Yes	Petrous bone
R.R. 20 M	Yes (Surgical)	4/24/67	Yes	Yes	Yes	Yes	Roof of frontal sinus
M.P. 45 F	Yes (Surgical)	5/1/67	No	No	No		
L.D. 58 F	No	5/17/67 5/24/67	No Yes	Yes Yes	No Yes	Yes	Anterior wall of sella turcica
S.R. 21 M	Yes	6/26/67	Yes	Yes	Yes	Yes	Cribriform plate
A.J. 14 M	Yes	6/26/67	No	No†	No		
T.H. 42 M	Yes	7/14/67	No	Yes	Yes	Yes	Petrous bone
D.G. 28 F	Yes	8/22/67	No	No	No		
R.C. 20 M	Yes	9/1/67	Yes	Yes	Yes	Yes	Cribriform plate
M.J. 25 F	Yes	11/24/67	No	No	No		

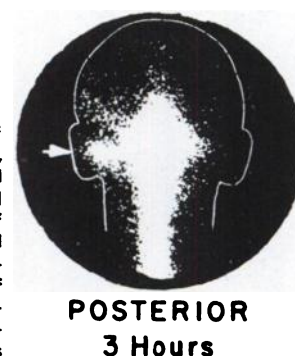
* An abnormal collection of tracer was seen in the area of the cribriform plate but no extracranial extension.
† An abnormal collection of tracer was noted in the infrafrontal area but no extracranial extension.

scintigram are obtained at 24 hr. Although the radioactivity has diminished considerably by this time, we occasionally see evidence of abnormal CSF reservoirs which may suggest potential sites of leak.

The intensity control, which determines the brightness of each recorded flash on the cathode-ray tube, must be set somewhat higher than ordinarily would be desired for a good-quality scintiphoto. The small amount of radioactivity within the leak is usually far below the level of activity present in the basal cisterns and will not be seen if the intensity setting is adjusted too low. Between 40,000 and 60,000 counts are accumulated for each scintigraphic projection. This usually requires from 2 to 6 min of exposure time when the 4,000-hole, low-energy collimator is used (12,000–15,000 counts when ^{131}I -albumin is used with the 1,000-hole, $1\frac{1}{2}$ -in. collimator). The pinhole collimator may be used when better resolution is desired, but it has seldom provided significant additional information.

Important landmarks are identified on one or more of the scintiphotos during the course of the examination. Following the completion of an exposure the patient is instructed to remain in place while a long, thin wax crayon is placed against the desired landmark perpendicular to the cover of the detector. A mark is made on the detector face-plate

FIG. 4. Posterior scintiphoto of patient with left chronic mastoiditis, recurrent meningitis and left-sided CSF rhinorrhea. Note abnormal collection of tracer in region of left petrous bone (arrow). Surgical exploration of left middle ear disclosed slow accumulation of CSF which apparently drained into nasopharynx via eustachian tube. Surgical repair of dural defect was successful in stopping leak.






FIG. 5. Following extensive head injuries, subdural hematoma was evacuated through right temporal craniotomy. Postoperatively patient developed serosanguinous rhinorrhea thought to arise from petrous bone. (A) At 3 hr lateral cisternogram is normal. (B) 15 min later tracer is seen to collect slightly below cribriform plate (arrow) and is best seen at 3½ hr (C). (D) 15 min later, following gush of fluid from nose, accumulation has gone. At surgery 3-mm defect in right cribriform plate was located and repaired.

and the patient is moved away from the detector. ^{57}Co point sources are placed on these marks and an additional exposure is made for approximately 1,000 counts. This provides a "double exposure" which may be used for the localization of abnormal collections of the CSF-tracer on subsequent scintiphotos. The point sources are not used routinely on all exposures because they might obscure the leak.

DISCUSSION

Radioisotope cisternography has been very helpful to the neurosurgeons in our institution who now request the procedure on each case of cerebrospinal fluid rhinorrhea prior to surgery. Failure to identify the probable site of a cerebrospinal fluid leak before surgical exploration often subjects the patient to an

extensive intracranial procedure which may or may not be successful in stopping the CSF rhinorrhea. If the neurosurgeon is aware of the most likely site of leak, he may approach that area by the most direct route consistent with safety.

In most cases the approximate site of the CSF leak can be satisfactorily determined if the patient is leaking at the time of the cisternogram (Table 1). In no instance has the cisternogram provided misleading information regarding the site of leakage. In every case where the leak was demonstrated and surgery performed there was agreement as to location. In the cases shown in Figs. 4 and 5 there was as much clinical evidence to suggest that the CSF leak was occurring through a defect in the petrous bone into the middle ear and out the eustachian tube as there was for the leak occurring anteriorly. Based on the information provided by the cisternogram, the correct surgical approach was selected in each case and the defects successfully repaired. In another case (Fig. 6) the middle cranial fossa rather than the posterior fossa would have been explored had the cisternogram not shown an abnormal collection of the CSF-tracer in the pontocerebellar cistern on the side of the head injury.

Iatrogenic CSF rhinorrheas may occasionally be the result of intracranial surgery particularly in the pituitary fossa. In the case shown in Fig. 7 the neurosurgeon had inadvertently entered the frontal sinus during a frontal exploration. The cisternogram was helpful in determining the probable anterior site through which the CSF was draining.

In most cases the lateral cisternogram is best able to delineate the region of leak when it occurs anteriorly. However, in one case (Fig. 8) the anterior scintigram was also necessary to establish that the CSF-tracer was accumulating in the maxillary sinus.

While it is desirable to visualize the entire track, this is not always possible. A long "trail" of activity may occasionally be observed which often represent nothing more than CSF-tracer in the nasal cavity being channeled by the internal structures of the

FIG. 6. Right-sided CSF rhinorrhea followed blast injury to right parietal region. Several right temporal craniotomies failed to locate leak. Posterior scintigram shows abnormal collection of tracer in area of cerebellopontine cistern adjacent to petrous bone on right (arrow). Larger collection of tracer above this point represents filling of space created by previous craniotomies. Exploration of posterior fossa disclosed leak site and was followed by successful repair.

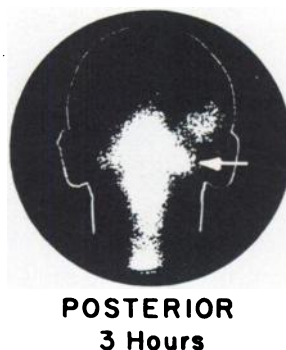
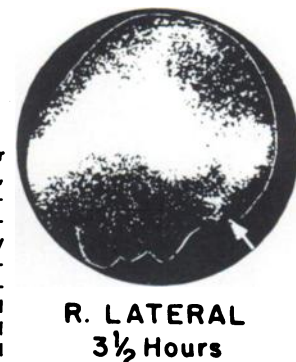
FIG. 7. During craniotomy for repair of infected frontal bone flap, frontal sinus was inadvertently entered. Postoperatively CSF rhinorrhea developed. Cisternography confirmed abnormal pooling in frontal sinus (arrow) as well as enlarged subarachnoid space behind bone flap. At reoperation dural rent above frontal sinus was found and repaired.



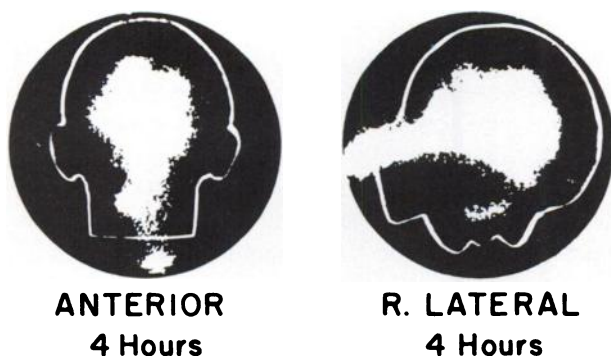


FIG. 8. Case of CSF rhinorrhea following gunshot wound to right parietal region. Anterior view shows low-lying accumulation of tracer to right of midline. Right lateral view locates collection in maxillary sinus. Leak, apparently emanating from cribriform plate, stopped spontaneously following severe bout of meningitis.

nose. However, the proximal portion of this "trail" is usually in close proximity to the actual site of leak as was seen in two cases (Figs. 9 and 10). More often, the location of leak must be reconstructed by reviewing sequential scintigrams (see Fig. 5), each showing a slightly different appearance as the CSF-tracer flows through the defect in the arachnoid and dural membranes.

It should be realized that acquiring such sequential scintigraphic exposures requires considerable time and patience on the part of the physician and technician and may be very tiring for the patient. It is not unusual to obtain 20 or 30 exposures before satisfactorily identifying the site of leak. This procedure requires the full-time efforts of a responsible technician who frequently consults with the physician regarding further views and positioning of the patient. While cisternography is not as technically difficult to perform as fractional pneumoencephalography, both demand direction by the physician and should not be left solely to the discretion of the technician.

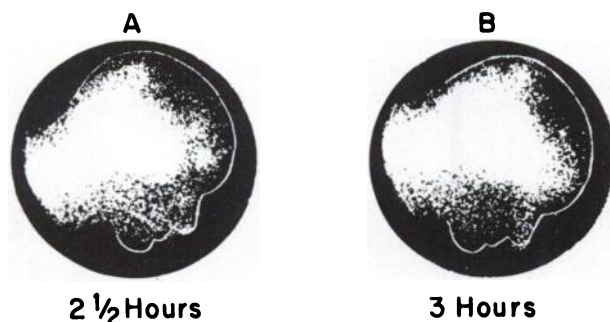


FIG. 9. Case of spontaneous CSF rhinorrhea. (A) At 2 1/2 hr only small collection of tracer can be seen in nasal cavity. (B) At 3 hr trail of activity can be traced from cribriform plate down into nasal cavity. At surgery atrophy of olfactory bulb was found with no recurrence of rhinorrhea following repair.

Based on our experience in performing over 200 cisternograms using high-specific-activity ^{131}I -albumin and 31 cisternograms employing $^{99\text{m}}\text{Tc}$ -albumin, we feel that the procedure is without significant morbidity if the same normal precautions are taken as with any lumbar puncture where a drug is to be administered intrathecally. Except for the rare occurrence of a slight headache, we have observed no untoward reactions associated with the injection of the tracer, even in those patients who have received up to four cisternograms.

The radiation absorbed dose received by the patients from the procedure does not appear to be excessive. We estimate that the central nervous system receives approximately 0.3 rads/mc of $^{99\text{m}}\text{Tc}$ -albumin and 1.3 rads/100 μc of ^{131}I -albumin. The whole-body radiation absorbed doses were calculated to be 0.01 rads and 0.12 rads, respectively, for the $^{99\text{m}}\text{Tc}$ -albumin and ^{131}I -albumin doses above.

SUMMARY

In our experience the radioisotope cisternogram has been the most valuable diagnostic test for evaluating cerebrospinal fluid rhinorrhea prior to surgery. Failure to demonstrate the site of leak prior to neurosurgical repair often necessitates a more extensive intracranial procedure.

The technique of radioisotope cisternography using the scintillation camera has been described in detail and examples of verified CSF leaks shown.

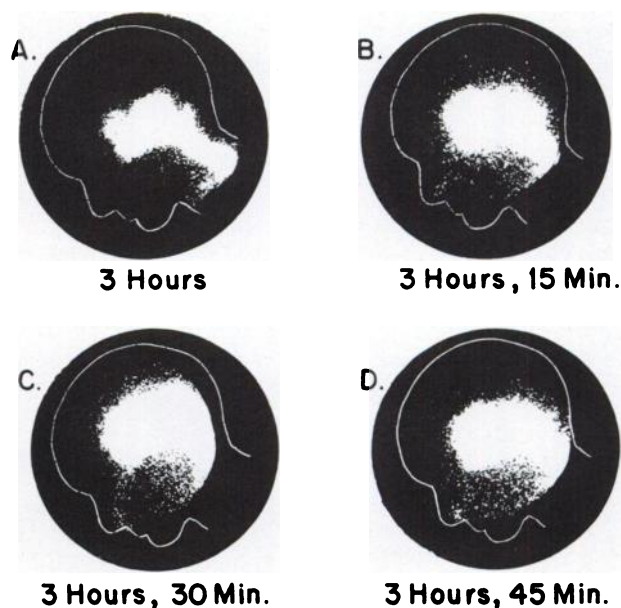


FIG. 10. Lateral scintiphotos obtained at 15-min intervals on patient with spontaneous CSF rhinorrhea. On only one of exposures (C) can entire trail of activity be seen coming from region of sella turcica. This demonstrates transient and intermittent nature of CSF leaks.

The paramount advantage of using the scintillation camera, aside from speed, is the ability to examine the patient in any position which will elicit the maximum flow of CSF through the site of leak. This position is most often with the head bent forward which precludes lateral scanning with the currently available commercial rectilinear scanners.

ACKNOWLEDGMENT

The authors wish to thank Col. L. G. Kemp, MC and Lt. Col. William M. Hammon, MC of the Walter Reed Army Hospital, Washington, D. C. and Cdr. S. E. Senn, MC of the U. S. Naval Hospital, Bethesda, Maryland for allowing us to examine several of their patients as part of this study.

REFERENCES

1. OMMAYA, A. K., DI CHIRO, G., BALDWIN, M. AND PENNYBACKER, J. B.: Non-traumatic cerebrospinal fluid rhinorrhea. *J. Neurol. Neurosurg. Psychiat.* In press.
2. BRANDT, C.: Zur Röntgendiagnostik der Liquorfisteln und Pneumatocelen insbesondere der vorderen Schädelgrube. *Fortschr. Röntgenstr.* 2:182, 1958.
3. JEFFERSON, A. AND LEWTAS, N.: Value of tomography and subdural pneumography in subfrontal fractures. *Acta Radiol.* 1:118, 1963.
4. CROW, H. J., KEOGH, C. AND NORTHFIELD, D. W. C.: The localization of cerebrospinal-fluid fistulae. *Lancet* 271:325, 1956.
5. KLINE, J. C., PULETTI, F., BENNETT, M. AND CAMERON, J. R.: The detection and localization of cerebrospinal fluid fistulae. *J. Nucl. Med.* 5:376, 1964.
6. EVANS, J. P., ET AL.: Danger in the use of intrathecal methylene blue. *J. Am. Med. Assoc.* 174:856, 1960.
7. KIRCHNER, F. R. AND PROUD, G. O.: Method for the identification and localization of cerebrospinal fluid rhinorrhea and otorrhea. *Laryngoscope* 70:921, 1960.
8. MAHALEY, M. S. AND ODOM, G. L.: Complication following intrathecal injection of fluorescein. *J. Neurosurg.* 25:298, 1966.
9. GHOURALAL, S., MYERS, P. W. AND CAMPBELL, E.: Persistent cerebrospinal rhinorrhea originating in fracture through petrous bone and cured by muscle graft: Report of a case. *J. Neurosurg.* 13:205, 1956.
10. JUNGSMANN, A. AND PEYSER, E.: Roentgen visualization of cerebrospinal fluid fistula with contrast medium. *Radiology* 80:92, 1963.
11. ROCKETT, F. X., WITTENBORG, M. H., SHILLITO, J., JR. AND MATSON, D. D.: Pantopaque visualization of a congenital dural defect of the internal auditory meatus causing rhinorrhea. Report of a case. *Am. J. Roentgenol. Radium Therapy Nucl. Med.* 91:640, 1964.
12. TENG, P. AND EDALATPOUR, N.: Cerebrospinal fluid rhinorrhea with demonstration of cranionasal fistula with Pantopaque. *Radiology* 81:802, 1963.
13. DI CHIRO, G., REAMES, P. M. AND MATTHEWS, W. B., JR.: RISA-ventriculography and RISA-cisternography. *Neurology* 14:185, 1964.
14. DI CHIRO, G. AND REAMES, P. M.: Isotopic localization of cranionasal cerebrospinal fluid leaks. *J. Nucl. Med.* 5:376, 1964.
15. DI CHIRO, G. AND ASHBURN, W. L.: Isotope cisternography and ventriculography. *J. Nucl. Med.* 8:266, 1967.
16. DI CHIRO, G. AND MATTHEWS, W. R., JR.: The Tetrascanner: a device for rapid three-dimensional brain scanning. *J. Nucl. Med.* 7:330, 1966.
17. DI CHIRO, G., OMMAYA, A. K., ASHBURN, W. L. AND BRINER, W. H.: Isotope cisternography in the diagnosis and follow-up of cerebrospinal fluid rhinorrhea. *Neurology*. In press.
18. DI CHIRO, G.: Specific activity of radioiodinated human serum albumin for intrathecal injection. A correction. *Neurology* 15:950, 1965.
19. DETMER, D. E. AND BLACKNER, H. M.: A case of aseptic meningitis secondary to intrathecal injection of ¹³¹I human serum albumin. *Neurology* 15:642, 1965.
20. NICOL, C. F.: A second case of aseptic meningitis following isotope cisternography using ¹³¹I human serum albumin. *Neurology* 17:199, 1967.
21. RICHARDS, P. AND ATKINS, H. L.: High specific activity technetium-99m albumin. *J. Nucl. Med.* 8:396, 1967.
22. DI CHIRO, G.: New radiographic and isotopic procedures in neurological diagnosis. *J. Am. Med. Assoc.* 188:524, 1964.
23. DI CHIRO, G.: Movement of the cerebrospinal fluid in human beings. *Nature* 204:290, 1964.
24. DI CHIRO, G.: Observations on the circulation of the cerebrospinal fluid. *Acta Radiol.* 5:988, 1966.
25. RIESELBACH, R., DI CHIRO, G., FREIREICH, E. AND RALL, D.: Subarachnoid distribution of drugs following lumbar injection determined by autoradiography and external scanning. *New Engl. J. Med.* 267:1,273, 1962.