

Mercury-197 and Mercury-203 Chlormerodrin for Evaluation of Brain Lesions Using a Rectilinear Scanner and Scintillation Camera²

Merle K. Loken,¹ Ph.D., M.D., Luther O. Wigdahl, M.D.,
J. Michael Gilson, M.D., and Edward V. Staab, M.D.

Minneapolis, Minnesota

INTRODUCTION

During the past three years we have performed brain scans on more than 1200 patients. Early in this period, ²⁰³Hg-chlormerodrin was our scanning agent. Results obtained using this agent in over 400 patients are being considered elsewhere (1). Since November, 1963, ¹⁹⁷Hg tagged to chlormerodrin has been used almost exclusively with selected patients being studied with both ¹⁹⁷Hg and ²⁰³Hg-chlormerodrin. In the early part of 1965, we acquired a scintillation (Anger) camera (2), and all patients who have undergone a conventional brain scan since that time have also been simultaneously studied on the camera. With the acquisition of a scintillation camera, ^{99m}Tc pertechnetate and ¹⁹⁷Hg chlormerodrin became the agents employed for brain scanning. This report will include an evaluation of our experience with ¹⁹⁷Hg-chlormerodrin as used conventionally, and as it appears when both the camera and conventional rectilinear scanning are used together. Reference is also made to the use of both ¹⁹⁷Hg- and ²⁰³Hg-chlormerodrin in 42 patient studies.

MATERIALS AND METHODS

Patient Selection—In the period from October, 1963, to January, 1965, 432 patients from the clinical services at the University of Minnesota and Veterans Administration Hospital, Minneapolis were studied. The more recent group of 107 studies using both camera and scanner were performed at the University of Minnesota.

¹From the University of Minnesota and Veterans Administration Hospitals, Minneapolis.

²Supported in part by funds from the American Cancer Society (Institutional Grant) and the Graduate School, University of Minnesota.

- Agents — ^{197}Hg -chlormerodrin (Squibb).
 ^{203}Hg -chlormerodrin (Squibb, Abbott).
- Equipment — Magnascanner (Picker) with a three by two inch crystal and 19 hole collimator was employed for conventional scanning. The scintillation camera (Nuclear Chicago) has an $11 \times \frac{1}{2}$ inch crystal. Two collimators have been tried with the camera. The most satisfactory has been the 1.5 inch thick multichannel collimator.
- Procedure — *Conventional:* $10\mu\text{C}/\text{kg}$ of ^{197}Hg -chlormerodrin was administered intravenously two to four hours prior to scanning. More recently one millicurie of ^{197}Hg -chlormerodrin was given to those patients studied with both the Magnascanner and the camera. Speed for conventional scanning was varied from 30-60 cm/minute depending on the amount of radioactivity present. Line spacing of 0.3 cm was used in the majority of scans. With this technique, the scanning time varied from 10-25 minutes. Routinely, both lateral projections were obtained and any additional projections thought necessary.
- Camera:* A variety of control settings have been tried with the scintillation camera. Two-tenths of the widest window obtainable appears to give the best results; the highest counting rate consistent with acceptable resolution. The optimal threshold setting appears to be 5.5. The intensity control is to provide the best Polaroid film presentation based on the total number of counts accepted. Usually, 100,000 total counts were taken per projection. Four projections were normally obtained on each patient. Each projection takes four to eight minutes depending upon the radioactivity present.

RESULTS

Forty-two cases were studied in which both ^{203}Hg -chlormerodrin and ^{197}Hg -chlormerodrin were used. Eight positive cases were found in this group, being adequately visualized with either isotope. The smallest lesion discovered was a 1.5 cm metastasis near the apex of the skull. This experience correlates well with that of others (3,4,5).

Table I contains the results of 432 patients scanned with ^{197}Hg -chlormerodrin. Analysis of these cases in a retrospective blind study yielded 104 positive, 284 negative, and 44 indeterminate. This latter group is made up of both technically inadequate studies and equivocal scans.

Of the 104 positive studies, 39 indicated primary brain tumors, 35 metastatic neoplasms, and 30 non-neoplastic lesions. Table II contains an analysis of the primary lesions proven by surgery or autopsy. A total of 50 primary lesions are known to have existed. Thirty-nine of these 50 had positive brain scans. The 78% figure is comparable to that found in a previously reported series reviewed by Overton (6).

Five of the remaining eleven cases proven to have primary brain tumors are listed in the indeterminate group. Further consideration will be given to these.

TABLE I

¹⁹⁷Hg CHLORMERODRIN BRAIN SCANS FROM OCT. 1963 TO JAN. 1965

<i>Interpretation</i>	<i>No. of Patients</i>	<i>% of Total</i>
Positive	104	24
Negative	284	65
Indeterminate	44	11
	432	100

TABLE II

INTERPRETATION OF BRAIN SCANS IN PATIENTS WITH PRIMARY BRAIN NEOPLASMS

<i>Pathological Type</i>	<i>Positive</i>	<i>Negative</i>	<i>Indeterminate</i>	<i>Total</i>
Astrocytoma (Grades I-IV)	27	4	5	36
Meningioma	5	0	0	5
Cholesteatoma	1	0	0	1
Chromophobe adenoma	3	2	0	5
Acoustic neuroma	1	0	0	1
Hemangioendothelioma (recurrent)	1	0	0	1
Thalamic tumor	1	0	0	1
	39	6	5	50

TABLE III

POSITIVE SCANS IN METASTASIS TO BRAIN*

<i>Lesion</i>	<i>No. of Cases</i>
Hypernephroma	6
Lung	12
Melanoma	3
Breast	4
Lymphoma	3
Adenocarcinoma	4
Choriocarcinoma	1
Sarcoma—soft tissue	1
Prostate, undifferentiated	1
	35

*17 proven surgery or autopsy, 18 diagnosed by clinical history and x-ray contrast studies.

Table III lists the 35 metastatic neoplasms having positive scans. Seventeen of these cases were verified by autopsy or surgery. In the remainder there was strong clinical and/or x-ray evidence of metastases to the brain.

Table IV lists the 30 positive scans obtained in non-neoplastic diseases. Cerebrovascular accidents accounted for 18 of these. Five cases with intracerebral hematomas and two with subdural collections of blood had positive scans. Measurements of the fluid in one of the subdural cases showed a higher activity than that in the patient's blood serum at the corresponding time (1.75 to 1). The three cases listed as trauma resulted from gunshot wounds. Two patients with intracranial aneurysms causing subarachnoid bleeding had definitely positive scans. Presumably, these were caused by blood about the aneurysm.

Table V contains an analysis of the brain scans considered as indeterminate for a variety of reasons. This includes equivocal scans and those technically inadequate. Twenty (20) of these patients were found to have intracranial disease, either space-occupying lesions or cerebral infarction. In addition, two others had abnormalities that explained the unusual brain scans obtained. One patient with a superior-vena-cava syndrome had an unusual amount of radioactivity distributed over the posterior portion of the skull. The other had an infected scalp laceration in the area of the positive scan.

Table VI summarizes the results of 107 patients studied with both the Magnascanner and the scintillation camera. Twenty-eight (28) positive camera studies were recorded. On two occasions the camera recorded positive scintiphotograms in cases where conventional rectilinear scanning had been technically inadequate. In both instances the patients were disoriented, unable to co-operate for very long periods of time despite the use of a Flexicast headhold (Picker Nuclear, White Plains, New York).

On the other hand twenty-nine (29) positive scintiphotograms were obtained by rectilinear scanning. Three scans were positive that did not appear so in the camera positive group. One was a posterior-fossa lesion in which a camera picture in the posterior-anterior projection was inadvertently not obtained. Another case was considered suggestive but placed in the equivocal category. The last was a neoplasm of the posterior fossa which was clearly demarcated by rectilinear scanning, but could not be readily appreciated on the camera pictures because of their overexposure due to an improper intensity setting.

TABLE IV

POSITIVE BRAIN SCANS IN NON-NEOPLASTIC DISEASE

<i>Lesion</i>	<i>No. of Cases</i>
CVA	18*
Intracerebral hematoma	5**
Subdural hematoma	2
Trauma (gunshot wounds)	3
Subarachnoid hemorrhage	2
	—
	30

*Clinical diagnosis

**Two proven surgically. Three diagnosed by clinical history and x-ray contrast studies.

TABLE V
INDETERMINATE BRAIN SCANS

<i>Lesion</i>	<i>Surgery or Autopsy</i>		<i>Clinical</i>	
	<i>Positive*</i>	<i>Negative</i>	<i>Positive</i>	<i>Negative</i>
Neoplasms				
Primary	5**			
Known primary elsewhere	5	4	5	2
CVA***	3	2	7	
Misc. C.N.S. disturbances	1			8
Scalp laceration	1			
Sup. vena cava syndrome	1			
	—	—	—	—
	16	6	12	10

*Positive and negative refer to lesions expected to give a positive brain scan.

**All astrocytomas.

***Clinical Diagnosis.

TABLE VI
COMPARISON STUDIES WITH CAMERA* AND CONVENTIONAL SCANNING**

	<i>Camera</i>		<i>Conventional</i>	
	<i>Total</i>	<i>% of Total</i>	<i>Total</i>	<i>% of Total</i>
Positive	28***	26	29****	27
Negative	70	66	69	65
Equivocal	9	8	9	8
	—	—	—	—
	107	100	107	100

*Scintillation (Anger) Camera

**Picker Magnascanner

***Two positive with camera. Equivocal negative with scan.

****Three positive with scan. Equivocal or negative with camera.

Scintiphotograms obtained on five patients being evaluated for possible brain lesions who were studied by rectilinear scanning and the scintillation camera after receiving ¹⁹⁷Hg-chlormerodrin are shown in Figures 1-5. Results of camera studies are shown on the left and scanner studies on the right.

Figure 1 shows left lateral scintiphotograms obtained on a 14-year-old girl ten months after subtotal resection of a grade-four astrocytoma from the left parietal lobe. This patient did well for several months following surgery but was re-admitted because of recurrence of right-sided weakness and symptoms of increased intracranial pressure. These scintiphotograms reveal an area of increased activity approximately six centimeters in diameter. This proved to be recurrent astrocytoma in this area.

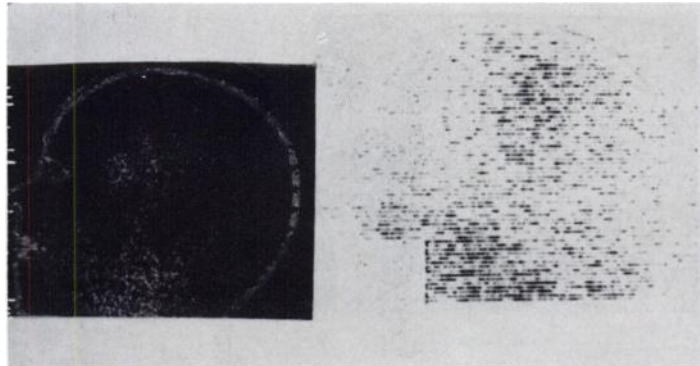


Fig. 1. Left lateral scintiphotograms showing increased activity in a grade-four astrocytoma in the parietal region.

Scintiphotograms of a 76-year-old lady admitted to our hospital following an auto accident are shown in Figure 2. These left lateral projections show increased activity in the left frontotemporal area. Anterior views (not shown) likewise demonstrated this lesion. This patient expired and at autopsy infarcted brain tissue was found in the area of increased radioactivity by the scanner and camera.

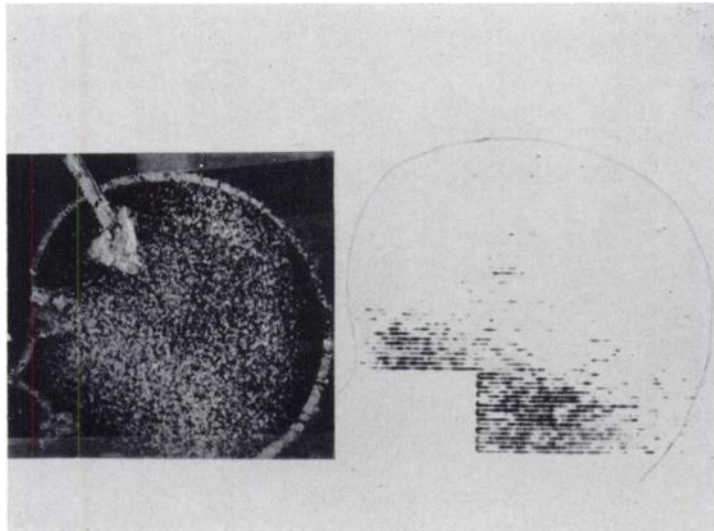


Fig. 2. Scintiphotograms showing an area of infarcted brain tissue in left fronto-temporal area.

Right lateral views of a 51-year-old man with a history of headache and personality change are shown in Figure 3. Several days prior to obtaining this study, a pneumoencephalogram and bilateral carotid angiograms were performed. These studies were reported as normal. An electroencephalogram showed a delta focus in the frontal area bilaterally. At surgery a grade-four astrocytoma was partially resected from the right parietal area.

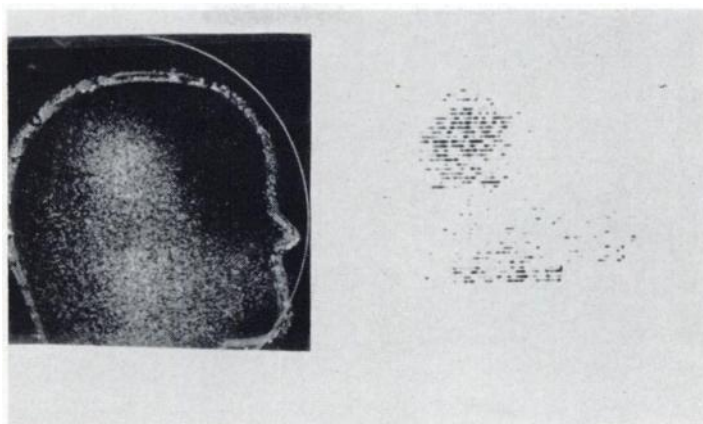


Fig. 3. Right lateral scintiphotograms showing increased activity in the parietal area. This was found to be a grade four astrocytoma.

Left lateral scintiphotograms of a 73-year-old lady are shown in Figure 4. This patient was admitted because of mental deterioration and evidence of right-sided weakness. These views reveal a focus of activity in the temporo-parietal area in the left side. This proved to be metastatic carcinoma. X-ray examinations revealed osteolytic lesions in the right femur and pelvis. This patient had a mass in the left breast which proved to be carcinoma.

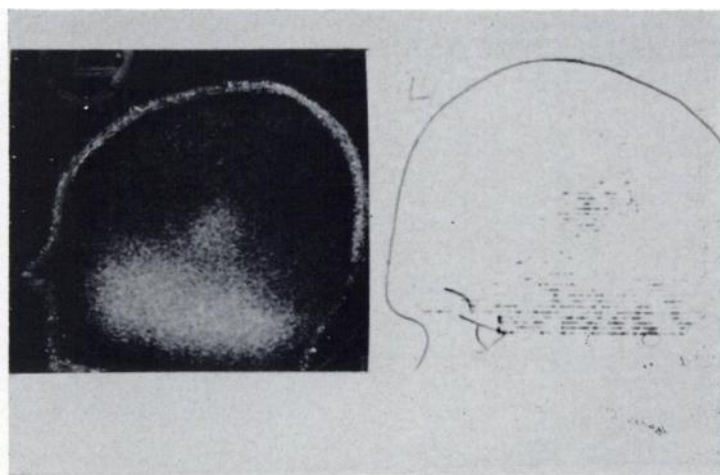


Fig. 4. Left lateral scintiphotograms showing a focus of activity in the temporal-parietal area. At surgery this was found to be metastatic carcinoma with a primary lesion in the left breast.

Figure 5 includes scintiphotogram of the anterior and right lateral projections made of a 3-year-old boy who had had incomplete resection of an optic glioma invading the frontal lobe of the brain two years previously. This patient did well postoperatively until about three months prior to his admission to this hospital when increased irritability and other signs of increased intracranial pressure were noted. A large area of increased activity is noted in the frontal area. Surgery was performed and a large recurrent tumor was found in the area shown on the scintiphotograms.

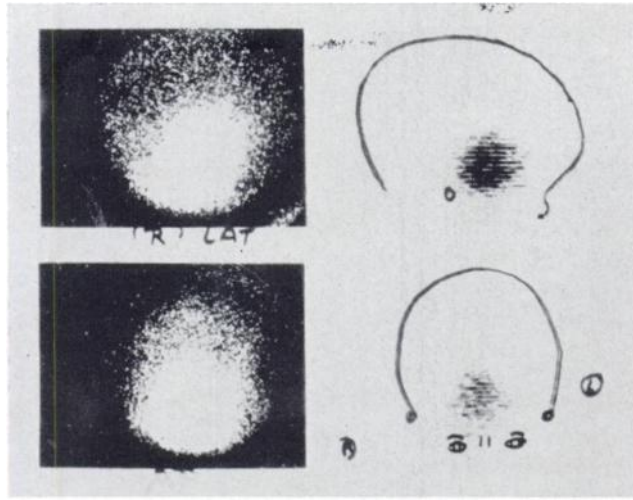


Fig. 5. Anterior and right lateral scintiphotograms showing a large area of increased activity in the frontal lobe. This was a recurrent optic glioma.

DISCUSSION

Based on the present series of patients studied with ^{197}Hg -chlormerodrin and in some instance with ^{203}Hg -chlormerodrin, and the patients who had been previously studied in our clinic with ^{203}Hg -chlormerodrin, we have concluded that there is no significant difference in the value of these agents for demonstrating brain disease. The same conclusion has been reached by Overton *et al* (3) and Yamamoto *et al* (4) and Rhoton *et al* (5). Thus, we have chosen to use ^{197}Hg -chlormerodrin almost exclusively because of the smaller radiation dose to our patients than if ^{203}Hg -chlormerodrin was used.

Our series again introduces the topic of indeterminate or equivocal scans (6,7). Forty-four of the 432 scans were placed in this category. We have now followed this group for periods ranging from six months to two years. Sixteen of the 44 patients studied have subsequently been found to have intracranial disease. This represents almost 36% of this group. In the final evaluation of this group, one must bear in mind that pathology was demonstrated some time *after* the scan was obtained. Occasionally, this time lapse amounted to several months. Also, several of the tumors were found at autopsy and were less than 1.5 cm in diameter.

Five primary brain tumors were present in this indeterminate group. When these scans were reviewed in light of other information, the abnormal areas were seen, although the differential radioisotope uptake was less and more diffuse in appearance than in unequivocally positive cases. This was true also in a number of other pathologically proven lesions.

The scans were placed in the indeterminate group for a variety of reasons. First, diffuse increased activity was observed with fair localization in only one projection. More than 50% of the scans in this indeterminate group fall into this

category. It is important to further evaluate patients having indeterminate scans making use of all techniques available because of the strong expectancy of disease.

Other reasons for indeterminate brain scans were: 2) inadequate radioactivity for statistical reliability; 3) poor technique of scanning (patient immobilization, settings used, line spacing, and lack of appropriate projections), and 4) finally, lesion location. Abnormalities at the base of the skull, posterior fossa, and along the sagittal sinus are difficult to distinguish unless marked differential radioactive uptake occurs.

Fifty per cent of the patients (22/44) have been evaluated on a clinical basis only. A longer follow-up period will be needed on this group for complete evaluation.

Studies are not termed positive unless there is increased radioactivity in at least two projections. Thus, no false positives have been found in this series. Our doing this has encouraged the surgeons to place more reliance on the positive scans. Not infrequently surgery is undertaken although the brain scan is the only laboratory evidence indicating intracranial disease.

Not all positive scans indicate the presence of space-occupying lesions (8,9). Table IV shows that positive brain scans were obtained in 18 patients with cerebral infarction. Patients with positive brain scans and no shift of midline structure as seen on the echogram are most likely to have cerebral infarctions.

The most recent series of patients studied in which both the scintillation camera and conventional rectilinear scanner were used, demonstrate a strong correlation between these two methods of visualization of brain disease. This has required careful supervision of technical factors used with both the scanner and the camera.

Advantages of the scintillation camera include the ease with which the camera is positioned, the opportunity for the patient to remain in more comfortable positions, shorter period of time necessary for the procedure, smaller amount of time required for setting technical factors, and the optimal use of high activities of very short-lived isotopes (*i.e.* $^{99\text{m}}\text{Tc}$ -pertechnetate). An apparent disadvantage of the camera is the difficulty obtaining anatomic landmarks on the scintiphotogram. Also, we find that the small Polaroid picture obtained with this unit is somewhat more difficult for us to interpret than is a life-sized photoscan. This is due in part to our more limited experience with the camera as compared to that obtained with a rectilinear scanner.

SUMMARY

- 1) The results were presented of 432 patients conventionally scanned with ^{197}Hg -chlormerodrin were studied in a retrospective blind study.
- 2) Forty-two patients in which ^{203}Hg -chlormerodrin and ^{197}Hg -chlormerodrin was used as the radioactive agent were studied, and no significant difference in percentage of positive examinations was found.
- 3) 107 patients, after receiving ^{197}Hg -chlormerodrin, were studied using both the scintillation camera and rectilinear scanning techniques. A comparison

of the two methods used consecutively revealed that each gave information verifying the other and of essentially equal accuracy.

ACKNOWLEDGMENTS

We wish to acknowledge with thanks the technical assistance of Mrs. Lucille Gomez, Miss Pearl Varian, Miss Norma Constantino and Mr. John Colles.

REFERENCES

1. LOKEN, M. K., HEWEL, C. AND FRENCH, L. A.: Comparison of Scintiscanning with ^{203}Hg Chlormerodrin and Special Radiographic Procedures in the Evaluation of Brain Pathology. Manuscript in Preparation.
2. ANGER, H. O.: Scintillation Camera with Multichannel Collimators *Journal of Nuclear Medicine* 5:515, 1964.
3. OVERTON, M. C. III, OTTE, W. K., BEENTJES, L. B., AND HAYNIE, T. P.: A Comparison of ^{197}Hg Mercury and ^{203}Hg Mercury Chlormerodrin in Clinical Brain Scanning *Journal of Nuclear Medicine* 6:28, 1965.
4. YAMAMOTO, Y. L., FEINDEL, W. AND ZENELLI, J.: Comparative Study of Radioactive Chlormerodrin (Neohydrin) Tagged with Mercury ^{197}Hg and Mercury ^{203}Hg for Brain Scanning. *Neurology* (Minneapolis). 14:815, 1964.
5. RHOTON, A. L., CARLSSON, A., AND TERPOGOSSIAN, M. M.: Brain Scanning with Chlormerodrin ^{197}Hg and Chlormerodrin ^{203}Hg . *Archives of Neurology*. 10:369, 1964.
6. OVERTON, M. C. III, SNODGRASS, S. R., AND HAYNIE, T. P.: Brain Scans in Neoplastic Lesions. *JAMA*. 192:747, 1965.
7. GREEN, J., NOPPARAT, T., AND RUBIN, PHILIP: Brain Tumor Scanning Accuracy of Radiomercury—Chlormerodrin. *N.Y. State Journal of Medicine*. 65:403, 1965.
8. OVERTON, M. C. III, HAYNIE, T. P., AND SNODGRASS, S. R.: Brain Scans in Non-neoplastic Lesions. *JAMA*. 191:431, 1965.
9. MORRISON, R. T., AFIFI, A. K., VANALLEN, M. W., AND EVANS, T. C.: Scintiscanning for the Detection and Localization of Non-neoplastic Intracranial Lesions. *Journal of Nuclear Medicine* 6:7, 1965.

Announcements

11th Annual Meeting of the *Health Physics Society* will be held at the *Shamrock-Hilton Hotel in Houston, Texas*, on *June 27-30, 1966*. The Program Committee Chairman is James Terrill Jr., Division of Radiological Health, U.S. Public Health Service, 330 Jefferson Drive, S.W., Washington, D.C. 20201.

The Ninth Annual Institute on Neurology, co-sponsored by the Philadelphia Neurologic Society and the Veterans Administration Hospital, Coatesville, Pennsylvania will be held on April 1, 1966 at Coatesville VA Hospital. Participants will be Dr. Bernard J. Alpers, Emeritus Professor of Neurology, Jefferson Medical College, "Pathogenesis of Cerebral Vascular Occlusion"; Dr. Frederick Snyder, Chief of Section on Psychophysiology of Sleep, National Institutes of Health, "Clinical Implications of Dreaming (the REM state)"; Dr. Dominick Purpura, Assistant Professor of Anatomy and Neurology, College of Physicians & Surgeons, Columbia University, "Neurobasis for Subcortical-Cortical Regulatory Mechanisms"; Dr. Lawrence S. Lessin, Department of Medicine, University of Pa., "Ultrastructure and Function of Anterior Pituitary Cells" and Dr. John H. Lawrence, Director, Donner Laboratory & Donner Pavilion, University of California at Berkeley, "Heavy Particles in Medicine". For further information contact Dr. J. A. Doering, Hospital Director, VA Hospital, Coatesville, Pa. 19320.