



Each month the editor of *Newsline* selects articles on therapeutic, diagnostic, research, and practice issues from a range of international publications. Most selections come from outside the standard canon of nuclear medicine and radiology journals. Note that although we have divided the articles into diagnostic and therapeutic categories, these lines are increasingly blurred as nuclear medicine capabilities rapidly expand. Many diagnostic capabilities are now enlisted in direct support of and, often, in real-time conjunction with, therapies. These briefs are offered as a monthly window on the broad arena of medical and scientific endeavor in which nuclear medicine now plays an essential role. This month, the literature yielded an unusually high number of articles on nuclear medicine techniques in breast cancer, including evidence of a growing focus on scintimammography and PET imaging.

### Factors in Successful SLN Biopsy

Schirmeister et al. from the University of Kiel (Germany) reported in the December issue of *Cancer Biotherapy and Radiopharmaceuticals* (2004;19:784–790) on a multicenter study to assess the reliability of sentinel lymph node (SLN) biopsy in breast cancer and to identify factors influencing success rates. The study included 814 patients in whom SLN biopsy and axillary lymph node dissection were performed. Surgeons were allowed to choose the use of the blue dye (137 patients), radiocolloid (169 patients), or combined blue dye/radiocolloid (508 patients) techniques. The SLN was identified in 83.9% of all patients, a rate that varied with technique (blue dye, 71.6%; radiocolloid, 78.8%; combined blue dye and radiocolloid, 89.6%). Other

significant factors included the method of injection (with the combined subdermal/peritumoral injection of the colloid showing a higher identification rate than subdermal or peritumoral injection alone) and whether or not the SLN biopsy was performed before or after lumpectomy (94.7% and 82.8% detection rates, respectively). The experience of the surgeon in performing the detection procedure was also directly correlated with success rates. The authors concluded that SLN mapping predicts the axillary lymph node status accurately and that while several factors may influence the detection rate, “the false-negative rate was independent of experience and injection technique.”

*Cancer Biotherapy and Radiopharmaceuticals*

### <sup>99m</sup>Tc-Sestamibi Scintimammography

A group from the European Institute of Oncology (Milan, Italy) reported in the October issue of *Cancer Biotherapy and Radiopharmaceuticals* (2004;19:621–626) on a study of the utility of <sup>99m</sup>Tc-sestamibi scintimammography in the management of patients with suspected primary or recurrent breast cancer in whom conventional diagnostic methods had proven equivocal or inconclusive. De Cicco et al. studied 40 women with a total of 44 breast lesions (21 palpable, 23 not palpable). All underwent <sup>99m</sup>Tc-sestamibi scintimammography with subsequent histologic determination of 24 lesion specimens as malignant. Scintimammography correctly identified 21 of these, as well as 12 true negatives. Eight lesions were false-positives, so that overall the sensitivity of the technique was 87.5%, specificity was 60%, positive predictive value was 72.4%, and negative predictive value was 80%, with a 100% sensitivity in palpable le-

sions. The authors concluded that scintimammography “is useful in equivocal palpable lesions for resolving diagnostic uncertainty after conventional examination, and can limit the number of surgical interventions for benign disease.” They did not recommend the use of the technique in nonpalpable tumors.

*Cancer Biotherapy and Radiopharmaceuticals*

### <sup>99m</sup>Tc-Labeled Tracers and In Situ Breast Carcinoma

In a report e-published on November 8 ahead of print in *Breast Cancer Research* (2005;7:R33–R45), Papantoniou et al. from the Alexandria University Hospital (Athens, Greece) described a retrospective study undertaken to investigate the distribution of <sup>99m</sup>Tc-pentavalent dimercaptosuccinic acid (<sup>99m</sup>Tc-V-DMSA) and <sup>99m</sup>Tc-sestamibi in ductal breast carcinoma in situ and lobular breast carcinoma in situ. The study included 102 women with palpable masses or mammographic findings, who were assigned to 1 of 3 scintimammography imaging groups (<sup>99m</sup>Tc-V-DMSA, <sup>99m</sup>Tc-sestamibi, and both radiotracers). Images were acquired at 10 and 60 minutes, and results were correlated with mammographic, histologic, and immunohistochemical characteristics. Diffuse <sup>99m</sup>Tc-V-DMSA accumulation was noted in 18 of 19 cases of in situ carcinoma identified after surgery, whereas diffuse <sup>99m</sup>Tc-sestamibi was noted in 6 of 13 such cases. For <sup>99m</sup>Tc-V-DMSA, the tumor-to-background ratio was significantly higher at 60 minutes, and the uptake was associated with the presence of suspicious microcalcifications. The authors showed complementarity in results from the 2 tracers, with <sup>99m</sup>Tc-V-DMSA having a high sensitivity and <sup>99m</sup>Tc-sestamibi a high specificity

in detecting in situ breast carcinoma. They concluded that “these radiotracers could provide clinicians with preoperative information not always obtainable by mammography.”

*Breast Cancer Research*

### Prognostic Value of Residual $^{99m}\text{Tc}$ -Sestamibi Uptake After Chemotherapy for Breast Cancer

In an article e-published ahead of print on January 6 in *Cancer*, Dunnwald et al. from the University of Washington (Seattle) reported on a study of the prognostic value of residual tumor uptake of  $^{99m}\text{Tc}$ -sestamibi after neoadjuvant chemotherapy for locally advanced breast cancer. The study included 62 patients with locally advanced breast cancer who underwent  $^{99m}\text{Tc}$ -sestamibi scintimammography immediately before chemotherapy and 2 months later, with a third imaging procedure performed in those individuals whose treatment lasted more than 3 months.  $^{99m}\text{Tc}$ -sestamibi uptake was quantified using the lesion-to-normal breast ratio. Outcomes were compared with posttherapy primary  $^{99m}\text{Tc}$ -sestamibi uptake. The authors found that patients with high uptake on the last  $^{99m}\text{Tc}$ -sestamibi (whether the second or third) had shorter disease-free survival and overall survival times than patients with low uptake. They concluded that “serial MIBI imaging may provide a useful quantitative surrogate end point for neoadjuvant chemotherapy trials” and that “given the association between MIBI uptake and tumor blood flow, this prognostic capability may be related to retained tumor vascularity after treatment.”

*Cancer*

### An Improved Camera for Mammography

Writing in the February issue of *Technology in Cancer Research and Treatment* (2005;4:61–68), Reznik et al. from the University of Toronto

(Ontario, Canada) reported on the development of a positron emission mammography (PEM) system that the authors maintain retains the high specificity of  $^{18}\text{F}$ -FDG PET and provides improved collection efficiency for the radiotracer signal and the potential for images with better spatial resolution. The result is a system that can enable detection of much smaller lesions than can be visualized with whole-body PET. The compact dual-head PEM camera combines the fast scintillation light decay and high light yield of lutetium oxyorthosilicate with the quantum efficiency, large avalanche gain, and rapid response time of an amorphous selenium photodetector.

*Technology in Cancer Research and Treatment*

### Promise of PET Mammography

In a separate article in *Technology in Cancer Research and Treatment* (2005;4:55–60), Weinberg et al. from Naviscan PET Systems (Rockville, MD) discussed the performance advantages of a full-breast positron emission mammography (PEM) device that provides images with spatial resolution matching individual ducts (1.5 mm full width at half maximum). This spatial resolution, supported by count efficiency that results in high signal-to-noise ratio, allows confident visualization of intraductal as well as invasive breast cancers. They cited clinical trials with the PEM device that have shown 93% sensitivity and 83% specificity for characterizing images identified as suspicious through conventional imaging or palpation. This high sensitivity (91%) was preserved for intraductal cancers. The authors concluded that “it is likely that the use of PEM will complement anatomic imaging modalities in the areas of surgical planning, high-risk monitoring, and minimally invasive therapy” and that the “quantitative nature of PET promises to assist researchers interested in studying the response of putative

cancer precursors (e.g., atypical ductal hyperplasia) to candidate prevention agents.”

*Technology in Cancer Research and Treatment*

### Asymptomatic Diabetic Patients and SPECT Screening

In the January 4 issue of the *Journal of the American College of Cardiology* (2005;45:43–49), Rajagopalan et al. from the Mayo Clinic (Rochester, MN) reported on an extension of their investigations into the utility of SPECT screening in asymptomatic diabetic patients. The group previously reported a high percentage of abnormal and high-risk SPECT scans in such patients (*Am Heart J.* 2004;147:890–896). In the current study, they examined the associations between clinical and laboratory variables, long-term survival, and high-risk stress SPECT scans in 1,427 asymptomatic diabetic patients without known coronary artery disease (CAD) in an effort to assess which patients should be screened. More than half of the patients (826; 58%) had abnormal stress SPECT scans, and 261 (18%) had scans classified as high risk. They identified 7 variables as independently associated with high-risk scans, with the 2 most important being electrocardiogram (ECG) Q waves and peripheral arterial disease (PAD). Coronary angiography was performed in 127 of the high-risk SPECT imaging patients, 61% of whom were shown to have angiographic high-risk CAD. Mortality rates at 1 year for the patients screened by SPECT were: high-risk, 5.9%; intermediate-risk, 5.0%; and low-risk, 3.6%. The authors concluded that the use of ECG Q waves and/or evidence of PAD might be used to identify the most suitable candidates for screening and that the high prevalence of severe CAD and high annual mortality rate among those identified by SPECT as high-

risk is a strong argument in favor of such screening.

*Journal of the American College of Cardiology*

## SPECT MPI in High-Risk Patients

Borges-Neto et al. from Duke University (Durham, NC) reported in the January 15 issue of the *American Journal of Cardiology* (2005;95:182–188) on a study designed to evaluate the prognostic power of SPECT myocardial perfusion imaging (MPI) in a group of patients with known or suspected coronary artery disease. The study included 3,275 patients who underwent cardiac catheterization and SPECT MPI. The median follow-up was 3.1 years, and outcomes measured included death, cardiovascular death, and a composite of cardiovascular death or nonfatal myocardial infarction. The authors correlated a SPECT summed stress score (SSS) with each outcome and found that a 1-unit change in SSS was associated with increased risks of 4%, 7%, and 5% for death, cardiovascular death, and death or nonfatal myocardial infarction, respectively. The authors concluded that SPECT SSS provides information beyond clinical and angiographic data in patients who have known or suspected coronary artery disease and that “this information may be useful for stratifying patients into multiple risk categories for future cardiovascular events and potentially guiding therapy.”

*American Journal of Cardiology*

## Radionuclide-Guided Endoscopy

Raylman and Srinivasan, from West Virginia University (Morgantown) reported in the December issue of *Medical Physics* (2004;31:3306–3313) on a system for performing radionuclide-guided endoscopies. The Endoprobe system includes a beta detector and position tracker, which are mounted on the tip of an endoscope, and a user interface that displays in-

formation from the beta detector and tracking system as well as the video signal from the endoscope. The device facilitated visual identification of simulated lesions in <sup>18</sup>F-FDG phantom studies. The position tracking system was used to plot the location of the Endoprobe tip in real time on a previously acquired PET/CT image of the phantom. The device was able to assist in distinguishing normal esophagus from simulated tracer-avid areas as small as 3.5 mm in diameter. The authors noted that the Endoprobe is suitable for use with other PET tracers and that work continues toward eventual clinical applications.

*Medical Physics*

## Registration of PET and CT Images of the Liver

In the December 7 issue of *Physics in Medicine and Biology* (2004;49:5393–5405), van Dalen et al. from the University Medical Center Nijmegen (The Netherlands) reported on a semiautomatic, organ-focused method to minimize the uncertainty usually present in registration of PET and CT images of the liver. The study included CT and <sup>18</sup>F-FDG PET images of 10 patients with liver metastases. The novel method included restricting registration to the liver region, isolating the liver on CT from surrounding structures using a thresholding technique, and using the mutual information-based method as implemented in the National Library of Medicine’s Insight Toolkit. Results of this method were compared with results of manual, landmark-based, and standard mutual information-based methods or registration in which no dedicated image processing was performed. The new method outperformed the other methods with a precision of  $2.5 \pm 1.3$  mm. The authors concluded that their approach “allows for robust CT-FDG-PET registration of the liver, with an accuracy better than the spatial resolution of the PET scanner that was used.”

*Physics in Medicine and Biology*

## Value of Extensive Staging in Melanoma

In a study published in the January issue of the *Journal of the European Academy of Dermatology and Venereology* (2005;19:66–73), Vereecken et al. from the Free University of Brussels (Belgium) evaluated the effect of extensive initial staging, including PET, on the management of intermediate/high-risk melanoma patients. The study included 43 patients with prognoses of intermediate/poor primary melanoma who underwent staging with CT, MR imaging, and whole-body <sup>18</sup>F-FDG PET before complementary excision and sentinel lymph node (SLN) biopsy. The SLN procedure identified regional lymph node metastases in 10 patients, of whom PET identified only 4. These 10 patients benefited from early surgery and were included in adjuvant treatment protocols. The combination of staging techniques also identified a secondary primary cancer in 2 additional patients. The authors noted that the development of new adjuvant therapies and a wider choice of therapeutic procedures have placed new emphasis on extensive staging of patients with melanoma and intermediate/poor prognoses. Although PET was determined to be unhelpful in the detection of micrometastases and inferior to SLN biopsy in initial regional staging, the authors were encouraged by the fact that “12 of 43 patients were treated early or were included early in treatment protocols thanks to the extensive staging procedure.” They called for caution in drawing conclusions about the overall utility of such screening and for larger prospective trials to evaluate the effects of these early diagnoses and new treatments on overall survival before defining new diagnostic and therapeutic guidelines.

*Journal of the European Academy of Dermatology and Venereology*

## PET After Therapy in Head and Neck Cancer

In an article e-published ahead of print on December 30 in *Head and Neck*, Porceddu et al. from the Peter MacCallum Cancer Centre (East Melbourne, Australia) reported on the use of  $^{18}\text{F}$ -FDG PET in the detection of disease in residual neck nodes after definitive chemo- and radiation therapy. The study included 39 patients with node-positive mucosal head and neck squamous cell carcinoma who achieved complete response at the primary site but had residual mass 8 weeks or more after chemo- and radiotherapy. All patients underwent PET scanning for reevaluation. PET showed no metabolic activity in the residual mass in 32 patients. Of these, 5 underwent a neck dissection and were negative for disease. The remaining 27 patients in the group were observed for a median of 34 months, with only 1 locoregional failure. The negative predictive value of PET for viable disease in a residual anatomic abnormality was 97%. The authors concluded that “patients who have achieved a complete response at the primary site but have a residual abnormality in the neck that is PET negative approximately 12 weeks after treatment do not require neck dissection and can be safely observed.”

*Head and Neck*

## PET and Pancreatic Cysts

Sperti et al. from the University of Padua (Italy) and the Castelfranco Hospital (Treviso, Italy) reported in the January issue of the *Journal of Gastrointestinal Surgery* (2005;9:22–29) on the use of  $^{18}\text{F}$ -FDG PET in the preoperative work-up of patients with pancreatic cystic lesions. The study included 50 such patients who underwent both PET and spiral CT imaging, with results compared with pathologic findings after surgery (31 patients), percutaneous biopsy (4 patients), and follow-up (15 patients). Of the 17 patients who were shown to have malignant cystic lesions, 16 had

increased tracer uptake on PET. CT identified only 11 of these patients. Of the 33 patients with benign tumors, 2 patients had increased uptake on PET (false-positives) and 4 patients were false-positive on CT. The authors concluded that  $^{18}\text{F}$ -FDG PET “is accurate in identifying malignant pancreatic cystic lesions and should be used in combination with CT in the preoperative evaluation of patients with pancreatic cystic lesions” and added that “a negative result with  $^{18}\text{F}$ -FDG PET may avoid unnecessary operation in asymptomatic or high-risk patients.”

*Journal of Gastrointestinal Surgery*

## Therapy

### $^{131}\text{I}$ -Tositumomab and Mantle Cell Lymphoma

Rajendran et al. from the University of Washington (Seattle) reported in the December issue of *Cancer Biotherapy and Radiopharmaceuticals* (2004;19:738–745) on a review of normal organ radiation-absorbed doses to antigen-bearing tumor in 25 patients with mantle cell lymphoma who received myeloablative radioimmunotherapy (RIT) using  $^{131}\text{I}$ -tositumomab. Radiation dosimetry was performed on all patients after a trace-labeled infusion of  $^{131}\text{I}$ -tositumomab to calculate the required amount of radioactivity for therapy. The mean organ residence times (in hours) were corrected for CT-derived organ volumes and were: lungs, 9.0; liver, 12.4; kidneys, 1.7; spleen, 2.17; and whole body, 62.4. Mean radiation absorbed doses (in mGy/MBq) were: lungs, 1.2; liver, 1.1; kidneys, 0.85; spleen: 1.7; and whole body, 0.21. The authors concluded that “myeloablative RIT using  $^{131}\text{I}$ -tositumomab results in normal organ radiation-absorbed doses similar to those in patients with other non-Hodgkin’s lymphoma, and is suitable for treating patients with relapsed or refractory MCL.”

*Cancer Biotherapy and Radiopharmaceuticals*

## NMT PET Radiation Dose

In the February issue of *Health Physics* (2005;88:S17–S21), an Australian group headed by Robinson from Austin Health (Heidelberg, Victoria) and others from the Australian Radiation Service (Nunawading, Victoria) reported on the results of a study of the personal radiation dose received by nuclear medicine technologists working in a dedicated PET center. They determined that the typical staff member received approximately 1  $\mu\text{Sv}$  per minute of close contact with patients, which resulted in an average daily dose for nuclear medicine technologists of approximately 31  $\mu\text{Sv}$ . The average daily administered activity to patients at the facility was 1,280 MBq.

*Health Physics*

## Third-Party Exposure to $^{131}\text{I}$

The debate over the significance and regulation of third-party radiation exposure from patients treated with  $^{131}\text{I}$  continues in the United States and around the world. In an article in the December issue of *Medical Physics* (2004;31:3194–3200), Matheoud et al. from the Ospedale Maggiore di Milano (Italy) reported on a study that included 33 hyperthyroid patients treated with a mean administered activity of 414 MBq radioiodine. The purpose of the study was to determine whether pretreatment dosimetry could be used to give radiation protection advice that could improve compliance with effective dose constraints suggested by the European Commission. The mean estimated effective doses to travelers, coworkers, and sleeping partners were 0.11 mSv, 0.24 mSv, and 1.8 mSv, respectively. The authors identified the best correlation between effective dose in millisieverts and maximum activity ( $\text{AU}_{\text{max}}$ ) in megabecquerels taken up in the thyroid. For co-workers, the effective dose constraint of 0.3 mSv could be met with no restrictions if the  $\text{AU}_{\text{max}}$  was lower than 185 MBq or by having the

patient take 3 days off work if it was higher. For sleeping partners, the effective dose constraint of 3 mSv could be met with no restrictions if the  $AU_{max}$  was lower than 185 MBq and with 4 nights sleeping apart if it was higher. The potential for contamination was determined from perspiration samples taken from patients' hands, foreheads, and necks, and from saliva at 4, 24, and 48 hours after radioiodine treatment. The authors concluded that their results "indicate that there is minimal risk of contamination from these patients."

*Medical Physics*

### Retinoids and Increases in Iodine Uptake

Short et al. from the Royal Marsden Hospital (London, UK) reported in the December issue of *Clinical Oncology* (Royal College of Radiology) on a phase II study designed to assess whether oral isotretinoin could increase radioiodine uptake in patients who had uptake-negative thyroid cancers. The study included 16 patients with iodine-uptake-negative

metastatic papillary (9 patients), follicular (5 patients), or Hurthle cell (2 patients) thyroid cancers, who were imaged with CT or MR and in whom absence of iodine uptake was confirmed using a diagnostic radioiodine scan before study entry. All patients were reviewed every 2 weeks during the full 8-week oral isotretinoin treatment period. All patients tolerated 8 weeks of oral isotretinoin. In 1 patient, radioiodine uptake increased after retinoid administration, but not sufficiently to permit a significant dose of iodine to sites of metastases. No uptake was seen in the remaining 15 patients, indicating that the retinoid did not redifferentiate cells to allow for increased radioiodine uptake.

*Clinical Oncology*

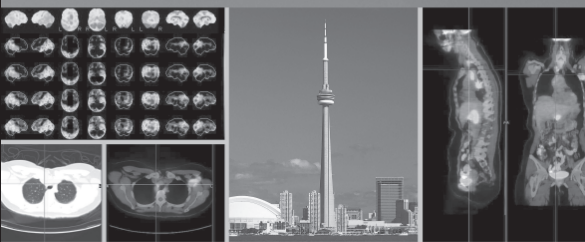
### $^{131}\text{I}$ -MIBG and $^{111}\text{In}$ -Octreotide Palliation in Neuroendocrine Neoplasms

Both  $^{111}\text{In}$ -octreotide and  $^{131}\text{I}$ -metaiodobenzylguanidine ( $^{131}\text{I}$ -MIBG) have shown limited antitumor effects in therapy for neuroendocrine

neoplasms (NENs). In a study published in the December issue of *Surgery* (2004;136:1218–1226), Pasieka et al. from the University of Calgary and Tom Baker Cancer Center (Alberta, Canada) assessed the palliative effects of these radionuclides in such therapeutic applications. The study included 24 patients with progressive, nonsurgically resectable NENs. Patients whose NENs were MIBG positive (13) received  $^{131}\text{I}$ -MIBG therapy, and patients whose NENs were octreotide-only-positive (11) received  $^{111}\text{In}$ -octreotide therapy. Twelve patients (92%) in the  $^{131}\text{I}$ -MIBG group experienced symptomatic improvement. Symptomatic benefit was seen in 6 patients (55%) in the  $^{111}\text{In}$ -octreotide group. A wide range of variations in types of disease was seen across the spectrum of participants in this study. The authors concluded that "radionuclide therapy appears to offer good palliation to patients with progressive NENs."

*Surgery*

Society of Nuclear Medicine  
52<sup>nd</sup> Annual Meeting  
PRELIMINARY PROGRAM



June 18–22, 2005 • Metro Convention Centre • Toronto, Canada • [www.snm.org/am](http://www.snm.org/am)

SAVE ON REGISTRATIONS!  
REGISTER BY APRIL 29, 2005  
TO RECEIVE DISCOUNTED RATES!

snm  
advancing molecular imaging

# Stay updated...

Society of Nuclear Medicine 52<sup>nd</sup> Annual Meeting  
PRELIMINARY PROGRAM

Included with this issue or visit [www.snm.org/am](http://www.snm.org/am)