
Electrocardiographic Gated ^{99m}Tc -MIBI SPECT for Functional Assessment of Patients After Coronary Artery Bypass Surgery: Comparison of Wall Thickening and Wall Motion Analysis

Junichi Taki, MD, PhD¹; Takahiro Higuchi, MD¹; Kenichi Nakajima, MD, PhD¹; Ichiro Matsunari, MD, PhD²; Eui-Hyo Hwang, MD, PhD¹; Hisashi Bunko, MD, PhD¹; Michio Kawasuji, MD, PhD³; Go Watanabe, MD, PhD³; and Norihisa Tonami, MD, PhD¹

¹Department of Biotracer Medicine, Kanazawa University Graduate School of Medical Sciences, Kanazawa, Japan; ²Department of Thoracic, Cardiovascular, and General Surgery, Kanazawa University Graduate School of Medical Sciences, Kanazawa, Japan; and ³Medical and Pharmacological Research Foundation, Hakui, Japan

Abnormal septal motion after coronary artery bypass graft surgery (CABG) is a common finding. This study was undertaken to investigate the change in various global and regional ventricular function parameters measured by gated myocardial perfusion SPECT after surgery and to determine which quantitative parameter of WT and WM is more appropriate for the evaluation of regional cardiac function, especially in the septum of patients with CABG. **Methods:** Before and 3 to 5 wk after CABG (all patients underwent at least 1 bypass grafting to the left anterior descending coronary artery), 35 patients (28 men, 7 women) underwent gated SPECT using ^{99m}Tc -methoxyisobutylisonitrile. Quantitative global and regional ventricular functional analysis was performed using quantitative gated SPECT software. **Results:** Global ejection fraction did not change ($59.3\% \pm 16.0\%$ to $60.5\% \pm 14.5\%$, $P = 0.24$). However, end-diastolic and end-systolic volumes lessened significantly after CABG (81.4 ± 37.3 mL to 68.9 ± 28.9 mL, $P < 0.0001$, and 38.1 ± 33.1 mL to 30.4 ± 23.0 mL, $P < 0.005$, respectively). As global function parameters, the changes in both total WM ($r = 0.88$) and WT ($r = 0.86$) correlated well with the change in ejection fraction after surgery. Segmental analysis showed a significant postoperative increase in relative tracer uptake in the anterior, anteroseptal, inferoseptal, and inferior walls and in the apex. Segmental wall motion (WM) deteriorated in the anteroseptal, inferoseptal, and mid anterior walls. On the other hand, anterolateral, inferolateral, and inferior WM increased. As a whole, these WM changes showed a reduction in septal motion associated with a concomitant increase in lateral motion after surgery. Segmental wall thickening, however, did not decrease in septal areas and did not increase in the lateral wall and correlated with percentage tracer uptake ($r = 0.69$) better than WM did ($r = 0.30$) after CABG. **Conclusion:** In patients with CABG, postoperative WM analysis by gated SPECT underestimated septal motion and overestimated lateral motion because of exaggerated systolic

anteromedial cardiac translation. Therefore, wall thickening analysis would be recommended for the evaluation of postoperative cardiac function.

Key Words: gated SPECT; methoxyisobutylisonitrile; septum; wall motion; ventricular function

J Nucl Med 2002; 43:589–595

Before the introduction of gated myocardial SPECT, global and regional functional assessments were performed on the basis of wall motion (WM) obtained by a first-pass study or electrocardiographic gated blood-pool scintigraphy. Recently, gated SPECT has become a reality in daily nuclear cardiology practice because of the development of sophisticated software and a dramatic decrease in processing time thanks to the evolution of computer technology. Accurate measurement of left ventricular functional parameters such as ejection fraction (EF), global and regional systolic wall thickening (WT) and WM, end-diastolic volume (EDV), and end-systolic volume (ESV) by gated SPECT has been reported (1–6). For evaluation of regional myocardial function, as a new parameter, WT can be estimated simultaneously with WM by gated SPECT; WM is evaluated by measuring the excursion of the ventricular endocardial surface, and systolic WT is evaluated by assessing changes in regional myocardial counts or the combination of count change and dimensional change between endocardial and epicardial surfaces (2,6,7). In the assessment of cardiac function in patients with coronary artery disease, WT, as well as WM, has proven to be a reliable functional parameter (2,8–13). Septal WM after coronary artery bypass graft surgery (CABG) has been reported to deteriorate despite lack of significant myocardial damage (14–17). Therefore, assessment of septal function after CABG has been considered to be difficult, and exclusion of this region

Received Jul. 30, 2001; revision accepted Jan. 16, 2002.
For correspondence or reprints contact: Junichi Taki, MD, PhD, Department of Biotracer Medicine, Kanazawa University Graduate School of Medical Sciences, 13-1 Takara-machi, Kanazawa, 920-8640, Japan.
E-mail: taki@med.kanazawa-u.ac.jp

from analysis has been recommended. However, WT may be an alternative approach to functional assessment after CABG (18,19).

Therefore, the aim of this study was to investigate the changes in various global and regional functional parameters obtained by gated SPECT after surgery and to determine which quantitative parameter of WT and WM is more appropriate for the evaluation of regional cardiac function, especially in the septum of patients with CABG.

MATERIALS AND METHODS

Patients

This study included 35 patients (28 men, 7 women; mean age \pm SD, 66 ± 7.6 y) with chronic coronary artery disease who had been scheduled for bypass surgery. Thirteen patients (11 men, 2 women) had a previous myocardial infarction. Of these, 8 patients had an anterior myocardial infarction and 5 had an inferior myocardial infarction. Four patients had 1-vessel disease, 9 had 2-vessel disease, and 22 had 3-vessel disease. All patients underwent bypass grafting to the left anterior descending coronary artery, with an average of 2.7 ± 0.9 bypass grafts per patient (a total of 96 grafts). Arterial grafts were inserted to all left anterior descending coronary arteries ($n = 35$) and to 4 circumflex coronary arteries. Venous grafts were used in the right ($n = 24$) and left ($n = 26$) circumflex coronary arteries and in the diagonal branches ($n = 7$). Graft patency was confirmed in 17 patients near the time of the postoperative SPECT study. All arterial grafts were patent

except in 1 patient with poor runoff; however, 5 (2 grafts to the right coronary arteries and 3 to the left circumflex coronary arteries) of 29 venous grafts were occluded. All patients in this study had sinus rhythm, and none had cardiomyopathy or valvular heart disease. No patients had any evidence of perioperative myocardial infarction or complications after surgery.

Gated SPECT

All patients underwent gated SPECT before and 3–5 wk after bypass surgery. Forty minutes to 1.5 h after intravenous injection of 740–1,000 MBq ^{99m}Tc -methoxyisobutylisonitrile (MIBI) at rest, gated SPECT was performed using a triple-head system (9300A; Toshiba, Tokyo, Japan) equipped with low-energy, high-resolution parallel-hole collimators. The energy discrimination was centered on 140 KeV with a 20% window, and a total of 60 projection images were obtained in a 64×64 matrix over 360° , with 60 s per view. At each projection, 12 electrocardiographic gated frames per cardiac cycle were acquired. For image reconstruction, after projection data were prefiltered using a Butterworth filter (order, 8; cutoff frequency, 0.4 cycles per centimeter), filtered backprojection was performed using a ramp filter.

Data Analysis

After image reconstruction, the data were analyzed using commercially available automatic-processing software for gated perfusion SPECT (quantitative gated SPECT [QGS], version 2; Cedars-Sinai Medical Center, Los Angeles, CA). This software was previously described and validated (1,2,20). Polar maps of regional perfusion, WM, and WT were generated. Regional perfusion

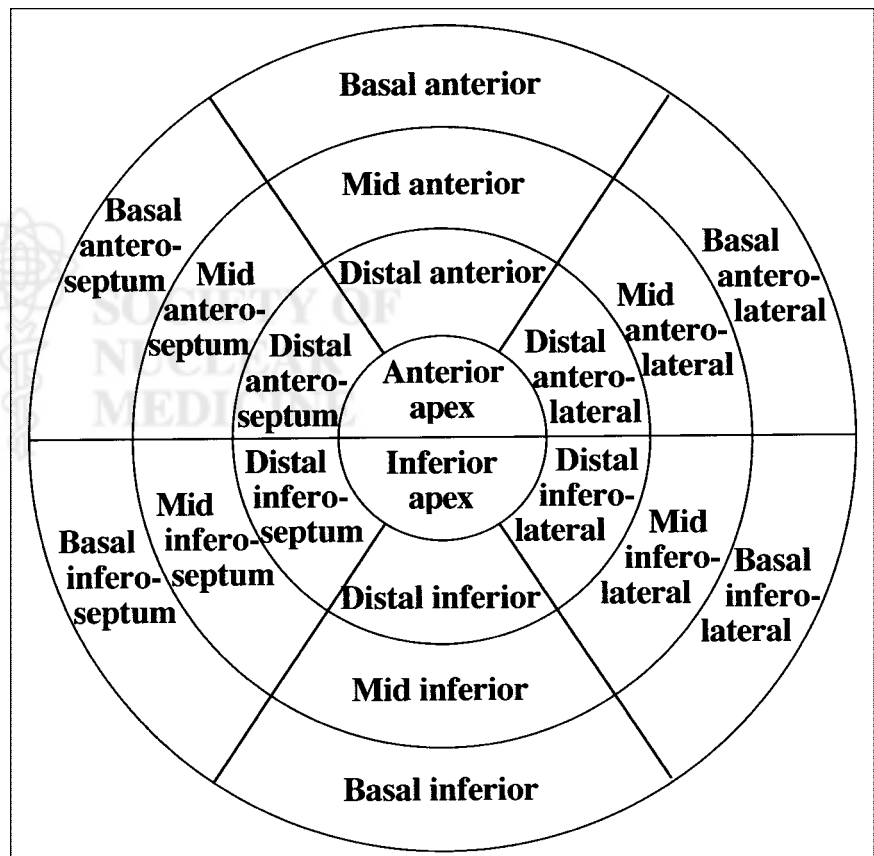


FIGURE 1. Myocardium was divided into 20 segments. Percentage tracer uptake, WM, and WT were analyzed.

(tracer uptake) was expressed as the percentage of maximal myocardial counts on nongated images. WM was expressed as endocardial inward movement (in millimeters) from the end-diastolic to the end-systolic phase. WT was expressed as the percentage increase in wall thickness from the end-diastolic to the end-systolic phase. For regional functional analysis, the distal, mid, and basal areas of the myocardium were divided into 6 segments each, and the apex into 2 segments, and analyzed quantitatively on the basis of each functional polar map (Fig. 1). For global functional analysis, total WM and total WT were calculated by summing all 20 segmental values.

Statistical Analysis

All results were expressed as mean \pm 1 SD. The significance of the mean difference before and after CABG was assessed with a paired *t* test. The relationship between perfusion and functional parameters (WM and WT) and between EF and functional parameters was evaluated using linear regression plots. $P < 0.05$ was considered statistically significant.

RESULTS

Global EF improved slightly, from $59.3\% \pm 16.0\%$ to $60.5\% \pm 14.5\%$, preoperatively to postoperatively, but this change was not statistically significant ($P = 0.24$). However, EDV and ESV lessened significantly after CABG (81.4 ± 37.3 mL to 68.9 ± 28.9 mL, $P < 0.0001$, and 38.1 ± 33.1 mL to 30.4 ± 23.0 mL, $P < 0.005$, respectively). The total WM did not change (131 ± 40 mm to 129 ± 38 mm, $P = 0.53$) after surgery, nor did the total WT ($765\% \pm 284\%$ to $778\% \pm 298\%$, $P = 0.58$). When the global functional parameters were analyzed, good correlations were observed both between global EF change and total WM change ($r = 0.88$; $P < 0.0001$) and between global EF change and total WT change ($r = 0.86$; $P < 0.0001$) (Fig. 2).

Segmental relative tracer uptake before and after CABG is shown in Figure 3. Significant postoperative increases in relative tracer uptake were observed in the apex and in the mid to distal anterior, anteroseptal, basal to distal inferoseptal, inferior, and mid anterolateral walls. As shown in Figure 4, segmental WM deteriorated in the basal to distal anteroseptal, inferoseptal, and mid anterior walls. On the other hand, basal to distal anterolateral, inferolateral, and inferior WM increased. As a whole, these WM changes showed a reduction in septal motion associated with a concomitant increase in lateral motion after surgery. However, segmental WT did not decrease in septal areas or increase in the lateral wall and improved significantly in the basal and mid inferoseptal wall and in the basal inferior wall (Fig. 5).

In the subset of 9 patients with global EF reduction (preoperative EF $< 50\%$), similar tendencies were observed. Global EF tended to improve—from $38.1\% \pm 10.5\%$ preoperatively to $42.2\% \pm 7.7\%$ postoperatively ($P = 0.058$). However, EDV and ESV lessened significantly after CABG (120 ± 50.2 mL to 98.2 ± 34.7 mL, $P < 0.05$, and 78.3 ± 42.5 mL to 58.8 ± 26.1 mL, $P < 0.05$,

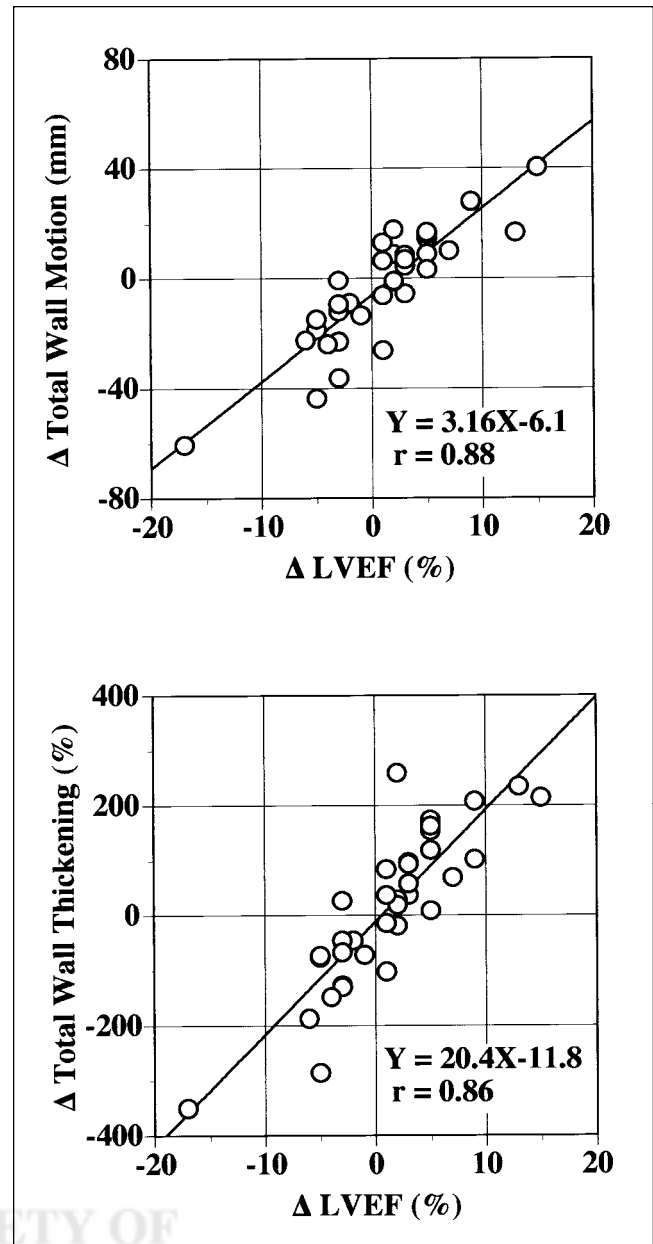


FIGURE 2. Correlation between change in EF and change in total WM and between change in EF and change in total WT after bypass surgery. LVEF = left ventricular EF.

respectively). Total WM did not change after surgery (76.5 ± 21 mm to 85.3 ± 13 mm, $P = 0.16$), nor did total WT ($398\% \pm 123\%$ to $445\% \pm 77\%$, $P = 0.11$). In segmental analyses, significant postoperative increases in relative tracer uptake were observed in the anterior and inferior apices and in the distal inferoseptal and inferior walls. WM deteriorated in the basal to distal anteroseptal and inferoseptal walls, with an increase in WM in the mid to distal anterolateral wall, basal to distal inferolateral wall, and anterior apex. However, WT did not decrease in septal areas or increase in the lateral wall and improved significantly in the basal anterior wall and in the anterior apex.

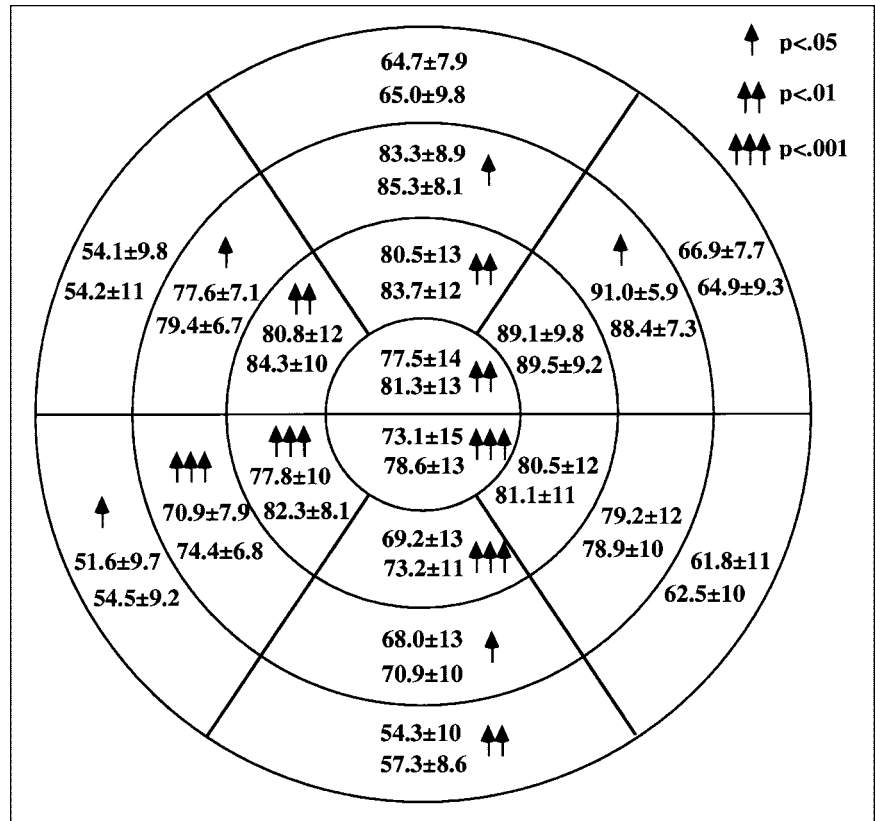


FIGURE 3. Change in segmental relative tracer uptake (percentage, mean ± SD) before and after CABG. In each segment, top values are preoperative uptake and bottom values are postoperative uptake.

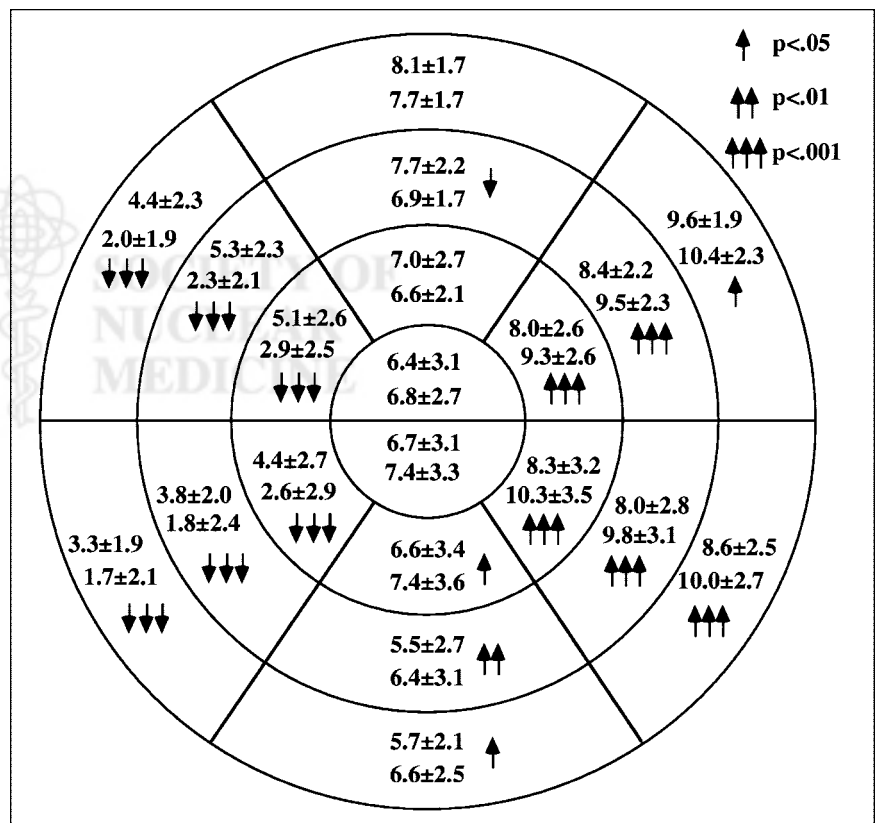


FIGURE 4. Change in segmental WM (millimeters, mean ± SD) before and after CABG. In each segment, top values are preoperative WM and lower values are postoperative WM. After CABG, concomitant deterioration of septal WM and augmentation of lateral WM were observed.

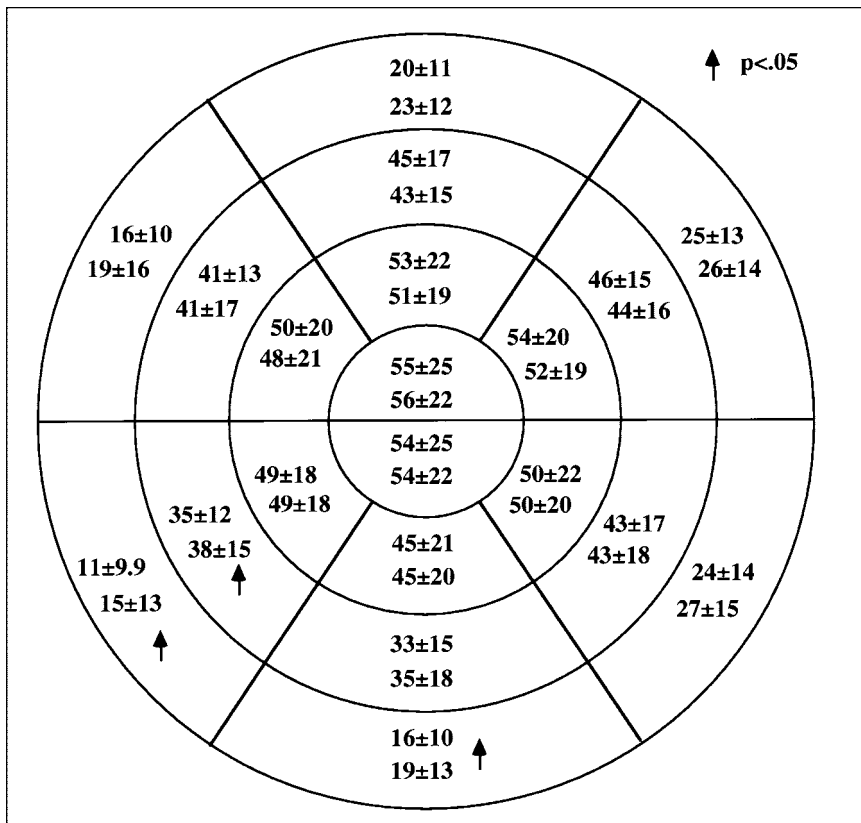


FIGURE 5. Change in segmental systolic WT (percentage, mean \pm SD) before and after CABG. In each segment, top values are preoperative WT and bottom values are postoperative WT. No deterioration of WT in any segments was observed despite septal WM deterioration.

In the whole population, a significant but weak correlation between perfusion (percentage of MIBI uptake) and WM was observed both before and after surgery, although the correlation coefficient deteriorated from 0.49 to 0.30 after surgery. After CABG, lateral WM tended to be larger and septal WM to be smaller in comparison with percentage of tracer uptake (Fig. 6A). The relationship between perfusion and WT was better than that between perfusion and WM, and the correlation coefficients were similar before and after surgery (0.76 and 0.69, respectively). Septal and lateral WT, when compared with percentage of tracer uptake, distributed similarly both before and after CABG (Fig. 6B).

DISCUSSION

This study revealed that, in CABG patients with an uncomplicated clinical course, although global ventricular functional parameters such as LVEF, total segmental WM, and WT did not change significantly 3–5 wk after surgery, EDV and ESV decreased significantly. These nonsignificant LVEF changes and the decrease in EDV and ESV early after surgery are consistent with previous studies using gated blood-pool and gated myocardial SPECT (21,22). As a global function parameter, the changes in both total WM ($r = 0.88$) and WT ($r = 0.86$) correlated well with the EF change after surgery. As a regional function parameter, septal WM decreased and lateral WM increased postoperatively; however, WT did not deteriorate in any segments.

These results suggested that the WM analysis after bypass surgery underestimated septal function and overestimated lateral function because of an anteromedial systolic ventricular shift. Furthermore, regional WT correlated better with regional percentage of MIBI uptake than did WM. Therefore, for assessment of regional ventricular function after bypass surgery, systolic WT analysis would be preferable.

In previous studies evaluating left ventricular function after bypass surgery, septal functional analysis was avoided because of frequent postoperative WM abnormality. Such WM abnormality was frequently observed without evidence of perioperative myocardial infarction, new perfusion abnormality, or complications during recovery after the operation (17,23), and the evidence from the current study that septal motion reduction accompanied enhanced lateral motion after CABG suggested that septal motion abnormality is an artifactual finding caused by the systolic anteromedial translation of the entire heart (14,16,24). This exaggerated cardiac mobility is thought to be related to sternotomy and pericardiotomy (14,17) or to events occurring during cardiopulmonary bypass (24).

Determination of regional and global left ventricular function after CABG allows evaluation of intraoperative cardiac injury, improvement of function, and subsequent prognosis and thus is important for patient management. For assessment of regional function, use of WM analysis has been common. In most of the modalities, such as ventriculography with contrast medium, gated blood-pool scintigraphy

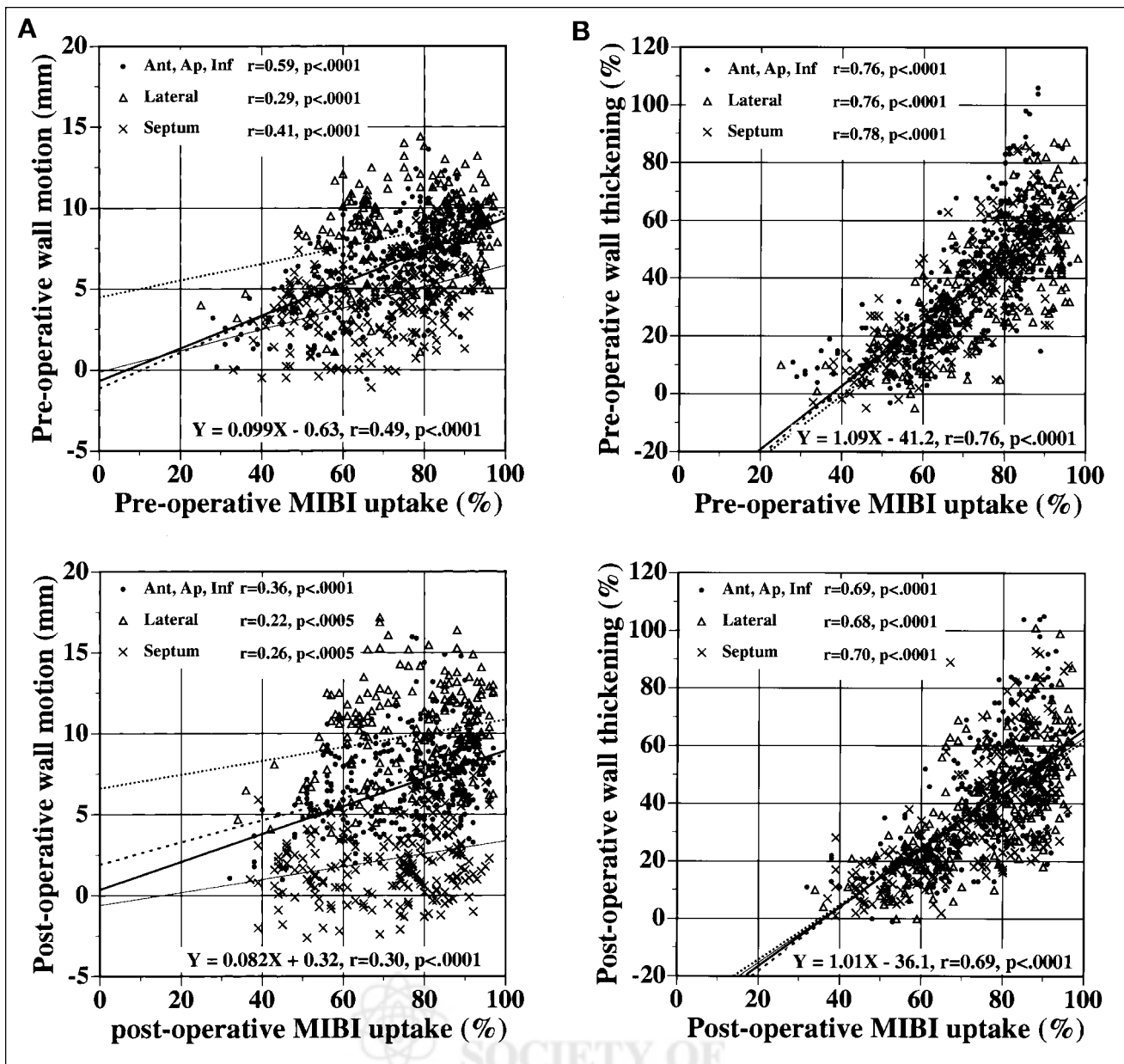


FIGURE 6. Relationship between perfusion (MIBI uptake) and functional parameters (WM [A] and WT [B]) before and after bypass surgery. Bold solid lines indicate regression lines of all data; equation is provided. Light solid lines, dotted lines, and dashed lines indicate regression lines of septal wall data, lateral wall data, and anteroapical inferior (Ant, Ap, Inf) wall data, respectively.

phy, echocardiography, and MRI, WM is usually measured on the basis of excursion of a particular endocardial area relative to a fixed reference point and not to the ventricular center. Therefore, one should remember that systolic anteromedial cardiac translation after CABG results in underestimation of septal motion, suggesting that detection of perioperative infarction in the septum is difficult. Furthermore, artifactual overestimation of lateral WM can mask its deterioration after CABG. To date, only postoperative artifactual underestimation of septal motion has been emphasized; little attention has been paid to overestimation of lateral motion. In this study in patients with uncompli-

cated bypass surgery, regional WT did not deteriorate in any segment and correlated well with regional perfusion (percentage of MIBI uptake) both preoperatively and postoperatively. Accordingly, for assessment of regional ventricular function after CABG, WT analysis would be preferable, especially in quantitative analysis. For this purpose, gated myocardial perfusion imaging is suitable because it is more objective and because automated, reproducible quantitative WT analysis is available and provides simultaneous information about myocardial perfusion. Further assessment of WT analysis as a functional parameter is warranted.

CONCLUSION

In patients after bypass surgery, WM analysis by gated myocardial perfusion SPECT underestimates septal motion and overestimates lateral motion because of exaggerated systolic anteromedial cardiac mobility. WT correlated well with percentage of MIBI uptake both before and after bypass surgery. Therefore, WT analysis would be recommended for evaluation of postoperative cardiac function.

REFERENCES

1. Germano G, Kiat H, Kavanagh PB, et al. Automatic quantification of ejection fraction from gated myocardial perfusion SPECT. *J Nucl Med.* 1995;36:2138–2147.
2. Germano G, Erel J, Lewin H, Kavanagh PB, Berman DS. Automatic quantitation of regional myocardial wall motion and thickening from gated technetium-99m sestamibi myocardial perfusion single-photon emission computed tomography. *J Am Coll Cardiol.* 1997;30:1360–1367.
3. Cwajg E, Cwajg J, He ZX, et al. Gated myocardial perfusion tomography for the assessment of left ventricular function and volumes: comparison with echocardiography. *J Nucl Med.* 1999;40:1857–1865.
4. Chua T, Kiat H, Germano G, et al. Gated technetium-99m sestamibi for simultaneous assessment of stress myocardial perfusion, postexercise regional ventricular function and myocardial viability: correlation with echocardiography and rest thallium-201 scintigraphy. *J Am Coll Cardiol.* 1994;23:1107–1114.
5. Nichols K, DePuey EG, Rozanski A. Automation of gated tomographic left ventricular ejection fraction. *J Nucl Cardiol.* 1996;3:475–482.
6. Faber TL, Cooke CD, Folks RD, et al. Left ventricular function and perfusion from gated SPECT perfusion images: an integrated method. *J Nucl Med.* 1999;40:650–659.
7. Cooke CD, Garcia EV, Cullom SJ, Faber TL, Pettigrew RI. Determining the accuracy of calculating systolic wall thickening using a fast Fourier transform approximation: a simulation study based on canine and patient data. *J Nucl Med.* 1994;35:1185–1192.
8. Buda AJ, Zotz RJ, Pace DP, Krause LC. Comparison of two-dimensional echocardiographic wall motion and wall thickening abnormalities in relation to the myocardium at risk. *Am Heart J.* 1986;111:587–592.
9. Chen L, Ma L, de PV, et al. Effects of beta-blockade and atropine on ischemic responses in left ventricular regions subtending coronary stenosis during dobutamine stress echocardiography. *J Am Coll Cardiol.* 1996;28:1866–1876.
10. Hammond HK, McKirnan MD. Effects of dobutamine and arbutamine on regional myocardial function in a porcine model of myocardial ischemia. *J Am Coll Cardiol.* 1994;23:475–482.
11. Baer FM, Smolarz K, Jungehulsing M, et al. Feasibility of high-dose dipyridamole-magnetic resonance imaging for detection of coronary artery disease and comparison with coronary angiography. *Am J Cardiol.* 1992;69:51–56.
12. Corya BC, Rasmussen S, Feigenbaum H, Knoebel SB, Black MJ. Systolic thickening and thinning of the septum and posterior wall in patients with coronary artery disease, congestive cardiomyopathy, and atrial septal defect. *Circulation.* 1977;55:109–114.
13. Sechtem U, Sommerhoff BA, Markiewicz W, et al. Regional left ventricular wall thickening by magnetic resonance imaging: evaluation in normal persons and patients with global and regional dysfunction. *Am J Cardiol.* 1987;59:145–151.
14. Kerber RE, Litchfield R. Postoperative abnormalities of interventricular septal motion: two-dimensional and M-mode echocardiographic correlations. *Am Heart J.* 1982;104:263–268.
15. Righetti A, Crawford MH, O'Rourke RA, et al. Interventricular septal motion and left ventricular function after coronary bypass surgery: evaluation with echocardiography and radionuclide angiography. *Am J Cardiol.* 1977;39:372–377.
16. Waggoner AD, Shah AA, Schuessler JS, et al. Effect of cardiac surgery on ventricular septal motion: assessment by intraoperative echocardiography and cross-sectional two-dimensional echocardiography. *Am Heart J.* 1982;104:1271–1278.
17. Okada RD, Murphy JH, Boucher CA, et al. Relationship between septal perfusion, viability, and motion before and after coronary artery bypass surgery. *Am Heart J.* 1992;124:1190–1195.
18. Voci P, Bilotta F, Aronson S, et al. Echocardiographic analysis of dysfunctional and normal myocardial segments before and immediately after coronary artery bypass graft surgery. *Anesth Analg.* 1992;75:213–218.
19. Tadamura E, Kudoh T, Motooka M, et al. Use of technetium-99m sestamibi ECG-gated single-photon emission tomography for the evaluation of left ventricular function following coronary artery bypass graft: comparison with three-dimensional magnetic resonance imaging. *Eur J Nucl Med.* 1999;26:705–712.
20. Germano G, Kavanagh PB, Kavanagh JT, et al. Repeatability of automatic left ventricular cavity volume measurements from myocardial perfusion SPECT. *J Nucl Cardiol.* 1998;5:477–483.
21. Kubo S, Tadamura E, Kudoh T, et al. Assessment of the effect of revascularization early after CABG using ECG-gated perfusion single-photon emission tomography. *Eur J Nucl Med.* 2001;28:230–239.
22. Ghods M, Panchoy S, Cave V, Cassell D, Heo J, Iskandrian AS. Serial changes in left ventricular function after coronary artery bypass: implications in viability assessment. *Am Heart J.* 1995;129:20–23.
23. Ribeiro P, Nihoyannopoulos P, Farah S, et al. Role of transient ischaemia and perioperative myocardial infarction in the genesis of new septal wall motion abnormalities after coronary bypass surgery. *Br Heart J.* 1985;54:140–144.
24. Lehmann KG, Lee FA, McKenzie WB, et al. Onset of altered interventricular septal motion during cardiac surgery: assessment by continuous intraoperative transesophageal echocardiography. *Circulation.* 1990;82:1325–1334.

