
Low-Dose Dobutamine Electrocardiograph-Gated Myocardial SPECT for Identifying Viable Myocardium: Comparison with Dobutamine Stress Echocardiography and PET

Keiichiro Yoshinaga, Koichi Morita, Satoshi Yamada, Kaoru Komuro, Chietsugu Katoh, Yoshinori Ito, Yuji Kuge, Tetsuro Kohya, Akira Kitabatake, and Nagara Tamaki

Departments of Nuclear Medicine, Cardiovascular Medicine, and Tracer Kinetics, Hokkaido University School of Medicine, Sapporo, Japan

The identification of severely dysfunctional but viable myocardium is of particular importance for the selection of patients with depressed left ventricular function who will benefit from coronary revascularization. Assessment of inotropic reserve with dobutamine has recently been used for this purpose. This study compared the accuracy of low-dose dobutamine stress gated myocardial SPECT (DS SPECT) with the accuracy of dobutamine stress echocardiography (DSE) and resting perfusion SPECT for the identification of viable myocardium in patients with previous myocardial infarction. **Methods:** Resting and low-dose dobutamine (7.5 $\mu\text{g}/\text{kg}/\text{min}$) gated $^{99\text{m}}\text{Tc}$ -tetrofosmin SPECT and echocardiography and resting ^{18}F -FDG PET were prospectively studied in 23 patients with previous myocardial infarction and severely depressed regional function. Twenty-one of them were successfully studied with each technique. The left ventricular wall was divided into 14 segments to assess wall motion using a 5-point scale. PET viability was defined as FDG uptake $\geq 50\%$ of the maximum uptake in a region with normal wall motion. For DS SPECT and DSE studies, viable myocardium was defined as hypokinetic areas with ≥ 1 point improvement in wall motion. For resting perfusion SPECT, viable myocardium was defined as hypokinetic areas with a relative uptake $\geq 50\%$ of the maximum uptake. **Results:** Of a total of 294 segments, 55 had severe resting dyskinesia. Thirty-four segments were identified as viable on FDG PET, and 21 segments were identified as nonviable. Eleven segments were inadequately visualized with DSE, including 5 segments in the apex. Sensitivities (78% vs. 76%) and specificities (94% vs. 100%) were similar for DSE and DS SPECT, with a concordance of 86% ($\kappa = 0.72$). DS SPECT and perfusion SPECT did not significantly differ with respect to sensitivities (76% vs. 85%, respectively). However, specificity was significantly higher for DS SPECT than for perfusion SPECT (100% vs. 52%, respectively, $P < 0.05$). **Conclusion:** This study indicated that DS SPECT correlates well with DSE in the assessment of viability. In addition, gated SPECT can evaluate regional wall motion, even in areas inadequately assessed by echocardiography. DS

SPECT may also provide additional information for identifying viable myocardium, which is often overestimated by routine perfusion scans.

Key Words: myocardial viability; dobutamine; emission CT echocardiography; FDG

J Nucl Med 2001; 42:838–844

In patients with chronic myocardial infarction and impaired left ventricular function, differentiation of dysfunctional but viable myocardium from irreversibly damaged scar tissue has important clinical implications (1,2). Several imaging techniques that evaluate different aspects of myocardial viability are used to identify viable myocardial regions with severely depressed function (3–5). Among these, PET using ^{18}F -FDG is the accepted gold standard for differentiating viable myocardial tissue from scar tissue (6–9). However, this technique can be used only in centers that have a PET camera.

Low-dose dobutamine echocardiography is widely used to assess the inotropic reserve of severely dysfunctional myocardium (10). It is generally accepted that myocardial regions in which contractile function improves after inotropic stimulation will recover function spontaneously or after coronary revascularization (11). Gated myocardial SPECT has been widely used for the simultaneous assessment of perfusion and function. In addition, gated myocardial SPECT permits objective assessment of regional function. Everaert et al. (12) reported that low-dose dobutamine gated SPECT agreed well with dobutamine stress echocardiography (DSE) for the identification of inotropic reserve in infarcted areas. However, those authors did not correlate their findings with other imaging results.

The purpose of this study was to compare the accuracy of low-dose dobutamine stress gated myocardial SPECT (DS SPECT) and resting perfusion SPECT with DSE for the

Received Sep. 20, 2000; revision accepted Feb. 14, 2001.

For correspondence or reprints contact: Nagara Tamaki, MD, Department of Nuclear Medicine, Hokkaido University School of Medicine, Kita-Ku, Kita 15 Nishi 7, Sapporo, 060-8638, Japan.

TABLE 1
Clinical Characteristics of the 21 Patients

Patient no.	Age (y)	Sex	Myocardial infarction	Coronary stenosis	Ejection fraction (%)
1	64	M	Inferior	RCA	45
2	74	M	Inferior	RCA, LAD	68
3	66	M	Anteroseptal	RCA, LAD	38
4	64	M	Inferior	RCA, LAD, LCX	27
5	60	M	Anterior	LAD	47
6	70	M	Inferior	RCA	49
7	66	F	Anterior	LAD	24
8	74	M	Inferior	RCA	47
9	67	M	Anterior	LAD	54
10	70	M	Ischemic cardiomyopathy	RCA, LAD, LCX	43
11	59	M	Inferior	RCA, LAD, LCX	34
12	74	M	Inferior	RCA, LAD	55
13	47	F	Inferior	RCA, LAD	49
14	74	M	Inferior	RCA, LAD, LCX	64
15	65	M	Anterior	LAD, LCX	57
16	66	M	Anterior	LAD	44
17	73	F	Inferior	RCA, LAD, LCX	67
18	72	F	Anteroseptal, inferior	RCA, LAD	44
19	49	M	Inferior	RCA	39
20	67	M	Anteroseptal, inferior	RCA, LAD	48
21	76	F	Anteroseptal	RCA, LAD, LCX	60

RCA = right coronary artery; LAD = left anterior descending coronary artery; LCX = left circumflex coronary artery.

identification of viable myocardium in patients with previous myocardial infarction.

MATERIALS AND METHODS

Study Patients

Twenty-three sequential patients with previous myocardial infarction were prospectively studied from August 1999 to July 2000 (18 men, 5 women; mean age \pm SD, 66.5 \pm 7.8 y). These patients met the following criteria: the presence of a Q wave infarction caused by total or subtotal occlusion of a coronary artery, the presence of asynergy (severe hypokinesis, akinesis, or dyskinesis) on resting echocardiography, the presence of a normal sinus rhythm, and no concomitant cardiopulmonary or severe valvular diseases or evidence of left ventricular aneurysm. Two patients (8.7%) were excluded from the final evaluation, one patient because of inadequate FDG uptake caused by severe diabetes, and the other because of the development of paroxysmal atrial fibrillation during DSE. Table 1 summarizes the clinical characteristics of the 21 patients. Mean left ventricular ejection fraction was 47.8% \pm 11.3% as determined by quantitative gated SPECT images using the fully automatic algorithm developed at Cedars-Sinai Medical Center (Los Angeles, CA) (13). β -adrenergic blocking agents were withdrawn 48 h before the study. The study was approved by the ethics committee of Hokkaido University Hospital. Written informed consent was obtained from each patient.

SPECT Protocol

Perfusion imaging was performed with a 1-d protocol after either maximal treadmill exercise using the Bruce protocol ($n = 8$) or pharmacologic vasodilation ($n = 9$). The remaining 4 patients underwent only resting perfusion imaging. Two of these 4 patients

took an additional exercise stress test, which had positive findings for one patient, who underwent revascularization, and negative findings for the other patient, who did not undergo revascularization. Patients who underwent exercise treadmill testing received 300 MBq ^{99m}Tc -tetrofosmin (Nihon Mediphysics, Hyougo, Japan) at peak exercise and exercised at the same level for an additional minute. Stress imaging was performed 30 min after injection. Patients undergoing pharmacologic testing received an infusion of 0.16 mg/kg/min of adenosine triphosphate for 5 min. Three minutes after completion of the infusion, 300 MBq tetrofosmin were injected. The stress imaging did not use dobutamine studies. Five hours later, 600 MBq tetrofosmin were injected at rest, and imaging was performed 30 min later. After the resting images were obtained, dobutamine stress electrocardiograph- (ECG-) gated acquisition was performed. Uptake was sufficient in almost all segments to perform wall motion analysis, and no difference was observed between resting and dobutamine studies. One patient showed severe reduction of regional uptake. The SPECT window levels were changed for the analysis in this patient.

SPECT Acquisition and Processing

SPECT images were acquired using a rotating dual-detector gamma camera with the detectors mounted at right angles and fitted with high-resolution collimators (VXHR, Vertex; ADAC Laboratories, Milpitas, CA). The image acquisition variables included a 140-keV photopeak with a 20% window, 64 projections at 40 s per projection over a 180° (90° per detector) elliptic orbit, a 38-cm roving detector mask, and a matrix size of 64 \times 64. Acquisitions were gated for 8 frames per cardiac cycle, with 100% beat acceptance.

The 8-interval projection datasets were prefiltered with a 2-dimensional Butterworth filter (order, 2.5; critical frequency, 0.22 cycles per pixel; pixel size, 0.64 cm) and reconstructed with filtered backprojection (ramp filter) and no attenuation correction. The resulting transaxial image sets were reoriented into short-axis sets that were then processed in batch mode using a stand-alone workstation (Sun Microsystems, Palo Alto, CA) running software to automatically quantify left ventricular ejection fraction.

The projection datasets were also summed and were prefiltered with a 2-dimensional Butterworth filter (order, 2.5; critical frequency, 0.33 cycles per pixel; pixel size, 0.64 cm), producing high-count short, vertical, and horizontal long-axis images for qualitative interpretation and for polar plot and circumferential count displays.

DS SPECT

A low-dose, graded infusion of dobutamine was administered intravenously at a starting dose of 5 $\mu\text{g}/\text{kg}/\text{min}$ and increased by 2.5 $\mu\text{g}/\text{kg}/\text{min}$ at 3-min intervals. ECG-gated SPECT was then performed during the dobutamine infusion at a dose of 7.5 $\mu\text{g}/\text{kg}/\text{min}$. The patients underwent continuous ECG monitoring, and blood pressure was recorded at 1-min intervals using an automated cuff.

SPECT Image Interpretation

For the analysis of wall motion, the left ventricle was divided into 14 segments (Fig. 1). These segments included the anterior, septal, inferior, posterior, anterolateral, and lateral walls, each subdivided into a basal and mid portion, and the anterior apex and inferior apex. Endocardial wall motion was assessed visually and quantified using a 4-point scoring system as follows: 1 = normal, 2 = mild hypokinesia, 3 = severe hypokinesia, and 4 = akinesia. Viable myocardium was defined as hypokinetic areas with a ≥ 1 point improvement in the score.

The gated image sets were read independently by 2 expert observers who were unaware of patient identity and the results of DSE. Interobserver concordance was 94% before discrepancies were resolved by consensus. One observer reviewed the studies twice, at least 2 wk apart, with an intraobserver concordance of 96%.

$^{99\text{m}}\text{Tc}$ -Tetrofosmin Image Analysis

For the quantitative analysis of regional tracer uptake, the individual frames of raw projection data were summed to reconstruct nongated tomograms. Tracer uptake in the summed images was calculated using an automated circumferential profile analysis

and expressed as a percentage of the maximum uptake. For resting perfusion SPECT, viable myocardium was defined as hypokinetic areas with a relative tracer uptake $> 50\%$ of the maximum uptake.

Echocardiography Protocol

Dobutamine echocardiography was performed using a standard protocol. First, resting echocardiography was performed with the patient lying in the left lateral recumbent position. Echocardiographic imaging was then performed during the intravenous infusion of dobutamine, starting at a dose of 5 $\mu\text{g}/\text{kg}/\text{min}$, which was increased every 3 min to 7.5, 10, 20, 30, and 40 $\mu\text{g}/\text{kg}/\text{min}$. Images were obtained in the standard parasternal long-axis and short-axis views, with particular attention to determining regional function. During dobutamine infusion, the 12-lead ECG and blood pressure were monitored every minute. The test was ended prematurely if the heart rate reached 85% of the predicted maximum or if any of the following developed: severe angina, a systolic blood pressure < 85 or > 220 mm Hg, ≥ 2 mm of ST depression, or significant arrhythmia (≥ 6 beats of supraventricular tachycardia or ≥ 3 beats of ventricular tachycardia). All studies were performed on a Sonos 1500 ultrasound system (Agilent Technologies, Palo Alto, CA) equipped with a 2.5-MHz transducer.

Echocardiographic Image Processing and Analysis

For the analysis of wall motion, the left ventricle was divided into 14 segments as described for the SPECT study. The basal and middle thirds were divided into 6 segments for the short-axis image. Apical 2-chamber views and vertical long-axis views showed the apical segments, which were divided into 2 segments (Fig. 1). Wall motion was assessed visually, using both endocardial motion and wall thickening, and was quantified using a 5-point scoring system as follows: 1 = normal, 2 = mild hypokinesia, 3 = severe hypokinesia, 4 = akinesia, and 5 = dyskinesia. Viable myocardium was defined as hypokinetic areas with ≥ 1 point improvement in the wall motion score.

The dobutamine echocardiographic studies were interpreted randomly using all 7 digital images for each view displayed on 2 monitors placed side by side to allow simultaneous review of all 7 stages of the test. All studies were read by a single experienced investigator who was unaware of the clinical information, the radionuclide information, and the results of resting echocardiography. A wall motion score was assigned to each of the 14 segments for every stage of the test.

FDG PET

PET was performed using a whole-body scanner (ECAT EXACT HR+; Siemens Medical Systems, Inc., Hoffman Estates, IL/CTI, Knoxville, TN) equipped with $^{68}\text{Ge}/^{68}\text{Ga}$ retractable line sources for transmission scans. Transmission images were obtained using an external ring of ^{68}Ga so that the emission images could be corrected for photon attenuation. The intrinsic resolution was 4.5-mm full width at half maximum. For improved myocardial glucose uptake, each patient received a solution containing 50 g glucose 30 min before the injection of FDG ($n = 5$). If glucose intolerance was apparent, hyperinsulinemic-euglycemic clamping was performed ($n = 16$). Images were corrected for attenuation using coefficients received during a 20-min transmission scan. Thirty minutes after glucose loading, or 1 h after the start of insulin clamping, 555 MBq FDG were injected. Forty minutes later, exogenous myocardial glucose use was determined from a 20-min static scan.

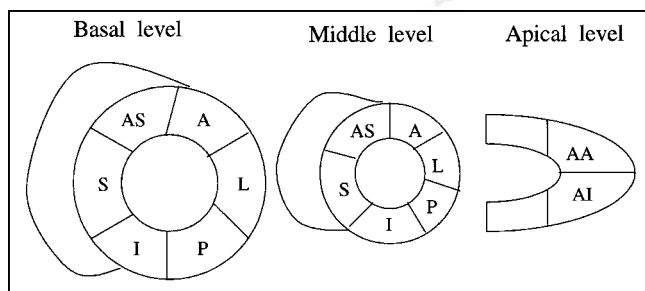


FIGURE 1. Segmental evaluation pattern for DSE, DS SPECT, and FDG positron emission tomograms. A = anterior; AA = anterior apex; AI = inferior apex; AS = anteroseptal; I = inferior; L = lateral; P = posterior; S = septal.

PET Image Analysis

Segmental FDG uptake was assessed quantitatively using 2 short-axis and vertical long-axis tomograms. Viability was defined as a mean segmental FDG uptake $\geq 50\%$ of the maximum uptake.

Statistical Analysis

Data are reported as mean \pm SD. The κ statistic was used to evaluate concordance among DS SPECT, DSE, and perfusion SPECT. Frequencies were compared using χ^2 analysis or the Fisher exact test. $P < 0.05$ was considered statistically significant.

RESULTS

No patients experienced chest pain or significant ST depression during DS SPECT or low-dose DSE.

All segments in the wall motion analysis could be assessed using DS SPECT. In contrast, 11 segments, including 5 apical segments, could not be well visualized by DSE. Of the 294 segments analyzed, 55 had severe resting dys-synergy (echocardiographic score ≥ 3). Thirty-four of these segments were identified as viable (Fig. 2) on the basis of FDG PET analysis, and 21 segments were identified as nonviable (Fig. 3). No segments with wall motion abnormality were considered nonviable at a dobutamine dose of $7.5 \mu\text{g}/\text{kg}/\text{min}$ but viable at doses $> 7.5 \mu\text{g}/\text{kg}/\text{min}$.

No significant differences were observed between DSE and DS SPECT with respect to the sensitivity, specificity, positive predictive value, and negative predictive value for the detection of dysfunctional but viable myocardium (Table 2). In the dysfunctional segments, the rate of concordance for detecting viability between DS SPECT and DSE was 86% ($\kappa = 0.72$; Table 3).

DS SPECT and perfusion SPECT at rest did not significantly differ in sensitivity and negative predictive value for

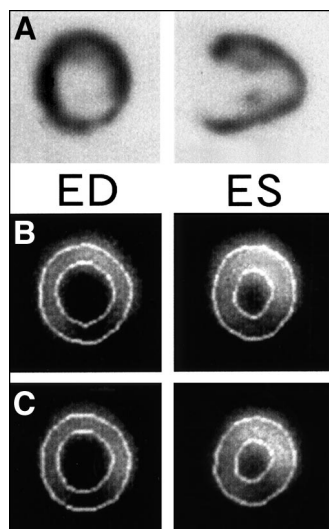


FIGURE 2. Representative images from 70-y-old man with inferior myocardial infarction. (A) Inferior segment was considered viable on basis of FDG PET findings. (B) Inferior segment had severe hypokinesia in resting gated SPECT image. (C) Dobutamine stress improved wall motion abnormality. ED = end-diastole; ES = end-systole.

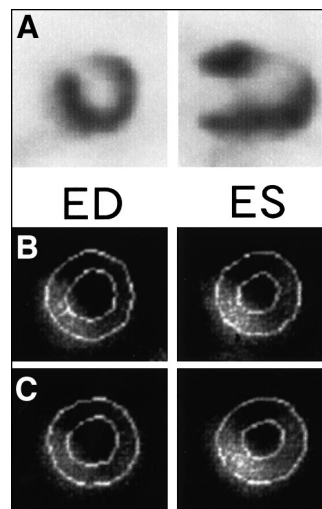


FIGURE 3. Representative images from 72-y-old woman with anteroseptal myocardial infarction. (A) Anteroseptal segment was considered not viable on basis of FDG PET findings. (B) Anteroseptal segment showed severe hypokinesia on resting gated SPECT image. (C) No improvement in wall motion was observed during dobutamine infusion. ED = end-diastole; ES = end-systole.

detecting dysfunctional but viable myocardium. However, DS SPECT had a significantly higher specificity ($P < 0.05$) and positive predictive value ($P < 0.01$) than did perfusion SPECT at rest (Table 3). In dysfunctional segments, the rates of concordance for detecting viability between DS SPECT and perfusion SPECT at rest was only 65% ($\kappa = 0.32$; Table 4).

DISCUSSION

The data indicate that DS SPECT correlates well with DSE in the assessment of viability. Because objective assessment of regional function is available with SPECT, gated SPECT can be used to evaluate regional wall motion, even in areas inadequately assessed by echocardiography. In addition, in the identification of viable myocardium, DS SPECT may provide information that is lacking from routine resting perfusion scans.

Gated SPECT has been used for the objective assessment of left ventricular function (13,14). We have applied gated SPECT to the assessment of regional function under low-dose dobutamine infusion. Our study showed that the results of DS SPECT correlated well with those of DSE. This finding is in keeping with the previous report showing good agreement between DS SPECT and DSE in the identification of inotropic reserve in infarcted areas (12). However, the previous study did not compare these results with other measures of viability, such as PET measurements of viability or functional recovery (10). To the best of our knowledge, our study is the first to compare the 2 methods with FDG PET.

Low-dose dobutamine echocardiography has been used as an effective method for evaluating myocardial viability.

TABLE 2
Diagnostic Accuracy of Viability Assessment by Each Method

Method	Sensitivity	Specificity	PPV	NPV
DS SPECT	76% (26/34)	100% (21/21)	100% (26/26)	72% (21/29)
DSE	78% (25/32)	94% (17/18)	96% (25/26)	70% (17/24)
Rest SPECT	85% (29/34)	52% (11/21)*	74% (29/39) [†]	69% (11/16)

* $P < 0.05$ vs. DS SPECT.

[†] $P < 0.01$ vs. DS SPECT.

PPV = positive predictive value; NPV = negative predictive value.

Previous studies of low-dose dobutamine echocardiography have predicted the recovery of regional function after revascularization with sensitivities ranging from 74% to 92% and specificities ranging from 74% to 96% (5,15–18). Recent studies comparing nuclear methods with DSE and regional wall motion after revascularization confirmed the high sensitivity and high negative predictive value of PET and thallium SPECT imaging. In contrast, DSE was found to be slightly less sensitive but more specific for predicting functional improvement (19).

The sensitivities determined in this study (DSE, 78%; DS SPECT, 76%) agree with previous data. The specificities determined in this study (DSE, 96%; DS SPECT, 100%) are also in keeping with previous data. Therefore, DS SPECT is relatively sensitive and highly specific in predicting functional recovery.

DS SPECT and DSE

In this study, 11 of 294 segments (3.7%) could not be adequately assessed by DSE. Five of them were in the apex. Previous studies have shown that 0%–10% of segments are inadequately assessed by DSE (5,15,19–21). Sawada et al. (22) reported that 10% of segments cannot be assessed. In our study, the percentage of segments with inadequate assessment was slightly higher, probably because of the relatively greater age of our population (mean age, 67 y). The echocardiographic analysis was complicated by the presence of chronic obstructive pulmonary disease and other factors. Therefore, in patients whose regional wall motion cannot be assessed by DSE, DS SPECT can be used to evaluate myocardial viability.

Comparison with Perfusion Imaging

Myocardial uptake of ^{99m}Tc-labeled perfusion agents can be used to identify reversible ischemic myocardium (18,19,23). Uptake and retention of ^{99m}Tc depends on cell membrane integrity and mitochondrial function and therefore reflects cellular viability. Recent studies indicated that, on the basis of a relative uptake $\geq 50\%$ of the normal value defining viability (23), ^{99m}Tc had high sensitivity but relatively low specificity for identifying viable tissue (15,24–26). Our findings agree with these previous data. In our study, the specificity and positive predictive value of DS SPECT were significantly higher than the values for resting perfusion SPECT. Therefore, in the identification of viable myocardium, DS SPECT may provide information in addition to that provided by routine perfusion scans.

Study Limitation

Assessing regional function in patients with a large and severe perfusion defect is somewhat difficult. Manrique et al. (27) reported underestimation of left ventricular ejection fraction by gated SPECT in patients with perfusion defects. However, Germano (28) and Stollfuss et al. (29) found that large perfusion defects had no significant effect on estimation of left ventricular ejection fraction. In our study, no patients had large perfusion defects, which may cause errors in defining myocardial walls.

We used FDG PET as the gold standard for detecting myocardial viability. However, we did not assess the reversibility of regional wall motion abnormalities or global dysfunction, although this reversibility is considered an accurate indicator of myocardial viability.

TABLE 3
Viability Findings Based on DS SPECT and DSE

DSE	DS SPECT		Total
	Viable	Nonviable	
Viable	22	3	25
Nonviable	4	21	25
Total	26	24	50

Concordance rate = 86%; $\kappa = 0.72$.

TABLE 4
Viability Findings Based on DS SPECT and Rest SPECT

Rest SPECT	DS SPECT		Total
	Viable	Nonviable	
Viable	23	16	39
Nonviable	3	13	16
Total	26	29	55

Concordance rate = 65%; $\kappa = 0.32$.

Germano et al. (30) reported that quantitative gated SPECT (QGS) software (Cedars-Sinai) can be used to assess regional ventricular function quantitatively. However, evaluation of wall motion in the abnormal area is difficult. In this study, we also used automated algorithms for the assessment of changes in regional wall thickening but could not separate viable from nonviable segments. The QGS software divided left ventricular segments automatically. If the areas of asynergy are small, the automatically separated segments can include both normal and abnormal areas and thereby underestimate wall motion abnormalities.

The analytic correlation among echocardiographic segments, SPECT and PET segments, anatomy, and vascular territories is not known precisely. However, we used the same 14-segment model for 3 modalities, thereby reducing misalignment between these modalities.

In SPECT, image quality may deteriorate with gut activity; however, no overlapping gut activity occurred in this study. DS SPECT required a long acquisition time. Shortening of acquisition time is needed for further studies.

Echo data analysis used all the images from stress echocardiography (5–40 $\mu\text{g}/\text{kg}/\text{min}$), whereas DS SPECT used only the 7.5 $\mu\text{g}/\text{kg}/\text{min}$ image. Afridi et al. (5) reported that the optimal dose of dobutamine in the detection of myocardial hibernation was 7.5 $\mu\text{g}/\text{kg}/\text{min}$. In our study, we evaluated wall motion on DS SPECT at a 7.5 $\mu\text{g}/\text{kg}/\text{min}$ dose of dobutamine.

Some of our patients had relatively preserved global left ventricular function. However, these patients had regionally severe left ventricular dysfunction. Differentiation of viable myocardium is also relevant in these patients, who need revascularization to improve their prognosis and lower the risk of cardiac events. The current data provide useful information for clinical decision making. Larger numbers of patients with severely depressed left ventricular function are needed to further validate this method.

Clinical Implications

FDG PET, although considered the most reliable method for determining viability, is not widely available. In addition, applying FDG PET to diabetic and glucose-intolerant patients poses difficulties. These patients may require euglycemic–hyperinsulinemic clamping to assess viability using FDG PET (31).

The echocardiographic approaches are attractive from both an acquisition time and an economic point of view. However, echocardiography could not adequately assess many obese or elderly patients in this study. Image quality had a significant effect on the assessment of regional wall motion (20). Recently, the percentage of obese and elderly individuals with lung disease has increased among patients with ischemic heart disease. On the other hand, DS SPECT can be performed on almost every patient irrespective of body size or age. In addition, objective assessment of regional function is feasible in any location. Therefore, DS

SPECT may be a valuable method for assessing myocardial viability.

CONCLUSION

DS SPECT correlated well with DSE in the detection of viable myocardium. In addition, gated SPECT could evaluate regional wall motion, even in areas inadequately assessed by echocardiography. In the identification of viable myocardium, dobutamine gated SPECT may provide information that is often missed by routine perfusion scans.

REFERENCES

1. Gould KL. Myocardial viability: what does it mean and how to measure it? *Circulation*. 1991;83:333–335.
2. Wijns W, Vatner SF, Camici P. Hibernating myocardium. *N Engl J Med*. 1998;339:173–181.
3. Braunwald E, Rutherford JD. Reversible ischemic left ventricular dysfunction: evidence for the “hibernating myocardium.” *J Am Coll Cardiol*. 1986;8:1467–1470.
4. Baer FM, Voth E, Schneider CA, et al. Dobutamine-gradient echo MRI: a functional and morphologic approach to the detection of residual myocardial viability. *Circulation*. 1995;91:1006–1015.
5. Afridi I, Kleiman NS, Raizner AE, Zoghbi WA. Dobutamine echocardiography in myocardial hibernation: optimal dose and accuracy in predicting recovery of ventricular function after coronary angiography. *Circulation*. 1995;91:663–670.
6. Schelbert HR. Positron emission tomography for the assessment of myocardial viability. *Circulation*. 1991;84(suppl 1):I122–I131.
7. Tamaki N, Yonekura Y, Yamasita K, et al. Positron emission tomography using fluorine-18-deoxyglucose in evaluation of coronary artery bypass grafting. *Am J Cardiol*. 1989;64:860–865.
8. Bonow RO, Dilsizian V, Cuocolo A, Bacharach SL. Identification of viable myocardium in patients with chronic coronary artery disease and left ventricular dysfunction: comparison of thallium scintigraphy with reinjection and PET imaging with ^{18}F -fluorinedeoxyglucose. *Circulation*. 1991;83:26–37.
9. Baer FM, Voth E, Deutsch HJ, et al. Predictive value of low-dose dobutamine transesophageal echocardiography and ^{18}F -fluorinedeoxyglucose positron emission tomography for recovery of regional left ventricular function after successful revascularization. *J Am Coll Cardiol*. 1996;28:60–69.
10. Smart SC, Sawada S, Ryan T, et al. Low dose dobutamine echocardiography detects reversible dysfunction after thrombolytic therapy of acute myocardial infarction. *Circulation*. 1993;88:405–415.
11. Qureshi U, Nagueh SF, Afridi I, et al. Dobutamine echocardiography and quantitative rest-redistribution ^{201}Tl tomography in myocardial hibernation: relation of contractile reserve to ^{201}Tl uptake and comparative prediction of recovery of function. *Circulation*. 1997;95:626–635.
12. Everaert H, Vanhove C, Franken P. Low-dose dobutamine gated single-photon emission tomography: comparison with stress echocardiography. *Eur J Nucl Med*. 2000;27:413–418.
13. Germano G, Kiat H, Kavanagh PB, et al. Automatic quantification of ejection fraction from gated myocardial perfusion SPECT. *J Nucl Med*. 1995;36:2138–2147.
14. Berman D, Germano G, Lewin H, et al. Comparison of post-stress ejection fraction and relative left ventricular volumes by automatic analysis of gated myocardial perfusion single-photon emission computed tomography acquired in the supine and prone positions. *J Nucl Cardiol*. 1998;5:40–47.
15. Baumgartner H, Porenta G, Lau YK, et al. Assessment of myocardial viability by dobutamine echocardiography, positron emission tomography and thallium-201 SPECT: correlation with histopathology in explanted hearts. *J Am Coll Cardiol*. 1998;32:1701–1708.
16. Anese M, Cornel JH, Salustri A, et al. Prediction of improvement of regional left ventricular function after surgical revascularization: a comparison of low-dose dobutamine echocardiography with 201-Tl SPECT. *Circulation*. 1995;91:2748–2752.
17. Vanonerschelde J-LJ, Dhondt A-M, Marwick T, et al. Head-to-head comparison of exercise-redistribution-reinjection thallium single-photon emission computed tomography and low-dose dobutamine echocardiography for prediction of reversibility of chronic left ventricular ischemic dysfunction. *J Am Coll Cardiol*. 1996;28:432–442.
18. Udelson JE, Coleman PS, Metherall J, et al. Predicting recovery of severe regional ventricular function: comparison of resting scintigraphy with ^{201}Tl and $^{99\text{m}}\text{Tc}$ -sestamibi. *Circulation*. 1994;89:2552–2561.

19. Bax JJ, Wijns W, Cornel JH, Visser FC, Boersma E, Fioretti PM. Accuracy of currently available techniques for prediction of functional recovery after revascularization in patients with left ventricular dysfunction due to chronic coronary artery disease: comparison of pooled data. *J Am Coll Cardiol.* 1997;30:1451-1466.
20. Spinelli L, Petretta M, Cuocolo A, et al. Prediction of recovery of left ventricular dysfunction after acute myocardial infarction: comparison between ^{99m}Tc-sestamibi and low-dose dobutamine echocardiography. *J Nucl Med.* 1999;40:1683-1692.
21. Hoffmann R, Lethen H, Marwick T, et al. Analysis of interinstitutional observer agreement in interpretation of dobutamine stress echocardiograms. *J Am Coll Cardiol.* 1996;27:330-336.
22. Sawada S, Elsner G, Segar D, et al. Evaluation of patterns of perfusion and metabolism in dobutamine-responsive myocardium. *J Am Coll Cardiol.* 1997;29:55-61.
23. Matsunari I, Fujino S, Taki J, et al. Quantitative rest technetium-99m tetrofosmin imaging in predicting functional recovery after revascularization: comparison with rest-redistribution thallium-201. *J Am Coll Cardiol.* 1997;29:1226-1233.
24. Marzullo P, Sambucetti G, Parodi O. The role of sestamibi scintigraphy in the radioisotopic assessment of myocardial viability. *J Nucl Med.* 1992;33:1925-1930.
25. Marzullo P, Sambucetti G, Parodi O. Regional concordance and discordance between rest thallium 201 and sestamibi imaging for assessing tissue viability: comparison with postrevascularization functional recovery. *J Nucl Cardiol.* 1995;2:309-316.
26. Gonzalez P, Massardo T, Munoz A. Is the addition of ECG gating to technetium-99 sestamibi SPET of value in the assessment of myocardial viability? *Eur J Nucl Med.* 1996;23:1315-1322.
27. Manrique A, Faraggi M, Vera P, et al. ²⁰¹Tl and ^{99m}Tc-MIBI gated SPECT in patients with large perfusion defects and left ventricular dysfunction: comparison with equilibrium radionuclide angiography. *J Nucl Med.* 1999;40:805-809.
28. Germano G. On the accuracy and reproducibility of quantitative gated myocardial perfusion SPECT. *J Nucl Med.* 1999;40:810-813.
29. Stollfuss J, Haas F, Matsunari, et al. Regional myocardial wall thickening and global ejection fraction in patients with low angiographic left ventricular ejection fraction assessed by visual and quantitative resting ECG-gated ^{99m}Tc-tetrofosmin single-photon emission tomography and magnetic resonance imaging. *Eur J Nucl Med.* 1998;25:522-530.
30. Germano G, Erel J, Lewin H, Kavanagh P, Berman D. Automatic quantitation of regional myocardial wall motion and thickening from gated technetium-99m sestamibi myocardial perfusion single-photon emission computed tomography. *J Am Coll Cardiol.* 1997;30:1360-1367.
31. Knutti MJ, Nuutila P, Saraste R, et al. Euglycemic hyperinsulinemic clamp and oral glucose load in stimulating myocardial glucose utilization during positron emission tomography. *J Nucl Med.* 1992;33:1255-1262.

