

3. Buchsbaum D, Khazaeli MB, Liu T, et al. Fractionated radioimmunotherapy of human colon carcinoma xenografts with ¹³¹I-labeled monoclonal antibody CC49. *Cancer Res* 1995;55:5881s-5887s.
4. Weber DA, Eckerman KF, Dillman LT, Ryman JC, eds. In: *MIRD: radionuclide data and decay schemes*. Society of Nuclear Medicine, New York; 1989.
5. Kaminski MS, Zasadny KR, Francis IR, et al. Radioimmunotherapy of B-cell lymphoma with [¹³¹I]anti-B1 (anti-CD20) antibody. *N Engl J Med* 1993;329:459-465.
6. Press OW, Eary JF, Appelbaum FR, et al. Radiolabeled-antibody therapy of B-cell lymphoma with autologous bone marrow support. *N Engl J Med* 1993;329:1219-1224.
7. Welt S, Divgi CR, Kemeny N, et al. Phase I/II study of iodine-131-labeled monoclonal antibody A33 in patients with advanced colon cancer. *J Clin Oncol* 1994;12:1561-1571.
8. Divgi CR, Scott AM, Dantis L, et al. Phase I radioimmunotherapy trial with I-131 CC49 in metastatic colon carcinoma. *J Nucl Med* 1995;36:586-592.
9. Welt S, Scott AM, Divgi CR, et al. Phase I/II study of iodine-125-labeled monoclonal antibody A33 in patients with advanced colon cancer. *J Clin Oncol* 1996;14:1787-1797.
10. Alvarez RD, Partridge EE, Khazaeli MB, et al. Intraperitoneal radioimmunotherapy of ovarian cancer with ¹⁷⁷Lu-CC49: a phase I/II study. *Gynecol Oncol* 1997;65:94-101.
11. Mulligan T, Carrasquillo JA, Chung Y, et al. Phase I study of intravenous ¹⁷⁷Lu-labeled CC49 murine monoclonal antibody in patients with advanced adenocarcinoma. *Clin Cancer Res* 1995;1:1447-1454.
12. Tempero M, Lechner P, Dalrymple G, et al. High-dose therapy with iodine-131-labeled monoclonal antibody CC49 in patients with gastrointestinal cancers: a Phase I trial. *J Clin Oncol* 1997;15:1518-1528.
13. Riethmuller G, Schneider-Gadicke E, Schlimok G, et al. Randomised trial of monoclonal antibody for adjuvant therapy of resected Dukes' C colorectal carcinoma. German Cancer Aid 17-1A Study Group. *Lancet* 1994;343:1177-1183.
14. Gottlinger HG, Funke I, Johnson JP, et al. The epithelial cell surface antigen 17-1A, a target for antibody-mediated tumor therapy: its biochemical nature, tissue distribution and recognition by different monoclonal antibodies. *Int J Cancer* 1986;38:47-53.
15. Hird V, Maraveyas A, Snook D, et al. Adjuvant therapy of ovarian cancer with radioactive monoclonal antibody. *Br J Cancer* Rockville, MD: 1993;68:403-406.
16. *Federal Guide #8.39*. Rockville, MD: Nuclear Regulatory Commission; April 1997.
17. Weiden PL, Breitz HB, Seiler CA, et al. Rhenium-186-labeled chimeric antibody NR-LU-13: pharmacokinetics, biodistribution and immunogenicity relative to murine analog NR-LU-10. *J Nucl Med* 1993;34:2111-2119.
18. Rosch F, Herzog H, Plag C, et al. Radiation doses of yttrium-90 citrate and yttrium-90 EDTMP as determined via analogous yttrium-86 complexes and positron emission tomography. *Eur J Nucl Med* 1996;23:958-966.
19. Shen S, DeNardo GL, DeNardo SJ, et al. Dosimetric evaluation of copper-64 in copper-67-2IT-BAT-Lym-1 for radioimmunotherapy. *J Nucl Med* 1996;37:146-150.
20. Humm JL, Cobb LM. Nonuniformity of tumor dose in radioimmunotherapy. *J Nucl Med* 1990;31:75-83.
21. O'Donoghue JA, Bardies M, Wheldon TE. Relationships between tumor size and curability for uniformly targeted therapy with beta-emitting radionuclides. *J Nucl Med* 1995;36:1902-1909.
22. Stoldt HS, Aftab F, Chinol M, et al. Pretargeting strategies for radio-immunoguided tumour localisation and therapy. *Eur J Cancer* 1997;33:186-192.
23. Abrams P, Breitz H, Axworthy D, et al. Phase I clinical evaluation of pretargeted ⁹⁰Y radioimmunotherapy [Abstract]. *Proc Annu Meet Am Soc Clin Oncol* 1995;14:A1348.
24. Chatal JF, Le Doussal JM, Chetanneau A, et al. Pretargeting of colorectal and medullary thyroid carcinomas with bispecific immunoconjugates [Abstract]. *Diagnostic and therapeutic applications in benign and malignant disorders*. Fourth annual symposium: current status and future directions of immunoconjugates. Key Biscayne, FL; 1992:56.
25. Wilbur DS, Hamlin DK, Vessella RL, et al. Antibody fragments in tumor pretargeting. Evaluation of biotinylated Fab' colocalization with recombinant streptavidin and avidin. *Bioconjug Chem* 1996;7:689-702.
26. Billette R, Lobuglio AF. Chimeric antibodies. *Int Rev Immunol* 1993;10:165-176.
27. Caron PC, Schwartz MA, Co MS, et al. Murine and humanized constructs of monoclonal antibody M195 (anti-CD33) for therapy of acute myelogenous leukemia. *Cancer* 1994;73:1049-1056.
28. Milenic DE, Yokota T, Filipula DR, et al. Construction, binding properties, metabolism, and tumor targeting of a single-chain Fv derived from the pancreatic carcinoma monoclonal antibody CC49. *Cancer Res* 1991;51:6363-6371.
29. Benhar I, Pastan I. Characterization of B1(Fv)PE38 and B1(dsFv)PE38: single-chain and disulfide-stabilized Fv immunotoxins with increased activity that cause complete remissions of established human carcinoma xenografts in nude mice. *Clin Cancer Res* 1995;1:1023-1029.
30. Kobayashi H, Yoo TM, Drumm D, et al. Improved biodistribution of ¹²⁵I-labeled anti-Tac disulfide-stabilized Fv fragment by blocking its binding to the alpha subunit of the interleukin 2 receptor in the circulation with preinjected humanized anti-Tac IgG. *Cancer Res* 1997;57:1955-1961.
31. Wu C, Jagoda E, Brechbiel M, et al. Biodistribution and catabolism of Ga-67-labeled anti-Tac dsFv fragment. *Bioconjug Chem* 1997;8:365-369.
32. Kreitman RJ, Mansfield E, Wang Q-C, et al. The activity of disulfide-stabilized recombinant immunotoxin RFB4(dsFv)-PE38 towards human CD22+ lymphoma/leukemia xenografts in mice and fresh cells from patients [Abstract]. *Proc Annu Meet Am Assoc Cancer Res* 1997;38:A187.

Diagnostic Accuracy of Technetium-99m-Pertechnetate Scintigraphy with Lemon Juice Stimulation to Evaluate Warthin's Tumor

Yuji Murata, Ichiro Yamada, Isao Umehara, Norihiko Okada and Hitoshi Shibuya

Department of Radiology, Faculty of Medicine, Tokyo Medical and Dental University, Tokyo; Department of Clinical Laboratory, Faculty of Dentistry, Tokyo Medical and Dental University, Tokyo, Japan

This study investigated the diagnostic accuracy of ^{99m}Tc-pertechnetate scintigraphy with lemon juice stimulation for evaluating parotid gland Warthin's tumor. **Methods:** Technetium-99m-pertechnetate scintigraphy with intraoral lemon juice stimulation was used to evaluate a total of 68 parotid gland lesions clinically suspected of being Warthin's tumor in 62 patients. Twenty-three of the 68 lesions were subsequently histologically confirmed to be Warthin's tumor, whereas the remaining 45 lesions were histologically diagnosed as being other lesions. **Results:** Technetium-99m-pertechnetate scintigraphy with lemon juice stimulation correctly diagnosed 18 of 23 Warthin's tumors as being Warthin's tumor but was unable to diagnose the other five Warthin's tumors. Further, scintigraphy correctly diagnosed 41 of 45 non-Warthin's tumors as being non-

Warthin's tumor but misdiagnosed other four non-Warthin's tumors as Warthin's tumor. Thus, the sensitivity of scintigraphy for diagnosing Warthin's tumor was found to be 78%, its specificity 91% and its accuracy 87%. On the basis of prestimulation images alone, however, the sensitivity was estimated to be 65%, its specificity 93% and its accuracy 84%. **Conclusion:** For evaluating Warthin's tumor, the sensitivity of ^{99m}Tc-pertechnetate scintigraphy was relatively low, although the specificity was sufficiently high. Lemon juice stimulation improved the sensitivity markedly but decreased the specificity slightly. Thus, ^{99m}Tc-pertechnetate scintigraphy with lemon juice stimulation should be carefully performed for diagnosis of Warthin's tumor.

Key Words: Warthin's tumor; parotid gland; neoplasms; technetium-99m-pertechnetate; lemon juice stimulation

J Nucl Med 1998; 39:43-46

Received Jan. 3, 1997; accepted Apr. 8, 1997.

For correspondence or reprints contact: Yuji Murata, MD, Department of Radiology, Faculty of Medicine, Tokyo Medical and Dental University, 1-5-45 Yushima, Bunkyo-ku, Tokyo 113, Japan.

Warthin's tumor, which is also known as papillary cystadenoma lymphomatosum, is a common benign parotid tumor that frequently occurs in elderly men. Warthin's tumor is a very slowly growing tumor with no symptoms (1). Furthermore, for elderly patients with non-enlarging Warthin's tumor, surgical removal is not needed. Thus, a definitive diagnosis of Warthin's tumor is important for an appropriate method of patient management.

Technetium-99m-pertechnetate scintigraphy has been used for diagnosing salivary gland tumors (2,3), and intraoral acid administration at this scintigraphy has recently been introduced to stimulate the flow of saliva (4-7). This article discusses the diagnostic accuracy of this scintigraphy with acid administration for evaluation of Warthin's tumor.

We reviewed the results of ^{99m}Tc-pertechnetate scintigraphy with lemon juice stimulation in 62 patients who were suspected of having Warthin's tumor and got histopathologic diagnosis so as to determine the sensitivity and specificity in diagnosing Warthin's tumor and to assess the intraoral lemon juice stimulation method.

MATERIALS AND METHODS

Patients

Sixty-two (35 men, 27 women; age range 25-76 yr; mean age 51 yr) patients who underwent ^{99m}Tc-pertechnetate scintigraphy at our radiology department because they were clinically suspected of having Warthin's tumors were included in this study. Further, 59 patients had one lesion, two patients had two lesions and one patient had five lesions. Thus, a total of 68 lesions were investigated in this series.

All the patients underwent surgery within 1 mo after this scintigraphic study, and all 68 lesions were subsequently diagnosed histopathologically. Among the 68 lesions, 23 lesions were histologically confirmed to be Warthin's tumor. The remaining 45 lesions were histologically diagnosed as being other lesions, including 37 benign and 8 malignant lesions. The pathologic diagnosis of 45 non-Warthin's tumors was as follows: pleomorphic adenoma (n = 28), lymphepithelial lesion (n = 2), basal cell adenoma (n = 1), papillary cystadenoma (n = 1), neurilemmoma (n = 1), fibroxanthomatous lesion (n = 1), fibrous scar (n = 1), chronic inflammatory lesion (n = 1), fatty degeneration (n = 1), adenoid cystic carcinoma (n = 3), adenocarcinoma (n = 1), unclassified carcinoma (n = 1), adenocarcinoma in Warthin's tumor (n = 1), carcinoma in pleomorphic adenoma (n = 1) and malignant lymphoma (n = 1). In addition, the lesion of adenocarcinoma in Warthin's tumor was classified as non-Warthin's tumor in this study.

Imaging Examinations

All 62 patients received 370-555 MBq (10-15 mCi) ^{99m}Tc-pertechnetate. Twenty minutes after an injection of the tracer, anterior and bilateral scans were obtained by a single-head gamma camera equipped with a low-energy, all-purpose, parallel-hole collimator. Subsequently, after an intraoral administration of 1 ml lemon juice, repeated bilateral scans were obtained.

Image Analysis

As shown in Table 1, the scintigraphic findings were classified into four types. Radioactivity was assessed on each image before and after an administration of lemon juice. Type 1 had increased activity before administration and retentive activity after; Type 2 had normal activity before and retentive activity after; Type 3 had normal activity before and no retentive activity after; and Type 4 had decreased activity before and no retentive activity after.

Scintigraphic studies were evaluated with blinded separate interpretations by three independent radiologists. Scintigraphic

TABLE 1
Classification of Findings in Pertechnetate Parotid Gland Scintigraphy

Type	Scintigraphic images	
	Activity on prestimulation images	Retention on poststimulation images
Type 1	Increased	Present
Type 2	Normal	Present
Type 3	Normal	Absent
Type 4	Decreased	Absent

images were interpreted independently without knowledge of the histopathological diagnosis. When the observers did not fully agree, diagnosis was achieved by consensus.

The scintigraphic findings of all 68 lesions were then compared lesion by lesion with the results of the histopathological findings. After routine hematoxylin-eosin staining, all microscopic inspections were performed by one of the authors.

RESULTS

Comparison of Scintigraphic Findings and Pathological Diagnosis

The comparison of the scintigraphic findings and the pathological diagnosis is summarized in Table 2. Out of the 23 Warthin's tumors, scintigraphy revealed 15 lesions to be Type 1 and 3 lesions to be Type 2 (Fig. 1). However, the remaining five Warthin's tumors were Type 3 or Type 4 lesions (Fig. 2).

Among 45 non-Warthin's tumors, 41 non-Warthin's tumors were Type 3 or Type 4 lesions. However, the remaining four lesions were identified as being Type 1 or Type 2 lesions (Fig. 3), and the pathological diagnoses of the four lesions were as follows: pleomorphic adenoma (n = 1), lymphepithelial lesion (n = 1), chronic inflammatory lesion (n = 1) and adenocarcinoma (n = 1).

Diagnostic Accuracy of Scintigraphy with Lemon Juice Stimulation

On the basis of the scintigraphy with lemon juice stimulation, we diagnosed Type 1 and Type 2 lesions as being Warthin's tumors and Type 3 and Type 4 lesions as being non-Warthin's tumors. Thus, the sensitivity of this method for detecting Warthin's tumor was estimated to be 78%, its specificity 91% and its accuracy 87% (Table 3).

Thus, our data demonstrate that the sensitivity of scintigraphy with lemon juice stimulation for diagnosing Warthin's tumor was relatively low although the specificity was sufficiently high.

Diagnostic Accuracy of Prestimulation Images

To assess the lemon juice stimulation method, the sensitivity and specificity of prestimulation images alone were also determined. On the basis of the prestimulation images alone, we diagnosed Type 1 lesions as being Warthin's tumors, and Type 2, Type 3 and Type 4 lesions as being non-Warthin's tumors. Thus, the sensitivity of prestimulation images alone was estimated to be 65%, its specificity 93% and its accuracy 84% (Table 3).

These data demonstrate that the addition of the intraoral lemon juice stimulation improved the sensitivity markedly but decreased the specificity slightly (Table 3).

DISCUSSION

Previous reports have shown that among parotid gland tumors only Warthin's tumor and oncocytoma manifest an accumulation of radioactivity at ^{99m}Tc-pertechnetate scintigra-

TABLE 2
Comparison of Scintigraphic Findings and Histopathologic Diagnosis in Sixty-Eight Lesions

Scintigraphic findings	Warthin's tumor (n = 23)	Non-Warthin's tumor	
		Benign (n = 37)	Malignant (n = 8)
Type 1 (n = 18)	15	2	1
Type 2 (n = 4)	3	1	0
Type 3 (n = 12)	3	8	1
Type 4 (n = 34)	2	26	6

phy (8). The mechanism of ^{99m}Tc -pertechnetate accumulation in these tumors is thought to be due to the epithelial cells contained within tumors that can extract large anions such as pertechnetate from the blood (7-9). As an oncocytoma is extremely rare, this scintigraphic finding has been used mainly for differentiating Warthin's tumor from other parotid gland tumors.

However, recent reports have described cases of Warthin's tumors without increased activity of ^{99m}Tc -pertechnetate (9,10). In addition, some case reports have described non-Warthin's tumors, including carcinomas, that show increased activity of ^{99m}Tc -pertechnetate (3,11).

Our results indicate that the sensitivity of the scintigraphy for evaluating Warthin's tumor is relatively low (78%). Among five false-negative lesions, three lesions were Type 3 and two lesions were Type 4. Thus, 22% of Warthin's tumors are of normal or decreased activity with no apparent retention on the scintigraphy. Although the reason for the lack of increased and retentive radioactivity in false-negative Warthin's tumors is not clear, these Warthin's tumors may have less active epithelial cells (9).

Although the specificity of the scintigraphy was high (91%), four non-Warthin's tumors showed Type 1 or Type 2 finding, so that the scintigraphy misdiagnosed them as being Warthin's tumors. Three of the four lesions were other benign lesions: pleomorphic adenoma, lymphoepithelial lesion and chronic in-

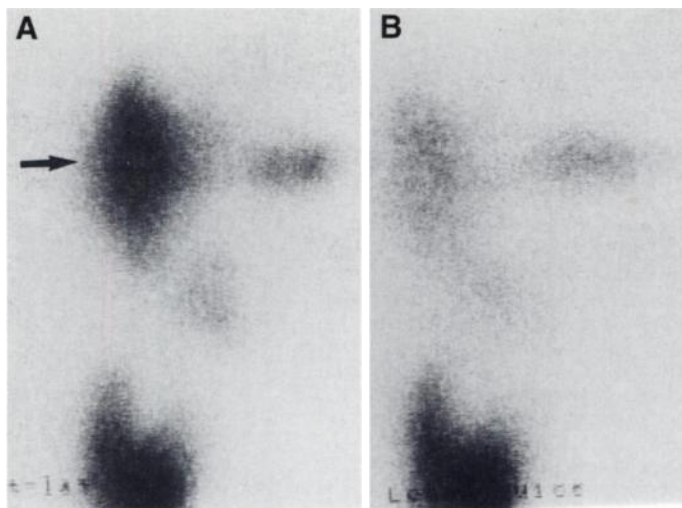


FIGURE 2. A 48-yr-old woman with a Warthin's tumor in the right parotid gland that showed Type 3 finding. (A) Technetium-99m-pertechnetate image on the right lateral view shows normal activity in the right parotid gland (arrow). (B) After the oral administration of lemon juice, a repeat image shows no abnormal retention of radioactivity in the right parotid gland.

flammatory lesion. However, the remaining one lesion was found to be an adenocarcinoma. Thus, our data demonstrate that other benign lesions and malignant neoplasms can show Type 1 and Type 2 findings, thus mimicking Warthin's tumors at the scintigraphy.

Recent reports have discussed the usefulness of washout study using intraoral acid stimulation (5,6). In our series, on the basis of prestimulation images alone, three Type 2 Warthin's tumors were misdiagnosed as non-Warthin's tumor, and one Type 2 non-Warthin's tumor was correctly diagnosed as non-Warthin's tumor. Thus, the sensitivity of scintigraphy consisting of pre- and poststimulation images (78%) was much higher than that of prestimulation images alone (65%), whereas the

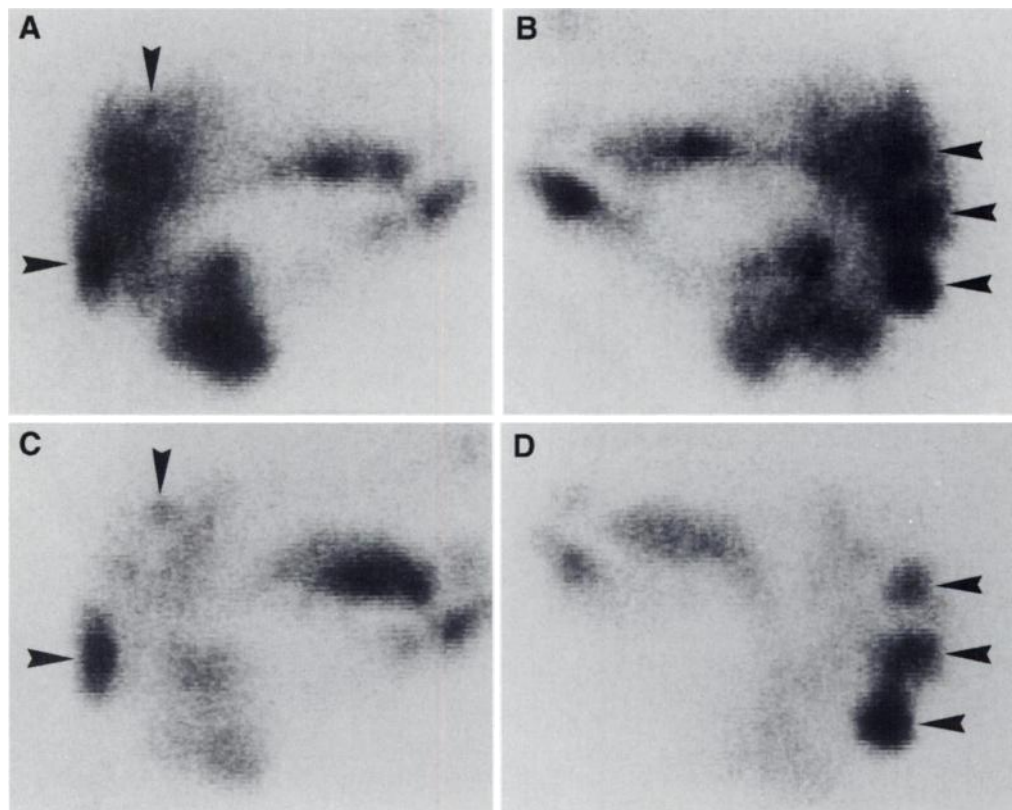


FIGURE 1. A 59-yr-old man with multiple Warthin's tumors in bilateral parotid glands that showed Type 1 finding. Technetium-99m-pertechnetate images on the right (A) and left (B) lateral views show multiple areas of increased activity (arrowheads) in bilateral parotid glands. (C,D) After the oral administration of lemon juice, repeat images also show multiple areas of increased activity (arrowheads) in bilateral parotid glands.

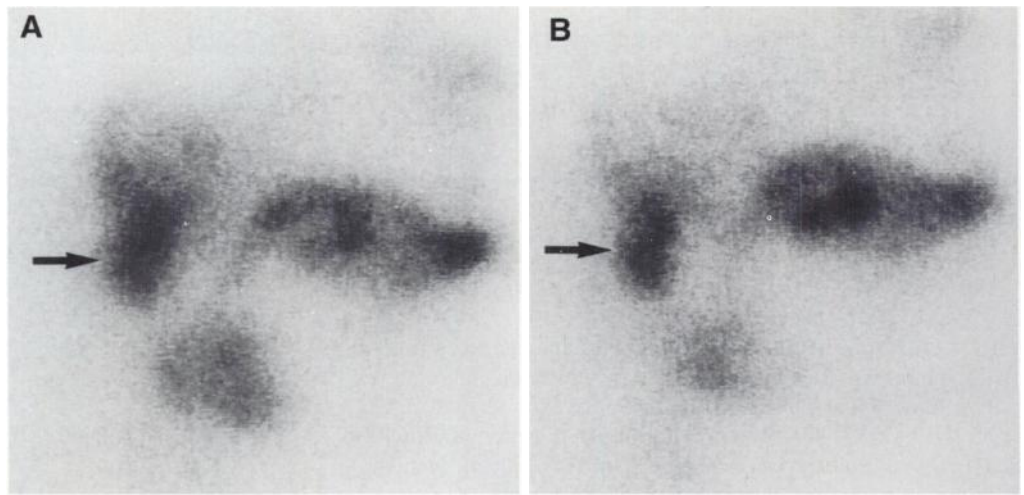


FIGURE 3. A 56-yr-old man with an adenocarcinoma in the right parotid gland that showed Type 1 finding. (A) Technetium-99m-pertechnetate image on the right lateral view shows an area of increased activity (arrow) in the lower pole of the right parotid gland. (B) After the oral administration of lemon juice, a repeat image also shows an area of increased activity (arrow) in the lower pole of the right parotid gland.

specificity of scintigraphy consisting of pre- and poststimulation images (91%) was slightly lower than that of prestimulation images alone (93%). The addition of the intraoral stimulation method was found to improve the sensitivity markedly but decrease the specificity slightly.

Furthermore, in Type 1 Warthin's tumors, poststimulation images were found to be superior to prestimulation images for detection and localization of Warthin's tumors, due to higher contrast between the tumor and surrounding parotid gland tissue. Thus, the intraoral acid stimulation method should be included in a protocol of the ^{99m}Tc -pertechnetate scintigraphy for evaluating Warthin's tumor.

CONCLUSION

For evaluating Warthin's tumor, the sensitivity of ^{99m}Tc -pertechnetate scintigraphy was relatively low although the

specificity was sufficiently high. The use of lemon juice stimulation improved the sensitivity markedly but decreased the specificity slightly. Thus, we believe that ^{99m}Tc -pertechnetate scintigraphy with lemon juice stimulation should be carefully performed for diagnosis of Warthin's tumor.

REFERENCES

1. Chapnik JS. The controversy of Warthin's tumors. *Laryngoscope* 1983;93:695-716.
2. Stebner FC, Eylar WR, DuSault LA, Block MA. Identification of Warthin's tumors by scanning of salivary glands. *Am J Surg* 1968;116:513-517.
3. McGuirt WF, McCabe BF. Limitations of parotid scans. *Ann Otol* 1977;86:247-250.
4. Higashi T, Murahashi H, Ikuta H, Mori Y, Watanabe Y. Identification of Warthin's tumors with technetium-99m pertechnetate. *Clin Nucl Med* 1987;12:796-800.
5. Sostre S, Medina L, DeArellano GR. The various scintigraphic patterns of Warthin's tumor. *Clin Nucl Med* 1987;12:620-626.
6. Liu RS, Yeh SH, Yen TC, Hsu DF. Salivary scintigraphy with vitamin C stimulation: an aid in differentiating unilateral parotitis from Warthin's tumor. *Eur J Nucl Med* 1990;16:689-691.
7. Weinstein GS, Harvey RT, Zimmer W, Ter S, Alavi A. Technetium-99m pertechnetate salivary gland imaging: its role in the diagnosis of Warthin's tumor. *J Nucl Med* 1994;35:179-183.
8. San Pedro EC, Lorberboym M, Machac J, Som P, Shugar J. Imaging of multiple bilateral parotid gland oncocytoma. *Clin Nucl Med* 1995;20:515-518.
9. Yoshimura Y, Kohtomi M. Bilateral papillary cystadenoma lymphomatosum of the parotid gland without accumulation of technetium 99m pertechnetate: report of a case and review of the literature. *J Oral Maxillofac Surg* 1991;49:401-404.
10. Arbab AS, Koizumi K, Uchiyama G, Arai T. The usefulness and limitations of combined Tc-99m pertechnetate and Ga-67 citrate imaging of salivary gland disorders. *Clin Nucl Med* 1995;20:5-12.
11. Noyek AM, Greyson ND, Fernandes BJ, Chapnik JS. Radionuclide salivary scan imaging of a "functioning" malignant parotid tumor (mucous-producing papillary adenocarcinoma). *J Otol* 1982;11:83-85.

TABLE 3

Diagnostic Accuracy of Scintigraphy for Evaluating Warthin's Tumor in Sixty-Eight Lesions

Scintigraphy	Sensitivity (%)	Specificity (%)	Accuracy (%)
Prestimulation alone	15/23 (65)	42/45 (93)	57/68 (84)
Poststimulation alone	18/23 (78)	41/45 (91)	59/68 (87)
Pre- and poststimulation	18/23 (78)	41/45 (91)	59/68 (87)