

Biliary Dyskinesia: Role of the Sphincter of Oddi, Gallbladder and Cholecystokinin

Shakuntala Krishnamurthy and Gerbail T. Krishnamurthy

Nuclear Medicine Department, Tuality Community Hospital, Hillsboro, Oregon; and Nuclear Medicine Section/Imaging Service, Veterans Affairs Medical Center, and University of Arizona, Tucson, Arizona

The availability of objective and quantitative diagnostic tests in recent years has allowed more precise documentation of biliary dyskinesia. Biliary dyskinesia consists of two disease entities situated at two different anatomical locations: sphincter of Oddi spasm, at the distal end of the common duct, and cystic duct syndrome, in the gallbladder. Both conditions are characterized by a paradoxical response in which the sphincter of Oddi and the cystic duct contract (and impede bile flow) instead of undergoing the normal dilatation, when the physiological dose of cholecystokinin is infused. Quantitative cholescintigraphy can clearly differentiate one disease entity from the other. The therapies of choice are sphincterotomy, sphincteroplasty or antispasmodics for sphincter of Oddi spasm and cholecystectomy for cystic duct syndrome. After quantitative cholescintigraphy, the final impression should identify the disease entity by name to assist the referring physician in making an appropriate therapeutic decision; a mere statement that a test is consistent with biliary dyskinesia is no longer sufficient.

Key Words: biliary dyskinesia; cholecystokinin; sphincter of Oddi spasm; gallbladder; cystic duct syndrome

J Nucl Med 1997; 38:1824-1830

Clinical acceptance of the role of quantitative biliary dynamic studies has progressed slowly, and only recently have quantitative biliary dynamic studies gotten the attention of practicing clinicians. Historically, this has been typical for the acceptance of any new knowledge in biliary anatomy, physiology or pathology. First, doubts were expressed about the existence of a sphincter at the distal end of the common bile duct (CBD). Later, questions were raised as to the cause of contraction and emptying of the gallbladder. When the existence of the sphincter of Oddi (1) and the hormone mechanism [cholecystokinin (CCK)] for gallbladder emptying (2) were proposed and confirmed, new doubts were expressed about the entity of biliary dyskinesia (3). Measurement of sphincter of Oddi dynamics by biliary manometry (4) and gallbladder and bile duct emptying by cholescintigraphy (5) have allowed for objective documentation of biliary dyskinesia. The entity of biliary dyskinesia is now well-defined (6), and appropriate therapeutic options are available (7). Diagnosis of biliary dyskinesia requires a clear understanding of the physiological relationship between the sphincter of Oddi and the gallbladder and of the effect of CCK on them in both good health and disease. In this article, we first will review the basic pathophysiology and later summarize the scintigraphic approach to the diagnosis of biliary dyskinesia.

SPHINCTER OF ODDI

In 1887, Rugero Oddi first proposed a sphincter mechanism at the distal end of the CBD, which today bears his name (1). The presence of the sphincter remained controversial for many

years until Boyden's detailed work put an end to uncertainty (8). The functional role of the sphincter of Oddi is now widely accepted. The sphincter consists of three parts: one surrounding the intraduodenal part of the distal CBD, called the choledochal sphincter; one at the distal end of the pancreatic duct (duct of Wirsung), called pancreatic sphincter; and one surrounding the common channel, called the ampullary sphincter. The distal end of the common duct, surrounded by the ampullary sphincter, opens into second part of the duodenum at the postero-medial wall at an elevation called the ampulla of Vater. The name sphincter of Oddi generally refers to all three sphincters (Fig. 1).

Bile Flow

Of 600 ml of bile produced by the liver per day (0.4 ml/min), about 70% enters the gallbladder during fasting, and the remaining 30% enters the duodenum directly (9). The volume of hepatic bile that partitions between the two organs is dependent on the sphincter of Oddi tone, which is maintained by periodic contractions. During fasting, the sphincter of Oddi exhibits a median of 4 contractions/min, of which approximately 80% proceed antegrade, 13% proceed retrograde and the remaining 9% occur simultaneously at three levels within the sphincter (Table 1). The basal mean pressure of 15 mmHg between contractions rises to 135 mmHg at the peak of the phasic wave (10). Cholecystokinin administration normally abolishes the phasic wave activity and promotes dilation of the sphincter of Oddi, facilitating smooth passage of the bile it receives from the gallbladder.

Cholecystokinin

In 1928, Ivy and Oldberg (2) first proposed a hormonal mechanism for contraction and emptying of the gallbladder induced by acidification of upper small intestine, and named the hormone CCK. For a while, it was also called pancreozymin because it increased the production of pancreatic enzymes (11). Later, it was shown that a single hormone produced both effects (12). Because the gallbladder effect was described first, the title of CCK has been restored. Meal ingestion stimulates the release of CCK from cells scattered in the mucosa of the duodenum and upper jejunum (Fig. 1). There are no CCK-secreting cells in the esophagus, stomach or intestine, beyond the terminal jejunum (13). Two forms of CCK have been identified: one with 33 and another with 39 amino acids. The form with 33 amino acids is the most abundant. The biological action of the hormone resides mainly at the C-terminal tetrapeptide (14). Cholecystokinin-33 can be cleaved at different locations (Fig. 2), and the fragment that retains the C-terminal tetrapeptide continues to have most of the biological function of the parent molecule (15). Other peptides such as gastrin and cerulein, which have the identical C-terminal tetrapeptide, also possess a cholecystokinetic effect. A peptide consisting of the terminal eight amino acids (CCK-8) of the hormone has been synthesized and marketed as Sincalide or Kinevac. The seventh amino acid, tyrosine, is sulfated, which

Received Nov. 12, 1996; revision accepted Jan. 20, 1997.

For correspondence or reprints contact: S. Krishnamurthy, MD, Nuclear Medicine, Tuality Community Hospital, 335 8th Ave. S.E., Hillsboro, OR 97123.

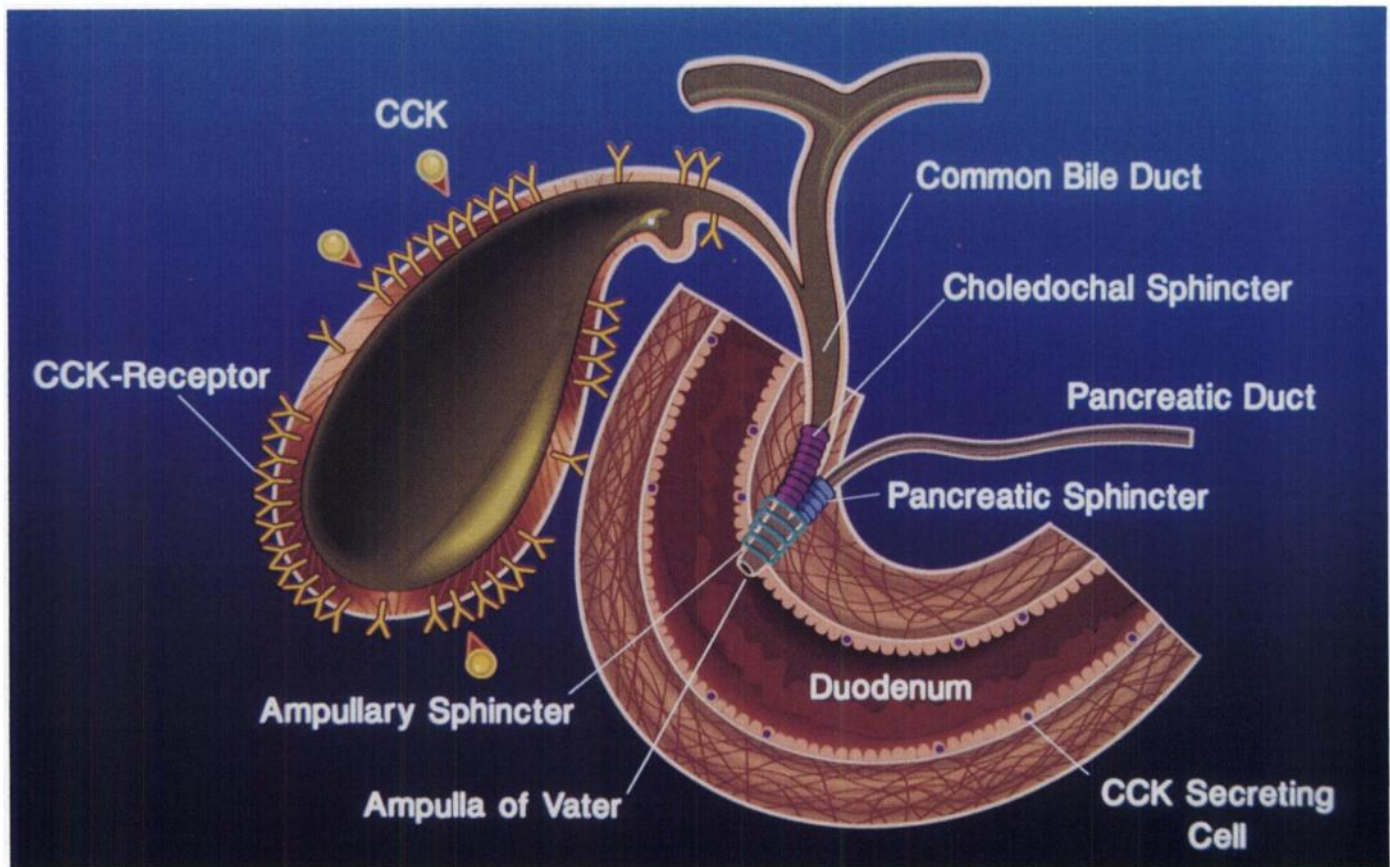


FIGURE 1. Sphincter of Oddi. Choledochal sphincter covers the intraduodenal part of the CBD before it joins the pancreatic duct. The pancreatic sphincter covers the distal end of the pancreatic duct. The ampullary sphincter covers the common channel formed by the union of the CBD and the pancreatic duct (duct of Wirsung). The name sphincter of Oddi refers to all three sphincters.

is an essential requirement for retaining the biologic potency of the hormone (16).

Actions of Cholecystinin

In addition to inducing gallbladder contraction, pancreatic enzyme secretion and sphincter of Oddi dilatation, CCK has many other biological actions:

- Contraction and emptying of the gallbladder.
- Relaxation of the sphincter of Oddi.
- Increase in pancreatic enzyme secretion.
- Increase in secretion of insulin, glucagon and somatostatin by Islet cells.
- Inhibition of gastric emptying by contraction of the pyloric sphincter.
- Increase in hepatic bile secretion.
- Increase in intestinal peristalsis.
- Increase in intestinal blood flow.
- Suppression of appetite.
- Decrease in systolic blood pressure.

Cholecystinin acts by attaching to CCK receptors (Fig. 1) distributed in the smooth muscle of the gallbladder and sphincter of Oddi (17). The degree of gallbladder emptying is CCK dose-dependent. Gallbladder ejection fraction increases as the dose is enhanced from 0.5 ng/kg/min to 3.3 ng/kg/min (10 ng/kg/3 min) and then begins to decrease when larger doses are infused, especially when CCK is given as a rapid intravenous bolus (18). This seemingly paradoxical response in normal subjects is attributed to the different threshold level of the CCK receptors in the body, fundus and cystic duct. In animals, it was shown that the cystic duct smooth muscle threshold for CCK-induced contraction is much higher than the threshold for

contraction of the muscle in the body and fundus of the gallbladder (19). The cystic duct, therefore, does not contract when a physiological dose of CCK is infused. When large, nonphysiological CCK doses are given, however, the gallbladder ejection fraction decreases, probably related to cystic duct contraction when the dose exceeds the threshold value for contraction (18). The degree of gallbladder emptying also is related directly to the total number of receptors in the gallbladder wall smooth muscle (20). In addition to inducing contraction of the gallbladder, CCK simultaneously relaxes the sphincter of Oddi, mainly by abolishing phasic wave activity (Fig. 3). The sphincter of Oddi relaxation is attributed to the binding of CCK to inhibitory receptors. The dose recommended in the Sincalide package insert was developed for oral cholecystogram and for inducing pancreatic enzyme production and was found

TABLE 1
Pressure and Wave Frequency, Sequence and Amplitude Changes in a Normal Sphincter of Oddi

Parameters	Normal		Abnormal
	Median	Range	
Basal pressure (mmHg)	15	5-15	>40
Wave amplitude (mmHg)	135	95-195	>300
Wave frequency (no./min)	4	2-6	>7
Sequence			
Antegrade (%)	80	12-100	—
Simultaneous (%)	13	0-50	—
Retrograde (%)	9	—	>50

Reproduced from Ref. 10 with permission from the author and publisher.

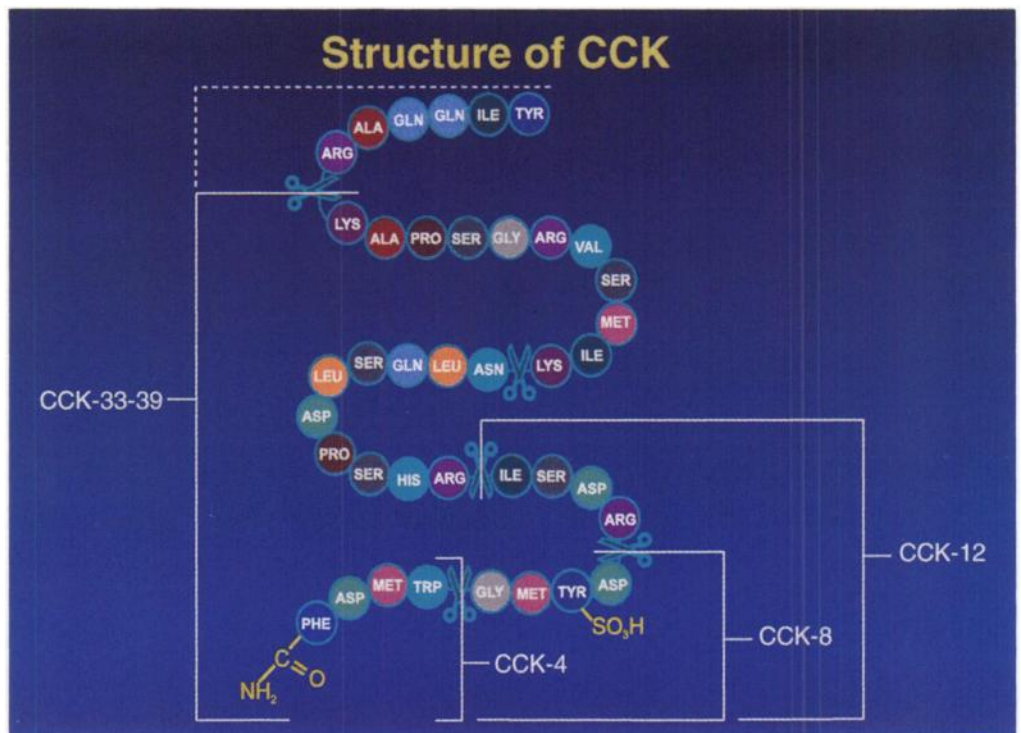


FIGURE 2. Molecular structure of CCK. Both 33- and 39-amino acid chain length molecule can be cleaved at different locations (scissors). All fragments attached to the C-terminal tetrapeptide retain most of the biological function of the parent molecule. Note the attachment of the sulfate to the seventh amino acid, tyrosine, which is a prerequisite for hormonal action.

to be too large for cholescintigraphy. Large nonphysiological dose produces low ejection fraction in association with abdominal pain in normal subjects and, hence, should be avoided in patients (18,21). The normal gallbladder ejection fraction value of 35% and higher is based on 3-min infusion of 10 ng/kg of CCK-8 (3.3 ng/kg/min). Infusions performed at a different rate could produce either higher or lower ejection (9).

Biliary Dyskinesia

Two disease entities that qualify for inclusion under this title are: cystic duct syndrome (CDS), involving the gallbladder, and sphincter of Oddi spasm (SOS), involving the distal CBD. Both of these diseases were recognized many years ago but remained controversial due to lack of a reliable, objective and reproducible diagnostic test. Introduction of biliary manometry (4,22,23) and the scintigraphic measurement of the gallbladder ejection fraction (5) have provided objective tests for the diagnosis. Both endoscopic retrograde cholangiopancreatography and biliary manometry are used for diagnosis and sphincterotomy for the

treatment of SOS (6). Manometry and endoscopic retrograde cholangiopancreatography are relatively invasive, expensive and skill-intensive. Sphincterotomy for biliary disease is invasive and is associated with an overall complication rate of 9.8%; the rate is much higher (23%) in patients with SOS (7,24). One option available for reducing complication rate is to restrict such high-risk diagnostic and therapeutic procedures to a select group of patients with high likelihood of the disease under consideration (25). Noninvasive studies are preferable. Cholescintigraphic studies, which are noninvasive, quantitative and relatively inexpensive, can provide enough basic information to justify performing invasive manometric studies in a select group of patients when appropriate (26,27).

Sphincter of Oddi Spasm

This disease is also known in the literature as sphincter of Oddi dysfunction, papillary stenosis and bile duct dyskinesia. In patients with SOS, the liver function tests and the size of the CBD on ultrasound are usually normal in most patients with an intact gallbladder. The duct may show slight compensatory enlargement in those patients who have had cholecystectomy. In patients with SOS, an intact gallbladder serves as a low-pressure (<10 mmHg) reservoir by accepting increased bile that is diverted to it by the tight sphincter. Because of this accommodation, the CBD does not dilate. When this protective mechanism is removed by cholecystectomy, the CBD dilates to compensate for higher pressure (>15 mmHg) at the sphincter. Manometrically, SOS shows an increase in the number of basal phasic waves, the majority of which propagate retrograde (6,10,22). Cholecystokinin infusion produces a paradoxical response (23,28,29). Instead of a normal inhibition of phasic waves and dilatation of the sphincter of Oddi (Fig. 3), CCK injection in SOS patients increases both the number of waves and the number of retrograde waves per minute, resulting in sphincter contraction, which impedes bile flow through it (Fig. 4).

Cystic Duct Syndrome

Cystic duct syndrome was first described in 1963 by Cozzolino et al. (30), but it remained controversial due to lack of a reliable diagnostic test for measuring gallbladder emptying.

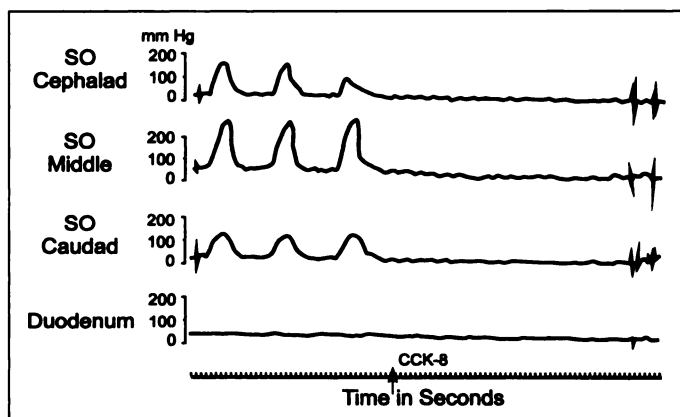


FIGURE 3. Effect of CCK-8 on a normal sphincter of Oddi. Note the abolishment of contraction waves with CCK-8, which facilitates sphincter dilation, allowing smooth passage of bile through it. (Reprinted with permission of the author from: Toouli J, Roberts-Thompson IC, Dent J, Lee J. Manometric disorders in patients with suspected sphincter of Oddi dysfunction. *Gastroenterology* 1985;88:1243-1250.)

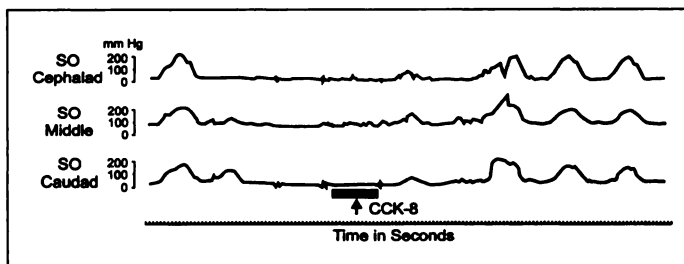


FIGURE 4. Effect of CCK-8 on the sphincter in a patient with SOS. Note the exaggeration of contraction waves with CCK-8 and the predominant retrograde propagation, which results in contraction of the sphincter instead of normal dilatation. (Reprinted with permission of the author from: Toouli J, Roberts-Thompson IC, Dent J, Lee J. Mahometric disorders in patients with suspected sphincter of Oddi dysfunction. *Gastroenterology* 1985;88:1243-1250.)

Major pathophysiology of the syndrome resides in the cystic duct itself. There is kinking, fibrosis and thickening of the wall and narrowing of the lumen of the cystic duct (31). Hepatic bile enters the gallbladder, often slowly, but cannot get out readily on feeding or injection of CCK. In the literature, it is also known by such names as chronic acalculous gallbladder disease or chronic acalculous cholecystitis.

Cholescintigraphic Diagnosis

A proper patient preparation, data acquisition and analysis is critical for diagnosis. The patient is asked to fast for a minimum of 4 hr and preferably for 8-10 hr. All drugs known to act on the sphincter of Oddi (e.g., opioids, calcium channel blockers, nitrates etc.) and gallbladder are discontinued for an appropriate length of time, depending on plasma $T_{1/2}$ of the drug. It is much easier to analyze the data when the hepatic and gallbladder phase studies are obtained separately on the computer (32).

Hepatic Phase Imaging

Anterior view images are acquired at 1 frame/min for 60 min with 2-4 mCi of ^{99m}Tc -mebrofenin, using a large field-of-view gamma camera fitted with a low-energy, all-purpose, parallel-hole collimator. The planar images are reformatted and photographed at two frames per image. A time-activity curve is generated over the upper right hepatic lobe. Liver peak uptake time and excretion $T_{1/2}$ are obtained from the liver curve. Hepatic extraction fraction, which allows for the separation of hepatic from biliary disease, is calculated when deconvolution software is available (33,34). Characteristics of bile formation and flow are analyzed from the planar images, with particular reference to the time of appearance of the gallbladder, intestine and CBD. The common bile duct is scrutinized for its size, course, bile pooling and any evidence of tapering or an abrupt cutoff sign (9).

Gallbladder Phase Imaging

These data are acquired as a separate 30-min study between 60 and 90 min after ^{99m}Tc -mebrofenin injection. If there was any superimposition of the duodenal and CBD radioactivity during the hepatic phase imaging, an attempt is made to separate them during the gallbladder phase by angling the camera in whatever direction and degree separates them maximally. In some patients, it may be an RAO view; in others, it may be an LAO view; and in most others, it could be the same angle that was used during the hepatic phase imaging. Duodenal activity, if present, can be cleared by asking the patient to drink a glass of water. The data are collected at 1 frame/min for 30 min. Five milliliters of saline are infused slowly at 2 min as a placebo, and CCK-8 is infused through an infusion pump beginning at 5 min, at a dose of 10 ng/kg/3 min. Before saline and CCK-8 infusion are begun, the patient is instructed to raise

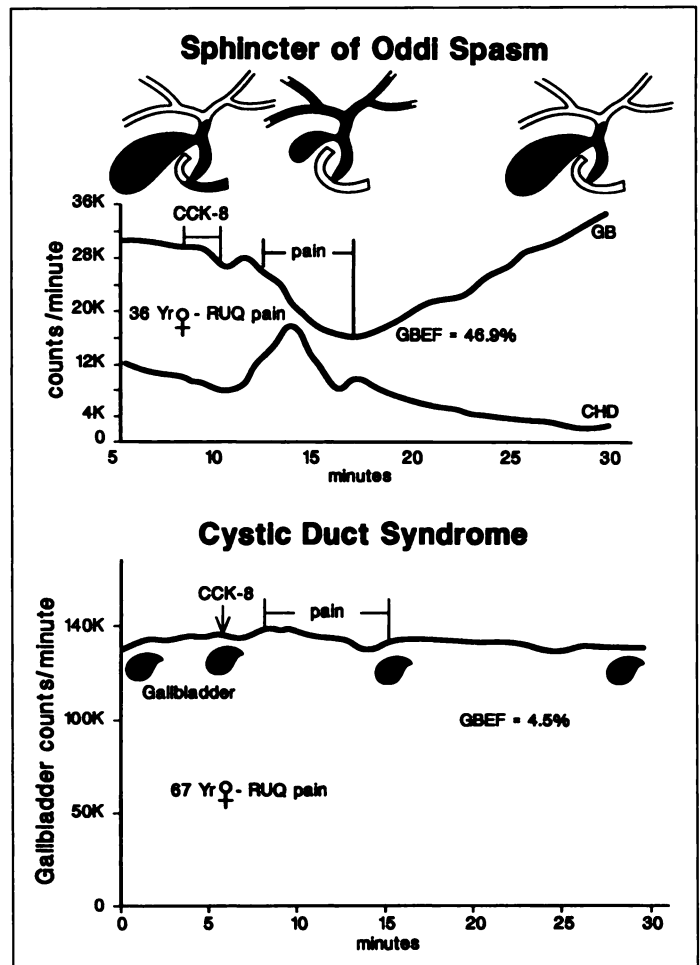


FIGURE 5. Gallbladder emptying in a patient with SOS (top) and CDS (bottom). Note normal ejection fraction and rapid refilling soon after the cessation of CCK-8 infusion in SOS and a low ejection fraction with no refilling in CDS.

her hand as soon as pain is felt and to raise it again when the pain is relieved. These time intervals are recorded and shown on the gallbladder curve (Fig. 5). The ejection fraction is calculated in the standard fashion (5,9). High-contrast biliary images are obtained and scrutinized carefully for evidence of bile reflux into common hepatic, right hepatic and left hepatic ducts during the ejection period. Rapid refilling of the gallbladder is checked both on the gallbladder curve and the planar images. In patients with postcholecystectomy CBD dilatation, a region of interest is drawn over the common duct (common hepatic duct + CBDs) from its origin at the junction of the right and left hepatic ducts to its termination at the duodenum, taking care not to include any of the intestinal activity. Post-CCK-8 ejection fraction and ejection rate for the common duct are calculated similar to the gallbladder (33).

Hepatic phase parameters aid in differentiating CBD stenosis from SOS. The gallbladder phase parameters help to differentiate SOS from CDS and provide quantification of the degree of abnormality. In patients with cholecystectomy who have CBD dilatation, CCK stimulation helps to document presence or absence of obstruction by measuring ejection fraction and ejection rate for CBD (34).

Cholescintigraphic Features of Sphincter of Oddi Spasm

Scintigraphic features may depend upon the presence or absence of the gallbladder. In patients with an intact gallbladder, scintigraphy usually shows normal anatomy of the CBD during the hepatic phase imaging, with minimal or no evidence

of bile pooling in the intra- or extrahepatic bile ducts. These features are quite different from those seen in stricture of the CBD, where there is intense bile pooling proximal to obstruction (9). The time to peak hepatic uptake may be delayed (26,35) or within normal range (36). The liver shows an increase in percent residual activity at 45 and 60 min, with decrease in the rate of liver bile emptying (27). Hepatic hilum to duodenal transit is increased (36). Extrahepatic ducts appear early and persist for a longer duration, especially in those patients with cholecystectomy. After CCK-8 infusion, the gallbladder may show a normal or slightly low ejection fraction. Almost all of the bile emptied from the gallbladder may reflux into common hepatic, right hepatic and left hepatic ducts during the ejection period and re-enter the gallbladder immediately upon cessation of CCK-8 infusion. The CBD curve shows a peak corresponding to this reflux in patients with an intact gallbladder (35). This sign also is noted in association with stricture of the CBD (37). The intrahepatic ducts can accommodate almost all of the bile emptied from the gallbladder (50 ml), without being dilated. Many, but not all, patients experience pain during the ejection period, and the pain is usually relieved when the gallbladder relaxes and begins to refill (Fig. 5). In patients without a gallbladder, cholescintigraphy shows prominent bile stasis within intra- and extrahepatic ducts and marked delay in time to hepatic peak (35,38). Cholecystokinin injection increases hepatic bile production and washes out bile stasis within the ducts rapidly when there no anatomic obstruction (33). This response is very similar to that of a lasix test in kidneys to rule out obstruction at the uretero-pelvic junction. The bile-emptying rate from CBD with stricture is much lower than in normal subjects. In subjects with an intact gallbladder, the normal bile-emptying rate is 3.5%/min or higher (9). The distinction between anatomic stricture (stenosis) versus functional obstruction also is made by administering amyl nitrite during cholescintigraphy (39). In five reports totaling 67 patients with suspected SOS, cholescintigraphy identified all patients, for a sensitivity of 100%, when any one of the abnormal parameters was used as evidence of SOS (26,27,36,38,39). Such results are not universal, and caution should be exercised during data acquisition, analysis and interpretation (35). The average scintigraphic sensitivity for SOS in the literature is between 70% and 90% (40). It is likely that many of the functional parameters described above may need further modification because a large number of patients is studied under different imaging protocols.

Scintigraphic Features of Cystic Duct Syndrome

On scintigraphy, most of the gallbladders with CDS are seen within 60 min, but some may be delayed for 3–4 hr due to slow absorption of water through the wall (32). The bile ducts are seen as normal during the hepatic phase imaging. On CCK-8 injection, the gallbladder shows a low ejection fraction. The exact duration of gallbladder ejection may be difficult to measure in some because the curves are often flat (Fig. 5). There is usually no bile reflux into common hepatic, right and left hepatic ducts. In five reported series, of a total of 281 patients with CDS who had cholecystectomy solely on the basis of low ejection fraction, 247 (88%) had relief of pain, and 250 patients (89%) had histological evidence of cystic duct or gallbladder abnormality (41–45). Based on such excellent outcome, more and more surgeons now feel confident performing cholecystectomy solely on the basis of a low ejection fraction.

ROLE OF NUCLEAR MEDICINE

The pain of biliary dyskinesia, in the beginning, is neither severe nor constant, and for these reasons, many patients tolerate it for a long time before seeking medical aid. When patients finally do seek medical help, their problem is not clarified immediately because of normal routine liver function tests and normal ultrasound studies of the gallbladder and the CBD. Only upon repeated presentation do the clinicians begin to consider biliary dyskinesia as a possibility and request these functional hepatobiliary studies. Patients are referred to nuclear medicine by the primary care physician under many different names, including to rule out "papillary stenosis, biliary spasm, postcholecystectomy syndrome, biliary pain, CDS or chronic acalculous gallbladder disease" or under some other vague diagnosis (3). Only a few physicians request the studies under the title "biliary dyskinesia." Because of unfamiliarity with quantitative biliary dynamic studies, the entity of biliary dyskinesia is probably underdiagnosed at this stage. A well-informed nuclear medicine physician can address a clinician's concern after knowing the clinical problem and custom-design the test for the patient. Attention is given to proper technical details including patient preparation, duration of fasting and infusion of physiological doses of CCK-8. All drugs that act on the sphincter and gallbladder (opiates, nitrates, calcium channel blockers, etc.) are discontinued before the test. Recording of the exact time of onset and relief of pain and its relation to the shape of the gallbladder curve is important in delineating the temporal relationship of pain to the gallbladder-emptying phase (Fig. 5). Pain occurring outside the gallbladder-emptying phase is probably nonbiliary in origin. Because the action of CCK includes an increase of intestinal peristalsis (see "Actions of Cholecystokinin"), late-onset pain may suggest an intestinal origin of pain.

FUTURE

The liver is the largest organ in the body and carries out the most complex biologic function. It concentrates about 98% of the injected dose of ^{99m}Tc -mebrofenin and rapidly secretes into bile (excretion $T_{1/2} = 16$ min). Almost 70% of the radioactivity secreted by the liver enters the gallbladder during fasting, giving excellent counts for imaging and quantitation. The normal physiological relation and complex pathological connection that exists among the sphincter of Oddi, gallbladder and CCK in patients offers a great opportunity for nuclear medicine to unravel the mystery. The appropriate therapy for CDS is cholecystectomy and, for SOS, it is sphincterotomy, sphincteroplasty or antispasmodics. Cholecystectomy for SOS may be inappropriate. Therefore, it is important to differentiate these two conditions to allow the referring physician to make an appropriate therapeutic decision (Fig. 6). An inappropriate response (contraction) by the cystic duct and the sphincter of Oddi to normal doses of CCK-8 is attributed to activation of inhibitory receptors, which normally remain unresponsive. In CDS and SOS, these inhibitory CCK receptors become activated and respond by contraction (Fig. 6, middle and right), preventing bile emptying through the cystic duct and the sphincter of Oddi, respectively (19). In CDS, the gallbladder counts in response to CCK-8 may decrease minimally or remain the same, whereas in SOS, the gallbladder counts may decrease significantly by emptying bile into the CBD (with reflux into common hepatic duct and right and left hepatic ducts and other segmental intrahepatic ducts), but the counts increase immediately due to refilling (Fig. 5) after cessation of CCK-8 infusion. A clear understanding of normal physiological changes and variations in pathology among the sphincter of Oddi, the cystic

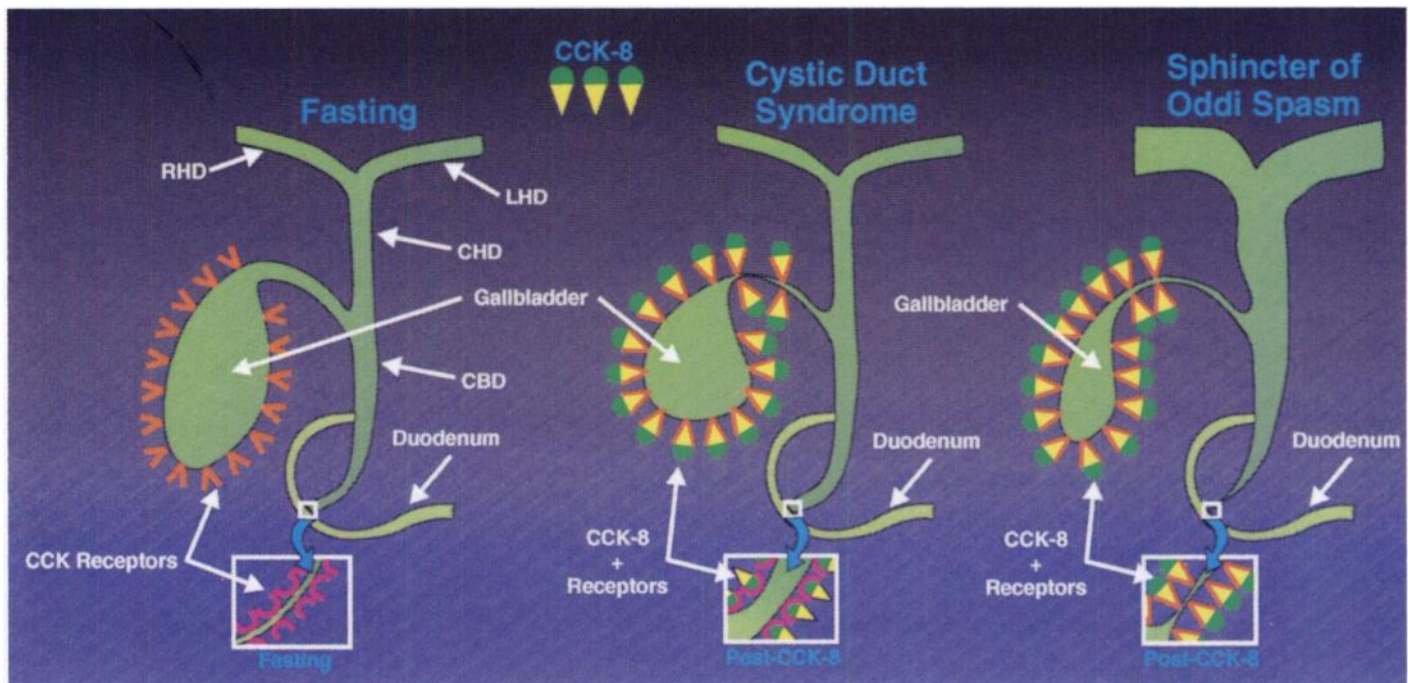


FIGURE 6. Schematic representation of the action of CCK-8 in patients with SOS or CDS. Note the contraction of the cystic duct, with poor emptying of the gallbladder in the case of CDS. Note the activation of contraction CCK receptors in the sphincter (inset), with bile reflux into common hepatic duct and intrahepatic ducts in case of SOS.

duct and the hormone CCK is essential in arriving at the correct diagnosis. A close working relationship between the referring physician and the nuclear medicine staff makes the challenge of diagnosing biliary dyskinesia a gratifying experience in the end.

ACKNOWLEDGMENT

This work was supported in part by the Department of Veterans Affairs.

REFERENCES

- Oddi R. D'une disposition a sphincter specille del'ouverture du canal cholidoque. *Arch Ital Biol* 1887;8:317-322.
- Ivy AC, Oldberg E. A hormone mechanism of gallbladder contraction and evacuation. *Am J Physiol* 1928;86:599-613.
- Steinberg WM. Sphincter of Oddi dysfunction: a clinical controversy. *Gastroenterology* 1988;95:1409-1415.
- Geenen JE, Hogan WJ, Dodds WJ, Stewart ET, Arndorfer RC. Intraluminal pressure recording from the human sphincter of Oddi. *Gastroenterology* 1980;78:317-324.
- Krishnamurthy GT, Bobba VR, Kingston E. Radionuclide ejection fraction: a new objective method of studying motor function of the human gallbladder. *Gastroenterology* 1981;80:482-490.
- Hogan WJ, Geenen JE. Biliary dyskinesia. *Endoscopy* 1988;20:179-183.
- Freeman ML, Nelson DB, Sherman S, et al. Complications of endoscopic biliary sphincterotomy. *N Engl J Med* 1996;335:909-918.
- Boyden EA. The sphincter of Oddi in man and certain representative mammals. *Surgery* 1937;1:25-37.
- Krishnamurthy GT, Bobba VR, McConnell D, et al. Quantitative biliary dynamics: introduction of a new noninvasive scintigraphic technique. *J Nucl Med* 1983;24:217-223.
- Thune A, Scicchitano J, Thompson IR, Toouli J. Reproducibility of endoscopic sphincter of Oddi manometry. *Dig Dis Sci* 1991;36:1401-1405.
- Harper AA, Raper HS. Pancreozymin, a stimulant of the secretion of pancreatic enzymes in extracts of the small intestine. *J Physiol* 1943;102:115-125.
- Jorpes JE, Mutt V. Cholecystokinin and pancreozymin, one single hormone? *Acta Physiol Scand* 1966;66:196-202.
- Sjolund K, Sanden G, Hakanson R, Sundler F. Endocrine cells in human intestine: an immunocytochemical study. *Gastroenterology* 1983;85:1120-1130.
- Mutt V. Cholecystokinin: isolation, structure, and functions. In: Jerzy Glass GB, ed. *Gastrointestinal hormones*. New York, NY: Raven Press; 1980:169-221.
- Rehfeld JF. Four basic characteristics of the gastrin-cholecystokinin system. *Am J Physiol* 1981;240:G255-G266.
- McGuigan JE. Hormones of the gastrointestinal tract. In: DeGroot LJ, ed. *Endocrinology*. Philadelphia, PA: Saunders; 1989:2741-2768.
- Steigerwalt RW, Goldfine ID, Williams JA. Characterization of cholecystokinin receptors on bovine gallbladder membranes. *Am J Physiol* 1984;247:G709-G714.
- Krishnamurthy GT, Bobba VR, Kingston E. Optimization of octapeptide of cholecystokinin (op-CCK) dose for gallbladder emptying. In: Raynaud C, ed. *Proceedings of the third world congress of nuclear medicine and biology*. Paris, France: Pergamon Press; 1982:2224-2247.

- Courtney DF, Clanachan AS, Scott GW. Cholecystokinin constricts the canine cystic duct. *Gastroenterology* 1983;85:1154-1159.
- Upp JR, Nealon WH, Singh P, et al. Correlation of cholecystokinin receptor with gallbladder contractility in patients with gallstones. *Ann Surg* 1987;205:641-648.
- Toftdahl DB, Hojgaard L, Winkler K. Dynamic cholescintigraphy: induction and description of gallbladder emptying. *J Nucl Med* 1996;37:261-266.
- Hogan WJ, Geenen JE, Dodd WJ. Dysmotility disturbances of the biliary tract: classification, diagnosis, and treatment. *Semin Liver Dis* 1987;7:302-310.
- Toouli J. What is sphincter of Oddi dysfunction? *Gut* 1989;30:753-761.
- Venu Rp, Geenen JE. Ampulla: motility and stricture. In: Barken JS, O'Phelan CA, eds. *Advanced therapeutic endoscopy*, 2nd ed. New York, NY: Raven Press; 1994:343-352.
- Huibregtse K. Complications of endoscopic sphincterotomy and their prevention. *N Engl J Med* 1996;335:961-963.
- Fullarton GM, Hilditch T, Campbell A, Murray WR. Clinical and scintigraphic assessment of the role of endoscopic sphincterotomy in the treatment of sphincter of oddi dysfunction. *Gut* 1990;31:231-235.
- Shaffer EA, Hershfield NB, Logan K, Kloiber R. Cholescintigraphic detection of functional obstruction of the sphincter of Oddi. Effect of papillotomy. *Gastroenterology* 1986;90:728-733.
- Meshkinpour H, Mollot M, Eckerling GB, Bookman V. Bile duct dyskinesia. Clinical and monometric study. *Gastroenterology* 1984;87:759-762.
- Toouli J, Roberts-Thompson IC, Dent J, Lee J. Manometric disorders in patients with suspected sphincter of Oddi dysfunction. *Gastroenterology* 1985;88:1243-1250.
- Cozzolino HJ, Goldstein F, Greening RR. The cystic duct syndrome. *J Am Med Assoc* 1963;185:920-924.
- Goldstein F, Grunt R, Margulies M. Cholecystokin cholestigraphy in the differential diagnosis of acalculous gallbladder disease. *Dig Dis* 1974;19:835-849.
- Krishnamurthy S, Krishnamurthy GT. Evolution of nuclear hepatology as a clinical entity. *J Nucl Med Technol* 1995;23(suppl):35S-45S.
- Krishnamurthy GT, Turner FE. Pharmacokinetics and clinical application of technetium-99m-labeled hepatobiliary agents. *Semin Nucl Med* 1990;20:130-149.
- Krishnamurthy S, Krishnamurthy GT. Technetium-99m-iminodiacetic acid organic anions: review of biokinetics and clinical application in hepatology. *Hepatology* 1989;9:139-153.
- Drane WE, Johnson DA. Sincalide-augmented quantitative hepatobiliary scintigraphy (QHBS): definition of normal parameters and preliminary relation between QHBS and sphincter of Oddi (SO) manometry in patients suspected of having SO dysfunction. *J Nucl Med* 1990;31:1462-1468.
- Cicala M, Scopinaro F, Corzziari E, Viscardi A, Habib FI, Torsoli A. Quantitative cholescintigraphy in the assessment of choledochoduodenal bile flow. *Gastroenterology* 1991;100:1106-1113.
- Brar HS. Scintigraphic cholecystokinin-induced bile reflux named as Krishnamurthy-Bobba sign. *J Nucl Med* 1990;31:248.
- Sostre S, Kallou AN, Spiegler EJ, Camargo EE, Wagner HN Jr. A noninvasive test of sphincter of Oddi dysfunction in postcholecystectomy patients: the scintigraphic score. *J Nucl Med* 1992;33:1216-1222.
- Madacsy L, Velosy B, Lonovics J, Csermay L. Differentiation between organic and functional dyskinesia of the sphincter of Oddi with amyl nitrite-augmented quantitative hepatobiliary scintigraphy. *Eur J Nucl Med* 1994;21:203-208.
- Dodds WJ, Thakur S, Collier RD. Quantitative hepatobiliary scintigraphy. *J Nucl Med* 1990;31:1468-1469.

41. Pickelman J, Peiss RL, Henkin R, Salo B, Nagel P. The role of sincalide cholescintigraphy in the evaluation of patients with acalculous gallbladder disease. *Arch Surg* 1985;120:693-697.
42. Fink-Bennet D, DeRidder P, Kolozsi WZ, Gordon R, Jaros R. Cholecystokinin cholescintigraphy: detection of abnormal gallbladder motor function in patients with chronic acalculous gallbladder disease. *J Nucl Med* 1991;32:1695-1699.
43. Zech ER, Simmons LB, Kendrick RR, et al. Cholecystokinin enhanced hepatobiliary scanning with ejection fraction calculation as an indicator of disease of the gallbladder. *Surg Gynecol Obstet* 1991;172:21-24.
44. Misra DC, Blossom GB, Fink-Bennet D, et al. Results of surgical therapy for biliary dyskinesia. *Arch Surg* 1991;126:957-960.
45. Halverson JD, Garner BA, Siegel BA, et al. The use of hepatobiliary scintigraphy in patients with acalculous biliary disease. *Arch Intern Med* 1992;152:1305-1309.