

SPECT Image Analysis Using Statistical Parametric Mapping: Comparison of Technetium-99m-HMPAO and Technetium-99m-ECD

James C. Patterson, Terrence S. Early, Andy Martin, Melanie Z. Walker, James M. Russell and Javier Villanueva-Meyer
*Department of Psychiatry and Behavioral Sciences, Clinical Research Center, and Department of Nuclear Medicine,
The University of Texas Medical Branch, Galveston, Texas*

The goal of this study was to examine the apparent differences in regional cerebral blood flow (rCBF) between two groups of normal individuals who received either of the two tracers, ^{99m}Tc -D,L-hexamethylpropylene amine oxide (^{99m}Tc -HMPAO, or exametazime) or ^{99m}Tc -ethylene-dicysteine diethylester (^{99m}Tc -ECD, or bicisate). **Methods:** Individuals were screened for drug use, head injury, medication status and other psychiatric and medical illnesses. The two groups were matched for age, sex and race. SPECT measurement of brain perfusion was performed in 35 individuals who received ^{99m}Tc -HMPAO and in 55 who received ^{99m}Tc -ECD. Subsequent analysis of these scans was done using computer software including Statistical Parametric Mapping and Analyze. Images were intensity-thresholded and spatially normalized to a standardized stereotactic (Talairach) space. This allowed for the objective, quantitative analysis of these data, demonstrating the extent and magnitude of rCBF changes. **Results:** Our results showed significant changes between these two groups of normal individuals, presumably due to differences in pharmacokinetics between the two radiolabeled tracers. Specifically, large areas of the parietal, occipital and superior temporal cortices were significantly lower in the ^{99m}Tc -HMPAO group than in the ^{99m}Tc -ECD group. Increases were seen in the subcortical nuclei, parts of the brain stem, hippocampus and small areas of the cerebellum in the ^{99m}Tc -HMPAO group as compared to the ^{99m}Tc -ECD group. **Conclusion:** We present a method of image analysis to semiquantitatively measure rCBF in SPECT images and the changes seen due to differences between the two radiotracers.

Key Words: neuroimaging; SPECT; technetium-99m-exametazime; technetium-99m-bicisate

J Nucl Med 1997; 38:1721-1725

There has been a call for standardization of measurement and data analysis in functional neuroimaging in the past few years; however, continuing advances in various areas related to neuroimaging make this difficult. Techniques and tracers used in SPECT imaging have undergone a considerable amount of change over the past 5 yr, as more accurate and powerful means of measurement have become available. The radiotracer ^{99m}Tc -ethylene-dicysteine diethylester (^{99m}Tc -ECD) is a relatively new radiotracer that can be used for measurement of regional cerebral blood flow (rCBF) (1). There have been several studies comparing the differences between this tracer and ^{99m}Tc -D,L-hexamethylpropylene amine oxide (^{99m}Tc -HMPAO), mainly in regard to image quality and pharmacokinetics (2-5). Both ^{99m}Tc -ECD and ^{99m}Tc -HMPAO are intravenously administered compounds that are highly lipophilic and quickly cross the blood-brain barrier. Previous work done on these tracers shows that images from patients scanned using ^{99m}Tc -ECD have a

better internal contrast (gray-to-white ratio) (2) and better external contrast (brain-to-body ratio) (3) than images using ^{99m}Tc -HMPAO. The better external contrast is probably due to the faster clearance of this tracer. Another study shows that, although both tracers have good uptake as a function of blood flow, ^{99m}Tc -ECD uptake is significantly more linear with regard to rCBF and, thus, has less back-diffusion and better correlation to flow (4).

Recently, a software package known as Statistical Parametric Mapping (SPM) has been developed that not only spatially normalizes PET or SPECT images to a standardized stereotactic space, but can then also perform statistical analyses on groups of images (6,7). This software allows for reliable, objective image handling and data analysis, which could definitely improve variability between studies due to the analytic process itself. Here, we use this technique to show the significant differences between these two common tracers used in SPECT brain imaging.

MATERIALS AND METHODS

Subjects

One hundred control subjects between the ages of 18 and 55 were screened for history of illicit drug use, alcohol abuse, serious neurologic or medical disorders, psychiatric disorders, psychiatric disorders in first-degree relatives or history of head injury with loss of consciousness. Eighty-five of these subjects were selected, 55 for the ^{99m}Tc -ECD group and 35 for the ^{99m}Tc -HMPAO group.

Subject Preparation

Before the SPECT scan was performed, all subjects had an intravenous line established while they were lying down, with their eyes open and ears unplugged, in a quiet darkened room with low ambient sound and light. After approximately 30 min, each subject received a 20-mCi (740-MBq) intravenous injection of tracer while they were still lying down in the same quiet darkened room.

Scan Procedure

SPECT scanning commenced 1 hr after tracer administration using a dual-headed gamma camera with a 12-mm FWHM resolution collimator. Standard head positioning was based on uniform alignment of the external auditory meatus using automated table positioning and camera-to-head-detector ratio values. Imaging of radiotracer distribution was achieved in a 35-min acquisition. The radius of rotation was kept as small as possible, between 14 cm and 18 cm. Each detector head acquired 64 projections, for 30 sec each, over 180°, providing a total of 128 images over 360°, which generated a 64 × 64 × 64 three-dimensional pixel matrix. Tomographic images were reconstructed from the three-dimensional 64 × 64 × 64 matrix in the transverse plane using filtered backprojection algorithms with a Butterworth filter, using a Nyquist frequency cutoff of 0.5 and order of 5. The volume images

Received Dec. 18, 1997; accepted Mar. 10, 1997.

For correspondence or reprints contact: James C. Patterson, MD, PhD, Department of Psychiatry, Clinical Research Center, The University of Texas Medical Branch, 301 University Boulevard, Route 0428, Galveston, TX 77555-0428.

TABLE 1
Demographic Subjects

	Group	
	^{99m} Tc-HMPAO	^{99m} Tc-ECD
Total no. of subjects	35	55
Sex		
Male	11	18
Female	24	37
Age (yr)	31 ± 7	30 ± 6
Race		
Black	10	25
White	14	20
Hispanic	8	7
Asian	2	3
Other	1	0
Handedness	3 L, 32 R	4 L, 51 R

L = left; R = right.

of transverse slices were then attenuation corrected, and the images were transferred to a SUN Sparcstation 20 for further processing.

Image Formatting

All subsequent image manipulation and data analysis were performed on a SUN Sparcstation 20 running Openwindows version 3.3. The software for image manipulation includes Matlab (Mathworks, Inc., Natick, MA), SPM (6,7) and Analyze. Trans-

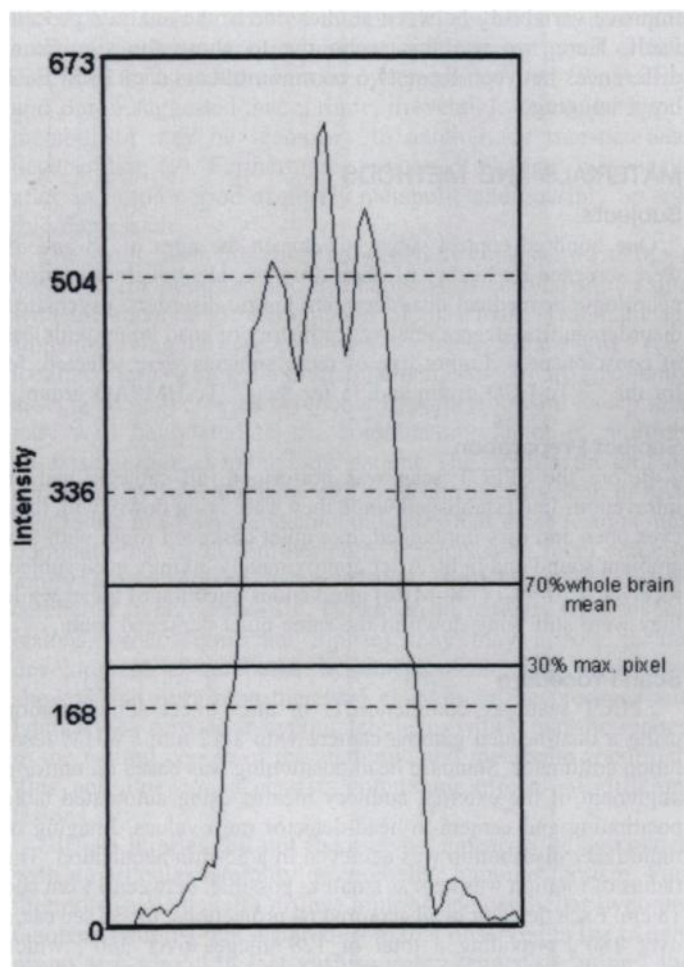


FIGURE 1. Line profile through a transverse slice of a SPECT image. This graph demonstrates the relationship of the 30% maximum pixel and the 70% whole-brain mean values with an image cross-section. The maximum pixel value varies slightly from image to image and is used as a first approximation to establish a whole-brain mean.

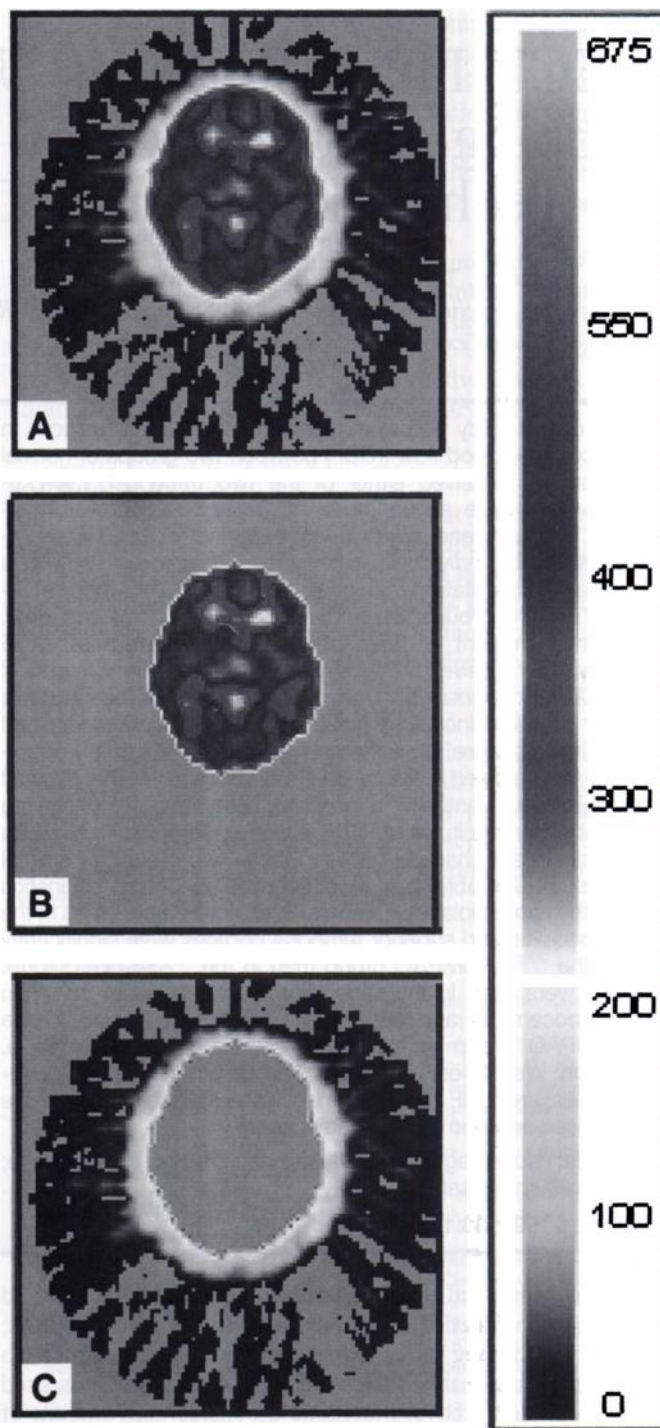


FIGURE 2. Example of SPECT image slice, pre- and post-thresholding. (A) Image slice after smoothing 6 mm but before thresholding. (B) Post-thresholding. (C) Subtracted image (A - B = C). This level of thresholding removes halo and partial volume error as much as possible while preserving brain signal.

verse slice image volumes from nuclear medicine were made compatible with Analyze and SPM by the creation of usable headers for the images in Analyze. Briefly, a file was created for each image that contained data regarding image size, number of slices, pixel depth (i.e., 16-bit), maximum pixel value and voxel size. Image intensity was then smoothed in SPM over a 6-mm³ volume to eliminate high spatial frequency noise. Whole-brain mean pixel intensity values were obtained in Analyze by the placement of a region of interest around the brain image, with the region of interest trace based on 30% of the maximum pixel value.

Apparent Decreases in Brain Perfusion of Subjects in ^{99m}Tc -HMPAO Group (^{99m}Tc -HMPAO < ^{99m}Tc -ECD)

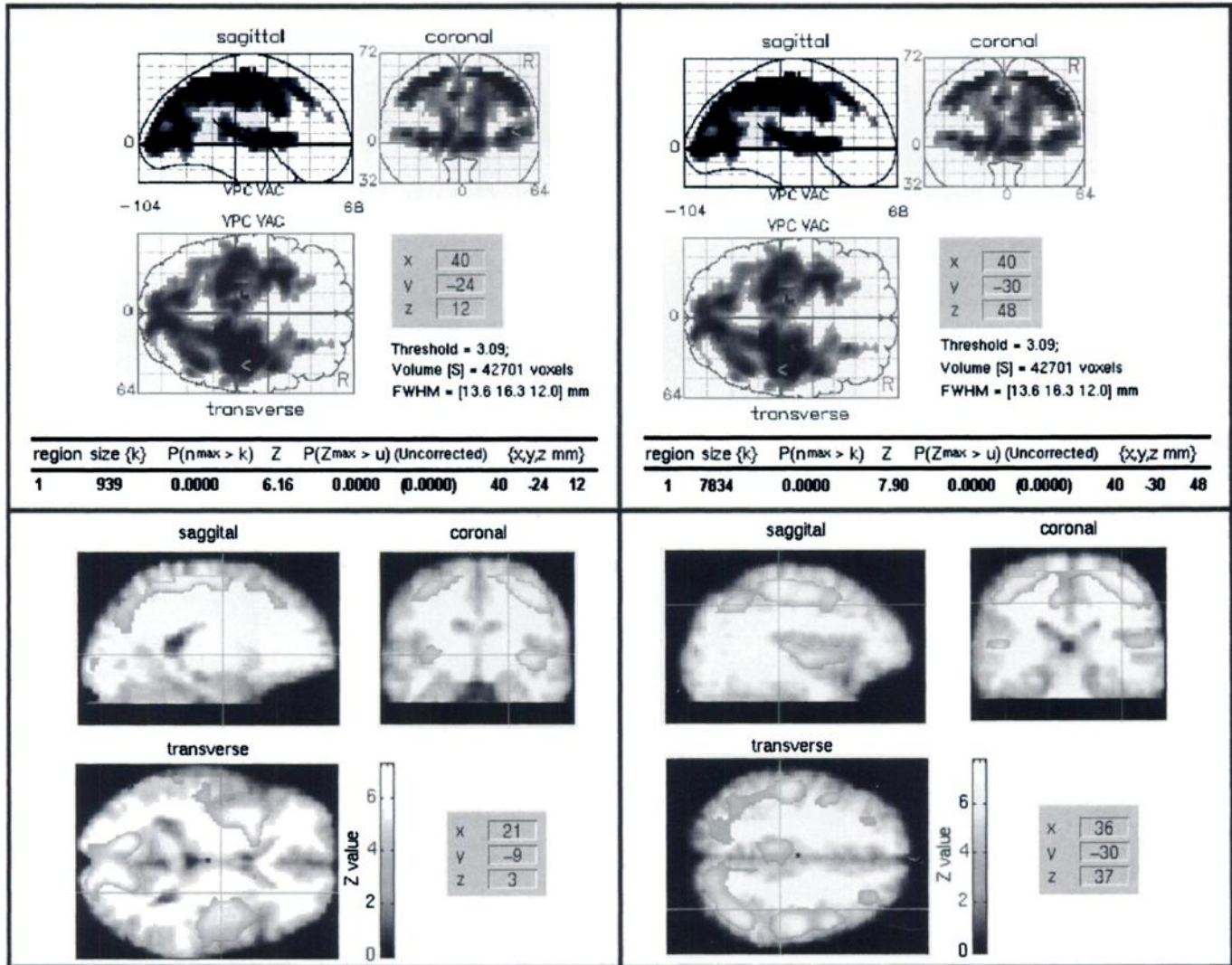


FIGURE 3. Apparent decreases in brain perfusion of normal subjects in ^{99m}Tc -HMPAO group (^{99m}Tc -HMPAO < ^{99m}Tc -ECD). Numerous large areas are seen in the parietal, occipital and superior temporal cortical areas, whereas no significant changes are seen in the frontal or lower temporal cortical areas. The top panel shows a three-way "glass brain" view of all the apparent decreases seen, whereas the bottom view shows the changes seen in the three slices of a given set of coordinates.

All brain image slices were then sampled and averaged to arrive at a mean pixel intensity value for that image. Image thresholding was performed in the Analyze 2D Morphology subroutine. The intensity threshold was set at 70% of the whole-brain mean. This eliminated low-intensity background noise inherent in the images and effectively removed brain-edge "halo" due to partial volume error, without losing any image data that were specific to the brain. This was absolutely necessary for accurate spatial normalization. The images were then spatially normalized in SPM to a standardized stereotactic space based on the Talairach and Tournoux atlas (8), using 12-parameter linear affine normalization algorithms. The normalization routine also included further smoothing, to a total of 12 mm. This corresponds to the resolution (12 mm FWHM) of the SPECT scanner. The initial image parameters were $64 \times 64 \times n$, where n = number of slices (varied from 25 to 35). They were 16-bit images with a voxel size of 5.1 mm (3). The final image format is 16-bit, with a size of $65 \times 87 \times 26$, voxel size $2 \times 2 \times 4$ mm.

Image Analysis

Data analysis was done using the program SPM. Statistical parametric maps are spatially extended statistical processes that were used to characterize regionally specific effects in imaging data. Statistical parametric mapping combines the general linear model (to create the statistical map or SPM) and the theory of Gaussian fields to make statistical inferences about regional effects (9,10). To examine images for specific regions of differences in perfusion between the two groups, the two groups were compared using contrasts. The first contrast examined areas of increased perfusion in one group, as compared to the other group, and the second contrast examined areas of decreased perfusion. The analysis included changes in global intensity levels between SPECT images as a confounding covariate. The resulting set of values for each contrast constituted a statistical parametric map of the t statistic $\text{SPM}\{t\}$. The $\text{SPM}\{t\}$ maps were then transformed to the unit's normal distribution ($\text{SPM}\{Z\}$) and thresholded at 3.09 (or $p = 0.001$, uncorrected). The resulting regions were then

Apparent Increases in Brain Perfusion of Subjects in ^{99m}Tc -HMPAO Group (^{99m}Tc -ECD < ^{99m}Tc -HMPAO)

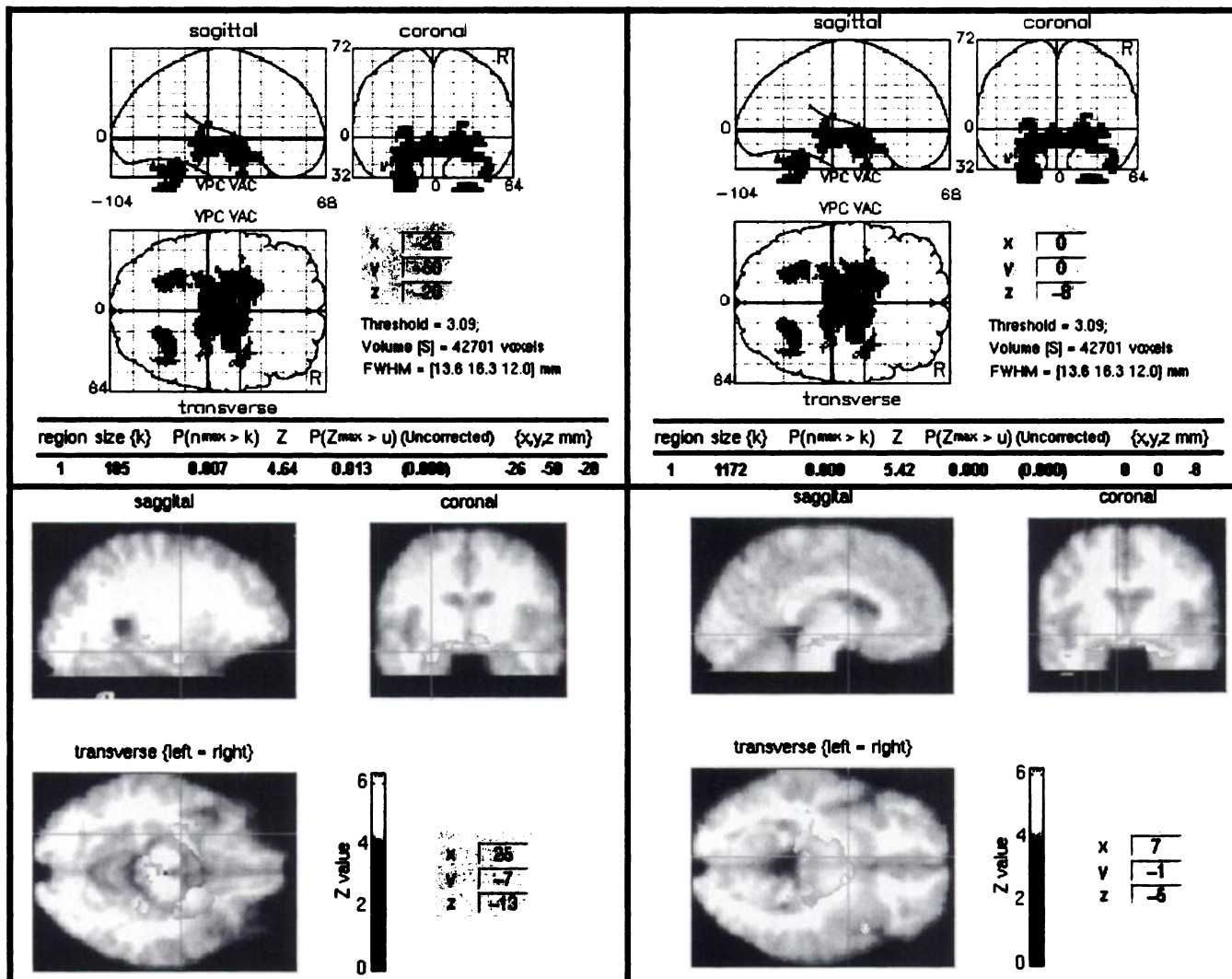


FIGURE 4. Apparent increases in brain perfusion of subjects in ^{99m}Tc -HMPAO group (^{99m}Tc -ECD < ^{99m}Tc -HMPAO). These areas include some brain stem areas and subcortical nuclei, as well as small areas of the hippocampus and cerebellum.

examined in terms of size (k) and peak height (u). The significance of each region was estimated using distributional approximations from the theory of Gaussian fields. This indicates the probability that a region of the observed number of voxels (or bigger) could have occurred by chance [$p(n_{\max} > k)$] or that the peak height observed (or higher) could have occurred by chance [$p(Z_{\max} > u)$] over the entire volume analyzed (i.e., a corrected p value). These areas of significance were best visualized as overlaid on a normalized magnetic resonance image to obtain a clear view of the location of the perfusion changes.

RESULTS

Data Analysis

Table 1 shows the demographics of the two groups of subjects. These subjects were well-matched for age, sex and race, as well as handedness. Figure 1 is a line profile graph demonstrating the relationship of the 70% whole-brain mean threshold to the overall brain intensity and the 30% maximum pixel value. The 30% maximum pixel value is too variable from image to image to use as a good threshold; therefore, it is used

as a first approximation to achieve a whole-brain mean value. Figure 2 shows an example of this threshold in a single slice. Figure 2C shows the results of subtracting Figure 2B from Figure 2A. The signal within the interior of the brain that is lower than the threshold is retained by a closure subroutine in the Analyze program package. The thresholding demonstrated here is crucial to achieving good spatial normalization within the program SPM, which is in turn necessary for objective analysis of groups of images.

Differences between the Two Groups

Because both groups are "normal," the apparent changes in perfusion shown here are given with respect to the ^{99m}Tc -ECD group as the reference group. It should be noted that the apparent increase in one group could just as easily be characterized as an apparent decrease in the other group. Regardless of the way the data are examined, the direction of the change is the same.

Apparent large changes were evident in the ^{99m}Tc -HMPAO group. These changes consisted of both areas of apparent increase and decrease (Figs. 3 and 4). The parietal, occipital and

superior temporal cortical areas were significantly lower bilaterally than in the group ^{99m}Tc -ECD, whereas some subcortical areas appeared to be higher. These subcortical changes were actually in a fairly limited area, including parts of the brain stem, subcortical nuclei, hypothalamus and smaller areas of the hippocampus and cerebellum. There were no apparent differences in the frontal lobes or the majority of the temporal cortices.

DISCUSSION

These data show that there are quantitative differences between the two radiotracers ^{99m}Tc -ECD and ^{99m}Tc -HMPAO. The differences in pharmacokinetics between the two tracers could be causing the significant changes seen in this study. Technetium-99m-ECD shows a more linear relationship between rCBF and tracer uptake (2), and thus, back-diffusion of this tracer is not as significant. This could be the causal factor of the large, numerous areas of apparently decreased flow of some cortical areas in the ^{99m}Tc -HMPAO group as compared to the ^{99m}Tc -ECD group. However, there are smaller areas of apparent increase in the ^{99m}Tc -HMPAO group. These areas are mainly subcortical within the brain stem and subcortical areas, but, still one would expect a decrease if the differences in pharmacokinetics were the only operating variable. Another possibility does exist, however. The enzymatic conversion of ^{99m}Tc -ECD from a lipophilic form to a hydrophilic form is processed by an enzyme or enzymes that are, apparently, evenly distributed in the brains of monkeys (11). It is possible that, at least in humans, a difference (albeit speculative) in enzyme levels exists between the cortex and these brain areas. This same difference in enzyme levels could putatively explain why there are changes in some parts of the cortex but not in others. The fact that there are no differences seen in the white matter correlates well with research that shows no difference in the steady-state influx constants between the two tracers in the white matter (0.23 ± 0.01 compared to 0.23 ± 0.02), whereas the gray matter constants were different (0.32 ± 0.03 for ^{99m}Tc -HMPAO compared to 0.35 ± 0.04 for ^{99m}Tc -ECD) (4).

CONCLUSION

Although these data are significant, in part due to the large number of participants, it seems possible that the two tracers

could be read differently by a radiologist not experienced enough to know the apparent differences between them. Although it is not immediately apparent that comparison of a single individual's brain, in a side-by-side comparison of these two tracers, would show any large differences, it does seem that large differences are present at the group level. Future work in this laboratory will concentrate on examining the differences between individuals that were scanned with both tracers (at different times) and exploring the possible clinical utility of using SPM to examine rCBF changes in single subjects as compared to controls.

ACKNOWLEDGMENTS

This research was supported by Department of Health and Human Services Grant 5R29 MH48196-03-04. Portions of the research presented here were also presented at the 43rd Annual Meeting of the Society of Nuclear Medicine, held June 3–5, 1996, in Denver, CO.

REFERENCES

1. Greenberg JH, Lassen NA. Characterization of ^{99m}Tc -bicisate as an agent for the measurement of cerebral blood flow with SPECT. *J Cereb Blood Flow Metab* 1994;14(suppl 1):S1–S3.
2. Friberg L, Andersen AR, Lassen NA, Holm S, Dam M. Retention of ^{99m}Tc -bicisate in the human brain after intracarotid injection. *J Cereb Blood Flow Metab* 1994;14(suppl 1):S19–S27.
3. Leveille J, Demonceau G, Walovitch RC. Intrasubject comparison between technetium-99m-ECD and technetium-99m-HMPAO in healthy human subjects. *J Nucl Med* 1992;33:480–484.
4. Pupi A, Castagnoli A, DeCristofaro MTR, Bacciottini L, Petti AR. Quantitative comparison between ^{99m}Tc -HMPAO and ^{99m}Tc -ECD: measurement of arterial input and brain retention. *Eur J Nucl Med* 1994;21:124–130.
5. Matsuda H, Li YM, Higashi S, et al. Comparative SPECT study of stroke using ^{99m}Tc -ECD, ^{123}I -IMP and ^{99m}Tc -HMPAO. *Clin Nucl Med* 1993;18:754–758.
6. Friston KJ, Ashburner J, Poline JB, Frith CD, Heather JD, Frackowiak RSJ. Spatial realignment and normalization of images. *Hum Brain Mapping* 1995;2:165–189.
7. Friston KJ, Holmes AP, Worsley KJ, Poline JB, Frith CD, Frackowiak RSJ. Statistical parametric maps in functional imaging: a general approach. *Hum Brain Mapping* 1995;2:189–210.
8. Talairach J, Tournoux P. *Co-planar stereotactic atlas of the human brain*. Stuttgart: Thieme;1988.
9. Friston KJ, Frith CD, Liddle PF, Frackowiak RSJ. Comparing functional (PET) images: the assessment of significant change. *J Cereb Blood Flow Metab* 1991;11:690–699.
10. Friston KJ, Worsley KJ, Frackowiak RSJ, Mazziotta JC, Evans AC. Assessing the significance of focal activations using their spatial extent. *Hum Brain Mapping* 1994;1:214–220.
11. Walovitch RC, Hill TC, Garrity ST, et al. Characterization of technetium-99m-L,L-ECD for brain perfusion imaging. Part 1: pharmacology of technetium-99m-ECD in nonhuman primates. *J Nucl Med* 1989;30:1892–1901.