

to estimate the number of projections required gives $N = \pi \cdot 200 / (16/2)$, approximately 78 projections over 360° or half that number over 180° . This suggests that the number of projections should be greater than the 32 commonly used, although use of 64 projections over 180° is overkill (48 angles might be considered ideal). Note that the number of angles has no direct relationship to the matrix size chosen or zoom factor used for either acquisition or reconstruction, contrary to some authors' discussions (2-5).

- For brain studies, the region of diagnostic interest tends to be located centrally. Therefore, in this case, the value for D does correspond to the dimension of the brain, typically 160 mm. Reconstructed resolution for brain studies is significantly better than that for cardiac studies and can be as low as 8 mm. Therefore, with a camera of 400-mm field size, a 128×128 matrix size is required to preserve resolution. The number of angles required is $N = \pi \cdot 160 / (8/2)$, approximately 125 angles over 360° . This is consistent with common practice. Note again that this is independent of the matrix size chosen; a zoomed acquisition using a smaller matrix size still requires the same number of projection angles.

The choice of angular sampling is frequently misunderstood and rarely appreciated. The discussion and illustration presented here, although intuitive, appears consistent with more rigorous descriptions and should assist readers in deciding what protocols are appropriate for any applications.

REFERENCES

- Rosenthal MS, Cullom J, Hawkins W, Moore SC, Tsui BMW, Yester M. Quantitative SPECT imaging: a review and recommendations by the focus committee of the Society of Nuclear Medicine Computer and Instrumentation Council. *J Nucl Med* 1995;36:1489-1513.
- Bracewell RN, Riddle AC. Inversion of fan-beam scans in radio astronomy. *Astrophys J* 1967;150:427.
- Snyder DL, Cox JR. An overview of reconstruction tomography and limitations imposed by a finite number of projections. In: *Reconstruction tomography in diagnostic radiology and nuclear medicine*. University Park Press; 1977:3.
- Huesman RH. The effects of a finite number of projection angles and finite lateral sampling of projections on the propagation of statistical errors in transverse section reconstruction. *Phys Med Biol* 1977;22:511-521.
- Larsson SA. Gamma camera emission tomography. *Acta Radiol* 1980;363(suppl):21-22.
- Bailey DL, Parker JA. Single-photon emission computerized tomography. In: Murray IPC, Ell PJ, eds. *Nuclear medicine in clinical diagnosis and treatment*, vol. 2. Edinburgh: Churchill Livingstone; 1994:1315-1326.

Brian Hutton
Westmead Hospital
Sydney, Australia

Carbon-14-Urea Breath Test: A Cautionary Note

TO THE EDITOR: We currently perform about 75 ^{14}C -urea breath tests annually based on the method of Marshall and Surveyor (1). Our experience with this test has highlighted the significance of fasting before the study. The paper by Marshall et al. (2) discusses the different results obtained between patients who fasted and those who ate a test meal. Our concern relates to clinicians using a reference range based on fasting patients, who may not be rigorous in their application of this fasting criterion.

Although our procedure for ^{14}C -urea breath testing involves informing the patient to fast (at least 6 hr) and confirming that the patient did indeed fast before the test commences, there are instances when this routine is not followed. On two occasions, patients started the test without fasting. These patients underwent a repeat study after fasting; the results from the second study are shown in Table 1.

We measure the $^{14}\text{CO}_2$ at 5-min intervals for 30 min and calculate the peak value after 10 min as: % dose/mmol $\text{CO}_2 \times$ body weight. We also measure the area under the curve after 10 min.

Both patients would have had equivocal or normal results because the test values were affected by the presence of food in their stomachs. Their

TABLE 1
Results for Carbon-14-Urea Breath Test before and after Fasting

Patient no.	Nonfasting		Fasting	
	Peak value	Area under curve	Peak	Area under curve
1	1.26	20.4	3.29	55.2
2	0.84	13.8	2.5	42.0

Our fasting reference ranges were: <0.5 normal; 0.5-1.5 equivocal; >1.5 positive for peak value; and 0-16 normal; 16-25 equivocal; >25 positive for the area under curve.

fasting values, however, were both positive for *Helicobacter pylori*. Unfortunately, there were no other follow-up tests performed to verify our results and, hence, the presence of *H. pylori*. The significant elevation of the fasting values warrants careful examination of the fasting state of each patient.

REFERENCES

- Marshall BJ, Surveyor I. Carbon-14-urea breath test for the diagnosis of *Campylobacter pylori* associated gastritis. *J Nucl Med* 1988;29:11-16.
- Marshall BJ, et al. A 20-minute breath test for *Helicobacter pylori*. *Am J Gastroenterol* 1991;86:4:438-445.

T. Warwick
Sir Charles Gairdner Hospital
Nedlands, Western Australia

Which Is Better for Inferior Wall Evaluation: A Full or Empty Stomach?

TO THE EDITOR: Technetium-99m-tetrofosmin, recently introduced as an agent for myocardial perfusion imaging, is excreted mainly by the biliary system (1). High intestinal activity may be seen in a one-day imaging protocol. This intestinal activity may create a major problem in the visual interpretation of the inferior myocardial wall, especially in the rest imaging.

In the study of Braat et al. (2), the inferior wall of myocardium was considered ischemic in three patients by at least two of the three different observers in the one-day protocol while in the two-day protocol, the same region was defined as scar tissue by the observers. The explanation for this discrepancy was proposed to be scatter from the abdominal and hepatic background to the inferior wall of the myocardium.

In our early studies with $^{99\text{m}}\text{Tc}$ -tetrofosmin, we told patients to have their normal meal 45-60 min before rest imaging. Imaging starts 20-30 min after injection and patients are advised to drink 200-300 cc water

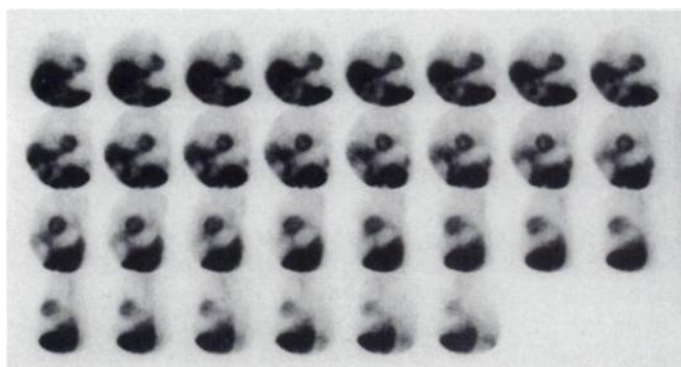


FIGURE 1. Raw data of rest myocardial SPECT image 20 min after an intravenous dose of 20 mCi of $^{99\text{m}}\text{Tc}$ -tetrofosmin. The patient was allowed to have his daily meal 1 hr before injection. Filled stomach appears as a photopenic area between myocardium and intestines in the frames.