Mammary Lymphoscintigraphy in Breast Cancer

Roger F. Uren, Robert B. Howman-Giles, John F. Thompson, David Malouf, George Ramsey-Stewart, Frederick W. Niesche and Stuart B. Renwick

Nuclear Medicine and Diagnostic Ultrasound, Camperdown, Australia; and Department of Surgical Oncology, Royal Prince Alfred Hospital, Sydney, New South Wales, Australia

Lymphoscintigraphy has previously been used to define lymph drainage patterns and locate sentinel lymph nodes, prior to surgery, in patients with cutaneous melanoma. The aim of this study was to apply this technique to patients with breast cancer using intramammary injections placed around the primary tumor in the breast. **Methods:** Lymphoscintigraphy using ^{99m}Tc-labeled antimony sulphide colloid was performed in 34 patients with a suspected primary breast cancer. Images were recorded immediately and at 2.5 hr using a LFOV digital gamma camera. Sentinel lymph node location was marked when possible. **Results:** Lymphatic drainage patterns were successfully recorded in all but three patients. Lymph drainage was to the axillary, internal mammary, supraclavicular and, in one patient, infraclavicular node fields in various combinations but always on the same side of the body as the breast tumor. There was unexpected drainage across the center line of the breast to axillary or internal mammary nodes in 32% of patients with inner or outer quadrant lesions. Direct drainage to supraclavicular or infraclavicular nodes occurred in 20% of upper quadrant lesions. Drainage to the ipsilateral axilla occurred in 85% of patients, where a single sentinel node was seen in all cases. **Conclusion:** Intramammary lymphoscintigraphy can be used to define the lymphatic drainage patterns of individual breast cancers. The surface location of sentinel lymph nodes in the draining node fields can be marked and in the axilla their depth can be measured. It should therefore be possible to use lymphoscintigraphy, along with a blue dye injection technique or the gamma probe at surgery, to locate sentinel lymph nodes in patients with breast cancer.

Key Words: lymphoscintigraphy; breast cancer; sentinel lymph nodes

J Nucl Med 1995; 36:1775–1780

Cutaneous lymphoscintigraphy has been used for many years in patients with melanoma to evaluate lymphatic drainage patterns prior to surgical resection of the lymph nodes (*1–3*). We have been performing lymphoscintigraphy in this role for the last 8 yr and like others have documented great variation in lymph drainage patterns from patient to patient (*4*). We have also found that lymphoscintigraphy can be used to locate the sentinel lymph nodes in patients with melanoma (*5*). Lymphoscintigraphy has previously been used in patients with breast cancer but usually either in an attempt to identify metastases in the axillary nodes (*6*) or to locate internal mammary nodes for radiation treatment planning (*7*). The aim of the study was to map the lymphatic drainage pattern from the actual tumor site in each patient, to mark any interval nodes occuring in the breast tissue and to observe whether sentinel node(s) could be detected in each drainage node group.

MATERIALS AND METHODS

Patients

Thirty-four patients were examined (32 women, 2 men) (Table 1). All patients had suspected primary breast cancer and were to undergo partial mastectomy or radical mastectomy after lymphoscintigraphy. Technetium-99m-antimony sulphide colloid (^{99m}Tc-Sb2S3) was prepared onsite for each patient using kits supplied by the Royal Adelaide Hospital radiopharmacy. Particle size varied from 3 to 12 nm (*8,9*).

Technetium-99m was supplied on a daily basis and was produced in the nuclear reactor at Lucas Heights in Sydney. Four small volume (0.05–0.1 ml) injections were used to surround the primary lesion. A 1-ml tuberculin syringe was used for each injection with the small volume of tracer, followed by 0.05 ml of air in the syringe, to ensure delivery of an exact amount of tracer at each injection site.

After skin preparation, the injections were given using a 25-gauge long-bore needle to ensure minimum trauma to the breast tissue and were placed at the 12, 3, 6 and 9 o'clock positions surrounding the breast mass and at the same depth as the mass. In this way, the injectate was placed within 2–3 mm of the margin of the tumor. The exact location and depth of the tumor were determined in each patient using high-resolution ultrasound in the injection room. The 25-gauge long-bore needle was advanced to the exact depth as determined on ultrasound.

All studies were performed prior to excision of the tumor. Specific activity of the dose varied from 50 to 70 MBq/ml so that each injection contained 2.5–7 MBq. The four injections used in each case delivered a radiation dose of less than 0.05 Sv to each injection site. This injection site was completely excised within 1 wk in all patients as part of their planned surgical treatment. Careful technique was required to ensure that the injections were made immediately adjacent to the tumor and that contamination of the skin was avoided. To aid in preventing skin contamination, a large waterproof incontinence sheet was used to cover the

Received Dec. 29, 1994; revision accepted Jun. 7, 1995.

For correspondence or reprints contact: Roger F. Uren, Nuclear Medicine and Diagnostic Ultrasound, Suite 7, Missenden Medical Centre, 54-60 Briggs St., Camperdown, NSW 2050, Australia.

TABLE 1
Patient Characteristics

Patient no.	Lesion site	Node fields	Lymph channels
1	IUOQ	la,lim,lsc	0
2	IUOQ	la	0
3	IUOQ	la	0
4	IUOQ	la	1
5	IUOQ	la,lim,lsc	0
6	IUOQ	la	0
7	IUOQ	la,lic	0
8	IUIOQ	la,lsc,lim	1
9	IUIOQ	la	0
10	IUIOQ	la	0
11	IUIOQ	0	0
12	IULOQ	la,lim	0
13	IBN	la	0
14	IBN	la	0
15	IUIQ	lim	0
16	IUIQ	0	0
17	IULIQ	la	0
18	ILOQ	la,lim	1
19	ILIQ	la,lim	0
20	ILIOQ	la	0
21	rUOQ	ra	0
22	rUOQ	ra	0
23	rUOQ	ra	1
24	rUOQ	ra,rim	2
25	rUIOQ	ra,rim	1
26	rUIOQ	ra,rim,rsc	0
27	rUIOQ	ra,rim	0
28	rUIQ	rim	0
29	rULOQ	ra	0
30	rLIQ	0	0
31	rLOQ	ra	1
32	rLOQ	ra	0
33	rLOQ	ra	0
34	rLOQ	ra	0

I = inner; U = upper; L = lower; O = outer; BN = behind nipple; ra = right axilla; la = left axilla; rim = right internal mammary; lim = left internal mammary; rsc = right supraclavicular; lsc = left supraclavicular; lic = left infraclavicular; 0 = not visualized.

patient's trunk and a window was cut in the sheet to expose the breast.

All scans were obtained using a large rectangular field of view digital gamma camera with a low-energy, high-resolution collimator. Each scan view was collected over 10 min. Scanning was commenced immediately to detect any major lymph channels. The digital camera enabled image enhancement to reveal even the faintest channels. Delayed scans were obtained routinely at 2.5 hr postinjection. At this time, an anterior view of the chest and axillary area was acquired. Lateral or oblique views were obtained, if necessary, to define the anterior or posterior position of a node in the axilla or to clarify unusual drainage patterns. Any discernible activity above background in recognized node groups was regarded as a positive finding on the delayed scans. Interval nodes were believed to be present if focal uptake along one of the lymph channels or in the breast tissue in the early scan was seen as a persisting focal area of uptake in the same spot on the delayed scans. For several patients who had no uptake or only faint nodal uptake at 2.5 hr, repeat scans were obtained 4 hr postinjection.

The skin overlying the sentinel node in the axilla was marked with an indelible pen. This procedure has been described elsewhere (*5*) and was performed with the patient in the normal position for surgery. The sentinel node was the first of the draining lymph nodes to accumulate tracer; in the delayed images it was the node with the most activity, as there was significant holdup of the colloid particles in the lymph nodes. For axillary node imaging, the patient was supine with the arm at right angles to the body. The surface location of any nodes seen in the internal mammary chain or supraclavicular node group was also marked. The depth of the sentinel node in the axilla was determined in most patients.

Blue dye was injected around the breast tumor prior to surgery in three patients and an attempt was made to locate any stained axillary sentinel nodes.

RESULTS

Lymph Drainage Patterns

Eighteen patients had a tumor entirely within the outer quadrant and 6 had a tumor entirely within the inner quadrant. Definite drainage to the internal mammary lymph nodes was seen in 3 of 11 upper outer quadrant lesions, 1 of 5 lower outer quadrant lesions and 1 of 2 lesions at the junction of the upper and lower outer quadrants (Table 2). Two of the six patients with inner quadrant lesions showed drainage to the axilla. Two patients showed no drainage on lymphoscintigraphy, and the remaining two patients had drainage to the internal mammary nodes.

Eight patients had tumors extending into the inner and outer quadrants of the breast and two patients had lesions directly behind the nipple. Four of 24 patients with upper quadrant lesions had direct drainage to supraclavicular nodes and one had drainage to an infraclavicular node. No lower quadrant lesions drained to supraclavicular nodes. The two patients with lesions behind the nipple showed drainage only to the axilla.

Eighteen of the 34 patients had drainage only to the axilla, 2 had drainage to internal mammary nodes only, 6 had drainage to the axilla and internal mammary nodes, 4 had drainage to the axilla, internal mammary and supraclavicular nodes, 1 had drainage to the axilla and an infraclavicular node and 3 had no movement of tracer. Two of the latter patients had inner quadrant tumors. One patient with a right lower inner quadrant tumor had had a previous mastectomy for cancer in her other breast and had metastases in the chest wall as well as a palpable lump in the right axilla. Lymphoscintigraphy detected drainage to the axilla in 29 of 34 patients.

Lymph Channels

Seven patients had clear lymph channels in the early dynamic study; one patient had two dominant channels, each passing to a different node field.

Interval Nodes and Sentinel Nodes

An intramammary interval node was seen in one patient. There was only a single sentinel node seen in the axilla in the 29 patients with axillary node drainage. We were able to mark the surface location of the sentinel node in the

TABLE 2
Lymphatic Drainage Patterns in Different Breast Quadrants

Breast quadrant	Number of patients	Node fields			
		Axilla	Internal mammary	Supraclavicular	Infraclavicular
Upper/Outer	11	11	3	2	1
Upper/Inner outer	7	6	4	2	1
Upper inner	3	—	2	—	—
Behind nipple	2	2	—	—	—
Upper/Lower outer	2	2	1	—	—
Upper/Lower inner	1	1	—	—	—
Lower outer	5	5	1	—	—
Lower inner	2	1	1	—	—
Lower inner/Outer	1	1	—	—	—

axilla in all of these patients and determine its depth in the 23 patients in whom this measurement was attempted. The depth of the sentinel node in the axilla varied from 2 to 8 cm (mean 3.5 cm) from the skin surface. Of the nine patients with internal mammary drainage who had nodes marked, the number of nodes varied from one to six with an average of two. In the supraclavicular node group, one patient had two sentinel nodes, whereas the others all had one sentinel node. One sentinel node was seen in the infraclavicular node field.

In the three patients who had blue dye injected prior to surgery, the sentinel node was located in each case. In two of the three patients, the sentinel node was positive for metastases and in the third patient all of the axillary nodes were negative for metastases. One of the positive cases was the patient who had an intramammary interval node, which was found at surgery and was almost completely replaced by tumor. Axillary dissection demonstrated 1/22 positive nodes. Eventual node status in these three patients was 2/23, 8/14 and 0/11 positive nodes, respectively.

DISCUSSION

There have been many previous studies reporting the use of lymphoscintigraphy in patients with breast cancer. These have included axillary lymphoscintigraphy, internal mammary and mammary lymphoscintigraphy. Axillary lymphoscintigraphy has been used in the preoperative search for nodal metastases in the axilla (*6,10*) or to assess the completeness of axillary dissection postoperatively (*11*) or intraoperatively (*12*). Internal mammary lymphoscintigraphy has been used in attempts to diagnose nodal metastases (*13*) and to locate the internal mammary nodes for radiation treatment planning (*7,14*).

Studies using mammary lymphoscintigraphy comprised a variety of techniques, including intratumoral injection (*15,16*), intramammary injection (*17*), periareolar (*18*), subareolar (*19*), intradermal (*20*) and subperiosteal injection (*21*). The aim of these studies was to diagnose nodal metastases. Saeki et al. (*17*) did attempt to map flow patterns in their 12 patients, but it is not clear if intramammary injections were given. Terui et al. (*21*) also sought to locate draining lymph nodes and diagnose metastases in 100 patients, but the tracer injections were subperiosteal and thus probably did not actually map the lymph drainage patterns of the breast tumors. Matsubara et al. (*20*) examined drainage patterns in their patients, but they used an intradermal injection of the tracer and found frequent drainage to the contralateral as well as the ipsilateral axilla. This observation is to be expected based on our results using lymphoscintigraphy in patients with cutaneous melanoma (*4*), but the relevance to lymph drainage patterns from tumors within breast tissue is doubtful. Moreover, Matsubara et al. studied patients after excision of the primary tumor, which may have disrupted lymphatic drainage patterns.

Our goal was to adapt the lymphoscintigraphy method we previously developed to study patients with melanoma (*4,5*). Our original work was stimulated by the surgical approach to the sentinel node described by Morton et al. (*22*) and we recently noted his group's successful application of that technique to patients with breast cancer (*23*). Our approach was to map the normal lymph drainage pattern surrounding the breast tumor in each patient. All of our studies were performed before excision of the tumor.

Lymph Drainage Patterns

In this preliminary work, we found quite different lymph drainage patterns, depending on the location of the breast tumor. The traditional concept of lymph drainage in the breast is that outer quadrant tumors drain to the axilla and inner quadrant lesions drain to the internal mammary nodes. In our patients, 28% of outer quadrant tumors showed unexpected drainage to the internal mammary nodes and 33% of inner quadrant tumors showed unexpected drainage to the axilla. Thus, 7 of 22 patients (32%) with an entirely inner or outer quadrant tumor had unexpected lymph drainage across the center line of the breast. In patients with upper quadrant tumors, 20% had direct drainage to supraclavicular or infraclavicular nodes. Because of the uncertain clinical relevance of these findings, it was not considered appropriate to modify the surgical management of the patients with unexpected drainage. The finding of drainage to the internal mammary nodes, however, did result in inclusion of these nodes in the field when the patients underwent radiotherapy.

We did not observe drainage from the lower quadrants to the supraclavicular or infraclavicular nodes. So far, we have only observed drainage to nodes on the same side of the body as the tumor. In the three patients who did not show migration of the tracer from the injection site, one had obvious chest wall metastases and a palpable metastasis in the ipsilateral axilla. The lymphatic channels may therefore have contained tumor, which may have affected tracer dynamics, as previously discussed by Giuliano et al. (*23*).

Lymph Channels

Only 21% of our patients had a clearly defined lymph channel in the early dynamic study (Fig. 1). This is in contrast to lymphoscintigraphy performed by intradermal injection around skin lesions, where dominant channels are almost always seen on the early scans, suggesting that the skin is more richly supplied with lymph channels than is breast tissue. The observation that 79% of patients had no movement of the tracer on the early image has important implications for surgeons using the gamma probe to locate the sentinel node in the axilla during surgery in breast cancer patients. All of our patients received ^{99m}Tc-antimony trisulphide colloid, which is the preferred tracer for lymphoscintigraphy. It has a small particle size of 3–12 nm, which allows rapid passage through the lymphatics but has good node retention. Our findings suggest that the peritumoral intramammary injections of this agent in breast cancer patients should be made at least 2–4 hr prior to surgery to ensure that all potential sentinel nodes will be detected by the gamma probe. Our results also suggest that agents such as ^{99m}Tc-sulphur colloid are unlikely to be satisfactory for either lymphoscintigraphy or gamma probe-guided surgery in the breast because the large particle size of 1 to 2 μm would mean poorer and slower movement through the lymphatics and visualization of fewer node fields and sentinel nodes.

The fact that we were unable to actually visualize channels meeting sentinel nodes in the majority of patients meant we had to assume that the node we eventually saw in the axilla was the true sentinel node. When there is only one node visualized in a node field, it seems reasonable to call this node the sentinel node. This was the case in many of of our patients with axillary drainage. Proof of this would require a blue-stained lymphatic to be seen entering the node following blue dye injection at surgery. This was only seen in three of our patients.

Interval and Sentinel Nodes

Only one intramammary interval node was seen in our patient group. Such nodes are not uncommonly seen at surgery and this experience differs significantly from our work with cutaneous lymphoscintigraphy in which interval nodes are often seen. It is, however, possible that the bloom of activity from the injection sites in the breast obscured other intramammary interval nodes with our lymphoscintigraphy technique. Interestingly, this intramammary node was located as a sentinel node in this patient and did contain metastases.

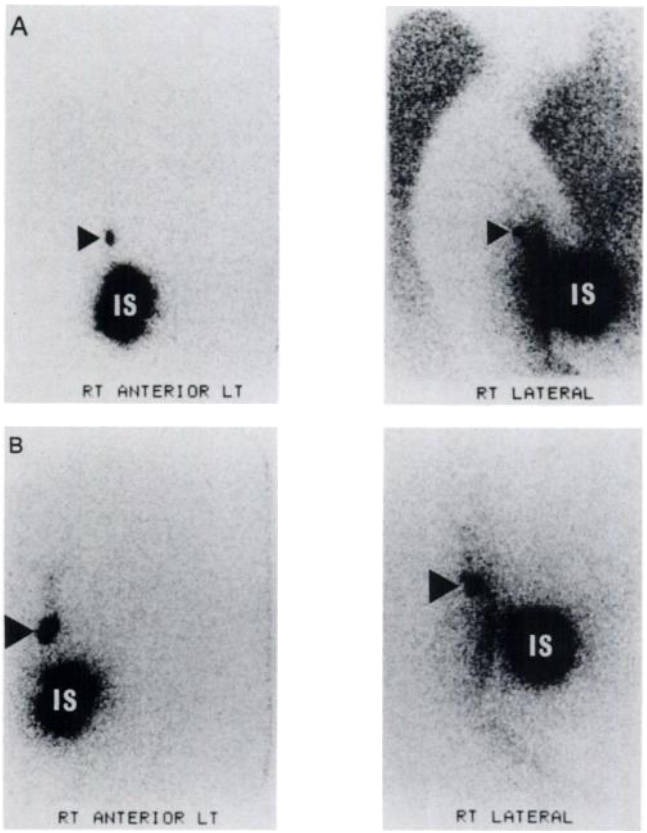

FIGURE 1. (A) In these scans from Patient 23 (Table 1), the injection site (IS) is clearly visualized and there is a dominant early lymph channel passing to a sentinel node in the right axilla in the anterior view (black arrowhead). In the right lateral view, a transmission source was used to demonstrate the relationship of the IS and activity in the sentinel node in the right axilla. There is some scatter off the anterior part of the right upper arm. (B) Delayed scans obtained 2.5 hr postinjection demonstrate activity in the right axillary sentinel node. There is no lymph drainage to other node fields. A small amount of tracer is visualized passing from the sentinel node into the subclavian chain. Scatter off the right upper arm is also demonstrated in the right lateral view.

Lymph drainage to the ipsilateral axillary node group occurred in 85% of patients, and lymphoscintigraphy visualized a single sentinel lymph node in each patient. Giuliano et al. (*23*) were able to identify axillary sentinel nodes in 78% of the last 50 patients they studied using intramammary blue dye injection to detect sentinel nodes in the axilla. This figure is similar to our incidence of axillary drainage. These data suggest that approximately 80%–85% of patients with breast cancer will have peritumoral lymph drainage to the axilla that can be detected by lymphoscintigraphy. If lymphoscintigraphy is combined with the blue-dye injection technique as we did for our patients with melanoma (*5*), it may be possible to accurately locate and biopsy the sentinel node or nodes during surgery. As Giuliano et al. (*23*) suggests, this may allow the axillary nodes to be adequately sampled for staging and prognostic purposes and simultaneously minimize the ex-

tent of axillary dissection. It may even prove possible to avoid axillary dissection altogether if lymphoscintigraphy fails to show any axillary drainage. We did not attempt extensive surgical correlation in our patients, but for the three patients who received the blue-dye technique, the sentinel node was located in each case and in the two patients with nodal metastases, the sentinel node was involved.

The presence of a single sentinel node in the axilla of each of our patients with drainage to this node field would suggest that gamma probe-guided surgery (*24*) may be useful. Other radiolabeled nodes in the axilla were often present, however, and not all radioactive nodes are sentinel nodes. Use of the gamma probe technique without prior lymphoscintigraphy and clearing the axilla of radioactivity at surgery would thus involve removing nonsentinel nodes unnecessarily. As previously mentioned, timing of the intramammary tracer injection prior to surgery is a critical factor and will have a significant effect on the number of nodes seen on lymphoscintigraphy or found with the gamma probe. Colloids with larger particle sizes, such as ^{99m}Tc-sulphur colloid, will migrate more slowly and again will influence the number of nodes visualized. Lymphoscintigraphy can also determine if there is drainage to the internal mammary nodes, the supraclavicular nodes or the infraclavicular nodes. The surface location of nodes in the internal mammary chain can be easily marked, but we were unable to determine the depth of these nodes because they were not visible in the orthogonal view (i.e., a lateral view), which is required to measure depth. The surface location of the supraclavicular nodes could also be readily marked, but, again, it was difficult to measure the depth of the nodes at this site.

SPECT may possibly help determine the depth of the nodes in the internal mammary and supraclavicular fields, but intense activity at the injection site would be a problem and we have not yet attempted this. Multiple lymph nodes were often visualized in the internal mammary chain, and the intensity of tracer accumulation in each node was often similar (Fig. 2). There thus appears to be a potential problem in determining which of the internal mammary nodes seen on delayed scans are actually sentinel nodes unless a channel is identified that leads to node detection on the early image. Such channels were only occassionally seen leading to internal mammary nodes. Clearly, the sentinel node or nodes in the internal mammary node field will be one or more of the nodes seen on the delayed scans, but, as previously mentioned, not all visualized nodes are sentinel nodes. For practical purposes, all nodes seen in the internal mammary node field must be considered as potential sentinel nodes. This was not a problem in the supraclavicular or infraclavicular node fields where a single sentinel node was seen in all but one patient.

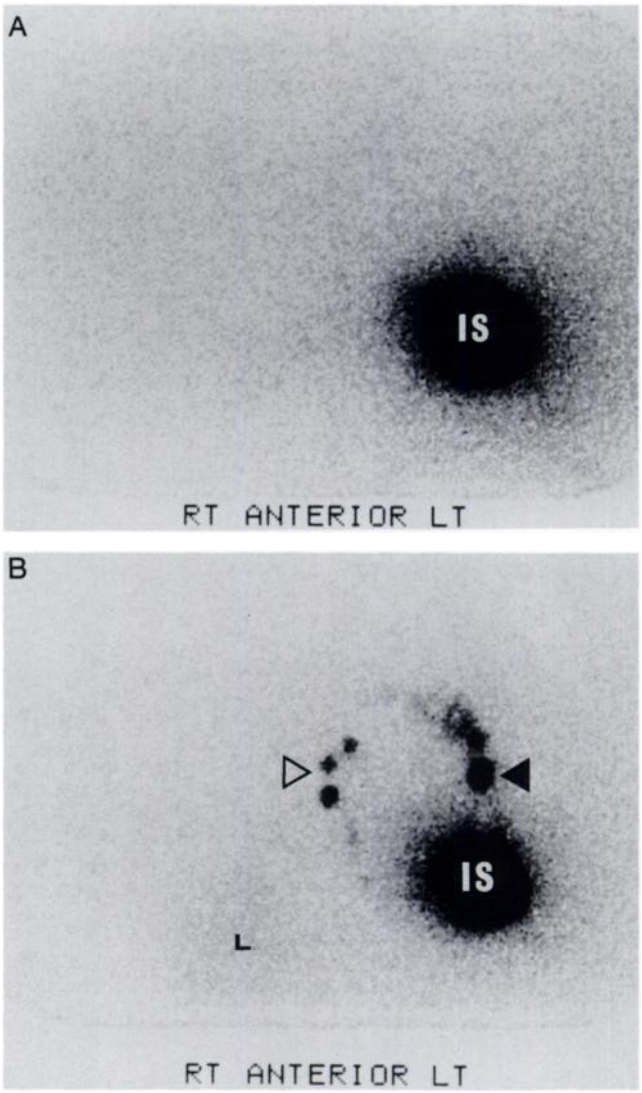

FIGURE 2. (A) Early image in the anterior view obtained immediately after tracer injection does not visualize any dominant channels or tracer movement. Only the injection site (IS) in the left breast is seen. (B) Delayed scan in the anterior view demonstrates activity at the IS, but tracer is also visualized in the sentinel lymph node in the left axilla (black arrowhead) and in several nodes in the left internal mammary lymph node field (open arrowhead). In the left axilla, activity is seen passing into the left subclavian lymph nodes. Faint activity is also present in the liver.

CONCLUSION

Lymphoscintigraphy of the breasts can be used to map lymphatic drainage in patients with breast tumors. The drainage pattern varies from patient to patient, depending on the tumor site and does not always follow expected routes. Lymph channels are less commonly visualized in the breast than in the skin. Sentinel nodes in the axilla can be located, which emphasizes the role of lymphoscintigraphy during surgical detection of the sentinel node in the axilla using a blue dye injection technique and also the gamma probe. Lymphoscintigraphy also identifies patients with lymph drainage to other node groups. The surface location of the sentinel node in the supraclavicular and

infraclavicular node groups can be marked, although it may be difficult to determine which nodes are actually sentinel nodes in the internal mammary node field when multiple nodes are seen on delayed scans.

The exact role of lymphoscintigraphy in sentinel node biopsy of the axilla in patients with breast cancer requires further study and several questions still need to be answered. Can axillary dissection be avoided in patients who do not show lymph drainage to the axilla? Can selective lymphadenectomy with sentinel node biopsy adequately stage the patient's breast cancer and give the needed prognostic information, thus reducing the morbidity from surgery in these patients? Does knowledge of lymph drainage to the internal mammary, supraclavicular or infraclavicular nodes alter the management of patients with breast cancer? These question can only be answered by studies with larger patient populations in which the scintigraphic results are correlated with surgical findings.

REFERENCES

1. Sullivan DC, Croker BP Jr, Harris CC, Deery P, Seigler HF. Lymphoscintigraphy in malignant melanoma: ^{99m}Tc antimony sulfur colloid. *AJR* 1981; 137:847–851.
2. Norman J, Cruse CW, Espinosa C, et al. Redefinition of cutaneous lymphatic drainage with the use of lymphoscintigraphy for malignant melanoma. *Am J Surg* 1991;162:432–437.
3. Lamki LM, Logic JR. Defining lymphatic drainage patterns with cutaneous lymphoscintigraphy. In: Balch CM, Houghton AN, Milton GW, Sober AJ, Soong S-J, eds. *Cutaneous melanoma*. Philadelphia:Lippincott;1992:367–375.
4. Uren RF, Howman-Giles RB, Shaw HM, Thompson JF, McCarthy WH. Lymphoscintigraphy in high risk melanoma of the trunk: predicting draining node groups, defining lymphatic channels and locating the sentinel node. *J Nucl Med* 1993;34:1435–1440.
5. Uren RF, Howman-Giles RB, Thompson JF, et al. Lymphoscintigraphy to identify sentinel lymph nodes in patients with melanoma. *Mel Res* 1994;4: 395–399.
6. Ege GN. Lymphoscintigraphy—techniques and applications in the management of breast carcinoma. *Semin Nucl Med* 1983;13:26–34.
7. Kaplan WD, Andersen JW, Siddon RL, et al. The three dimensional localization of internal mammary lymph nodes by radionuclide lymphoscintigraphy. *J Nucl Med* 1988;29:473–478.
8. Kaplan WD, Davis MA, Rose CM. A comparison of two technetium-99m-labeled radiopharmaceuticals for lymphoscintigraphy:concise communication. *J Nucl Med* 1979;20:933–937.
9. Ege GN, Warbick A. Lymphoscintigraphy: a comparison of ^{99m}Tc antimony suphide colloid and ^{99m}Tc stannous phytate. *Br J Radiol* 1979;52:124–129.
10. McLean RG, Ege GN. Prognostic value of axillary lymphoscintigraphy in breast carcinoma patients. *J Nucl Med* 1986;27:1116–1124.
11. Bourgeois P, Fruhling J, Henry J. Postoperative axillary lymphoscintigraphy in the management of breast cancer. *Int J Radiat Oncol Biol Phys* 1983;9:29–32.
12. Gitsch E, Philipp K, Kubista E. Intraoperative lymphoscintigraphy in radical surgery of cancer. *Geburtshilfe-Frauenheilkd* 1983;43:112–115.
13. Ege GN, Clark RM. Internal mammary lymphoscintigraphy in the conservative management of breast carcinoma: an update and recommendations for a new TNM staging. *Clin Radiol* 1985;36:469–472.
14. Yip TC, Ege GN. Determination of depth distribution of internal mammary lymph nodes on lateral lymphoscintigraphy. *Clin Radiol* 1985;36:149–152.
15. Gabelle P, Comet M, Bodin JP, et al. Mammary lymphatic scintiscans by intratumoral injection in the assessment of breast cancer: 105 examinations in 100 patients. *Nouv Presse Med* 1981;10:3067–3070.
16. Serin D, Vinot JM, Martin P, et al. The value of breast lymphoscintigraphy in the definition of axillary staging in cancer of the breast. *Bull Cancer* (Paris) 1986;73:299–304.
17. Saeki T, Karaki Y, Maeda M, et al. Development of ^{99m}Tc-labeled activated carbon microspheres and clinical application. *Nippon Geka Gakkai Zasshi* 1990;91:729–740.
18. Gasparini M, Andreoli C, Rodari A, et al. Lack of efficacy of lymphoscintigraphy in detecting axillary lymph node metastases from breast cancer. *Eur J Cancer Clin Oncol* 1987;23:475–480.
19. Mazzeo F, Accurso A, Petrella G, et al. Pre-operative axillary lymphoscintigraphy in breast cancer: experience with sub-areolar injection of ^{99m}Tc-nanocolloidal albumin. *Nucl Med Commun* 1986;7:5–16.
20. Matsubara S, Umehara I, Shibuya H, et al. Radionuclide lymphoscintigraphy performed on the mastectomized chest wall. *Cancer* 1986;58:1225–1230.
21. Terui S, Yamamoto. New simplified lymphoscintigraphic technique in patients with breast cancer. *J Nucl Med* 1989;30:1198–1204.
22. Morton DL, Wen D-R, Wong JH, et al. Technical details of intraoperative lymphatic mapping for early stage melanoma. *Arch Surg* 1992;127:392–399.
23. Giuliano AE, Kirgan DM, Guenther JM, Morton DL. Lymphatic mapping and sentinel lymphadenectomy for breast cancer. *Ann Surg* 1994;220:391–401.
24. Krag DN, Weaver JC, Alex JC, Fairbank JT. Surgical resection and radiolocalization of the sentinel lymph node in breast cancer using a gamma probe. *J Surg Oncol* 1993;2:335–340.

EDITORIAL

Lymphoscintigraphy and the Intraoperative Gamma Probe

Lymphoscintigraphy is not a new procedure, but one which has been in clinical use for decades. Yet, only now is this radionuclide imaging test gaining attention and enthusiasm from surgeons and the nuclear medicine community. This turn of events is largely related to the sentinel node concept (*1*) and appreciation for the impact of the lymphoscintigram on cost-effective patient management coupled with availability of a tool, the intraoperative hand-held gamma probe (*2*). Lymphoscintigraphy in conjunction with the probe, used to facilitate surgical localization and excision of the sentinel node, is finding a niche in the surgical management of patients with early melanoma and breast cancer.

The lymphoscintigram, performed as a two-phase study of dynamic followed by static imaging, defines the physiology of lymphatic flow through lymph channels to lymph nodes. The fact that functional imaging defines lymphatic pathways and nodal bed drainage from the tumor site which would not have been predicted from classical anatomic approaches (*3–5*) is changing surgical management in early clinical Stage I/II melanoma. The same potential for breast cancer surgical management also exists (*6*).

Received Jul. 20, 1995; accepted Jul. 20, 1995.

For correspondence or reprints contact: Naomi Alazraki, MD, Division of Nuclear Medicine, Department of Radiology, Emory University Hospital, 1364 Clifton Rd. NE, Atlanta, GA 30322.