
Split Dose Iodine-123-IMP SPECT: Sequential Quantitative Regional Cerebral Blood Flow Change with Pharmacological Intervention

Kazuo Hashikawa, Masayasu Matsumoto, Hiroshi Moriwaki, Naohiko Oku, Yutaka Okazaki, Toshiisa Uehara, Nobuo Handa, Hideo Kusuoka, Takenobu Kamada and Tsunehiko Nishimura

Department of Nuclear Medicine, First Department of Internal Medicine, Department of Neurology, Division of Tracer Kinetics, Osaka University Medical School, Osaka, Japan

At least two quantitative rCBF measurements are needed to evaluate rCBF changes with pharmacological intervention. We have developed the split dose ^{123}I -IMP SPECT method, which enables measurement of rCBF to be repeated in a short time. **Methods:** Thirty-one cerebrovascular disease patients were investigated to assess reproducibility and vasoreactivity to acetazolamide. During 44-min dynamic SPECT imaging, ^{123}I -IMP injection and respective arterial sampling were performed twice at an interval of about 25 min. The rCBF values were calculated using a microsphere model in which the washout of ^{123}I -IMP from the brain can be negligible in the first several minutes after injection. For the second rCBF measurement, the remaining activity due to the first ^{123}I -IMP injection was estimated and subtracted from the total brain activity. **Results:** In ten patients, two consecutive resting mean rCBF values in the MCA territory (CBF1 and CBF2) had good correlation (CBF1 = 47.4 ± 4.0 (ml/min/100 ml: mean \pm s.d.), CBF2 = 45.2 ± 8.2 , CBF2 = $0.900 \cdot \text{CBF1} + 2.9$, $r = 0.915$). In 11 patients with occlusive lesions in the unilateral ICA system, mean rCBF in the MCA territory was increased by only $27.7\% \pm 14.0\%$ in the affected side by a 1-g intravenous acetazolamide injection, while $44.5\% \pm 12.3\%$ increase was found in the nonaffected side. In 10 patients without a major arterial lesion, a $49.7\% \pm 17.0\%$ increase of rCBF was demonstrated. **Conclusions:** This split dose method ^{123}I -IMP SPECT can be useful to estimate vascular reserve.

Key Words: SPECT; cerebral blood flow; perfusion reserve; N-isopropyl-[I-123]p-iodoamphetamine; acetazolamide

J Nucl Med 1994; 35:1226-1233

Regional cerebral blood flow (rCBF) supply is regulated by delicate mechanisms to match the regional metabolic demand in normal brain tissues (1). In patients with cerebrovascular disease (CVD), however, this coupling is disrupted by drastic changes in rCBF, regional cerebral

blood volume and damage to the blood-brain barrier (2,3), and the regulating mechanism of rCBF cannot be maintained in these conditions. In order to understand the pathophysiology, including the function of the regulating mechanisms, it is very useful to assess perfusion reserve (3-11). The response of the cerebral circulation to pharmacological interventions, such as carbon dioxide inhalation or acetazolamide injection has been investigated to assess perfusion reserve. To evaluate these effects on rCBF, repeated quantitative rCBF measurements, with and without drugs, are necessary. N-isopropyl-[I-123]p-iodoamphetamine (^{123}I -IMP) SPECT with arterial sampling (12) is superior in reproducibility and has become a standard method for quantitative rCBF measurement (13-15). However, the two ^{123}I -IMP SPECT studies should be performed at an interval of at least several days, and double invasive arterial catheterization is required. In this study, we developed a split dose ^{123}I -IMP SPECT method that enables quantitative measurement of rCBF under two different conditions in a short time with a single arterial catheterization. A portion of the present investigation has been reported in abstract form (16).

MATERIALS AND METHODS

Theory

Iodine-123-IMP behaves like a microsphere early after intravenous injection because most of the tracer is extracted by brain tissue in the first cerebral circulation and the washout from brain tissue is negligible (12). We can thus estimate the absolute rCBF using a reference sample method in the first several minutes. However, the lung retains approximately 90% of the injected dose initially and therefore the actual initial brain uptake is markedly below the expected 20% of the injected amount if lung uptake is not present. The brain uptake increases gradually by washin from the lung. After this period, the increase of cerebral activity of ^{123}I -IMP becomes diminished, and about 20 min after injection the brain activity becomes almost stable while the washout from the brain becomes equivalent to the washin from the lung (17-19). During this period, estimation of the cerebral accumulation in the next several minutes can be easily performed using linear regression, as the time-activity curve is almost linear. Therefore, using the split dose method, the second measurement of rCBF can be

Received Aug. 2, 1993; revision accepted Mar. 23, 1994.

For correspondence or reprints contact: Kazuo Hashikawa, MD, First Department of Internal Medicine, Osaka University Medical School, 2-2 Yamadaoka, Suita 565, Japan.

TABLE 1
Summary of Subjects

Groups	n	Sex (M/F)	Age (mean ± s.d.)	Angiographic findings
Preliminary study to determine parameters of regression line				
P-Group	11	(7/4)	61.5 ± 12.7	No stenotic lesions
Reproducibility				
R-Group	10	(8/2)	64.2 ± 6.0	No stenotic lesions
Diamox® stress test				
C-Group	10	(9/1)	64.9 ± 7.1	No stenotic lesions
S-Group	11	(10/1)	52.4 ± 10.6*	Unilateral stenotic lesion

*Significantly lower versus P-Group, R-Group and C-Group ($p < 0.01$, Scheffé's multiple comparison after ANOVA).
Stenotic lesions were defined as greater than 90% stenosis in the CCA, ICA, MCA or their major branches.

performed with subtraction of the remaining activity due to the first ^{123}I -IMP injection.

In this study, two sets of tracer injections and respective arterial sampling were performed at an interval of about 25 min. The SPECT data between about 2 min 30 sec to 8 min after the first and second injections were used as rCBF values, respectively. The regression line was determined from the time-activity curve during the 14-min period just before the second injection.

Patients

A total of 42 patients with ischemic CVD disease were investigated (Table 1). In a preliminary study to determine the parameters of the regression line, 11 patients with mild CVD disease were studied. These patients suffered from nonfocal neurological symptoms of dizziness or headache and were shown to have no more than a 1-cm lesion by CT or MRI (P-Group). The remaining 31 patients were entered into the split dose ^{123}I -IMP SPECT study. To estimate reproducibility, 10 patients without major cerebral arterial lesions were selected (R-Group), and 21 patients were evaluated to determine its usefulness for measurement of vasoreactivity, using acetazolamide (Diamox, Lederle, Ltd., Tokyo, Japan). The latter patients were divided into two groups by angiographic findings: patients with a severe stenotic lesion in the unilateral intracarotid artery (ICA), middle cerebral artery (MCA), or common carotid artery (CCA) (S-Group: $n = 11$); and patients without stenotic lesions in these arteries (C-Group: $n = 10$). Stenotic lesions were defined as >90% stenosis on conventional angiography or digital subtraction angiography.

Preliminary Study to Determine the Parameters of Regression Line. Twelve-frame dynamic SPECT images were collected immediately after intravenous injection of ^{123}I -IMP (222 MBq) using a four-head SPECT system (20). During dynamic SPECT acquisition, the detectors were rotated continuously in reciprocal directions at 20 sec/revolution. Data acquisition was performed from 64 directions in a 64×64 matrix (1 pixel = $4 \text{ mm} \times 4 \text{ mm}$). One frame time was about 166 sec, which consisted of eight revolutions and the dead time for turning direction. The spatial resolution of this system using a low-energy, high-sensitivity collimator (LEHS) was 21.3 mm FWHM. The 8-mm slice transaxial images were reconstructed using a Butterworth filter for pre-filter and a Ramachandran filter for reconstruction filter. The region of interest (ROI) was drawn as the 50% iso-accumulation line of the maximum value in the thalamo-basal transaxial slice. Then the time-activity curve in this ROI of 12 frames was calculated. The

linear regression line ($C = k_1 \cdot F + k_2$, where k_1 and k_2 are constants, C is the total counts of the ROI, and F is frame number) was obtained from the fifth to ninth frame of each curve. Two values, F_{11} and F_{12} , were calculated in each subject by putting the observed C values of the eleventh and twelfth frame, $C_{11\text{obs}}$ and $C_{12\text{obs}}$, into the following equations (Fig. 1).

$$C_{11\text{obs}} = k_1 \cdot F_{11} + k_2,$$

$$C_{12\text{obs}} = k_1 \cdot F_{12} + k_2.$$

Reproducibility

Figure 2 shows the procedure of the ^{123}I -IMP split dose method. Twelve-frame dynamic SPECT was performed immediately after the first ^{123}I -IMP intravenous injection (55.5 MBq). The parameters of dynamic SPECT were the same as those for the preliminary study described above. Continuous blood sampling was performed with a withdrawal pump (model 98032H, Harvard Apparatus, South Natick, MA) from a 22-gauge teflon catheter placed in the radial artery through an extension tube. The total dead space for sampling was about 0.5 ml. Continuous blood sampling at a constant speed of 1 ml/min was started 30 sec before the corresponding ^{123}I -IMP injection and stopped 30 sec after the second frame. Therefore, the blood sample obtained was an integral of the radial arterial blood during the first and second frames after the first injection. Just before the tenth frame, arterial sampling of one point was performed to measure the remaining blood activity of the first injection. At the start of the tenth frame, about 25 min after the first ^{123}I -IMP injection, the second dose of 166.5 MBq of ^{123}I -IMP was injected. The second continuous arterial sampling was performed from 30 sec before the tenth frame to 30 sec after the end of the eleventh frame.

After the dynamic SPECT acquisition, static SPECT with a low-energy, general-purpose collimator (LEGP: spatial resolution = 13.0 mm FWHM) was performed. The acquisition time of this static SPECT was 12–15 sec/step, the acquisition step was 64, and the acquisition matrix was 64×64 (1 pixel = $4 \text{ mm} \times 4 \text{ mm}$). Total radioactivity of the blood sample (C -total) was measured by a scintillation well counter within 10 min after each sampling. The mixture of 0.5 ml of blood and 2 ml of octanol was shaken by a vortex and centrifuged at 3000 RPM for 20 min. The radioactivity of 1.0 ml of the octanol fraction was measured by a scintillation well-counter. The true input of ^{123}I -IMP was obtained by the following equation:

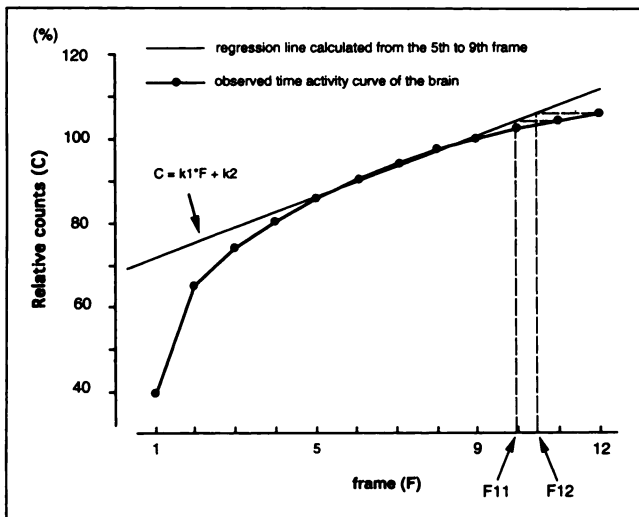


FIGURE 1. Scheme to determine the parameters of the regression line. The linear regression line was calculated from the fifth to ninth frames of each curve of P-group. Then, F11 and F12 were obtained for comparison with observed counts of the eleventh and twelfth frame.

$$C = 4 * (C\text{-octanol}/C\text{-whole}) * C\text{-total},$$

where C is true input of ^{123}I -IMP; C-octanol is radioactivity of 1.0 ml of octanol fraction; C-whole is radioactivity of 1.0 ml of whole blood; and C-total is total radioactivity of the whole blood sampling.

Acetazolamide Stress Test

Data acquisition was almost the same as the study for reproducibility except for acetazolamide injection. One gram of acetazolamide was injected at the end of the third frame of the first injection.

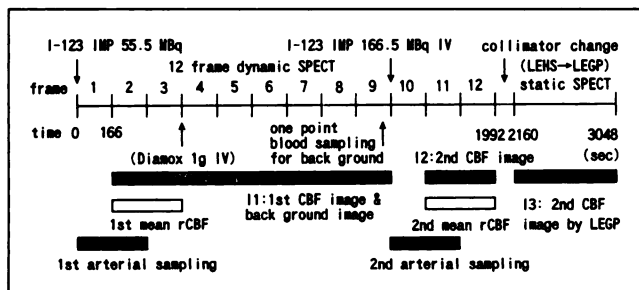


FIGURE 2. Protocol of ^{123}I -IMP split dose SPECT method. During 12-frame dynamic SPECT with low-energy, high-sensitivity collimator (LEHS: spatial resolution = 21.3 mm in FWHM), two sets of ^{123}I -IMP injection and corresponding arterial sampling were performed. The mean rCBF values were calculated from the summation of the second and third frames from the injection and the octanol fraction of each corresponding arterial blood sample. In calculation of the second mean rCBF value and the distribution of the second rCBF image, the remaining activities in the brain and arterial blood due to the first injection were subtracted. After the dynamic SPECT, the static SPECT was acquired with relatively high-resolution, low-energy, general-purpose collimator (LEGP: spatial resolution = 13.0 mm in FWHM).

Data Analysis

Four sets of transaxial images (I1, I2, I3 and I4) were reconstructed using a Ramachandran filter after pre-filtering with a Butterworth filter. The attenuation correction was made by the postcorrection method while the coefficient was set at 0.08 (1/cm). I1, I2 and I3 consisted of 8-mm thick transaxial images of the whole brain. I1 was reconstructed from the summation of the original eight frames, from the second to ninth frames; I2 was from the eleventh and twelfth frames; and I3 was from the acquisition data using the LEGP collimator.

To analyze the time-activity curve of the brain, one standard slice, including the thalamo-basal ganglia, was selected and a ROI was made as the inner part of the 50% iso-accumulation line of the maximum value of the whole slice. The obtained ROI (standard ROI) included almost the whole brain in the standard slice and consisted of 948–1199 pixels (1 pixel = 4 mm × 4 mm). I4 was 8-mm thick 12-frame dynamic transaxial images of the selected standard slice. The total counts in the standard ROI were calculated for I1, I2, I3 and I4. Quantitative rCBF images were obtained by the following equations in three steps.

1. Calculation of the mean rCBF values in the standard ROI:

$$\text{the first mean rCBF (CBF1)} = \text{CCF} * \{R[I4(2)] + R[I4(3)]\} / C1,$$

$$\text{the second mean rCBF (CBF2)} = \text{CCF} * \{R[I4(11)] + R[I4(12)]\} - [(k1 * mF11 + k2) + (k1 * mF12 + k2)] / (C2 - B).$$

2. Calculation of relative rCBF images:

$$\text{the first relative rCBF images (rCBFI1)} = I1,$$

$$\begin{aligned} \text{the second relative rCBF images (rCBFI2)} \\ = I2 - \{[(k1 * mF11 + k2) + (k1 * mF12 + k2)] / \\ \{R[I4(2) + \dots + R[I4(9)]\}\} * I1, \end{aligned}$$

$$\text{the second relative rCBF images with LEGP (rCBFIGP)}$$

$$= I3 - \{K * [(k1 * mF11 + k2) + (k1 * mF12 + k2)] / \{R[I4(2) + \dots + R[I4(9)]\}\} * I1.$$

3. Calculation of quantitative rCBF images:

$$\text{the first quantitative rCBF images (rCBF1)}$$

$$= \{CBF1 / R[rCBFI1]\} * rCBFI1,$$

$$\text{the second quantitative rCBF images (rCBF2)}$$

$$= \{CBF2 / R[rCBFI2]\} * rCBFI2,$$

$$\text{the second quantitative rCBF images with LEGP (rCBFIGP)}$$

$$= \{CBF2 / R[rCBFIGP]\} * rCBFIGP,$$

where CCF is a constant which calibrates the sensitivities of SPECT and a scintillation well-counter; $R[Ii(n)]$ is total counts in the standard ROI of n frame of I4 ($n = 1-12$); $R[rCBFIj]$ is total counts in the standard ROI of rCBFIj ($j = 1, 2$ or GP); C1 and C2 are counts measured by a scintillation well-counter of the octanol fraction of the first and second arterial blood samples; and B is counts of the octanol fraction of background sampling. These values are corrected by the time decay of the radioisotope and each sampling volume. K is the constant to correct the sensitivities of the two collimators, LEHS and LEGP. The two values, k1 and k2, are constants of the linear regression equation obtained from I1(5)–I1(9) for each subject. mF11 and mF12 are constants to estimate the background determined in the preliminary study. CCF was measured using a 20-cm cylinder phantom filled with ^{123}I -IMP solution every 2 mo and the nearest value for each study

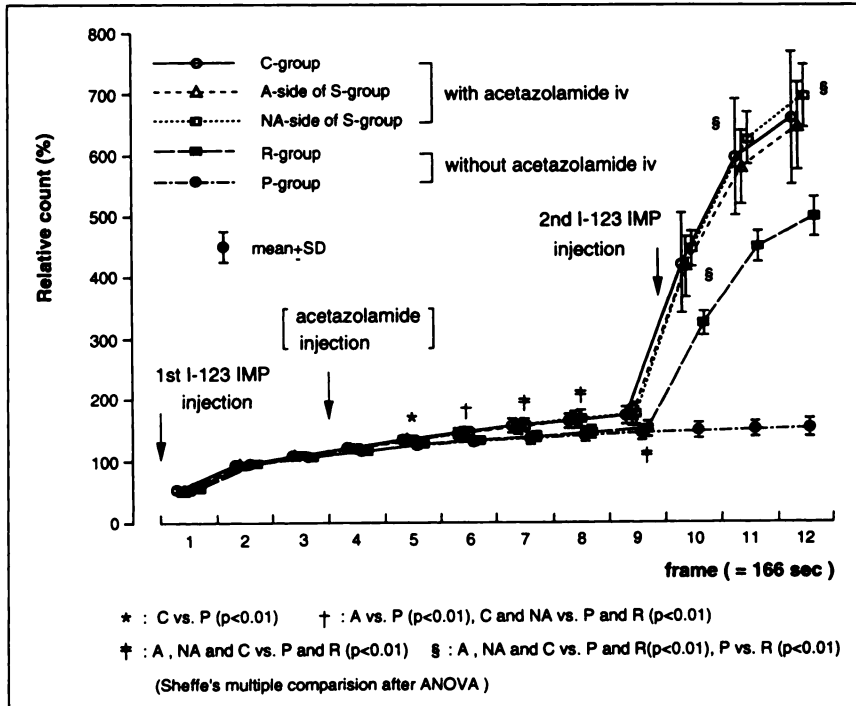


FIGURE 3. The time-activity curves of the MCA territory. The values were normalized by the average accumulation of the second and third frames, from which the first mean CBF was calculated. In the ninth frame, the period just before the second injection, the relative counts of the brain in the studies with acetazolamide injection; C-Group (172.7 ± 14.4) and S-Group (affected side: 173.1 ± 16.6 , nonaffected side: 176.8 ± 17.9), were significantly higher than those without acetazolamide injection; R-group (150.6 ± 12.3) and P-group (144.7 ± 11.0). However, there was no difference between affected and nonaffected sides of the S-group. These results suggest that the postinjection of acetazolamide elevated the brain accumulation after about 10 min, but the relative distribution of ^{123}I -IMP was kept constant in some degrees. The slopes of the brain activity curve between the eighth and ninth frames were 1.052 ± 0.026 , 1.042 ± 0.033 , 1.046 ± 0.033 , 1.037 ± 0.026 and 1.025 ± 0.009 in C-Group, affected side of S-Group, nonaffected side of S-Group, R-Group and P-Group, respectively. There were no differences among these slopes. C: C-Group, P: P-Group, A: affected side of S-Group, NA: nonaffected side of S-Group, and R: R-Group.

was applied for rCBF calculation. In a further investigation, quantitative analysis was made using rCBF1 and rCBF2. Because the spatial resolution of rCBFGP was different from those of other images, quantitative comparison would be difficult.

ROIs were drawn on thalamo-basal transaxial images from obtained quantitative images including almost the whole MCA territories, and mean counts of these ROIs were determined. ROI size was varied from 237 to 300 pixels. To evaluate regional reproducibility, the mean CBF in a 96 square ROI (12 mm \times 12 mm), which covered almost the whole brain, as calculated in one patient in the R-Group. Student's paired t-test was employed to compare the repeated measured data. Nonparametric comparisons of measured data of more than three groups were made by Friedman's analysis of variance (ANOVA). Then Scheffé's multiple comparison test was applied to examine the relation between variables. Values are expressed as mean \pm s.d.

RESULTS

Preliminary Study to Determine Parameters of Regression Line

The mean calculated values of F11 and F12 were 9.992 ± 0.309 and 10.393 ± 0.455 , respectively, thus mF11 and mF12 were determined as 9.992 and 10.393. Compared with observed values, the error of the summation of I11 and I12 estimated by the regression equation was $-2.16 \sim 1.66\%$ ($0.16 \pm 0.18\%$).

Effect of Acetazolamide on Time-Activity Curve of the Brain

Figure 3 shows the time course of the brain activity of all groups. The injection of acetazolamide caused a significant elevation of the latter portion of the brain activity. How-

ever, there were no significant differences among the slopes just before the second ^{123}I -IMP injection of five groups, P-Group, R-Group, C-Group, affected side (A-side) of S-group and nonaffected side (NA-side) of S-Group. These results suggest that the effect of acetazolamide injection on the distribution of ^{123}I -IMP is negligible and the regression line obtained from the study without acetazolamide injection can be applied in the study with acetazolamide injection.

Reproducibility

The mean first and second rCBF values in the MCA territory, (CBF1 and CBF2) were $32.5 \sim 65.0$ (ml/100 ml/min) (47.0 ± 8.4) and $33.3 \sim 60.4$ (45.2 ± 8.2), respectively. The ratio of mean rCBF (second-to-first) was $0.867 \sim 1.136$ (0.964 ± 0.068), and a good correlation was found between CBF1 and CBF2, $\text{CBF2} = 0.900 \cdot \text{CBF1} + 2.9$ ($R = 0.915$) (Fig. 4). Furthermore, a good reproducibility of rCBF was found (Figs. 5 and 6). These results indicate excellent reproducibility of this method.

Acetazolamide Stress Test

There were no significant differences among the resting mean rCBF in the MCA territories of the affected side (A-side) of the S-Group, the nonaffected side (NA-side) of the S-Group and the C-Group. The increase of mean rCBF by acetazolamide was lower in the A-side of the S-Group than those in the NA-side of the S-Group or C-Group, with significant differences (Fig. 7, Table 2). The partial pressure of carbon dioxide (PaCO_2) was increased significantly in the second study. This difference in PaCO_2 might influ-

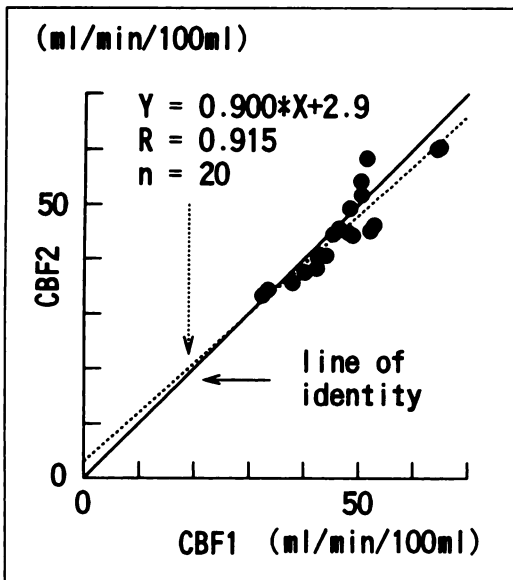


FIGURE 4. Reproducibility of rCBF measured by split dose ^{123}I -IMP SPECT. The values of mean rCBF (CBF1 and CBF2) were calculated in 8-mm thick slice including the thalami-basal ganglia.

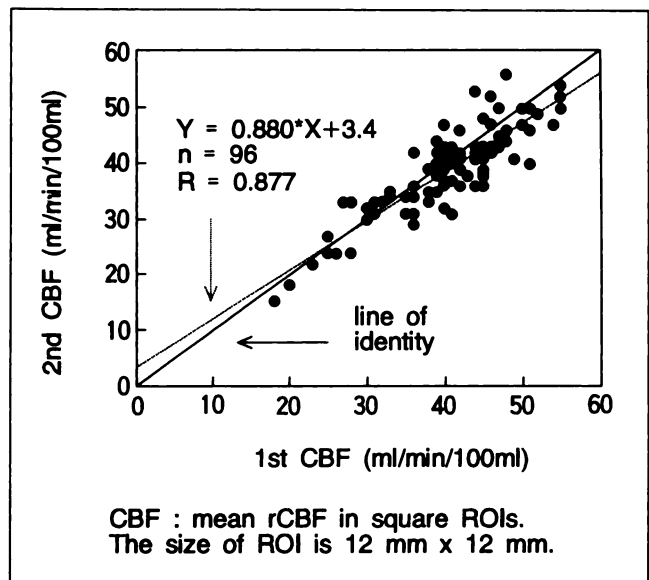


FIGURE 6. The regional CBF values of the same patients in Figure 5. The average CBF values in 96 square ROIs (12 mm \times 12 mm) were calculated.

ence CBF values, however, we did not apply correction factors because patients with CVD might have reduced vasoreactivity to PaCO_2 in varying degrees and the effect of PaCO_2 changes on rCBF in the vasodilated state by acetazolamide could not be assessed. Figure 8, shows representative SPECT images from the S-Group.

DISCUSSION

Sequential quantitative measurement of rCBF is useful for investigation of the pathophysiology of CVD. This method requires ^{15}O -water injection for PET (1,21), ^{133}Xe inhalation for SPECT (4,5,22), or cold xenon CT (23-24). However, PET involves much cost and manpower and

^{133}Xe inhalation requires special equipment. Therefore, we developed the split dose ^{123}I -IMP method which enables repeated quantitative measurements of rCBF using SPECT with a well-delivered tracer.

For the subtraction of the first remaining activity, the estimation of the brain activity of ^{123}I -IMP was indispens-

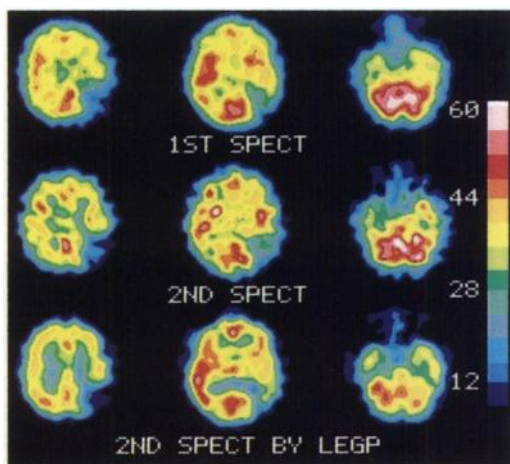


FIGURE 5. The representative SPECT images of R-group are shown of a 56-yr-old male suffering from an embolic infarction in the left parietal lesion. The two perfusion images under resting state showed good reproducibility of this method. LEGP = low-energy, general-purpose collimator (spatial resolution = 13.0 mm FWHM).

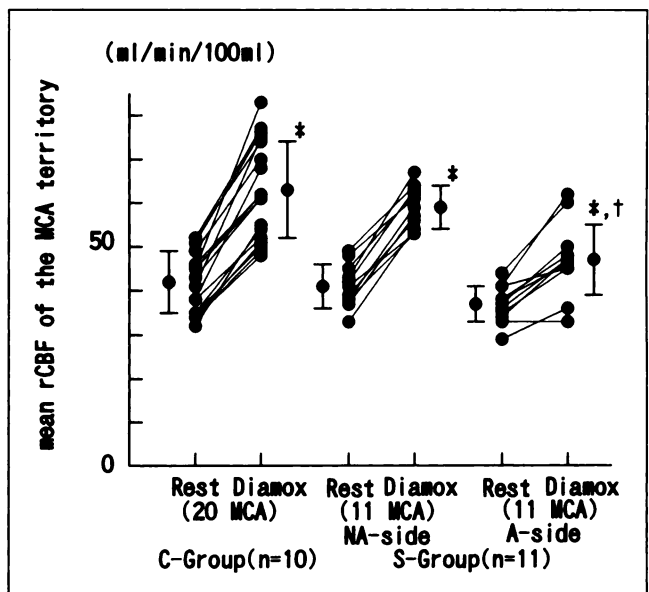


FIGURE 7. The mean rCBF of the MCA territories of C-Group and S-Group patients. There was no significant difference among resting mean rCBF values of affected side (A-side) and nonaffected side (NA-side) of the S-Group and C-Group (Scheffe's multiple comparison after ANOVA). * Significantly higher than mean rCBF in resting state ($p < 0.01$, paired t-test). † Significantly lower than mean rCBF of C-Group in acetazolamide (Diamox stressed state ($p < 0.01$, Scheffe's multiple comparison after ANOVA).

TABLE 2
Regional Cerebral Blood Flow Responses of MCA Territories to a 1-g Acetazolamide (Diamox®) Injection

PaCO ₂ (mmHg)	Resting Diamox	C-Group (n = 10)	S-Group (n = 11)	
		Sides of MCA territory		
		Bilateral (n = 20)	NA-side (n = 11)	A-side (n = 11)
		39.4 ± 1.8	37.0 ± 2.2	
		41.9 ± 2.6*	37.7 ± 1.6	
Mean rCBF (ml/min/100ml)	Resting	41.9 ± 6.6	41.0 ± 4.8	36.8 ± 4.4
	Diamox	62.5 ± 10.5*	58.9 ± 4.9*	47.2 ± 8.4*†
% increase of mean rCBF (%)		49.7 ± 17.0	44.5 ± 12.3	27.7 ± 14.0†

*Significantly higher versus resting ($p < 0.01$, paired t-test).

†Significantly lower versus C-group and NA-side ($p < 0.01$, Scheffé's multiple comparison after ANOVA). Values are expressed as mean ± s.d.

A-side = affected side of S-Group; NA-side = nonaffected side of S-Group.

able. The second injection was performed 24 min 54 sec after the first injection. At this time, the time-activity curves of the brain and artery had become relatively stable, and estimation of the latter portion of the curve was easy to perform. The preliminary study of time curves of brain activity in mild CVD cases suggested that the maximum error of the estimation was <3%. Considering about a twofold higher accumulation due to the second ¹²³I-IMP injection compared with remaining activity of the first injection, the error of the estimation of the second CBF calculation caused by this regression line would be negligible. The total errors of estimation became almost equal between the first and second CBF measurements (6). In two consecutive resting measurements, the variation of mean rCBF was about 6%, which was almost equivalent to the values with ¹³³Xe SPECT study (4,25) or PET study (26). The second mean rCBF was decreased slightly compared with the first mean rCBF, which might be caused by habituation of the patients (27). The good reproducibility of our method was due to the timing and the dose ratio of the two tracer injections.

To measure the cerebral activity curve, a relatively lower resolution collimator must be used. As a result, the spatial resolution of the first rCBF images was relatively poor, being almost equal to that of ¹³³Xe inhalation SPECT, but high-resolution rCBF images were obtained in the second study. Thus, more information could be obtained compared with the ¹³³Xe method, especially about the deep structures in the brain, which are difficult to evaluate using low-energy radioisotopes such as ¹³³Xe.

The mean rCBF values increased 49.7% in the MCA territory without stenotic lesions by 1 g of acetazolamide injection, and only 27.7% in that with severe stenotic lesions in the ICA system, which agrees with most previous reports (4,9,14,21). There was no significant difference between the increase of mean rCBF in the nonaffected side of S-Group and those of normal controls. However, some authors reported reduced vasoreactivity in the contralat-

eral of the affected side (4,6). In our study, the patients in the S-Group were younger than the controls. If younger controls were employed by our study, an increased ration by acetazolamide would become greater than that in the present study. The increase in accumulation of ^{99m}Tc-hexamethylpropyleneamine oxime (HMPAO) by 1 g of acetazolamide is reported to be less than expected. In our previous study (6), only about a 10% increase of ^{99m}Tc-HMPAO accumulation was observed by 5% carbon dioxide gas inhalation, which was expected to induce almost the same increase in CBF as 1.0 g of acetazolamide. This was considered due to the fact that the ^{99m}Tc-HMPAO retention did not increase linearly with perfusion, especially at high flow rates (6,28-30). The greater increase in our study (49.7%) demonstrated a good linearity with ¹²³I-IMP as the CBF tracer. To obtain sufficient counts for the first rCBF images, integral images of the second to ninth frame data were used. Considering the latent time for the appearance of the effects, acetazolamide must be injected in this period. Thus the distribution of the first images was influenced by acetazolamide injection to some degree. Since there were no significant differences between the time-activity curves of the affected side and nonaffected side of the S-Group, in which mean rCBF values differed from each other significantly, the effect of acetazolamide on ¹²³I-IMP distribution can be assumed to be insignificant. To fully validate this method, the brain-activity curve of a single injection of ¹²³I-IMP with acetazolamide must be done. However, as there was no difference between the slopes of time-activity curves with and without acetazolamide in the period just before the second injection, the influence of acetazolamide was thought to be small to negligible in the CVD patients. In addition, the results of the acetazolamide stress test in patients with an occlusive lesion in the unilateral ICA system showed good agreement with those from other modalities. Therefore, we believe that the effects of acetazolamide can be ignored in clinical use. Moreover, our method is applicable to other

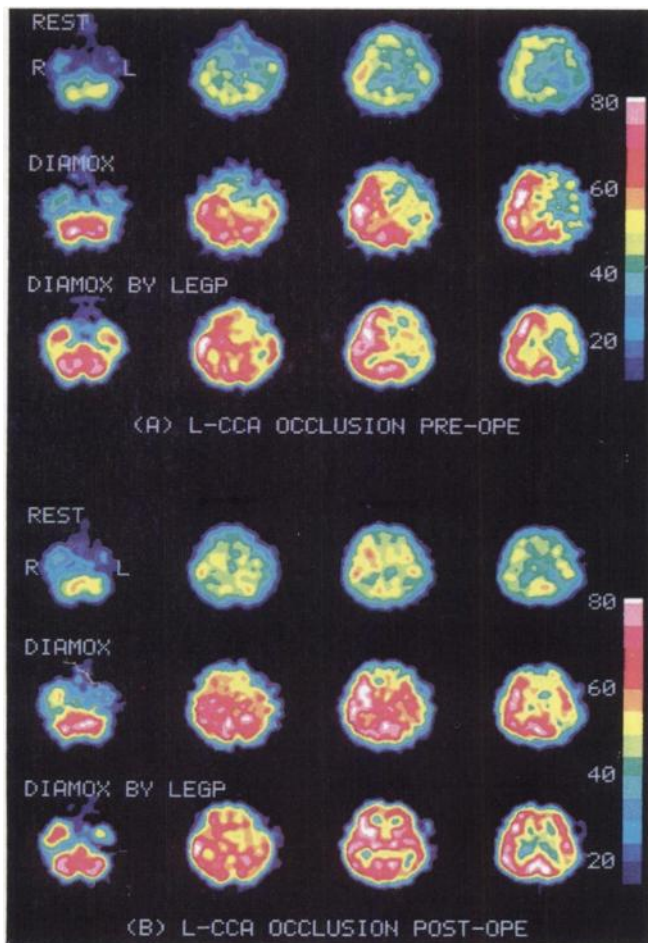


FIGURE 8. Representative patient from the S-group, a 58-yr-old male with common carotid artery (CCA) occlusion. He had suffered from transient ischemic attacks with right hemiparesis. Angiography revealed left CCA occlusion and there was no low-density area in CT images. The preoperative SPECT images (A) demonstrated low perfusion and decreased vasoresponse to acetazolamide (Diamox in the affected left middle cerebral artery area. On the basis of these results, his clinical symptoms were thought to be caused by hemodynamic events induced by left CCA occlusion and revascularization, left subclavian-CCA anastomosis was performed. After bypass surgery, improved perfusion reserve could be seen on rCBF images (B) and his clinical symptom had disappeared. LEGP = low-energy, general-purpose collimator (spatial resolution = 13.0 mm in FWHM).

activation studies which had no more effect on ^{123}I -IMP kinetics than the acetazolamide injection.

In acute CVD patients with drastic perfusion changes, especially those involving reperfusion by thrombolysis, ^{123}I -IMP kinetics will be changed extensively, and perfusion estimation will become impossible. When these abnormal states are involved, the methodological limitation of measuring rCBF must be considered in almost all methods. This is also a drawback to the split dose method. If the clinician suspects such an abnormal condition in the lesion, the time-activity curve of the region will be helpful in analyzing the pathophysiology.

We can also use the split dose ^{123}I -IMP method without arterial sampling. Although it was impossible to get abso-

lute CBF values, two perfusion images under different conditions, resting and vasodilated, can be obtained in a short time. Devous et al. (31) recently reported on dual-tracer method to assess vasoreactivity to acetazolamide using $^{99\text{m}}\text{Tc}$ -HMPAO and ^{123}I -IMP or ^{123}I -N,N,N'-trimethyl-N'-[2-hydroxyl-3-methyl-5-iodobenzyl]-1,3-propanediamine. The spatial resolution of the two images obtained by their method is superior to that of images obtained by our method. However, in semiquantitative analysis (e.g., using right-to-left ratio), the different linearity of two tracers is somewhat of a drawback. Our sequential rCBF method was more useful in such cases even without arterial sampling.

CONCLUSION

In this study, we evaluated the reproducibility and the usefulness of the split dose ^{123}I -IMP SPECT method to assess vascular reserve using acetazolamide. The results demonstrated good reproducibility and agreed with previous reports on CVD patients. Our method will be very useful in the investigation of the hemodynamics of CVD patients and will be applicable to other pharmacological interventions affecting cerebral circulation.

ACKNOWLEDGMENT

The authors thank Dr. K. Kimura (Osaka Seaman's Insurance Hospital) and Dr. H. Etani (National Osakaminami Hospital) for their constant interest and guidance in this investigation; Dr. T. Hayakawa and Dr. K. Yamada (Department of Neurosurgery, Osaka University Medical School); Mr. Yukio Nakamura and Yoshimi Kusumi for their technical assistance; and Miss Kayoko Moriguchi and Mrs. Mayumi Okumura for their secretarial assistance. This work was supported in part by the Smoking Research Foundation.

REFERENCES

1. Baron JC, Rougemont D, Collard P, Bustany P, Bousser MG, Comar D. Coupling between cerebral blood flow, oxygen consumption and glucose utilization: its study with positron tomography. In: *Positron emission tomography*. New York: Alan R. Liss, Inc.; 1985:203-218.
2. Baron JC, Frackowiak RSJ, Herholz K, et al. Use of PET methods for measurement of cerebral energy metabolism and hemodynamics in cerebrovascular disease. *J Cereb Blood Flow Metab* 1989;9:723-742.
3. Olsen TS. Regional cerebral blood flow after occlusion of the middle cerebral artery. *Acta Neurol Scand* 1986;73:321-337.
4. Vorstrup S. Tomographic cerebral blood flow measurements in patients with ischemic cerebrovascular disease and evaluation of the vasodilatory capacity by the acetazolamide test. *Acta Neurol Scand* 1988;114:1-47.
5. Herald S, Brown MM, Frackowiak RSJ, Mansfield AO, Thomas DJ, Marshall J. Assessment of cerebral haemodynamic reserve: correlation between PET parameters and CO_2 reactivity measured by the intravenous ^{133}Xe injection technique. *J Neurol Neurosurg Psychiatry* 1988;51:1045-1050.
6. Oku N, Matsumoto M, Hashikawa K, et al. Carbon dioxide reactivity by consecutive technetium-99m-HMPAO SPECT in patients with a chronically obstructed major cerebral artery. *J Nucl Med* 1994;35:32-40.
7. Buell U, Schicha H. Nuclear medicine to image applied pathophysiology: evaluation of reserve by emission computerized tomography. *Eur J Nucl Med* 1990;16:129-135.
8. Hasegawa Y, Yamaguchi T, Tsuchiya T, Minematsu K, Nishimura T. Sequential change of hemodynamics reserve in patients with major cerebral artery occlusion or severe stenosis. *Neuroradiology* 1992;34:15-21.
9. Pedersen EH. Effect of acetazolamide on cerebral blood flow in subacute and chronic cerebrovascular disease. *Stroke* 1987;18:887-891.
10. Levine RL, Dobkin JA, Rozental JM, Satter M, Nickles RJ. Blood flow

- reactivity to hypercapnia in strictly unilateral carotid disease: preliminary results. *J Neurol Neurosurg Psychiatry* 1991;54:204–209.
11. Tominaga S, Strandgaard S, Uemura K, et al. Cerebrovascular reactivity in normotensive and hypertensive man. *Stroke* 1976;5:507–510.
 12. Kuhl DE, Barrio JR, Huang SC, et al. Quantitative local cerebral blood flow by N-isopropyl-p-[I-123]iodoamphetamine Tomography. *J Nucl Med* 1982; 23:196–203.
 13. Hellman RS, Collier BD, Tikofsky RS, et al. Comparison of single photon emission computed tomography with [123I]iodoamphetamine and xenon-enhanced computed tomography for assessing regional cerebral blood flow. *J Cereb Blood Flow Metab* 1986;6:747–755.
 14. Greenberg JH, Kushner M, Rango M, Alavi A, Reivich M. Validation studies of iodine-123-iodoamphetamine as a cerebral blood flow tracer using emission tomography. *J Nucl Med* 1990;31:1364–1369.
 15. Podreka I, Baumgartner C, Suess E, et al. Quantification of regional cerebral blood flow with IMP-SPECT. Reproducibility and clinical relevance of flow values. *Stroke* 1989;20:183–191.
 16. Hashikawa K, Matsumoto M, Moriwaki H, et al. Sequential quantitative cerebral blood flow measurements using split dose I-123 IMP SPECT method [Abstract]. *J Nucl Med* 1993;34:209P.
 17. Nishizawa S, Tanada S, Yonekura Y, et al. Regional dynamics of N-Isopropyl-(123I)p-iodoamphetamine in human brain. *J Nucl Med* 1989; 30:150–156.
 18. Creutzig H, Schober O, Gielow P, et al. Cerebral dynamics of N-isopropyl-(123I)p-iodoamphetamine. *J Nucl Med* 1986;27:178–183.
 19. Weber DA, Cabahug C, Klieger P, et al. Effects of visual stimulation on the redistribution of iodine-123-IMP in the brain using SPECT imaging. *J Nucl Med* 1991;32:1866–1872.
 20. Kimura K, Hashikawa K, Etani H, et al. A new apparatus for brain imaging: four-head rotating gamma camera single photon emission computed tomograph. *J Nucl Med* 1990;31:603–609.
 21. Kanno I, Uemura K, Higano S, et al. Oxygen extraction at maximally vasodilated tissue in the ischemic brain estimated from the regional CO₂ responsiveness measured by positron tomography. *J Cereb Blood Flow Metab* 1988;8:227–235.
 22. Vorstrup S, Lassen NA, Henriksen L, et al. CBF before and after extracranial–intracranial bypass surgery in patients with ischemic cerebrovascular disease studies with ¹³³Xe-inhalation tomography. *Stroke* 1985; 16:616–626.
 23. Yamashita T, Kashiwagi S, Takasago T, Abiko S, Hayashi M, Ito H. The effect of EC-IC bypass surgery on resting cerebral blood flow and cerebrovascular reserve capacity studies with stable xenon-CT and acetazolamide test. *Neuroradiology* 1991;33:217–222.
 24. Rogg J, Rutigliano M, Yonas H, Johnson DW, Pentheny S, Latchaw RE. The Acetazolamide challenge: imaging techniques designed to evaluate cerebral blood flow reserve. *AJR* 1989;153:605–612.
 25. Devous MD, Stokely EM, Chehabi H, Bonte FJ. Normal distribution of regional cerebral blood flow measured by dynamic single-photon emission tomography. *J Cereb Blood Flow Metab* 1986;6:95–104.
 26. Frackowiak RSJ, Lenzi GL, Jones T, Heather JD. Quantitative measurement of regional cerebral blood flow and oxygen metabolism in man using ¹⁵O and positron emission tomography: theory, procedure, and normal values. *J Cereb Blood Flow Metab* 1980;6:727–736.
 27. Warach S, Gur RC, Gur RE, Skolnick BE, Obrist WD, Reivich M. Decreases in frontal and parietal lobe regional cerebral blood flow related to habituation. *J Cereb Blood Flow Metab* 1992;12:546–553.
 28. Choksey MS, Costa DC, Iannotti F, Ell PJ, Crockard HA. Technetium-99m-HMPAO SPET and cerebral blood flow: a study of CO₂ reactivity. *Nucl Med Commun* 1989;10:609–618.
 29. Burt RW, Witt RM, Cikrit DF, Reddy RV. Carotid artery disease: evaluation with acetazolamide-enhanced ^{99m}Tc-HMPAO SPECT. *Radiology* 1992;182:461–466.
 30. Ramsay SC, Yeates MG, Lord RS, et al. Use of technetium-HMPAO to demonstrate changes in cerebral blood flow reserve following carotid endarterectomy. *J Nucl Med* 1991;32:1382–1386.
 31. Devous MD, Payne JK, Lowe JL. Dual-isotope brain SPECT imaging with technetium-99m and iodine-123: clinical validation using xenon-133 SPECT. *J Nucl Med* 1992;33:1919–1924.