
Computer-Assisted Evaluation of Dipyridamole Thallium-201 SPECT in Patients with Aortic Stenosis

Peter Rask, Kjell Karp, Bo Edlund, Peter Eriksson, Thomas Mooe and Urban Wiklund

Departments of Clinical Physiology, Diagnostic and Interventional Radiology and Cardiology, University Hospital of Northern Sweden, Umeå, Sweden

Dipyridamole SPECT detects significant coronary artery disease (CAD) in patients without aortic stenosis. This study was done to establish normal ^{201}Tl distribution limits in patients with aortic stenosis and to apply these normal limits to patients with aortic stenosis and angiographically significant CAD ($\geq 75\%$ area reduction). **Methods:** Fifty-two patients (mean age 68 yr; mean valve area 0.67 cm^2) were examined with ^{201}Tl SPECT after dipyridamole infusion (0.56 mg/kg during 4 min). After tomographic reconstruction, basal, mid-ventricular and apical short-axis slices were selected. The highest activity in each six-degree segment was normalized to the maximal activity of each slice. **Results:** Significant CAD was found in 24 patients. Five patients without CAD, but with localized hypokinesia or left bundle-branch block, were excluded from the reference group which finally consisted of 16 patients. Sensitivity for CAD was 88% when the lowest relative activity in each segment was used as the lower limit of normal. With -2 s.d. and -2.5 s.d. curves the sensitivity was 83% and 75%, respectively. Gender-specific limits were not used. Nonsignificant CAD was found in seven patients ($<75\%$ stenoses). **Conclusions:** This study presents the normal distribution of ^{201}Tl uptake for patients with aortic stenosis, using dipyridamole SPECT. The range method had the highest sensitivity for detection of significant CAD.

Key Words: aortic stenosis; coronary artery disease; dipyridamole; thallium-201; SPECT; computer evaluation

J Nucl Med 1994; 35:983-988

In patients with aortic stenosis, the valve area can be determined noninvasively with two-dimensional and Doppler echocardiography (1-5). Simultaneously, additional valve lesions as well as left ventricular function can be assessed (6-9).

Concomitant coronary artery disease (CAD) is frequent in patients with aortic stenosis (10) making it necessary to exclude or confirm CAD prior to surgery. Angina pectoris is not a reliable predictor of CAD in adult patients with

aortic stenosis (11) and preoperative coronary angiography is performed in most institutions.

SPECT can detect significant CAD in patients without concurrent aortic stenosis (12,13). However, the presence of aortic stenosis introduces difficulties in the scintigraphic evaluation. Increased wall stress, left ventricular hypertrophy and shortened coronary perfusion time may alter the scintigraphic images even in the absence of CAD. Exercise stress tests with ^{201}Tl planar imaging (14-16) or with ^{201}Tl SPECT (17) have been used to assess CAD in patients with aortic stenosis. Dipyridamole can be used to achieve a near maximal increase in coronary blood flow prior to thallium administration (18,19). Dipyridamole has been used with a handgrip test and planar ^{201}Tl imaging in patients with aortic stenosis (20), and dipyridamole ^{201}Tl SPECT has also recently been used in a small number of patients with aortic stenosis (21). Dipyridamole cardiac imaging has been found to be a reasonably sensitive and safe method to assess CAD in patients with known or suspected cases (22,23). The normal limits of dipyridamole ^{201}Tl distribution within the myocardium has been presented for patients without aortic stenosis and CAD (24). This "normal distribution" in patients with aortic stenosis but without CAD has not been established previously.

The aim of this study was to establish the normal limits for the distribution of ^{201}Tl in patients with aortic stenosis without CAD using dipyridamole ^{201}Tl SPECT and to apply these normal limits to a group of patients with aortic stenosis and angiographically verified CAD.

MATERIALS AND METHODS

Patients

Fifty-two patients (28 males and 24 females, age range 44-79 yr; mean age, 67.7 yr) with aortic stenosis undergoing investigation prior to possible replacement of the aortic valve were included. Six patients had a history of previous myocardial infarction, 13 had a history of previous syncope and 37 had angina pectoris. Two patients were in functional class II, 48 in class III and 2 in class IV according to the NYHA classification.

Informed consent was given by all patients. The study was approved by the hospital ethics committee.

Received Aug. 23, 1993; revision accepted Feb. 10, 1994.
For correspondence or reprints contact: Peter Rask, MD, Dept. of Clinical Physiology, University Hospital of Northern Sweden, 901 85 Umeå, Sweden.

Echocardiography

Aortic valve area was calculated using echo-Doppler and the continuity equation (6). The peak gradient was obtained using continuous Doppler (1). Concomitant aortic or mitral regurgitation was assessed with color flow imaging and was graded as absent, slight, moderate or severe. Left ventricular wall motion was assessed using two-dimensional echocardiography. Myocardial mass was calculated using measurements made according to American Society of Echocardiography criteria and the cube formula of Troy et al. (25,26). Myocardial mass was corrected for body surface area. Left ventricular myocardial mass index was calculated as:

$$LVMI = 1.04[(IVS + LVDd + PW)^3 - (LVDd)^3]/BSA,$$

where IVS is thickness of septum (cm); LVDd is left ventricular diastolic internal diameter (cm); PW is thickness of posterior wall (cm); and BSA is body surface area (m²).

A myocardial mass index >150 g/m² for men and >120 g/m² for women was regarded as myocardial hypertrophy (27).

Equilibrium Radionuclide Angiography

Left ventricular ejection fraction (EF) was obtained in 50 patients (two patients with missing data) using a standard radionuclide equilibrium method.

Dipyridamole Thallium-201 SPECT

Dipyridamole (0.56 mg/kg body weight) was dissolved in 250 ml saline and infused intravenously during 4 min with the patients in a supine position. No additional stress was used. Two minutes after conclusion of the infusion, 74 MBq of ²⁰¹Tl was injected and 2 min thereafter 115 mg theophylline was slowly administered intravenously (28). A 12-lead electrocardiogram was monitored and cuff blood pressure was measured every second minute during the procedure.

Imaging started within 10 min after the injection of ²⁰¹Tl using a GE400T gamma camera with a low-energy high-resolution parallel-hole collimator. A dual-windowing technique was used with a 40% window centered around the 68–80-keV peak and a 15% window centered around the 158-keV peak. Thirty-two 40-sec images were acquired using 180° counter clockwise rotation starting from a left posterior oblique view. The images were acquired on a Gamma 11 computer system using a 32 × 32 matrix, and tomographic reconstructions were performed using filtered back-projection. The reconstructed short-axis images were transferred to a Macintosh IIsi computer for further evaluation. Image analysis was made using software based on "Image," (National Institutes of Health Research Service Branch, NIMH). A basal, mid-ventricular and apical short-axis slice were manually selected. For each selected slice, the outer boundary of the myocardium was defined by the operator. Starting at the "3 o'clock" position and moving clockwise, the computer program divided the slice into six-degree segments and the highest activity in each segment was normalized to the highest activity in any segment in the slice. The relative activity in each segment was then plotted (Figs. 1 and 2). The procedure was similar, but not identical, to a previously described procedure (24). Vascular territories were assigned for each slice as follows: The 147°–315° segment was assigned to the left anterior descending coronary artery (LAD), the 316°–63° segment was assigned to the left circumflex coronary artery (LCX) and the 64°–146° segment to the right coronary artery (RCA).

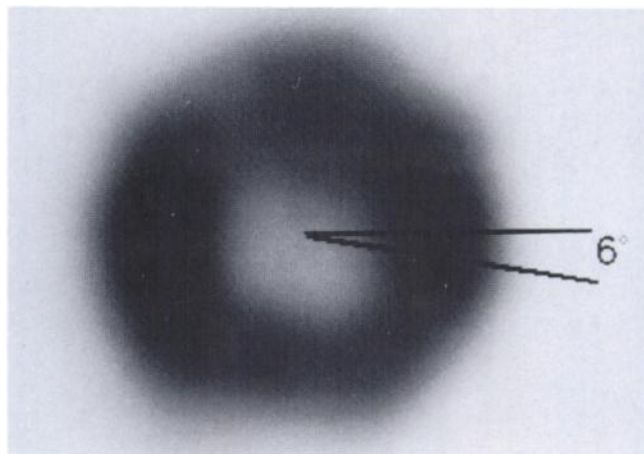


FIGURE 1. Quantitative analysis techniques. After operator determination of the outer boundary of the myocardium, the computer divides the cardiac image into 60 six-degree segments, and the maximal activity within each segment is measured.

Coronary Angiography

Coronary angiography was performed in all patients using the Judkins technique with multiple angulations. A visually assessed area reduction of at least 75% in at least one coronary artery or major branch was considered as angiographically significant CAD. All angiograms were evaluated by two independent observers and disagreement was solved by majority decision through a third observer.

Statistics

Student's two-tailed paired and unpaired t-test was used. A p value less than 0.05 was considered to be statistically significant. Mean and standard deviation was calculated from the normalized activity curves.

RESULTS

Echocardiography

The mean aortic valve area for the study population was 0.67 cm² (s.d. 0.26) with a range of 0.34–1.34 cm². The

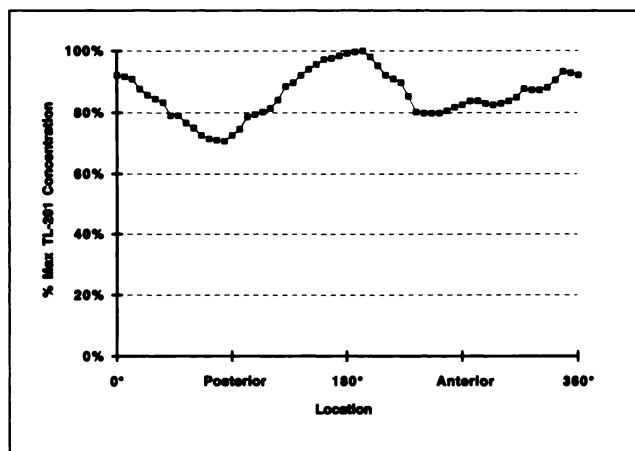


FIGURE 2. Thallium-201 distribution for the patient in Figure 1 (the midventricular plane from a patient with normal coronary angiogram).

TABLE 1
Hemodynamic Effects of Dipyridamole Infusion*

		Before dipyridamole	After dipyridamole	p value
Heart rate	Beats/min, mean (s.d.)	70 (15)	84 (16)	0.0001
Systolic blood pressure	mmHg, mean (s.d.)	139 (23)	134 (23)	0.01
Diastolic blood pressure	mmHg, mean (s.d.)	81 (12)	78 (12)	0.03

*There was a significant increase in heart rate and a small but significant decrease in both systolic and diastolic blood pressure (n = 52).

mean peak Doppler gradient was 85 mmHg (s.d. 34), range 23–163 mmHg. Nineteen patients had a slight mitral regurgitation and eight a moderate mitral regurgitation. Aortic regurgitation was present in 21 patients, slight in 18 and moderate in 3. No patient had severe aortic or mitral regurgitation. Mean LVMI was 206 (s.d. 69) g/m², ranging from 112 to 441 g/m² and 89% of the males and 92% of the females had myocardial hypertrophy.

Equilibrium Radionuclide Angiography

Mean ejection fraction measured in 50 patients (two patients with missing data) was 53% (range 18%–73%, s.d. 14%). Two patients had EF < 20%, with no signs of CAD according to angiography, but they were both excluded from the reference group due to severe hypokinesia shown by echocardiography.

Coronary Angiography

The 52 patients were divided into three groups according to angiography. Group 1 consisted of 21 patients with no angiographic signs of CAD, Group 2 consisted of 24 patients with angiographically significant CAD ($\geq 75\%$ area reduction) and Group 3 consisted of seven patients with coronary stenosis but <75% area reduction at angiography.

Dipyridamole Thallium-201 SPECT

Sixteen patients reported angina during the infusion, ranging from only a mild discomfort to strong chest pain (0.5–6 on the 10-grade Borg scale) (29). The chest pain was reversed by theophylline in all but a few patients who required additional sublingual nitroglycerine. During dipyridamole infusion, there was a significant increase in heart rate and a small but significant decrease in both systolic and diastolic blood pressure (Table 1). Forty patients showed a ST-segment depression on the resting electrocardiogram. Seventeen patients had a lowering of the ST-segment that was 1 mm or greater during dipyridamole infusion. Three patients reported headache during the dipyridamole infusion. There were no serious complications.

Five of the 21 patients with no angiographic signs of CAD had either a localized left ventricular hypokinesia according to echocardiography (4 patients), suggesting a previous myocardial infarction, or a left bundle-branch block on the electrocardiogram (1 patient), and were excluded from the reference group. The reference group thus

consists of 16 patients, 5 males and 11 females. The mean activity curve, the lower limit of range curve, the -2 s.d. and -2.5 s.d. curves in each slice are presented in Figure 3.

If more than one six-degree segment fell below the lower normal limit, the scintigraphic study was considered abnormal. When the lower limit of range in the reference group was regarded as the lower normal limit and applied to the Group 2 patients with significant CAD (n = 24), the sensitivity for detection of significant stenosis was 88% (21/24). When -2 s.d. was used as the lower normal limit, sensitivity was 83% (20/24). Sensitivity was 75% (18/24) using -2.5 s.d. as the lower normal limit.

Seven patients had an angiographic area reduction of less than 75% (Group 3 patients) and were considered to have nonsignificant coronary stenoses. With the range approach four patients fell outside the lower normal limit. Using -2 s.d. and -2.5 s.d., three and two patients, respectively, were considered to have pathological scintigrams.

Using the range method, 38 (69%) of 55 vessels with significant stenosis were correctly identified. In 12 patients with three-vessel disease, the extent of disease was correctly identified in seven patients. Twenty (53%) of the 38 vessels without significant stenosis were classified as scintigraphically normal. All the 48 vessels in the reference group were classified as normal. Overall, there was a match in 106 (75%) of 141 vessel areas using the range method.

The patients in the reference group had a slightly lower LVMI, mean 191 g/m² (s.d. 80 g/m²) than the patients with significant CAD, mean 199 g/m² (s.d. 55 g/m²). The difference was not statistically significant. The patients in the reference group had a smaller aortic valve area than the patients with CAD, mean 0.62 cm² (s.d. 0.24 cm²) and 0.76 cm² (s.d. 0.27 cm²) respectively, but the difference was not statistically significant.

There was no difference in the frequency or severity of aortic or mitral regurgitation between the patients in the reference group and the patients with angiographically significant CAD.

Left ventricular ejection fraction was higher in the reference group than in patients with CAD, 61% (s.d. 7%) and 54% (s.d. 13%), respectively, and the difference was almost statistically significant, p = 0.0503.

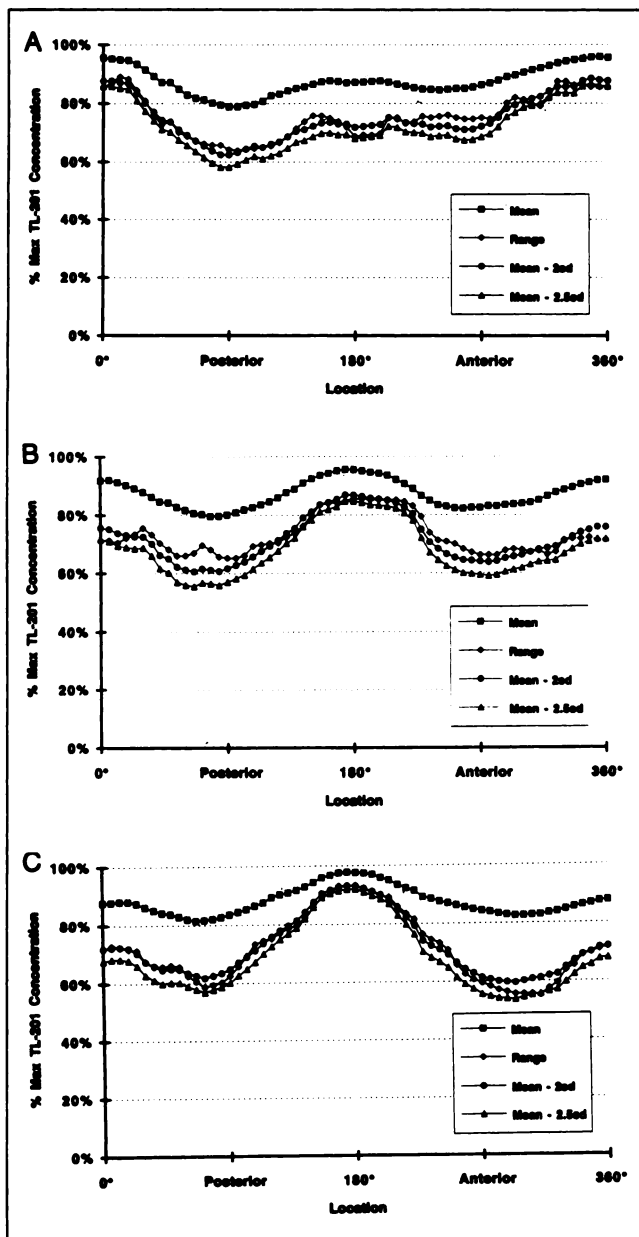


FIGURE 3. Thallium-201 distribution for all patients in the reference group, e.g., the patients with no signs of CAD according to angiography or echocardiography. The mean, the lower limit of range, mean minus 2 s.d. and mean minus 2.5 s.d. are shown. (A) basal plane; (B) midventricular plane; and (C) apical plane.

DISCUSSION

The fear of using vasodilator therapy in patients with severe aortic stenosis is well established, however, recent studies challenge this view and have even suggested beneficial effects of afterload reduction in these patients (30,31). Since the dipyridamole effects are reversible with a suitable antidote such as theophylline, a noninvasive diagnostic test which might spare the patient an invasive examination should not be excluded.

The incidence of dipyridamole-provoked chest pain in the present study is similar to the incidence reported in

patients without aortic stenosis (23,28), but is higher than the incidence reported using a dipyridamole handgrip test (20). The latter may be due to the increase in systolic blood pressure using a handgrip after dipyridamole, but may also be due to differences in the study populations.

In the present study, dipyridamole infusion caused no serious complications and none have been reported previously (20,21). Dipyridamole-²⁰¹Tl scintigraphy seems to be a safe method even in patients with severe aortic stenosis. To better assess the safety of the procedure, larger studies, preferably from several institutions, are needed.

The present study shows that dipyridamole-²⁰¹Tl SPECT can be useful in assessing the presence of CAD in elderly patients with aortic stenosis. The sensitivity for angiographically significant CAD in the present study is in the same range as for patients without aortic stenosis (22) and in the same range as reported using the dipyridamole handgrip test and planar ²⁰¹Tl imaging (20). The sensitivity found in the present study using the range method (88%) is also in the same range as recently reported using exercise ²⁰¹Tl SPECT (17).

Using dipyridamole to increase coronary blood flow makes it possible to investigate more patients since exercise stress testing in patients with aortic stenosis and left-ventricular failure may not be appropriate. The main purpose of the noninvasive test was to identify patients with concomitant CAD. Therefore, the lower limit of range method, which yielded the highest sensitivity (88%), is preferable. With this high sensitivity it might be possible to exclude patients with scintigraphic findings within normal limits from coronary angiography. Redistribution images were not analyzed since the main purpose of the present study was to reveal flow-limiting coronary stenoses.

Though rare, false-negative studies (3/24) must be considered. Angiography is the gold standard for determining coronary artery anatomy, but the method has several limitations (32,33). The interobserver variability may be reduced by quantitative computerized angiography. This method was not available to us at the time of the present study. Also, coronary angiography gives an estimate of the anatomical narrowing of the arteries but the effect on blood flow is only assumed (34). Therefore, both under- and overestimation of the hemodynamic effect is possible. The scintigraphic method also incorporates limitations, but conceptually assesses relative coronary perfusion reserve and may thus give a more physiologic measure of the hemodynamic significance of coronary artery stenoses than angiography. Complete agreement between coronary angiography and scintigraphy cannot be expected.

The seven patients with definite but angiographically insignificant CAD (Group 3) showed a spectrum of scintigraphic images. Regardless of which lower limit of normal was applied (range, -2 s.d. or -2.5 s.d.), two patients had scintigrams outside the normal limits and three patients had normal scintigrams. This clearly suggests that the coronary lesions in at least two of these patients might have been hemodynamically significant even though they were

considered to be insignificant at angiography. Scintigraphy may reveal important information prior to surgery that can help to determine if a coronary bypass should be performed at the same time as valve replacement.

A beneficial effect of simultaneous valve replacement and coronary bypass surgery in patients with aortic stenosis and significant coronary artery disease has been documented (35,36). We do not believe that these results can be applied on the particular subgroup of patients where the hemodynamic significance of a coronary stenosis is questionable. Valve replacement alone decreases myocardial oxygen demand and will also normalize coronary flow patterns (37).

The patients in this study were not compared to scintigraphic normal values in subjects without CAD and aortic stenosis. The pattern of thallium distribution in our patients with aortic stenosis but without CAD is similar to previously published patterns (24). The normal curves in the present study tend to be lower in some regions than the Iowa normals (24).

The value of a diagnostic method cannot be fully determined until specificity is evaluated; true specificity cannot be determined from the present study. It is not appropriate to calculate specificity on the same patient group used to provide the range, -2 s.d. and -2.5 s.d. limits of normal. Also, calculating the standard deviation from a material that is normalized to the maximum is not universally considered to be statistically correct, however, it is a widely used method and we think that it is feasible to describe the lower limit of normal. To calculate specificity, a prospective study should be performed. Nevertheless, using the range method, scintigraphy and angiography agreed in 75% of 141 vessel territories indicating a fair specificity, especially since there was no attempt to correct for individual variations in coronary anatomy or variation in coronary perfusion regarding the apical region.

In this study, the low number of patients without CAD is partly due to the exclusion of all patients with angiographically insignificant stenosis, e.g., an area reduction of less than 75% from the normal group. Because of difficulties in determining the hemodynamic effect of a stenosis by angiography, we only included patients without any sign of CAD to calculate the normal distribution of ^{201}Tl . Also, patients were excluded from the reference group who had an echocardiographically verified localized left ventricular hypokinesia, which might be due to a previous myocardial infarction thus causing a scintigraphic defect, as well as one patient with left bundle-branch block, which is also known to effect scintigraphic images. No patient with angiographically significant or insignificant coronary lesions had a left bundle-branch block. Another reason for the low number of patients without CAD in the present study is the older age of the study population.

Gender differences in normal scintigraphic findings have been reported (13). The present study does not include enough patients to allow us to reliably calculate normal limits for men and women separately. Even though no

gender specific limits were used, we found a high sensitivity for angiographically significant CAD. With a larger patient group allowing separate normal limits for men and women, the performance of the test may increase further.

CONCLUSION

The present study establishes the normal distribution of ^{201}Tl uptake in patients with aortic stenosis using dipyridamole to increase coronary blood flow. We conclude that dipyridamole ^{201}Tl SPECT seems to be safe even in patients with aortic stenosis, however, larger studies are needed to better assess safety. Computer-assisted evaluation gives a high sensitivity for angiographically significant coronary artery stenoses in patients with aortic stenosis using the lower limit of range as the discriminating threshold.

ACKNOWLEDGMENTS

This study was supported by the Umeå University Research foundation.

REFERENCES

1. Hatle L, Angelsen BA, Tromsdal A. Noninvasive assessment of aortic stenosis by Doppler ultrasound. *Br Heart J* 1980;43:284-292.
2. Hegrenæs L, Hatle L. Aortic stenosis in adults. Noninvasive estimation of pressure differences by continuous wave Doppler echocardiography. *Br Heart J* 1985;54:396-404.
3. Skjærpe T, Hegrenæs L, Hatle L. Noninvasive estimation of valve area in patients with aortic stenosis by Doppler ultrasound and two-dimensional echocardiography. *Circulation* 1985;72:810-818.
4. Teien D, Karp K, Eriksson P, Bjerle P, Osterman G. Noninvasive determination of the valve area in aortic valve disease by Doppler echocardiography and radionuclide angiography. *Int J Cardiol* 1987;15:205-214.
5. Grayburn P, Smith M, Harrison M, Gurley J, Demaria A. Pivotal role of aortic valve area calculation by the continuity equation for Doppler assessment of aortic stenosis in patients with combined aortic stenosis and regurgitation. *Am J Cardiol* 1988;61:376-381.
6. Skjærpe T, Hegrenæs L, Bathen J. Evaluation of the optimal level for noninvasive measurement of cardiac output in the left ventricular outflow tract and the ascending aorta. Comparison with two invasive methods. In: Skjærpe T. *Noninvasive quantification of global parameters on left ventricular function: the systolic pulmonary artery pressure and cardiac output*, Dissertation. Tapir, Trondheim; 1987:24-29.
7. Karp K, Teien D, Eriksson P. Doppler echocardiographic assessment of the valve area in patients with atrioventricular valve stenosis by application of the continuity equation. *J Intern Med* 1989;225:261-266.
8. Abbasi A, Allen MW, DeCristofaro D, Ungar I. Detection and estimation of the degree of mitral regurgitation by range-gated pulsed Doppler echocardiography. *Circulation* 1980;61:143-147.
9. Ciobanu M, Abbasi AS, Allen M, Hermer A, Spellberg P. Pulsed Doppler echocardiography in the diagnosis and estimation of severity of aortic insufficiency. *Am J Cardiol* 1982;49:339-343.
10. Pantely GA. Interaction of coronary artery disease and valvular heart disease. In: Greenberg B, Murphy E, eds. *Valvular heart disease*. Littleton: PSG Publishing Company; 1987:192-203.
11. Paquay PA, Anderson G, Diefenthal H, et al. Chest pain as a predictor of coronary artery disease in patients with obstructive aortic valve disease. *Am J Cardiol* 1976;38:863-869.
12. Fintel DJ, Links JM, Brinker JA, et al. Improved diagnostic performance of exercise thallium-201 single photon emission computed tomography over planar imaging in the diagnosis of coronary artery disease: a receiver operating characteristic analysis. *J Am Coll Cardiol* 1989;13:600-612.
13. DePasquale EE, Nody AC, DePuey EG, et al. Quantitative rotational thallium-201 tomography for identifying and localizing coronary artery disease. *Circulation* 1988;77:316-327.
14. Bailey IK, Come PC, Kelly DT, et al. Thallium-201 myocardial perfusion imaging in aortic valve stenosis. *Am J Cardiol* 1977;40:889-899.
15. Pfisterer M, Müller-Brand J, Bründler H, Cueni T. Prevalence and signifi-

- cance of reversible radionuclide ischemic perfusion defects in symptomatic aortic valve disease patients with or without concomitant coronary disease. *Am Heart J* 1982;103:92-96.
16. Huikuri HV, Korhonen UR, Heikkilä J, Takkunen JT. Detection of coronary artery disease by thallium scintigraphy in patients with valvar heart disease. *Br Heart J* 1986;56:146-151.
 17. Kupari M, Virtanen KS, Turto H, et al. Exclusion of coronary artery disease by exercise thallium-201 tomography in patients with aortic valve stenosis. *Am J Cardiol* 1992;70:625-640.
 18. Gould KL. Noninvasive assessment of coronary stenoses by myocardial imaging during pharmacological coronary vasodilatation. I. Physiologic basis and experimental validation. *Am J Cardiol* 1978;41:279-287.
 19. Gould KL, Westcott RJ, Albro PC, Hamilton GW. Noninvasive assessment of coronary stenoses by myocardial imaging during pharmacological coronary vasodilatation. II. Clinical methodology and feasibility. *Am J Cardiol* 1978;41:279-287.
 20. Huikuri HV, Korhonen UR, Ikäheimo MJ, Heikkilä J, Takkunen JT. Detection of coronary artery disease by thallium imaging using a combined intravenous dipyridamole and isometric handgrip test in patients with aortic valve stenosis. *Am J Cardiol* 1987;59:336-340.
 21. Aubry P, Assayag P, Faraggi M, et al. Détection d'une maladie coronarienne avant chirurgie valvulaire. *Ann Cardiol Angéiol* 1991;40:9-13.
 22. Stratman HG, Kennedy HL. Evaluation of coronary artery disease in patients unable to exercise: alternatives to exercise stress testing. *Am Heart J* 1989;117:1344-1365.
 23. Iskandrian AS, Jaekyeong H, Askenase A, Segal BL, Auerbach N. Dipyridamole cardiac imaging. *Am Heart J* 1988;115:432-443.
 24. Francisco DA, Collins SM, Go RT, Ehrhardt JC, Van Kirk OC, Marcus ML. Tomographic thallium-201 myocardial perfusion scintigrams after maximal coronary artery vasodilatation with intravenous dipyridamole. *Circulation* 1982;66:370-379.
 25. Sahn DJ, De Maria A, Kisslo J, Weyman A. Recommendations regarding quantitation in M-mode echocardiography: results of a survey of echocardiographic measurements. *Circulation* 1978;58:1072-1083.
 26. Troy BL, Pombo J, Rackley CE. Measurements of left ventricular wall thickness and mass by echocardiography. *Circulation* 1972;45:602-611.
 27. Levy D, Savage DD, Garrison RJ, Anderson KM, Kannel WB, Castelli WP. Echocardiographic criteria for left ventricular hypertrophy: the Framingham Heart Study. *Am J Cardiol* 1987;59:956-960.
 28. Younis LT, Chaitman BR. Update in intravenous dipyridamole cardiac imaging in the assessment of ischemic heart disease [Review]. *Clin Cardiol* 1990;13:3-10.
 29. Borg G, Linderholm H. Exercise performance and perceived exertion in patients with coronary insufficiency, arterial hypertension and vasoregulatory asthenia. *Acta Med Scand* 1970;187:17-26.
 30. Greenberg B, Massie B. Beneficial effects of afterload reduction therapy in patients with congestive heart failure and moderate aortic stenosis. *Circulation* 1980;61:1212-1216.
 31. Ikram H, Low C, Crozier I, Shirlaw T. Hemodynamic effects of nitroprusside on valvular aortic stenosis. *Am J Cardiol* 1992;69:361-366.
 32. Zir L, Miller S, Dinsmore R, Gilbert J, Harthorne W. Interobserver variability in coronary angiography. *Circulation* 1976;53:627-632.
 33. DeRouen T, Murray J, Owen W. Variability in the analysis of coronary arteriograms. *Circulation* 1977;55:324-328.
 34. White CW, Wright CB, Doty DB, et al. Does visual interpretation of the coronary angiogram predict the physiologic importance of a coronary stenosis? *N Engl J Med* 1984;310:819-824.
 35. Czer L, Gray, R, Stewart M, et al. Reduction in sudden late death by concomitant revascularization with aortic valve replacement. *Thorac Cardiovasc Surg* 1988;95:390-401.
 36. Jones M, Schofield PM, Brooks NH, et al. Aortic valve replacement with combined myocardial revascularisation. *Br Heart J* 1989;62:9-15.
 37. Yoshikawa J, Akasaka T, Yoshida K, Takagi T. Systolic coronary flow reversal and abnormal diastolic flow patterns in patients with aortic stenosis: assessment with an intracoronary Doppler catheter. *J Am Soc Echo* 1993;6:516-524.