Unilateral Absence of Right-Lung Perfusion with Normal Ventilation on Radionuclide Lung Scan as a Sign of Aortic Dissection

Suzanne M. Slonim, Christopher P. Molgaard, Imran T. Khawaja and David W. Seldin

Departments of Diagnostic Radiology and Pulmonary and Critical Care Medicine, Lahey Clinic Medical Center, Burlington, Massachusetts

A case of aortic dissection with unilateral absence of right-lung perfusion and normal ventilation on radionuclide ventilation/perfusion (V/Q) lung scan is presented with a review of the literature. Anticoagulation or thrombolytic therapy for presumed pulmonary embolism may be catastrophic if the clinical syndrome and V/Q scan appearance are instead due to aortic dissection. With this V/Q scan appearance, these therapies should not be instituted unless pulmonary embolism is diagnosed by pulmonary arteriography.

Key Words: aortic dissection; ventilation/perfusion lung scan; pulmonary embolism

J Nucl Med 1994; 35:1044–1047

Lung scans demonstrating unilateral absence of perfusion with preserved ventilation are rare. Aortic dissection with mediastinal hematoma compressing the right pulmonary artery may have this appearance and may be clinically confused with pulmonary embolism. Anticoagulation or thrombolytic therapy for presumed pulmonary embolism may be catastrophic if the clinical syndrome and absence of right lung perfusion are the result of aortic dissection. Such a case is presented, and prior reported cases are reviewed.

CASE REPORT

A previously healthy 48-yr-old man presented to an outside hospital after a syncopal episode at work. He was alert and oriented, with a respiratory rate of 20 per min, pulse rate of 120 per min and blood pressure 96/60. He had no chest pain. Initial physical examination was notable for jugular venous distention to the angle of the mandible. The carotid pulses were normal. Cardiac, pulmonary and abdominal examinations were otherwise unremarkable. Lower extremity pulses were not recorded. Varicose veins with chronic venous stasis changes were noted in both lower extremities. Arterial blood gas on room air revealed a pH of 7.38, PCO_2 of 32, PO_2 of 59, bicarbonate of 19, with an A-a oxygen gradient of 51.

A portable supine chest radiograph (Fig. 1) and a ^{99m}Tc-diethylenetriaminepentaacetic acid (DTPA) aerosol ventilation scan (Fig. 2A) were normal. A ^{99m}Tc macroaggregated albumin (MAA) perfusion lung scan (Fig. 2B) demonstrated absent perfusion to the right lung with normal perfusion to the left lung. The radionuclide study was interpreted as most suggestive of pulmonary artery obstruction by tumor, with pulmonary embolism a much less likely possibility. Computed tomography of the chest with intravenous drip infusion contrast enhancement was obtained. No definite mediastinal or hilar mass was seen. Contrast enhancement of the main and left pulmonary arteries was present, with no enhancement of the right pulmonary artery (Fig. 3). This was interpreted as consistent with an embolism in the right pulmonary artery. Even with retrospective review, no mediastinal hematoma, aortic intimal flap or false lumen was seen to suggest aortic dissection.

Based on the clinical presentation and diagnostic studies, the diagnosis of massive pulmonary embolism was made. Intravenous streptokinase therapy was initiated, and the patient was transferred to our institution for further management.

Doppler examination of the lower extremities demonstrated no evidence of deep venous thrombosis. Thrombolytic therapy was continued. The patient's status deteriorated over the next few

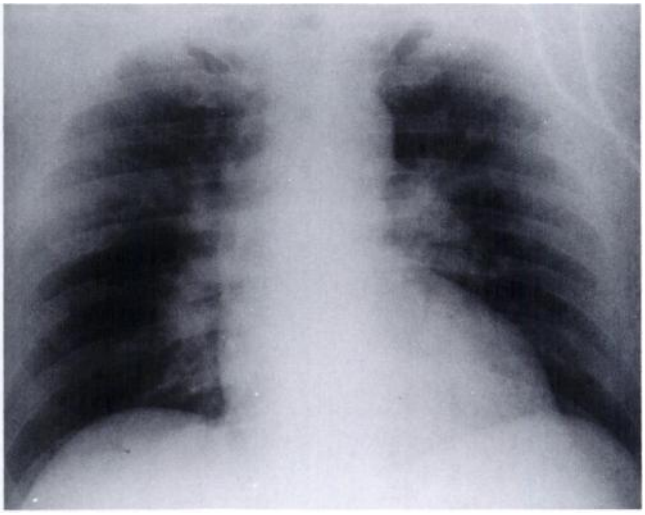

FIGURE 1. Portable supine chest x-ray is normal.

Submitted Nov. 8, 1993; accepted Jan. 20, 1994.

For correspondence and reprints contact: David W. Seldin, MD, Department of Radiology, Lahey Clinic Medical Center, 41 Mall Road, Burlington, MA 01805.

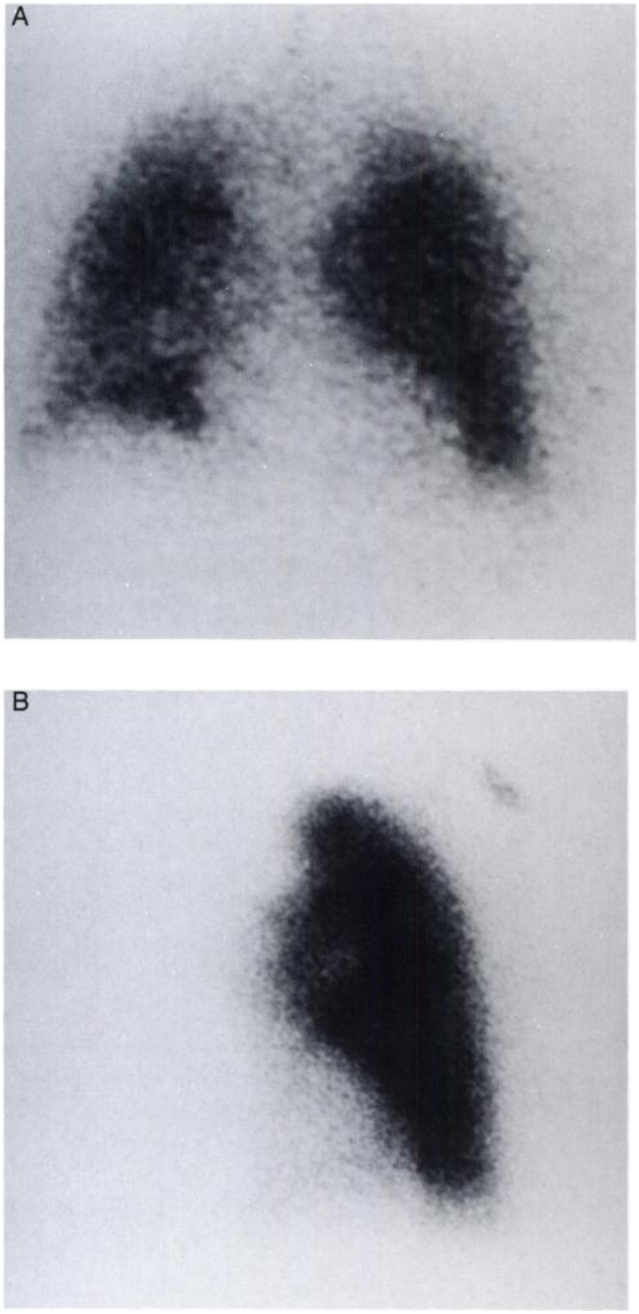

FIGURE 2. (A) Anterior view of the radionuclide ventilation scan demonstrates normal ventilation bilaterally. (B) Anterior view of the radionuclide perfusion scan demonstrates absent perfusion of the right lung with normal perfusion of the left lung.

hours, with progressive hypotension and acidosis. He required intubation and died shortly thereafter.

Autopsy revealed a dissection of the ascending aorta with rupture. There was acute and organizing mediastinal hematoma causing compression of the right pulmonary artery. The dissection began 3 cm above the aortic valve and extended 6 cm up the right side of the ascending aorta. There was no evidence of pulmonary embolism.

DISCUSSION

The demonstration of absence of perfusion to one lung is an uncommon finding on radionuclide lung scans, occurring in 13 of 607 patients (2%) in one series of perfusion lung scans (*1*). This appearance classically suggests bronchogenic carcinoma obstructing the pulmonary artery. Less common entities in the differential diagnosis include massive pulmonary embolism, severe pleural or parenchymal disease, surgically corrected congenital heart disease, the Swyer-James syndrome and pneumonectomy (*1,2,3*). Of these, normal ventilation may be obtained in bronchogenic carcinoma, surgically corrected congenital heart disease and pulmonary embolism. Although not included in the classic differential diagnosis, compression of the right pulmonary artery by hemorrhage from an aortic dissection can also present as unilaterally absent perfusion with normal ventilation on radionuclide lung scan. Five prior cases of aortic dissection resulting in compression of the right pulmonary artery have been reported (*4–8*). No reports of aortic dissection resulting in compression of the left pulmonary artery were found.

The clinical features of these cases and our case have been summarized in Table 1. Four of the six patients were men, with ages ranging from 48 to 68 yr (mean age 59 yr). Two of the patients were started on anticoagulation and one was started on thrombolytic therapy for a presumed diagnosis of pulmonary embolism based on their clinical presentation. All dissections involved the ascending aorta (Stanford Type A dissections) (*9*). Surgical repair of the dissection was attempted in two of the six patients (*5,6*). The outcome was death in all patients for whom follow-up

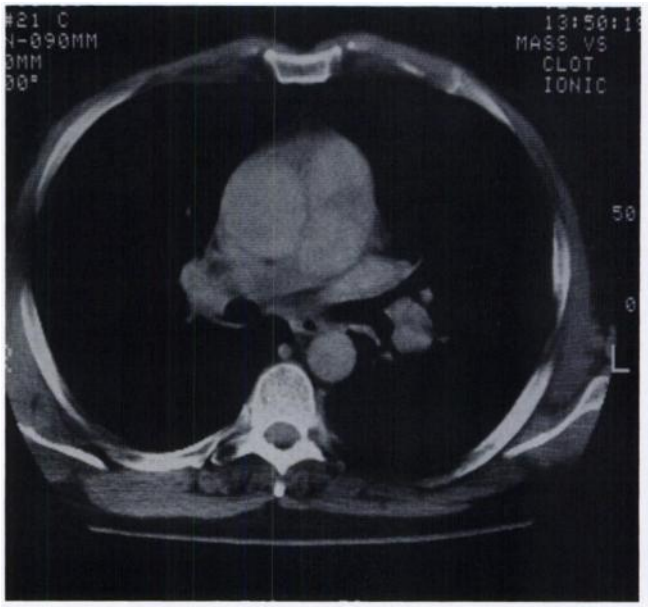

FIGURE 3. Computed tomography at the level of the pulmonary arteries and ascending aorta demonstrates contrast enhancement of the main and left pulmonary arteries without enhancement of the right pulmonary artery. No intimal flap or false lumen is seen in the ascending aorta.

TABLE 1
Clinical Features of Cases of Aortic Dissection Compressing the Pulmonary Artery

Patient no.	Reference	Age	Sex	Anticoagulation/ Thrombolysis	Outcome	Time from presentation to death
1	(*4*)	57	M	none	death	9 hours
2	(*5*)	52	F	none	death	10 days; surgical repair on day of presentation
3	(*6*)	66	M	heparin	death	9 days; attempted surgical repair on day 9
4	(*7*)	68	F	none	unknown	unknown
5	(*8*)	62	M	heparin	death	greater than 24 hours, shortly after angiogram
6	(present case)	48	M	streptokinase	death	14 hours

data is available (five of six patients). The minimum length of time from presentation to death was 9 hr.

The imaging features of the cases have been summarized in Table 2. When performed, perfusion scan demonstrated unilateral absence of right lung perfusion in four of four cases. The three patients who underwent ventilation scan showed largely normal ventilation in the non-perfused lung. Even retrospectively, computed tomography (CT) did not definitely demonstrate aortic dissection or compression of the pulmonary artery in the one patient in whom it was performed (present case). Echocardiography in a single patient did not demonstrate the aortic dissection (*8*). Pulmonary arteriography was performed in three patients (*5,6,8*) and demonstrated the extrinsic compression of the pulmonary artery. Each of these pulmonary arteriograms demonstrated the aortic dissection during the levophase of the study. Confirmatory aortic arteriography was performed in two of these cases (*6,8*). Aortic arteriography without pulmonary arteriography was performed in a single case (*7*) and demonstrated the aortic dissection.

Lung scans that demonstrate unilateral absence of right lung perfusion with largely normal ventilation should raise the suspicion of aortic dissection with compression of the right pulmonary artery when no clear evidence of central tumor exists. The clinical features of aortic dissection with compression of the pulmonary artery may be similar to clinical features of pulmonary embolism. Anticoagulation or thrombolytic therapy for presumed pulmonary embolism may be catastrophic when the clinical syndrome is instead due to aortic dissection. In instances of absent perfusion to the right lung without evidence of central tumor, pulmonary arteriography is important to determine if the findings are the result of pulmonary embolism prior to initiating therapy. If a pulmonary embolism is not identified and the right pulmonary artery is extrinsically compressed, the aorta should be evaluated to exclude dissection. Despite the failure of attempted surgical repair in the reported cases, prompt diagnosis of aortic dissection may permit lifesaving aortic repair.

TABLE 2
Imaging Features of Cases of Aortic Dissection Compressing the Right Pulmonary Artery

Patient no.	Reference	Perfusion Scan	Ventilation Scan	Angiogram	Comment
1	(*4*)	none	none	none	right PA compressed at autopsy
2	(*5*)	none	none	pulmonary	
3	(*6*)	right lung absent, patchy defects left lung	none	pulmonary, aortic	prosthetic aortic valve, not involved in dissection
4	(*7*)	right lung absent	right upper lung absent	aortic	
5	(*8*)	right lung absent	right lung heterogeneous	pulmonary, aortic	echocardiogram did not show dissection
6	(present case)	right lung absent	normal	none	CT did not show dissection

PA = pulmonary artery; CT = computed tomography.

REFERENCES

1. White RI, James AJ, Wagner HN. The significance of unilateral absence of pulmonary artery perfusion by lung scanning. *Am J Roentgenol Radium Ther Nucl Med* 1971;111:501–509.
2. Datz FL. *Gamuts in nuclear medicine*. Norwalk, CT: Appleton-Century-Crofts; 1983:116.
3. Silberstein EB, McAfee JG. *Differential diagnosis in nuclear medicine*. New York, NY: McGraw-Hill; 1984:267–268.
4. Buja LM, Ali N, Fletcher RD, Roberts WC. Stenosis of the right pulmonary artery: a complication of acute dissecting aneurysm of the ascending aorta. *Am Heart J* 1972;83:89–92.
5. Nasrallah A, Goussous Y, El-Said G, Garcia E, Hall RJ. Pulmonary artery compression due to acute dissecting aortic aneurysm: clinical and angiographic diagnosis. *Chest* 1975;67:228–230.
6. Charnsangavej C. Occlusion of the right pulmonary artery by acute dissecting aortic aneurysm. *Am J Roentgenol* 1979;132:274–276.
7. Wood M. Ventilation-perfusion mismatch: lung imaging. *Clin Nucl Med* 1983;4:181.
8. Tiu S, Toth PJ, Banner HJ, Kramer EL, Sanger JJ. Aortic aneurysm dissection causing V/Q mismatch. *Clin Nucl Med* 1988;13:190–191.
9. Daily PO, Trueblood HW, Stinson FB, Wuerflein RD, Shumway NE. Management of acute aortic dissections. *Ann Thorac Surg* 1970;10:237–246.