

Scintigraphic Detection of Hemobilia Complicating Angiodysplasia

William M. Yudt, Eugene D. Silverman and Aaron M. Kistler

Division of Nuclear Medicine, National Naval Medical Center; and the Uniformed Services University of the Health Sciences, Bethesda, Maryland

A 78-yr-old man underwent ^{99m}Tc -labeled red cell examination for a gastrointestinal bleeding episode. Gallbladder visualization was noted during the examination. Hemobilia has been reported in a variety of pathologic conditions; scintigraphic gallbladder visualization has also been reported as a result of the unusual radiolabeling characteristics of ^{99m}Tc during red cell scintigraphy. Postmortem examination revealed angiodysplasia of the gallbladder and other sites in the gastrointestinal tract. Angiodysplasia must be considered in the pathologic spectrum of causes of hemobilia.

Key Words: hemobilia; angiodysplasia; gastrointestinal hemorrhage

J Nucl Med 1994; 35:870-871

Scintigraphic techniques to identify gastrointestinal hemorrhage are well documented. In particular, ^{99m}Tc -labeled red cell scintigraphy offers an advantage of delayed imaging (1,2). When the examination with labeled red cells reveals radiotracer within the gallbladder, the pathologic causes of hemobilia must be considered as well as the possibility of altered biodistribution of ^{99m}Tc . A case of early visualization of the gallbladder is described with the attendant pathologic findings of angiodysplasia of the gallbladder and gastrointestinal tract.

CASE REPORT

A 78-yr-old man presented with rectal bleeding. There was no history of similar episodes. On admission, his pulse rate was 122/min, and his blood pressure was 160/90 mmHg, with a negative tilt test result. The abdomen was soft and nontender with normally active bowel sounds. Digital rectal examination yielded dark red blood.

Laboratory tests on admission yielded a hemoglobin level of 139 g/liter, hematocrit of 0.428, normal erythrocyte indices, a white blood cell count of 8.2×10^9 /liter, prothrombin time of 11.4 sec, partial thromboplastin time of 21.7 sec, the total bilirubin of 10.3 $\mu\text{mole/liter}$ (0.6 ml/dl), blood urea nitrogen of 11.8 $\mu\text{mole/liter}$ (33 mg/dl) and creatinine of 186 $\mu\text{mole/liter}$ (2.1 mg/dl).

A modified in vitro ^{99m}Tc -labeled red blood cell examination

was performed by intravenous administration of 15 mg of stannous pyrophosphate, harvesting of 10 ml of red cells 20 min later and incubation with 1.110×10^3 MBq (30 mCi) ^{99m}Tc -pertechnetate for 20 min before reinjection. Early images of the abdomen revealed typical distribution of labeled red cells in the heart, great vessels and abdominal viscera, with some attenuation of activity because of a large body habitus and possible splanchnic vasoconstriction in response to blood loss. Activity in the gallbladder, noted within 60 min of injection, intensified in a delayed image (Fig. 1). Intravenous injection of 1.5 μg of cholecystokinin resulted in prompt evacuation of tracer from the gallbladder (Fig. 2). At no time was free pertechnetate seen in the stomach. An ultrasonic examination of the hepatobiliary region excluded cholelithiasis, a dilated bile duct and thickening of the gallbladder wall. Endoscopic gastroduodenoscopy revealed small erosions but no ulcers or blood. Colonoscopy to the cecum revealed diverticulosis of the sigmoid region and blood-tinged fluid but no evidence of active bleeding.

By the second day, the hematocrit had dropped to 0.26, and two units of packed red blood cells were transfused. There were no clinical or laboratory findings of hemolysis. Signs of alcohol withdrawal and delirium tremens intervened. The patient became hypotensive but responsive to pressor therapy. He had a fatal cardiac arrest.

Necropsy established severe coronary atherosclerosis complicated by acute myocardial infarction as the cause of death. The anatomic diagnosis of angiodysplasia involving the stomach, gallbladder, intestine and cecum was made. The gastrointestinal tract contained no evidence of recent active hemorrhage. Petechiae were present diffusely in the gastric mucosa and in patchy distribution in the gallbladder, duodenum, jejunum, ileum, cecum and ascending colon. The liver was passively congested. No calculi were present in the biliary tract. The gallbladder contained dark green bile. Microscopy revealed multiple ectatic blood vessels in the submucosa of the gallbladder (Fig. 3), stomach and small intestine. In the cecum, transverse colon and sigmoid colon, the ectatic blood vessels in the lamina propria included arterioles and venules.

DISCUSSION

Hemobilia is uncommon. It may result from hepatic trauma and vascular malformations of the hepatic vessels (3,4). Hemobilia has been reported in papillary cystadenocarcinoma of the bile ducts and in heterotopic stomach in the gallbladder neck (5,6). Visualization of the gallbladder during ^{99m}Tc -labeled red blood cell scintigraphy may result presumably from altered biodistribution of ^{99m}Tc -labeled

Received Sept. 20, 1993; revision accepted Jan. 20, 1994.
For correspondence or reprints contact: Eugene D. Silverman, MD, Division of Nuclear Medicine, National Naval Medical Center, Bethesda, MD 20889-5000.

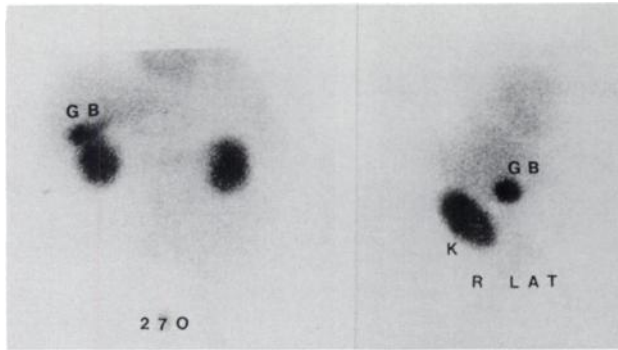


FIGURE 1. Scintigram of the abdomen using ^{99m}Tc -labeled autologous erythrocytes at 270 min postinjection in anterior and right lateral projections reveal increasing activity within the gallbladder (GB) and kidneys (K). Large body habitus and splanchnic vasoconstriction are responsible for lack of definition of blood-pool structures seen in the early images.

beta chains which, following hemolysis of red cells, appear as heme moieties in the gallbladder. Artifactual visualization in the gallbladder four or more hours postinjection has been associated with renal insufficiency, previous transfusion and anemia (7-10). Caslowitz et al. (11) suggested that early (less than 1 hr postinjection) gallbladder visualization in two patients occurred as a result of ^{99m}Tc binding to plasma proteins, with shapes and net charges altered by intravenous contrast.

In the present case, gallbladder visualization was seen early in a patient who had no predisposing factors to alter the biodistribution of the ^{99m}Tc -labeled red blood cells. There was no evidence of renal failure or hemolysis or a history of a contrast load. No other factors previously associated with hemobilia were present: trauma, vascular malformation, heterotopic gastric mucosa or tumor. A postmortem examination revealed petechiae in the stomach, small bowel and gallbladder, which microscopically showed submucosal groupings of ectatic vessels of capillary, arteriolar and venular size consistent with angiodysplasia. Angiodysplasia affecting the gallbladder wall should

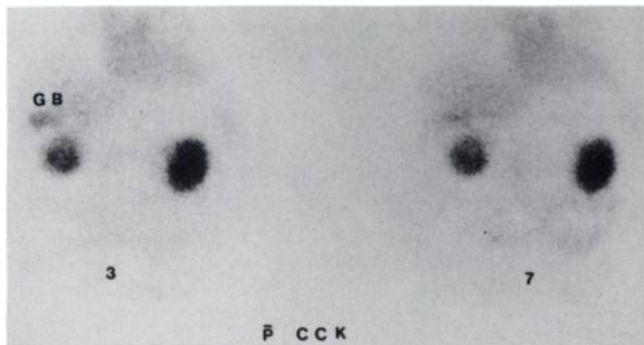


FIGURE 2. Scintigrams using ^{99m}Tc -labeled autologous erythrocytes at 3 and 7 min postinjection of 1.5 μg of cholecystikinin (CCK) intravenously indicate prompt evacuation of radiotracer from the gallbladder (GB).

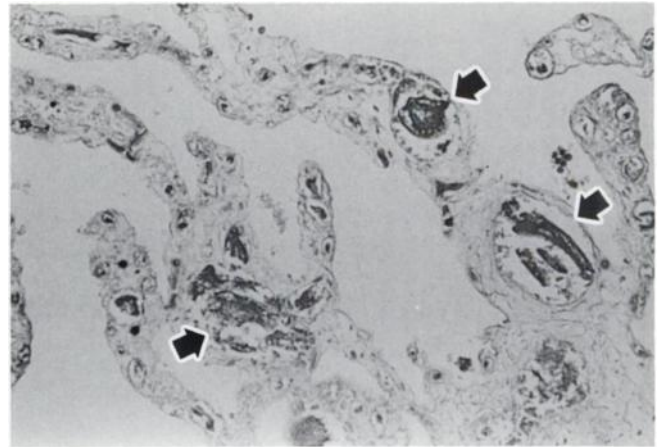


FIGURE 3. Postmortem photomicrograph of the gallbladder. Arrows indicate three of the multiple ectatic capillaries within the submucosa. The absence of epithelium is caused by autolysis (hematoxylin and eosin, $\times 200$). Similar findings of angiodysplasia occur in stomach, small intestine and cecum.

be added to the differential diagnosis of hemobilia and should be considered in the unusual cases of gallbladder visualization during ^{99m}Tc -labeled red cell scintigraphy.

ACKNOWLEDGMENTS

The authors thank M. Albahra, MD, and R. W. Lieberman, MD, for detailed postmortem examination, clinicopathologic correlation and preparation of photomicrographs. The opinions and assertions contained herein are the private ones of the authors and are not to be construed as official policy or reflecting the views of the Department of the Navy or the Department of Defense.

REFERENCES

- Voeller GR, Bunch G, Britt LG. Use of technetium-labelled red cell scintigraphy in the detection and management of gastrointestinal hemorrhage. *Surgery* 1991;110:799-804.
- Alavi A. Scintigraphic detection and localization in gastrointestinal bleeding sites. In: Gottschalk A, Hoffer PB, Potchen EJ, eds., *Diagnostic nuclear medicine*, 2nd edition. Baltimore: Williams and Wilkins; 1988:631-662.
- Vlahos L, Kalovidouris A, Gouliamos A, Kailidou E. Post-traumatic hemobilia. *Eur J Radiol* 1991;13:199-202.
- Stauffer JT, Weinman MD, Bynum TE. Hemobilia in a patient with multiple hepatic artery aneurysms: a case report and review of the literature. *Am J Gastroenterol* 1989;84:59-62.
- Alapati RA, Ibrahim MAH, D'Angelo DM, et al. Papillary cystadenocarcinoma of the bile ducts resulting in hemobilia. *Am J Gastroenterol* 1989;84:1564-1566.
- Adam RA, Fabiani B, Bismuth H. Hematobilia resulting from heterotopic stomach in the gallbladder neck. *Surgery* 1989;105:564-569.
- Wood MJ, Hennigan DB. Radionuclide tagged red blood cells in the gallbladder. *Clin Nucl Med* 1984;9:289-290.
- Brill DR. Gallbladder visualization during technetium-99m-labeled red blood cell scintigraphy for gastrointestinal bleeding. *J Nucl Med* 1985;26:1408-1411.
- Kotlyarov EV, Mattay VS, Reba RC. Gallbladder visualization during technetium-99m blood pool imaging. *Clin Nucl Med* 1988;13:515-516.
- Abello R, Haynie TP, Kim EE. Pitfalls of a ^{99m}Tc -RBC bleeding study due to gallbladder and ileal loop visualization. *Gastrointest Radiol* 1991;16:32-34.
- Caslowitz P, Achong DM. Early gallbladder visualization during Tc-99m RBC scintigraphy. *Clin Nucl Med* 1992;17:364-365.