Lung Tumor Metastasis to Breast Detected by Fluorine-18-Fluorodeoxyglucose PET

George J. Hunter, Noah C. Choi, Theresa C. McLoud and Alan J. Fischman

Department of Radiology, PET Center and Department of Radiation Oncology, Massachusetts General Hospital, Boston, Massachusetts

We report a case of breast metastasis from a large-cell bronchogenic adenocarcinoma. Serial ^{18}F-fluorodeoxyglucose (FDG) positron emission tomography (PET) was used to monitor the response of the primary lesion to radiation therapy. In the 7-wk interval between studies, an area of markedly increased FDG uptake appeared in the right breast. On subsequent biopsy this proved to be a metastatic deposit from the primary lesion. breast metastasis is uncommon. The ability of FDG-PET to detect metastatic lesions from primary lung tumor is variable. In this case, the finding of the new breast lesion resulted in introduction of chemotherapy to the treatment program.

J Nucl Med 1993; 34:1571–1573

Primary bronchogenic carcinoma is a common cause of mortality and morbidity worldwide. The increased incidence of these tumors is attributable mainly to smoking and, to a lesser extent, atmospheric pollution. In the USA alone, there were 161,000 new cases and 143,000 deaths due to lung carcinoma in 1991. It is the most frequent fatal malignancy in men and has overtaken breast cancer as the most common malignancy in women (*1*). One of the characteristics of these tumors is that they may remain occult until an advanced stage of growth. This results in substantial numbers of patients with advanced disease in whom accurate staging is necessary for correct management and prognosis. Traditionally, such evaluation included plain radiography, computed tomography (CT) and bone scintigraphy. More recently, the use of magnetic resonance imaging (MRI) and positron emission tomography (PET) have excited interest as tools for the staging and management of malignancy (*2–4*).

PET is an attractive modality for tumor evaluation. Changes in tumor pathophysiology occur before the onset of gross anatomical evidence of tumor regression or progression. PET is primarily a tool for the demonstration of function. In the context of cancer, many early workers have shown that tumors are more metabolically active than adjacent normal tissue and have a profound influence on their local vascular supply (*5–8*). It is logical therefore, to use a robust metabolic marker such as ^{18}F-fluorodeoxyglucose (FDG) to determine both tumor activity and extent of spread. The use of PET with FDG is becoming increasingly common for initial tumor assessment and subsequent response to therapy.

Primary carcinoma of the lung falls into four major categories (percentage of all lung cancer is given in parentheses): (1) epidermoid (squamous cell) carcinoma (25%–40%); (2) small cell carcinoma (18%–25%); (3) adenocarcinoma (20%–35%); and (4) large cell, anaplastic carcinoma (10%–15%) (*9*). The time of diagnosis and the metastatic potential of these tumor classes varies. Epidermoid carcinoma is a relatively slow growing and late metastasizing tumor. The large cell anaplastic carcinoma is similar to the epidermoid in that it is slow growing, but it metastasizes early. PET can be especially useful in those patients presenting with stage IIIb or IV in whom aggressive radiotherapy combined with adjunct procedures such as chemotherapy and surgery is the only option for treatment. Under these circumstances, PET may be invaluable as a method for monitoring the activity and spread of the tumor. Decreased activity or reduction in the amount of metabolically active tissue are markers of effective local therapy. The characteristics of FDG imaging can differ between tumors and indeed in the same tumor tissue present in different sites, e.q., brain metastasis from a primary lung tumor. We have found that primary lung tumors lend themselves well to the use of PET in their management. Occasionally PET has discovered a metabolically active metastasis during repeated evaluation of response of the primary tumor to therapy. We present an unusual case of a large cell, poorly differentiated lung malignancy with breast metastasis, producing a 1-cm^3 nodule of tissue within a 6-wk period.

CASE REPORT

A 57-yr-old woman presented with a history of dyspnea associated with cough. This led to a chest radiograph which showed a left hilar mass. A thoracic CT scan shortly after presentation showed a large left hilar mass with extension into the aortopul-

Received Jan. 26, 1993; revision accepted May 11, 1993.

For correspondence or reprints contact: Dr. George J. Hunter, Dept. of Radiology, MGH-NMR Center, Massachusetts General Hospital, Building 149, 13th St., Charlestown Navy Yard, Boston, MA 02129.

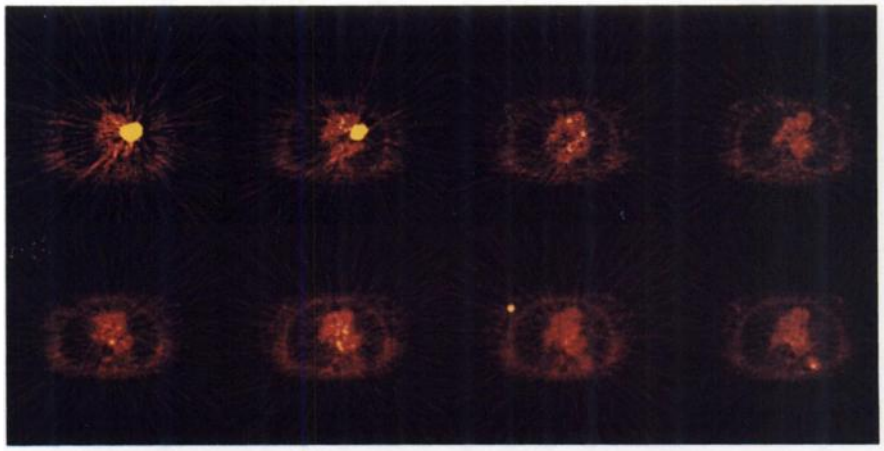

FIGURE 1. The top row of images is a series of four contiguous slices through the mid thorax from an ^{18}F-FDG study. The first two slices show markedly elevated activity in the left hilum corresponding to a primary, anaplastic cell lung tumor. The other two slices are included to show lack of activity in the breast region and posterior left hemithorax on the initial study. The bottom row of images acquired following therapy corresponds to the top row. Note the regression of the primary tumor. There is a new focus of activity in the right breast which proved to be a metastatic deposit. A second focus in the posterior left hemithorax subpleurally was probably due to inflammation rather than metastatic disease.

monary window. Further evaluation yielded a diagnosis of a poorly differentiated, large cell carcinoma. Head CT and bone scintigraphy did not reveal metastatic disease to the central nervous system or the skeleton. She had been a one pack per day smoker for 40 yr. Staging placed her as T3N2M0, an acceptable candidate for aggressive therapy. PET with 10 mCi of FDG and dynamic imaging for a total of 2 hr was performed immediately prior to radiotherapy in order to establish a baseline from which to monitor subsequent tumor regression. A highly metabolically active, multilobed mass was identified in the left hilum with direct tumor extension into the mediastinum. There were no other areas of abnormal FDG activity seen on initial scan (Fig. 1, top row).

Seven weeks later, after radiotherapy, a repeat FDG-PET scan was performed to ascertain the extent of remaining tumor activity. The primary tumor had regressed to a small, relatively inactive lesion. There was, however, a new, well defined area of markedly increased uptake within the right breast which was seen on one slice with lower activity present on two adjacent slices (Fig. 1, bottom row). An additional lesion was identified in the left thorax posteriorly on one slice. Subsequent CT scanning characterized this as an area of inflammation, but could not definitely exclude metastasis. No further investigation of this lesion was undertaken. The breast lesion was clearly absent from the initial PET scan which was confirmed by close review of the first study. CT and mammography were performed and demonstrated a well defined density in the upper outer quadrant of the right breast (Figs. 2 and 3). The lesion was excised and pathology examination revealed pleomorphic malignant cells with prominent nucleoli and cytological features similar to those seen in the primary lung lesion. Immunoperoxidase stains were positive, supporting the diagnosis that this was a carcinoma. Other stains were negative, ruling out malignant lymphoma and melanoma. Overall, the histological and histochemical features favored breast metastasis from the primary lung tumor. Following excision and treatment the patient has done well and remains symptom-free 9 mo after therapy.

DISCUSSION

In this case, PET clearly shows utility for elucidating distant metastatic disease. Since breast metastasis is so rare (<0.5% of all metastatic disease), it usually is discovered by accident rather than by active search (*10*). In some cases, the primary tumor is found only after routine screening has identified a breast lump diagnosed as secondary malignancy (*11*). In all cases, the high sensitivity of PET is able to identify tumor tissue, in a qualitative fashion. Unfortunately, it is currently impractical to perform routine total-body FDG-PET screens in cancer patients. Nevertheless, in selected areas, PET has an important and useful

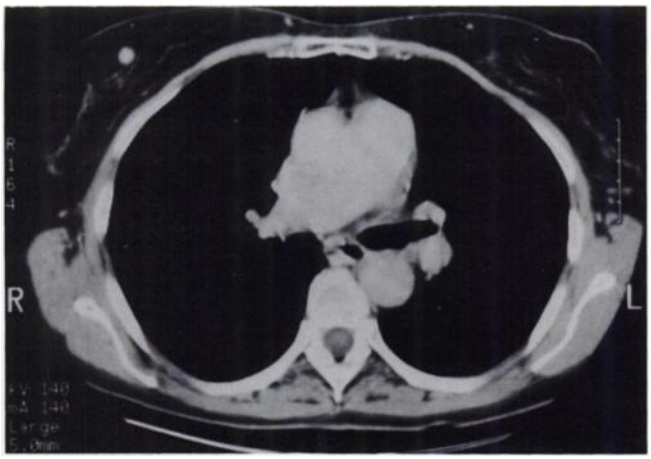

FIGURE 2. A single slice of a computed tomogram showing breast tissue and a high density, well circumscribed lesion present in the right breast, separate from the chest wall.

FIGURE 3. An oblique projection mammogram of the right breast showing a well circumscribed density in the upper outer quadrant.

role. A common area for lung tumor metastasis is the brain where multislice PET imaging can demonstrate the whole volume of search and add significantly to the accuracy of prognosis and the correct management path in a reasonable amount of time.

PET is not always useful; in some cases of proven secondary intracranial tumor, we have observed minimal activity on FDG scan (*unpublished data*). Reasons for this apparent heterogeneity of response in similar tissues found in different environments are unclear and form the basis of ongoing research (*12*).

In conclusion, FDG-PET studies of lung tumor patients may provide invaluable additional information about response to treatment, as well as the ability to identify metastases.

REFERENCES

1. Bragg DG. Current applications of imaging procedures in the patient with lung cancer. *Int J Radiat Oncol Biol Phys* 1991;21:847–851.
2. Nolop KB, Rhodes CG, Brudin LH, et al. Glucose utilization in vivo by human pulmonary neoplasms. *Cancer* 1987;60:2682–2689.
3. Ichiya Y, Kuwabara Y, Otsuka M, et al. Assessment of response to cancer therapy using fluorine-18-fluorodeoxyglucose and positron emission tomography. *J Nucl Med* 1991;32:1655–1660.
4. Batra P, Brown K, Aberle DR, Young DA, Steckel R. Imaging techniques in the evaluation of pulmonary parenchymal neoplasms. *Chest* 1992;101: 239–243.
5. Beaney RP, Lammertsma AA, Jones T, McKenzie CG, Halnan KE. Positron emission tomography for in vivo measurement of regional blood flow, oxygen utilisation and blood volume in patients with breast carcinoma. *Lancet* 1984;8369:131–134.
6. Mies G, Paschen W, Ebhardt G, Hossmann KA. Relationship between blood flow, glucose metabolism, protein synthesis, glucose and ATP content in experimentally-induced glioma (RG1 2.2) of rat brain. *J Neuro oncol* 1990;9:17–28.
7. Haberkorn U, Strauss LG, Reisser C, et al. Glucose uptake, perfusion, and cell proliferation in head and neck tumors: relation of positron emission tomography to flow cytometry. *J Nucl Med* 1991;32:1548–1555.
8. Hawkins RA. PET cancer evaluation with FDG [Editorial]. *J Nucl Med* 1991;32:1555–1556.
9. Allen HA, Stitik FP. Primary neoplasms of the lung, volume 1, In: Taveras JM, Ferrucci JT, eds. Radiology: diagnosis—imaging—intervention. Philadelphia: JB Lippincott; 1989;1–2.
10. Bohman LG, Basset LW, Gold RH, Voet R. Breast metastases from extramammary malignancies. *Radiology* 1982;144:309–312.
11. Hadju SI, Urban JA. Cancers metastatic to the breast. *Cancer* 1972;29: 1691–1696.
12. Fischman AJ, Alpert NM. FDG-PET in oncology: there's more to it than looking at pictures [Editorial]. *J Nucl Med* 1993;34:6–11.