

Med J 1988;64:4-17.

3. Walovitch RC, Williams SJ, LaFrance ND. Radiolabeled agents for SPECT imaging of brain perfusion. *Nucl Med Biol* 1990;17:77-83.
4. Gemmell HG, Evans NT, Besson JA, et al. Regional cerebral blood flow imaging: a quantitative comparison of technetium-99m-HMPAO SPECT with $C^{15}O_2$ PET. *J Nucl Med* 1990;31:1595-1600.
5. Anderson AR, Friberg HH, Schmidt JF, Hasselbalch SG. Quantitative measurements of cerebral blood flow using SPECT and ^{99m}Tc -d,l-HMPAO compared to xenon-133. *J Cereb Blood Flow Metab* 1988;8:S69-S81.
6. Yonekura Y, Nishizawa S, Mukai T, et al. SPECT with ^{99m}Tc -d,hexamethyl-propylene amine oxime (HM-PAO) compared with regional cerebral blood flow measured by PET: effects of linearization. *J Cereb Blood Flow Metab* 1988;8:S82-S89.
7. Neirinckx R, Canning L, Piper I, et al. Technetium-99m d,l-HM-PAO: a new radiopharmaceutical for SPECT imaging of regional cerebral blood perfusion. *J Nucl Med* 1987;28:191-202.
8. Leveille J, Demonceau G, De Roo M, et al. Characterization of ^{99m}Tc -L,L-ECD for brain perfusion imaging. Part 2. Biodistribution and brain imaging in humans. *J Nucl Med* 1989;30:1902-1910.
9. Vallabhajosula S, Zimmerman RE, Picard M, et al. Technetium-99m-ECD: a new brain imaging agent: in vivo kinetics and biodistribution studies in normal human subjects. *J Nucl Med* 1989;30:559-604.
10. Garrett K, Villanueva J, Kuperus J, Giombetti R, Mena I. A comparison of regional cerebral blood flow with Xe-133 to SPECT Tc-99m-ECD [Abstract]. *J Nucl Med* 1988;29:913.
11. Moretti JL, Defer G, Cinotti L, Cesaro P, Vigneron N, Pethe C. Comparative tomoscintigraphic study of strokes using ECD Tc-99m, HMPAO Tc-99m and IMP I-123, preliminary results [Abstract]. *Eur J Nucl Med* 1988;14(5/6):311.
12. Devous MD, Leroy RF, Payne JK, Lorimer MK, Bonte FJ. Comparison of Tc-99m-ECD to Xe-133 in the SPECT determination of regional cerebral blood flow in patients with mild perfusion abnormalities [Abstract]. *J Nucl Med* 1990;31:817.
13. Holman BL, Hellman RS, Goldsmith SJ, et al. Biodistribution, dosimetry, and clinical evaluation of Tc-99m ethyl cysteinate dimer (ECD) in normal subjects and in patients with chronic cerebral infarction. *J Nucl Med* 1989;30:599-604.
14. Costa DC, Ell PJ, Cullum ID, et al. The in vivo distribution of ^{99m}Tc -HMPAO in normal man. *Nucl Med Commun* 1986;7:647-658.
15. Bruno A, Dosio F, Benti R, et al. Tc-99m ECD: evaluation of a new brain perfusion tracer in humans. *Eur J Nucl Med* 1990;16:S187.
16. Nadler SB, Hidalgo JV, Bloch T. Predication of blood volume in normal human adults. *Surgery* 1962;51:224-232.
17. Castagnoli A, Borsato N, Bruno A, et al. SPECT brain imaging in chronic stroke and dementia: a comparison of Tc-99m-ECD to Tc-99m-HMPAO. In: Hartmann A, Hoyer S, Kuschinski W, eds. *Cerebral ischemia and dementia*. Stuttgart: Springer-Verlag; 1991:327-333.
18. Nakano S, Kazuo K, Jinnouchi S, Hoshi H, Watanabe K. Comparative study of regional cerebral blood flow images by SPECT using xenon-133, iodine-123-IMP, and technetium-99m-HM-PAO. *J Nucl Med* 1989;30:157-164.
19. Neirinckx RD, Burke JF, Harrison RC, Forster AM, Anderson AR, Lassen NA. The retention mechanism of technetium-99m-HM-PAO: intercellular reaction with glutathione. *J Cereb Blood Flow Metab* 1988;8:S4-S12.
20. Walovitch RC, Franceschi M, Picard M. Tc-99m-ECD metabolism of ^{99m}Tc -L,L-ethyl cysteinate dimer in healthy volunteers. *Neuropharmacology* 1991;30:283-292.
21. Moretti JL, Defer G, Cinotti L, et al. "Luxury perfusion" with ^{99m}Tc -HMPAO and ^{123}I -IMP SPECT imaging during the subacute phase of stroke. *Eur J Nucl Med* 1990;16:17-22

ERRATUM

In the February issue of the *Journal*, Figure 1 in "The Scintigraphic Appearance of Alzheimer's Disease: A Prospective Study Using Technetium-99m-HMPAO SPECT" by Holman et al. was incomplete. The correct figure is printed below.

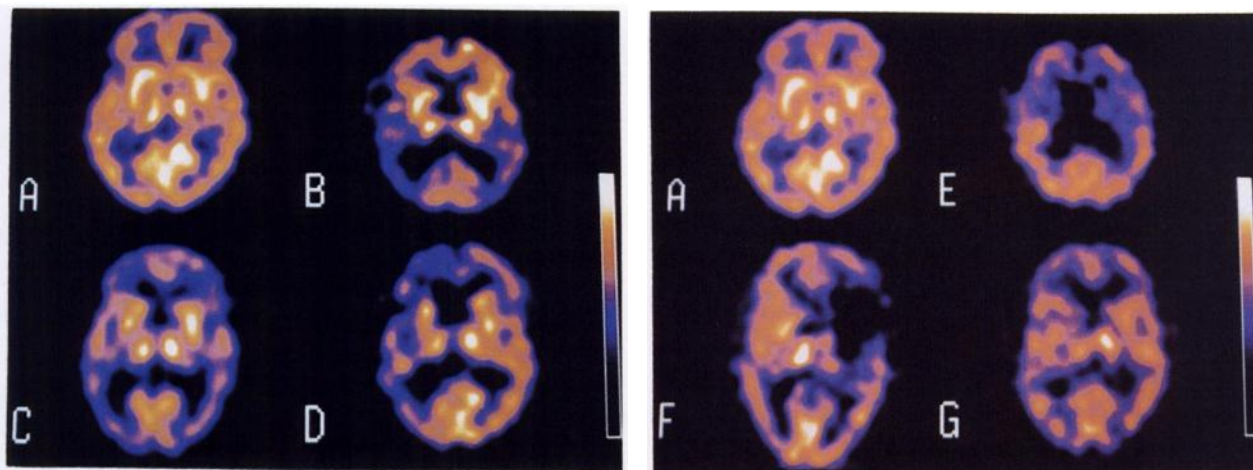


FIGURE 1. Examples of ^{99m}Tc -HMPAO SPECT perfusion patterns. Pattern A: Normal perfusion. Pattern B: Bilateral posterior temporal and parietal defects. Pattern C: Bilateral posterior temporal and parietal defects with additional frontal defects. Pattern D: Left temporal, parietal and frontal cortex defects. Pattern E: Extensive bilateral frontal defects. Pattern F: Large defect involving the right lateral frontal and anterior temporal lobes. Pattern G: Multiple small cortical defects.

- (A) Normal.
- (B) Bilateral posterior temporal and/or parietal cortex defects.
- (C) Bilateral posterior temporal and/or parietal cortex defects with additional defects.
- (D) Unilateral posterior temporal and/or parietal cortex defects with or without additional defects.
- (E) Frontal cortex defects only.
- (F) Other large (>1 cm) defects.
- (G) Multiple small (≤ 1 cm) cortical defects.