
Scintigraphic Detection of Bone and Joint Infections with Indium-111-Labeled Nonspecific Polyclonal Human Immunoglobulin G

Wim J.G. Oyen, Roland A.M.J. Claessens, Jim R. van Horn, Jos W.M. van der Meer, and Frans H.M. Corstens

University Hospital Nijmegen, Departments of Nuclear Medicine, Orthopaedics and Internal Medicine, University of Nijmegen, The Netherlands

The utility of indium-111- (^{111}In) labeled immunoglobulin G (IgG) to detect infection of bone and adjacent tissues was investigated. Proof of infection was obtained by cultures taken at surgery. All 32 patients showed focally increased uptake on the technetium-99m- ($^{99\text{m}}\text{Tc}$) methylene diphosphonate (MDP) skeletal scintigraphies. Labeled immunoglobulin correctly identified presence, location, extent and soft-tissue involvement of the suspected inflammatory site. In these patients, focally increasing accumulation was noted over 48 hr. Discrimination between infection and sterile inflammatory lesions was not possible. Two fractures, 6-mo-old, and an aseptic loosening of a total-hip prosthesis were not visualized. Side effects after the immunoglobulin administration were not observed. Radio-labeled immunoglobulin is a new and safe radiopharmaceutical for the investigation of infectious bone and joint disease. The sensitivity of this agent appears at least as high as that of labeled leukocytes. However, labeled immunoglobulin can easily be prepared in every nuclear medicine department.

J Nucl Med 1990; 31:403-412

Infections of bone and adjacent tissues often present a diagnostic and therapeutic problem, making the management of the disease difficult. The available scintigraphic imaging techniques show limitations in diagnosing these infections. This applies especially to patients who have undergone multiple revision operations for chronic osteomyelitis. Technetium-99m-methylene diphosphonate ($^{99\text{m}}\text{Tc}$ -MDP) bone imaging is nonspecific and not suitable to demonstrate the extent of the lesion accurately (1-3). Gallium-67 (^{67}Ga) may accu-

multate in areas of increased bone turnover and shows modest accumulation compared to indium-111- (^{111}In) labeled nonspecific polyclonal human immunoglobulin G (IgG) (2,4,5). Some authors reported a low sensitivity of ^{111}In -labeled white blood cells (WBC) scintigraphy to detect low-grade infection (2,6). The utility of $^{99\text{m}}\text{Tc}$ -WBC to detect chronic osteomyelitis has not been established. Above this, time-consuming techniques are required for every WBC labeling method (7,8). Labeling of leukocytes in full blood with $^{99\text{m}}\text{Tc}$ -colloid has not been sufficiently validated yet (9-11).

Recently, several reports have appeared suggesting the potential utility of ^{111}In -IgG as an imaging agent for detecting focal inflammation. These studies, both in animals and humans have been primarily concerned with soft-tissue, intraabdominal, and vascular infection (4,12-14). Because of the need for better techniques for imaging bone and joint infection, we initiated a study to evaluate the safety and accuracy of IgG scintigraphy in patients with infections of bone and adjacent tissue.

MATERIALS AND METHODS

Radiopharmaceuticals and Imaging Procedures

In all patients routine three-phase skeletal scintigraphy was performed after i.v. injection of 600 MBq $^{99\text{m}}\text{Tc}$ -MDP.

Diethylenetriaminepentaacetic bicyclic anhydride (bicyclic DTPA) was conjugated to human, nonspecific, polyclonal IgG (Sandoglobulin, Sandoz AG, Nuernberg, FRG) according to Hnatowich and colleagues (15). The purified DTPA-conjugated IgG was diluted to 5 mg/ml with 0.15 M acetate (pH = 6.5) and sterilized by membrane filtration. Aliquots of 0.5 ml of the conjugate were radiolabeled with ^{111}In (Indium chloride, Amersham International Ltd., Buckinghamshire, UK) via citrate transchelation. The radiochemical purity was determined by ITLC-SG chromatography (Gelman Laboratories, Ann Arbor, MI) with 0.1 M citrate (pH = 5) as the solvent. The labeling efficiency was always higher than 97%. A dose of ~1 mg of IgG labeled with 75 MBq ^{111}In was injected intravenously either between 2 and 7 days after the

Received Aug. 24, 1989; revision accepted Nov. 10, 1989.
For reprints contact: Frans Corstens, MD, Dept. of Nuclear Medicine, University Hospital Nijmegen, Box 9101, 6500 HB Nijmegen, The Netherlands.

^{99m}Tc-MDP skeletal scintigraphy had been completed, or after the second-phase images of ^{99m}Tc-MDP scintigraphy were obtained. The latter procedure was followed when operation was scheduled within 72 hr after the patient had been referred to the nuclear medicine department. Scintigraphic images were obtained with a Siemens Orbiter gamma camera connected to a Scintiview image processor (Siemens Inc., Des Plaines, IL). All images were collected in digital format in a 256 × 256 matrix. Bone images were always obtained with a low-energy parallel-hole collimator (140 keV photopeak, 15% symmetric window). However, when ¹¹¹In-IgG was injected after the second phase of the skeletal scintigraphy, the delayed bone images were obtained with a medium-energy parallel-hole collimator (140 keV photopeak, 15% symmetric window). Indium-111-IgG images were acquired at 4, 18–24, and 42–48 hr postinjection for a preset time of 5, 7.5, and 10 min, respectively. Approximately 1,000–1,500K cts for the trunk region, 600–750K cts for the pelvic region and 80–120K cts for the lower limb were collected. A medium-energy parallel-hole collimator (173 keV peak, 15% symmetric window; 247 keV peak, 15% symmetric window) was used. When injected after the second phase of the bone scan, the 173-keV ¹¹¹In peak was not used for imaging ¹¹¹In-IgG 4 and 18–24 hr postinjection.

All images were interpreted by three observers. The observers were not blinded for clinical information or radiographic images, when available. A definite judgement of the scintigraphic images was reached before any of the verification procedures were performed. The ¹¹¹In-IgG images were interpreted with the corresponding bone scintigraphy. An ¹¹¹In-IgG scan was interpreted as positive, if focal *increasing* accumulation could be noted over time. Nonvisualization of the lesion detected by bone scan and/or plain radiograph, or failure to show increasing accumulation was considered to be a negative ¹¹¹In-IgG scintigraphy.

Patients

Patients suspected of acute (evidence of infection since one or several days) or chronic (evidence of infection for weeks, months or even years) osteomyelitis or infectious arthritis in whom a ^{99m}Tc-MDP bone scan was indicated and in whom proof of the infection was likely to be obtained, were eligible for the study. In 22 out of 25 patients suspected of infection, cultures from the focus were obtained within two days after completion of the imaging procedures, either during operation or by needle aspiration. Furthermore, a small number of patients with noninfectious bone disease were studied to get an impression of the specificity of ¹¹¹In-IgG scintigraphy. One patient with clinically-cured sternal osteomyelitis was studied. If the attending physician agreed to perform ¹¹¹In-IgG scintigraphy, patients were informed about the experimental nature of the imaging procedure. Pregnant and lactating females were excluded from the study. No patient had a history suggestive of IgA- or IgG-deficiency or adverse reaction to previous IgG administration. Informed consent was obtained. The study was approved by the local ethical committee.

Other Procedures

Blood samples were taken from all patients immediately before and, if possible, 2–3 wk after the ¹¹¹In-IgG injection for extensive hematologic (full-blood cell count and WBC differ-

entiation) and biochemical (minerals, liver and kidney function, glucose, cholesterol, protein spectrum) assessment. Also qualitative urinalysis was performed. Vital signs were monitored up to 45 min after injection.

In five patients, suspected of infectious bone disease, the relative uptake of ¹¹¹In-IgG in the focus compared to the uptake in the contralateral limb was estimated after drawing variable size regions of interest (ROI) on the 42–48-hr images. Similar regions were then drawn over the corresponding areas on the 4- and 18–24-hr images. Before calculating the ratios on the consecutive images, the regions were normalized for slight differences in size of the two regions.

The same procedure was followed for calculating the ratios in five patients suffering from noninfectious bone disease. In case of nonvisualization of a lesion by ¹¹¹In-IgG, the placement of the region was guided by the area of increased uptake on the skeletal scintigraphy.

In three patients, a series of blood samples were taken after ¹¹¹In-IgG injection in order to estimate the blood clearance of ¹¹¹In-IgG.

RESULTS

Thirty-two patients (16 males, 16 females; mean age 52.7 yr, range 23–87 yr) were investigated. Twenty-five patients were suspected of bone and joint infections in 29 lesions. Seven patients were suffering from noninfectious bone and adjacent tissue disease.

The clinical characteristics of the investigated patients, the results of the ¹¹¹In-IgG scintigraphy, the verification procedure, and the results of the microorganism cultures are summarized in Tables 1–4. The patients are categorized on the basis of the clinical data available to the observers at the time of imaging. Sinus tract cultures are not included in Table 1 because they may not reflect the causative microorganism involved (16).

Clinical or biochemical side effects of the ¹¹¹In-IgG administration were not encountered.

In all 32 patients, the ^{99m}Tc-MDP skeletal scintigraphy was positive, indicating the site of the skeletal lesions. On the basis of the clinical features, the three-phase bone scan and the plain radiographs, it was possible to make the diagnosis of acute osteomyelitis or infectious arthritis with sufficient confidence. However, in cases of chronic osteomyelitis, bone scan and radiographs could not identify the presence, the degree, and the extent of infection.

Indium-111-IgG identified the 29 sites of inflammation in all 25 patients, suspected of having an infection. Moreover, with ¹¹¹In-IgG scintigraphy, we were able to discriminate between osseous and joint infection. The involvement of the adjacent soft tissues could be delineated accurately with help of the ^{99m}Tc-MDP images. Figures 1, 2, 3, and 4 show the images obtained by ^{99m}Tc-MDP and ¹¹¹In-IgG in four patients. In Figures 1 and 2, plain radiographs also are presented. In case of inflammation, in the first 48 hr a relative increase of

TABLE 1
Clinical Characteristics: Results of the ¹¹¹In-IgG Scintigraphy, Verification Procedures, and Culture Results of the Patients Suspected of Chronic Osteomyelitis

Patient (sex, age)	History	IgG-imaging	Verification procedure	Culture*
1 (F, 38)	Low-grade infection after osteosynthesis for femoral fracture	+	Operation	SA, B, P, PA, HS
2 (M, 30)	Low-grade infection after complicated tibial fracture	+	Operation	P, PA, E
3 (M, 81)	Total-hip arthroplasty, painful loosening	+	Operation	SA, SE, PA
4 (F, 23)	Complicated crural fracture at the age of 6; infection since elongation procedure lower limb 1 yr prior to scintigraphy	+	Operation	SA, D, HS
5 (M, 29)	Osteotomy femur, painful hip	+	Operation	SA
6 (F, 27)	Low-grade infection after osteosynthesis for tibial plateau fracture	+	Operation	SA, SE
7 (M, 61)	Recurrent low-grade osteomyelitis distal femur	+	Operation	SA
8 (M, 79)	Painful loosening total-knee prosthesis	+	Operation	P
9 (M, 63)	Painful loosening total-hip prosthesis, fistula	+	Operation	SA
10 (F, 63)	Painful loosening total knee prosthesis	+	Operation	D
11 (M, 58)	Chronic osteomyelitis after osteosynthesis for traumatic pelvic fracture	+	Operation	SA
12 (M, 40)	Chronic osteomyelitis upper arm with fistula after chemotherapy for testiscarcinoma	+	Operation	SA
13 (F, 28)	Postoperative chronic osteomyelitis ankle	+	Operation	SA, A
14 (F, 85)	Postoperative chronic osteomyelitis knee	+	Operation	SA
15 (F, 75)	Chronic osteomyelitis humerus	+	Operation	SA
16 (M, 39)	Post-traumatic low-grade tibial infection	+	Fistula	n.d.
17 (F, 38)	Postoperative recurrent, low-grade infection hip	+	Fistula	n.d.
18 (M, 32)	Chronic osteomyelitis after complicated femoral fracture	+	Fistula	n.d.

The patients are categorized on the basis of the clinical data available to the observers at the time of imaging. The patients were not using antibiotics unless stated.

* A = alcalignes species; B = bacteroides species; D = diptheroid rods; E = enterococcus; HS = hemolytic streptococcus; n.d. = not done; M = mycobacterium tuberculosis; P = peptostreptococcus; PA = pseudomonas aeruginosa; SA = staphylococcus aureus; and SE = staphylococcus epidermidis.

TABLE 2
Clinical Characteristics: Results of the ¹¹¹In-IgG Scintigraphy, Verification Procedures, and Culture Results of the Patients Suspected of Acute Osteomyelitis/Spondylodiscitis

Patient (sex, age)	History	IgG imaging	Verification procedure	Culture*
19 (M, 58)	Recurrent staphylococcal bacteraemia, spondylodiscitis thoracic spine. For 1 wk Flucloxacillin 3 g and Gentamycin 160 mg daily	+	Autopsy [†]	SA
20 (M, 43)	Possible osteomyelitis after biopsy ilium for a chondrosarcoma	+	Operation	Negative
21 (F, 66)	Acute spondylodiscitis thoracic spine, painful hip	+	Open biopsy	HS
22 (F, 79)	Acute spondylodiscitis lumbar spine, painful knee and shoulder. For 1 mo: Isoniazide 250 mg, Rifampicin 400 mg and Pyrazinamide 1500 mg daily	+	Needle aspiration	M

Patients are categorized on the basis of the clinical data available to the observers at the time of imaging. Patients were not using antibiotics unless stated.

* See Table 1 for definitions.

[†] Patient died of cardiorespiratory failure due to a pre-existing heart condition.

TABLE 3
Clinical Characteristics: Results of ¹¹¹In-IgG Scintigraphy, Verification Procedures, and Culture Results in Patients Suspected of Infectious Arthritis

Patient (sex/age)	History	IgG imaging	Verification procedure	Culture*
21 (F, 66)†	Acute spondylodiscitis thoracic spine, painful hip	+	Open biopsy	HS
22 (F, 79)†	Acute spondylodiscitis lumbar spine, painful knee and shoulder. For 1 mo: Isoniazide 250 mg, Rifampicin 400 mg and Pyrazinamide 1500 mg daily	+	Needle aspiration	M
23 (M, 60)	Staphylococcal bacteraemia, painful shoulder and upper part of leg. For 2 wk Flu-cloxacillin 12 g i.v. daily	+	Operation	SA
24 (F, 27)	Progressively painful shoulder	+	Operation	SA
25 (F, 87)	Painful knee, possible arthritis	+	Needle aspiration	Negative

Patients are categorized on the basis of clinical data available to the observers at the time of imaging. Patients were not using antibiotics unless stated.

* See Table 1 for definitions.

† Patients 21 and 22 were also listed under suspected of acute osteomyelitis/spondylodiscitis.

¹¹¹In-IgG activity was noted at the affected site compared to the same region in the contralateral limb. Figure 5 shows the increasing ratio of activity over time in five individual patients with infection.

In 22 out of 25 patients suspected of infection, cultures from the focus were obtained two days after completion of the imaging procedures. In 20 out of these 22 patients (Nos. 1–15, 19, 21–24), a positive culture was obtained, proving the infectious etiology of their disease (15 patients with chronic osteomyelitis, 2 with acute spondylodiscitis and arthritis, 1 with acute spondylodiscitis, and 2 with acute arthritis).

In two patients (Nos. 20 and 25) with positive ¹¹¹In-IgG scans, the cultures were negative. Patient 20 showed

clinical evidence of infection after a biopsy, taken from the right ilium because of a chondrosarcoma. The ¹¹¹In-IgG scintigraphy showed increased activity near the site of the biopsy. At surgery, a large hematoma was found near the biopsy site. Cultures taken at surgery remained sterile. The location of the hematoma matched with the site of the ¹¹¹In-IgG accumulation. In Patient 25 with ¹¹¹In-IgG accumulation in the left knee, joint fluid cultures remained sterile. The Gram-stain, however, showed marked leucocytosis. The patient was diagnosed as having a sterile synovitis of the left knee and recovered without further therapy.

At surgery, it appeared that ¹¹¹In-IgG correctly identified the presence and localization of the site of inflam-

TABLE 4
Clinical Characteristics: Results of ¹¹¹In-IgG Scintigraphy, Verification Procedures, and Culture Results in Patients Suspected of Noninfectious Bone Disease

Patient (sex, age)	History	IgG-imaging	Verification procedure	Culture*
26 (M, 62)	Silent rheumatoid arthritis, sudden onset pain tibia three weeks ago, stressfracture	+	Open biopsy	
27 (M, 23)	Recent (10 days) traumatic non-complicated tibial fracture	+	No surgery	
28 (F, 57)	Approximately 6-mo-old fracture pubic bone	–	No surgery	
29 (F, 84)	Approximately 6-mo-old fracture around femoral component total hip arthroplasty	–	No surgery	
30 (M, 36)	Soft-tissue tumour upper leg (haemangioma)	–	Operation	
31 (F, 51)	Post-mediastinoscopy sternal osteomyelitis, clinically cured for 3 mo	–	No surgery	
32 (F, 64)	Total-hip prosthesis both hips, pain right hip region since 6 mo, loosening, no evidence of infection	–	Operation	Negative

Patients are categorized on the basis of clinical data available to the observers at the time of imaging. Patients were not using antibiotics unless stated.

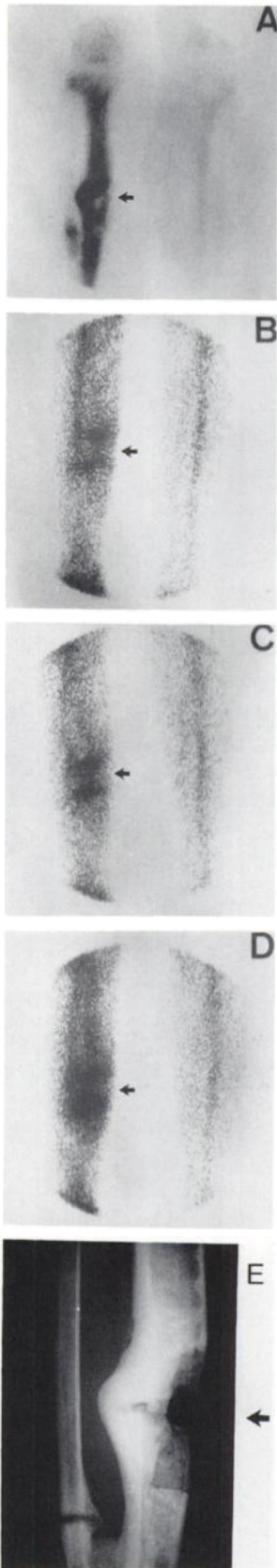


FIGURE 1
 Patient 4 (23-yr-old female). Complicated left crural fracture at age of 6, elongation procedure lower leg at age of 19 (fibular transplant), non-complicated refracture at age of 21, osteomyelitis since osteosynthesis. Surgery confirmed chronic osteomyelitis. Cultures showed growth of *Staphylococcus aureus* and epidermidis and beta-hemolytic *Streptococcus*. Technetium-99m-MDP 3 hr postinjection (A) and ^{111}In -IgG 4 (B), 24 (C), 48 (D) hr postinjection, and plain radiograph (E). The arrows indicate corresponding areas.

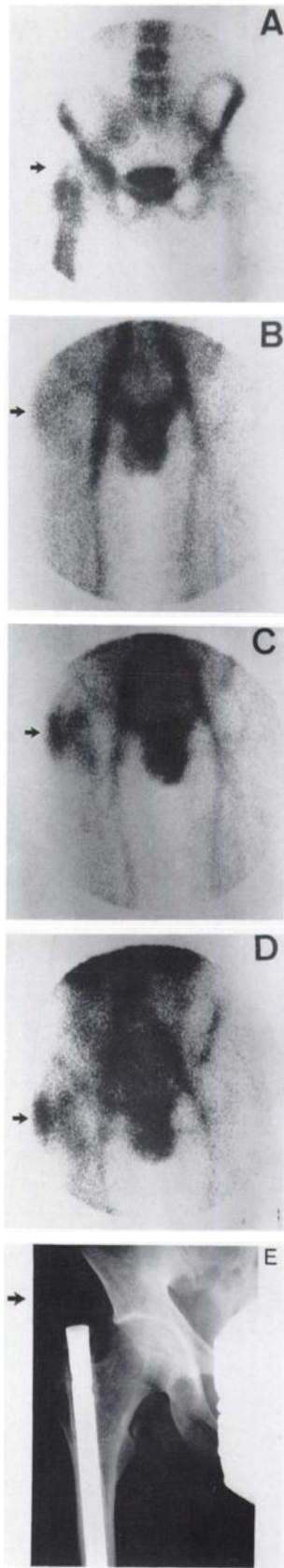


FIGURE 2
 Patient 5 (29-yr-old male). Femoral fracture at age of 15, elongation osteotomy at age of 23, infection at age of 25, and recently progressively painful hip. At operation a soft-tissue infection and a chronic osteomyelitis of the right femur were found. Cultures showed growth of *Staphylococcus aureus*. Technetium-99m-MDP 3 hr postinjection (A) and ^{111}In -IgG 4 (B), 24 (C), 48 (D) hr postinjection, and plain radiograph (E). The arrows indicate corresponding areas.

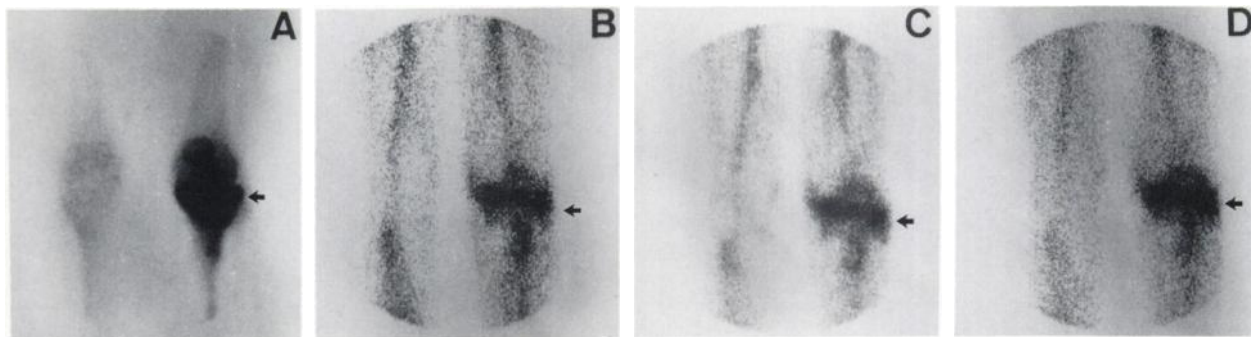


FIGURE 3

Patient 6 (27-yr-old female). Low-grade osteomyelitis after osteosynthesis for left tibial plateau fracture at age of 25. At surgery the diagnosis chronic osteomyelitis was confirmed. Cultures showed growth of *Staphylococcus aureus* and epidermidis. Technetium-99m-MDP 3 hr postinjection (A) and ^{111}In -IgG 4 (B), 24 (C) and 48 (D) hr postinjection. The arrows indicate corresponding areas.

mation. The impression at operation was, that bone, articular and soft-tissue involvement was predicted correctly by the ^{111}In -IgG scintigraphy.

In three out of 25 patients, clinically suspected of having chronic infectious bone disease (Nos. 16, 17, and 18) no cultures were obtained. These patients had a recent history of recurrent fistulae, thus proving the infectious etiology of the bone disease. In all three patients, ^{111}In -IgG correctly localized the lesion and demonstrated the soft-tissue involvement in the region of the fistula.

In addition to the 25 cases stated above, we also studied seven patients not suffering from bone and joint infection. Figure 6 shows the ratio between the ^{111}In -IgG uptake in the lesion and the corresponding area in the contralateral limb in five of these patients without evidence of infection. Patients 26 and 27 with recent tibial fractures (10 days and 3-wk-old, respectively) showed both positive skeletal and ^{111}In -IgG scintigraphies. Patients 28 and 29 with both ~6-mo-old fractures had a positive $^{99\text{m}}\text{Tc}$ -MDP bone scan. In these two patients, the ^{111}In -IgG did not show the lesion, resulting in a ratio of ~1. Patient 30 showed evidence of a well-perfused soft-tissue tumour without osseous involve-

ment just above the knee. Initially, the tumour was well visualized by ^{111}In -IgG, but over time no increasing ^{111}In -IgG accumulation in the tumour could be noted. Histologic examination showed a haemangioma.

Patient 31, with clinically-cured sternal osteomyelitis, still showed a hot spot in the sternum at scintigraphy with $^{99\text{m}}\text{Tc}$ -MDP. Indium-111-IgG scintigraphy did not reveal the lesion.

Figure 7 shows the scintigraphic images of Patient 32. This patient showed evidence of loosening of the right total-hip prosthesis. There was no evidence of septic loosening. The bone scintigram shows increased uptake in the right acetabular region. The ^{111}In -IgG around the prosthesis was normal. Cultures taken at surgery showed no bacterial growth.

A relatively high intravascular activity of ^{111}In -IgG can be noted up to 48 hr. Figure 8 demonstrates the blood clearance in three patients. The slow clearance of ^{111}In -IgG resulted in a relatively high background activity at scintigraphy.

DISCUSSION

Our results indicate that ^{111}In -IgG is able to identify the location and the extent of infectious bone and joint

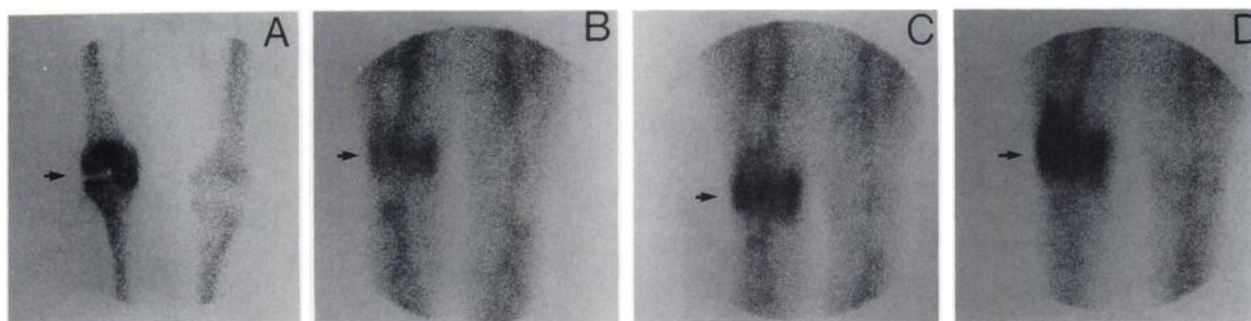


FIGURE 4

Patient 22 (79-yr-old female). Progressive pain in lumbar spine, right shoulder, and right knee for 2 mo. Cultures taken by needle aspiration showed growth of *Mycobacterium tuberculosis*. Knee region: $^{99\text{m}}\text{Tc}$ -MDP 3 hr postinjection (A) and ^{111}In -IgG 4 (B), 24 (C) and 48 (D) hr postinjection. The arrows indicate corresponding areas.

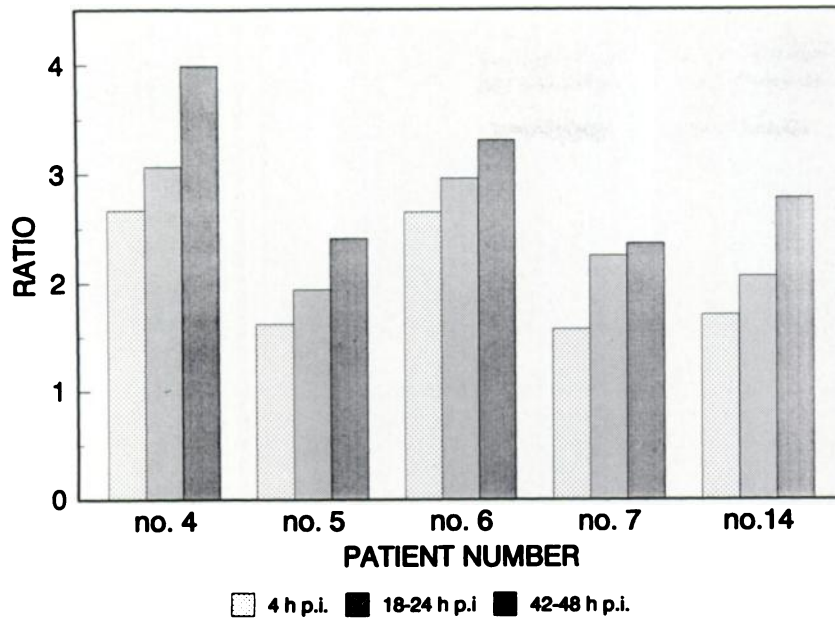


FIGURE 5
The ratio between the ^{111}In -IgG uptake in the infection focus and in the corresponding area in the contralateral limb in five patients.

disease. This is especially valuable in low-grade, chronic osteomyelitis.

Although $^{99\text{m}}\text{Tc}$ -MDP skeletal scintigraphy is indispensable for rapid localization of the site of the lesion and visualization of the osseous structures, little information can be obtained about soft-tissue involvement and the actual extent and nature of the lesion, since it lacks specificity to discriminate between reactive increased bone turn-over (i.e., bone remodelling) and actual inflammation (1,3,17,18).

In the literature, no definitive view has been reached on the value of ^{67}Ga scintigraphy and ^{111}In -WBC imaging in patients with bone infections. Some authors reported about the usefulness of ^{67}Ga scintigraphy in

chronic infectious bone disease (1,19). Others found a higher sensitivity of ^{111}In -WBC scintigraphy compared to ^{67}Ga imaging (2,17,20). It has been noted that ^{67}Ga may accumulate in areas of increased bone turn-over, decreasing the specificity for infection (2,21,22). In rats with artificial muscle infection, the degree of ^{67}Ga accumulation appeared to be modest compared to that of ^{111}In -IgG (4,5). In our limited experience ^{111}In -IgG did not accumulate locally in the remodelling phase of 6-mo-old fractures and in an aseptic loosening of a total-hip prosthesis.

While ^{111}In -WBC scintigraphy has proven to have a high diagnostic accuracy in acute infections, there is no consensus on the sensitivity of ^{111}In -WBC imaging in

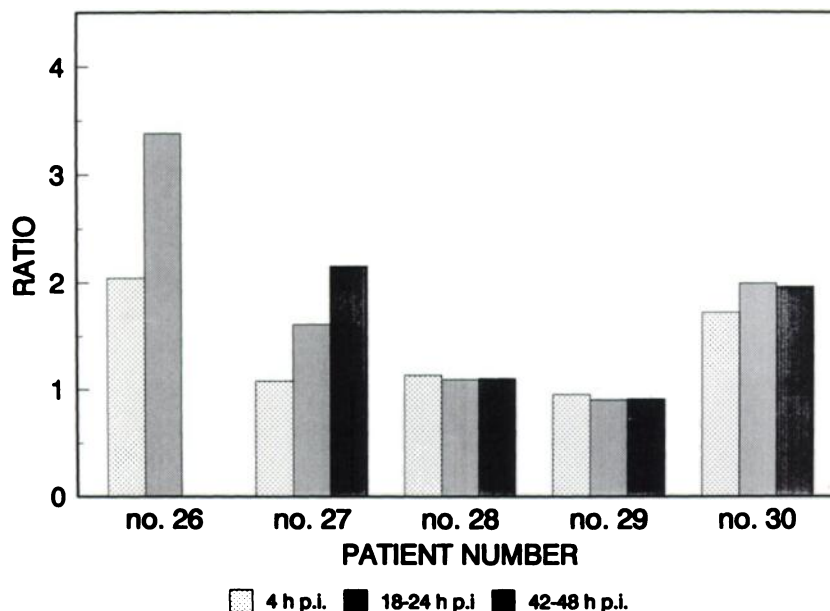


FIGURE 6
The ratio between the ^{111}In -IgG uptake in the lesion and the corresponding area in the contralateral limb in five patients suffering from noninfectious bone disease.

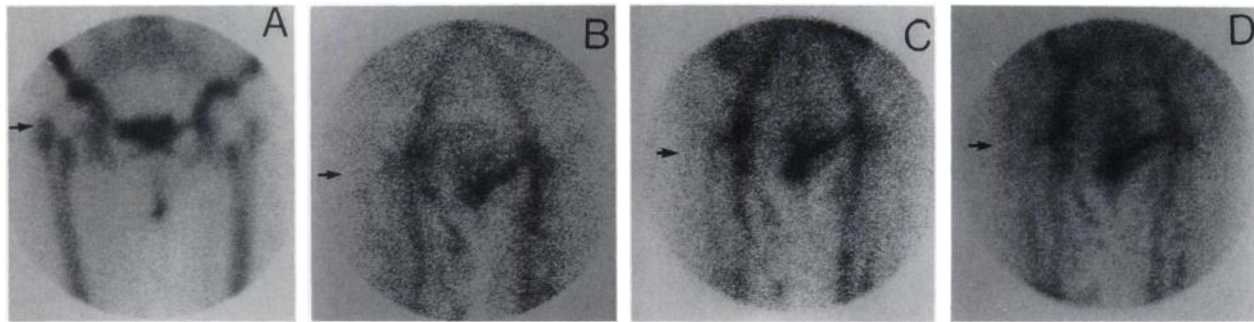


FIGURE 7
Normal ^{111}In -IgG scintigraphy. Patient 32 (female, 64 hr). Total hip prosthesis in both hips. Pain in right hip region for 6 mo. At surgery, loosening of the acetabular component of the right total hip prosthesis was found. Bacterial cultures remained sterile. Technetium-99m-MDP 3 hr postinjection (A) and ^{111}In -IgG 4 (B), 24 (C) and 48 (D) hr postinjection. The arrows indicate corresponding areas.

patients, suffering from chronic osteomyelitis (2,3,6,19, 20,23-25). In our study, ^{111}In -IgG identified all patients suffering from chronic osteomyelitis.

A major advantage of ^{111}In -IgG is the relatively easy and quick preparation of the radiopharmaceutical, when compared to ^{111}In or $^{99\text{m}}\text{Tc}$ -HM-PAO WBC. When using WBC, 40-50 ml of blood has to be drawn carefully in order to obtain sufficient undamaged leukocytes. Time-consuming, complex, and costly isolation and labeling techniques are required (7,8). Whereas the preparation of ^{111}In -WBC in our department requires at least 2.5 hr, labeling of the IgG-DTPA conjugate with ^{111}In takes only 10 min. In addition, a constant quality of ^{111}In -IgG is guaranteed. Whereas many smaller nuclear medicine departments have problems with the proper labeling of leukocytes with ^{111}In , every department should be able to prepare ^{111}In -IgG when the IgG-DTPA conjugate is available on the shelf. In view of the recent discussion between Mock et al. and

Hanna et al., the utility of labeling WBC with $^{99\text{m}}\text{Tc}$ colloid in *full blood* remains to be established (9-11).

Since oxine is a cytotoxic agent and ^{111}In may cause radiation damage to long-living T-lymphocytes, the ^{111}In -oxine dose in labeling WBC is limited (26). As a consequence, relatively long imaging times are necessary to obtain adequate images. In dogs, ^{111}In -WBC and $^{99\text{m}}\text{Tc}$ -HM-PAO WBCs identified recent, artificially inflicted osteomyelitis in the appendicular skeleton equally well. Whether infection in the axial skeleton can be adequately detected remains to be established (27). Furthermore, it needs to be clarified whether a time span of 24 hr is sufficient to detect low-grade osteomyelitis with $^{99\text{m}}\text{Tc}$ -labeled WBC scintigraphy.

One advantage of ^{111}In -WBC over ^{111}In -IgG is the relatively fast blood clearance of ^{111}In -WBC, resulting in a low background activity. This leads to a relatively good target-to-background ratio when ^{111}In -WBC accumulation is present. However, the relatively high

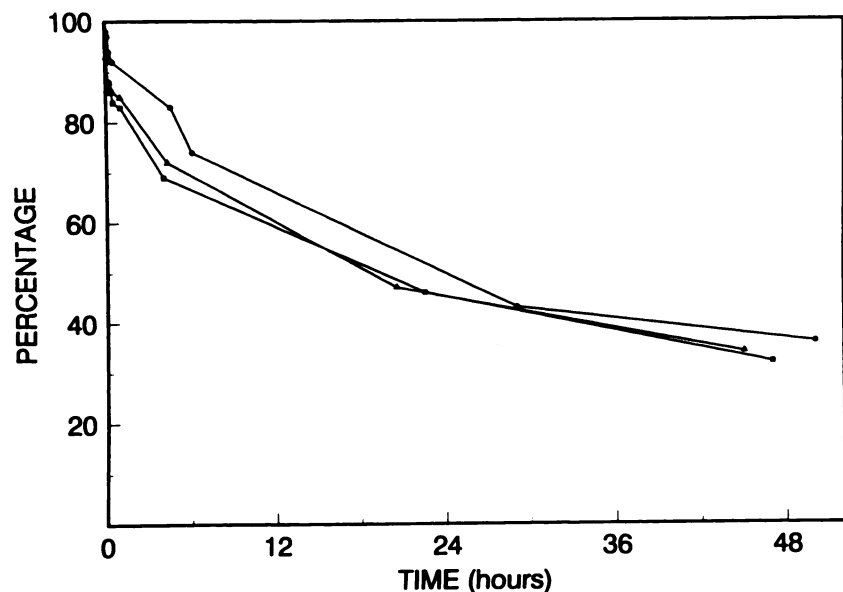


FIGURE 8
The blood clearance of ^{111}In -IgG in three patients. The activity in the blood sample taken after 2 min is denominated as 100%.

background activity of $^{111}\text{In-IgG}$, even after 24 and 48 hr, does not significantly interfere with image interpretation. In the majority of patients, the best quality images were obtained 48 hr postinjection. However, the focus of infection could very well be delineated after 24 hr. The images obtained 48 hr postinjection, were necessary in some cases to establish the diagnosis of low-grade osteomyelitis and helped to discriminate between hypervascular status and accumulation of $^{111}\text{In-IgG}$. This differentiation is not relevant in most patients. Imaging up to 24 hr postinjection is in most cases sufficient. Thus, with regard to the half-life of the radionuclide, IgG imaging with $^{99\text{m}}\text{Tc}$ would be possible.

We are currently comparing the utility of $^{111}\text{In-WBC}$ and $^{111}\text{In-IgG}$. Results in the first 16 patients, who were investigated with both techniques, suggest that $^{111}\text{In-IgG}$ is at least as potent as $^{111}\text{In-WBC}$ in revealing an inflammatory lesion. However, compared to $^{111}\text{In-WBC}$ a higher degree of uptake in a lesion can be noted when using $^{111}\text{In-IgG}$.

Since many patients in the study also received an injection of $^{99\text{m}}\text{Tc-MDP}$ shortly before the $^{111}\text{In-IgG}$ administration, high standard dosimetry was not possible. Preliminary data suggest that the radiation burden to any organ after the administration of 75 MBq $^{111}\text{In-IgG}$ is far less than 50 mGy (5 rad). This is in agreement with other reports (13). Further studies are in progress. Intravenous IgG preparations in gram doses have been a safe therapeutic agent for years. The injection of 1 mg of radiolabeled IgG did not produce any clinical or biochemical side effects. For these reasons, $^{111}\text{In-IgG}$ can be regarded as a safe radiopharmaceutical (13,28).

The mechanism of IgG uptake at the inflammation site has not been fully elucidated yet. On the basis of experiments, using Fab, F(ab)2 and Fc fragments of the complete IgG molecule, it has been suggested that the Fc-portion of IgG is responsible for the concentration at the inflammation site (4,12). Recently, enhanced vascular permeability followed by macromolecular entrapment in the connective tissues was reported as a possible explanation for IgG accumulation (29).

With $^{111}\text{In-IgG}$, no definite discrimination is possible between infectious and sterile inflammation. In our study, this is demonstrated by the positive $^{111}\text{In-IgG}$ scintigraphy in patients with a hematoma, sterile arthritis, and recent fractures. This also applies to $^{111}\text{In-WBC}$ scintigraphy (3,24,30-32). In case of chronic osteomyelitis, this is of minor importance, since a sterile inflammatory process seems unlikely in an area with recurrent infections. Of major importance is differentiation between increased bone turn-over (due to repair process) and persisting infection.

Only 3 out of 32 patients were using antibiotics at the time of imaging. Therefore, no conclusions can be drawn regarding the effect of antibiotics on the outcome

of $^{111}\text{In-IgG}$ scintigraphy. Data in the literature suggest little influence of an antibiotic regimen on the outcome of IgG scintigraphy (4).

Fischman et al. reported the usefulness of serial $^{111}\text{In-IgG}$ scintigraphy in, for example, inflammatory bowel disease to assess the cure of the infection (4,13). Whether this holds true for the assessment of cure of infections of bone and joint will be the object of further studies. In our study, a patient with cured sternal osteomyelitis showed a negative $^{111}\text{In-IgG}$ scintigraphy. Also, the specificity of $^{111}\text{In-IgG}$ imaging in skeletal infections has to be determined.

We conclude that with $^{111}\text{In-IgG}$ a safe, easily prepared radiopharmaceutical has become available. We have obtained promising results with regard to the capability of $^{111}\text{In-IgG}$ scintigraphy to localize infectious bone and joint disease. This property is especially valuable for the investigation of low-grade, chronic osteomyelitis.

ACKNOWLEDGMENTS

This study was supported in part by Ortho Biotech, Washington Crossing, NJ, USA.

The authors want to express their gratitude to Mr. Antoi Meeuwis and his staff and to Mr. Wim van den Broek for technical assistance, to J. Albert Lemmens, MD for supplying the radiographs, and to Robert H. Rubin, MD for critically reviewing the manuscript.

REFERENCES

1. Alazraki N, Fierer J, Resnick D. Chronic osteomyelitis: monitoring by $^{99\text{m}}\text{Tc}$ phosphate and ^{67}Ga citrate imaging. *Am J Roentgenol* 1985; 145:767-771.
2. Schauwecker DS, Park HM, Mock BH, et al. Evaluation of complicating osteomyelitis with Tc-99m MDP, In-111 granulocytes, and Ga-67 citrate. *J Nucl Med* 1984; 25:849-853.
3. Al-Shiekh W, Sfakianakis GN, Mnaymneh W, et al. Subacute and chronic bone infections: diagnosis using In-111, Ga-67 and Tc-99m MDP bone scintigraphy and radiography. *Radiology* 1985; 155:501-506.
4. Fischman AJ, Rubin RH, Khaw BA, et al. Detection of acute inflammation with 111-indium labeled non-specific polyclonal IgG. *Semin Nucl Med* 1988; 18:335-344.
5. Rubin RH, Fischman AJ, Needleman M, et al. Radiolabeled, non-specific, polyclonal human immunoglobulin in the detection of focal inflammation by scintigraphy: comparison with gallium-67 citrate and technetium-99m-labeled albumin. *J Nucl Med* 1989; 30:385-389.
6. Propst-Proctor SL, Dillingham MF, McDougall IR, Goodwin D. The white blood cell scan in orthopedics. *Clin Orthop* 1982; 168:157-165.
7. Thakur ML, Lavender JP, Arnot RN, Silvester DJ, Segal AW. Indium-111 labeled autologous leukocytes in man. *J Nucl Med* 1977; 18:1014-1021.
8. Kelbæk H, Linde K, Nielsen SL. Evaluation of a new leucocyte labeling procedure with Tc-99m-HMPAO. *Eur J Nucl Med* 1988; 14:621-623.
9. Hanna RW, Lomas FE. Identification of factors affecting technetium-99m leucocyte labelling by phagocytic engulfment and development of an optimal technique. *Eur J Nucl Med* 1986; 12:159-162.

10. Mock BH, English D. Leukocyte labeling with technetium-99m tin colloids. *J Nucl Med* 1987; 28:1471-1477.
11. Hanna R, Lomas F, Sullivan P. Leukocyte labeling with technetium-99m tin colloids [Letter]. *J Nucl Med* 1988; 29:729-730. Published erratum *J Nucl Med* 1988; 29:1305-1306.
12. Rubin RH, Young LS, Hansen P, et al. Specific and non-specific imaging of localized Fisher immunotype 1 *Pseudomonas Aeruginosa* infection with radiolabeled monoclonal antibody. *J Nucl Med* 1988; 29:651-656.
13. Rubin RH, Fischman AJ, Callahan RJ, et al. In-111 labeled nonspecific immunoglobulin scanning in the detection of focal infection. *N Engl J Med* 1989; 321:935-940.
14. LaMuraglia GM, Fischman AJ, Strauss HW, et al. Utility of indium-111 labeled human immunoglobulin G scan for the detection of focal vascular graft infection. *J Vasc Surg* 1989; 10:20-28.
15. Hnatowich DJ, Childs RL, Lantaigne D, Najafi A. The preparation of DTPA-coupled antibodies radiolabeled with metallic radionuclides: an improved method. *J Immunol Meth* 1983; 65:147-157.
16. Mackowiak PA, Jones SR, Smith JW. Diagnostic value of sinus tract cultures in chronic osteomyelitis. *JAMA* 1978; 239:2772-2775.
17. Seabold JE, Nepola JV, Conrad GR, et al. Detection of osteomyelitis at fracture nonunion sites: comparison of two scintigraphic methods. *Am J Roentgenol* 1989; 152:1021-1027.
18. Park HM, Wheat LJ, Siddiqui AR, et al. Scintigraphic evaluation of diabetic osteomyelitis: concise communication. *J Nucl Med* 1982; 23:569-573.
19. Sfakianakis GN, Al-Sheikh W, Heal A, Rodman G, Zeppa R, Serafani A. Comparison of scintigraphy with In-111 leukocytes and Ga-67 in diagnosis of occult sepsis. *J Nucl Med* 1982; 23:618-626.
20. Merkel KD, Brown ML, Dewanjee MK, Fitzgerald RH Jr. Comparison of indium-labeled-leucocyte imaging with sequential technetium-gallium scanning in the diagnosis of low-grade musculoskeletal sepsis. A prospective study. *J Bone and Joint Surg* 1985; 67-A:465-476.
21. Rosenthal L, Lisbona R, Hernandez M, Hadjipavlou A. 99m-Tc-PP and 67-Ga imaging following insertion of orthopedic devices. *Radiology* 1979; 133:717-721.
22. Wheat J. Diagnostic strategies in osteomyelitis. *Am J Med* 1985; 78:218-224.
23. McAfee JG, Samin A. In-111 labeled leukocytes: a review of problems in image interpretation. *Radiology* 1985; 155:221-229.
24. Wukich DK, Abreu SH, Callaghan JJ, et al. Diagnosis of infection by preoperative scintigraphy with indium-labeled white blood cells. *J Bone and Joint Surg* 1987; 69-A:1353-1360.
25. McCarthy K, Velchik MG, Alavi A, Mandell GA, Esterhai JL, Goll S. Indium-111-labeled white blood cells in the detection of osteomyelitis complicated by a pre-existing condition. *J Nucl Med* 1988; 29:1015-1021.
26. Thakur ML, McAfee JG. The significance of chromosomal aberrations in indium-111 labeled lymphocytes. *J Nucl Med* 1984; 25:922-927.
27. Mock BH, Schauwecker DS, English D, Young KA, Wellman HN. In vivo kinetics of canine leukocytes labeled with technetium-99m HM-PAO and indium-111 tropolonate. *J Nucl Med* 1988; 29:1246-1251.
28. Barundum S, Morell A. Adverse reactions to immunoglobulin preparations. In: Nydegger UE, ed. *Immunochemotherapy: a guide to immunoglobulin prophylaxis and therapy*. New York: Academic Press; 1981:223.
29. Morel EM, Tompkins RG, Fischman AJ, et al. Autoradiographic method for quantitation of radiolabeled proteins in tissues using indium-111. *J Nucl Med* 1989; 30:1538-1545.
30. Kim EE, Pjura GA, Lowry PA, Gobuty AH, Traina JF. Osteomyelitis complicating fracture: pitfalls of 111-Indium leukocyte scintigraphy. *Am J Roentgenol* 1987; 148:927-930.
31. Wing VW, van Sonnenberg E, Kipper S, Bieberstein MP. Indium-111 labeled leucocyte localization in hematomas: a pitfall in abscess detection. *Radiology* 1984; 152:173-176.
32. Abreu SH, van Nostrand D, Lower R, Callahan JR, Atkins FB. Indium-111 labeled white blood cell (In-WBC) uptake in non-infected closed fractures in humans: a prospective study [Abstract]. *J Nucl Med* 1987; 28:586.