

# Complex Partial Epilepsy: The Role of Neuroimaging in Localizing a Seizure Focus for Surgical Intervention

Case Presentation: Daniel Gzesh and Steven Goldstein

Discussion: Michael R. Sperling

Guest Editor: Abass Alavi

*Presented at the Philadelphia Nuclear Medicine Conference, March 14, 1990, Philadelphia, Pennsylvania*

---

**J Nucl Med 1990; 31: 1839-1843**

---

## CASE PRESENTATION

A 29-yr-old woman with medically intractable complex partial seizures was referred for consideration of epilepsy surgery. She was the product of full-term normal pregnancy and delivery, and her early development was unremarkable. At the age 18 mo, she had a febrile convulsion. Shortly thereafter she developed recurrent afebrile seizures, which have persisted to the present. Her seizures began with an aura described as an unpleasant rising sensation in the epigastrium, followed by unresponsiveness and flexion of the left arm. Postictally, she was confused for ~15 min. At times, she experienced the aura without subsequent impairment of consciousness. Some seizures were secondarily generalized with bilateral tonic-clonic movements. The seizures gradually increased in frequency over the past ten years. At the time of admission, she experienced four to five complex partial seizures per month and one secondarily generalized seizure per month.

She had been treated with maximum doses of phenytoin, carbamazepine, mysoline, valproate, and phenobarbital, alone and in combination, but these were ineffective. Her past medical history was otherwise unremarkable, and there were no other known risk factors for epilepsy. The family history was also negative.

The general physical examination was normal with no evidence of hemiatrophy. Mental status testing revealed fluent speech, but a poor fund of knowledge and mild-moderate memory impairment. Cranial nerves II-XII were normal. Tone, muscle bulk and strength, and

coordination were normal, and the reflexes were active and symmetric. Sensation was intact. Gait and station were normal.

Her preliminary studies suggested right temporal lobe seizure origin but were not definitive. Video-EEG monitoring with scalp and sphenoidal (basal temporal lobe) electrodes demonstrated right sphenoidal spike discharges only when asleep. Four seizures were recorded; one was not localized in origin and three displayed early right temporal lobe activity. A thiopental activation test was negative. Neuropsychometric studies disclosed mild impairment of both verbal and visuo-spatial (including facial recognition) memory. Intracarotid amobarbital injection demonstrated left hemisphere dominance for language and intact memory in the left hemisphere.

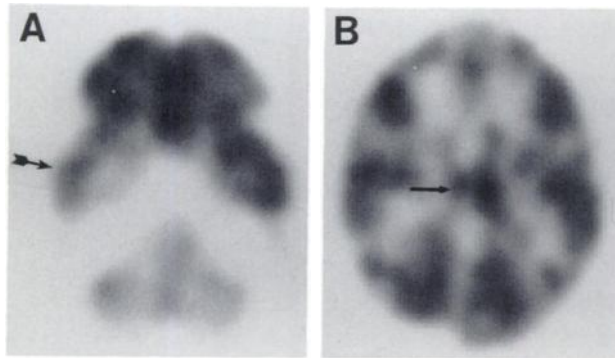
Because of the inconclusive preliminary testing, further diagnostic procedures were performed to establish a firm diagnosis. A positron emission tomography (PET) scan using fluorine-18-fluorodeoxyglucose (FDG) was performed to determine regional cerebral metabolism. This showed a significant reduction in the metabolic activity in the right temporal region and ipsilateral thalamus (Fig. 1). Intracranial electrodes were placed bilaterally in the temporal lobes and frontal lobes and the EEG was recorded to determine the source of her seizures. During her 19-day intensive monitoring session, five complex partial seizures and one secondarily generalized seizure were observed. All began in the right hippocampus and amygdala.

The patient underwent a right anterior temporal lobectomy shortly thereafter without complication. Histopathologic examination of the specimen showed mesial temporal sclerosis, with gliosis and cell loss in limbic structures. In the 6 mo since surgery, she has not experienced any auras or seizures, and reports a significant improvement in her mood and work performance. Postoperative neuropsychometric testing revealed improvement in facial recognition and visual scanning, and no change in verbal memory or language.

---

Received Jun. 11, 1990; accepted Jun. 11, 1990.

For reprints contact: Michael R. Sperling, MD, Department of Neurology, Graduate Hospital, One Graduate Plaza, Philadelphia, PA 19146.



**FIGURE 1**  
(A & B) Interictal PET scan illustrates diminished FDG uptake in the right temporal lobe, which is pronounced mesially (A). Also, ipsilateral thalamic activity appears decreased (B) (note arrows).

## DISCUSSION

### Epilepsy Considerations

This patient's history is typical for temporal lobe epilepsy. Many such patients have unremarkable prenatal and perinatal periods and appear in good health until they experience a febrile convulsion, usually before the age of 3 yr. Although the vast majority of febrile convulsions are benign (1), early childhood convulsions, whether febrile or nonfebrile, are common antecedents in patients with long-standing partial complex seizures (2,3). While recurrent seizures unrelated to febrile episodes may immediately follow an early childhood convulsion, they usually do not commence for several years. Once they begin, often the prognosis is poor. As many as 70% of patients with temporal lobe epilepsy whose seizures began in childhood require long-term anticonvulsant therapy, and half of these individuals may continue to experience seizures in spite of adequate treatment (3-5).

Persistent seizures that interfere with consciousness, particularly when associated with other neurologic impairments, often lead to permanent disability, psychiatric disorders, and social maladjustment (6,7). When seizures produce such impairments, consideration should be given to surgical therapy. Resection of epileptic tissue can eliminate or substantially mitigate seizures and the disabilities they cause, so that patients may live a relatively normal and more satisfying life (8,9). The probability of a successful outcome after surgery ranges from 50% to 90%, depending upon the underlying factors in each individual case, whereas serious permanent neurologic morbidity ranges from less than 1% to 5% depending on the surgical procedure performed (<1% for anterior temporal lobectomy in experienced hands) (9).

### Presurgical Evaluation Process

The purpose of the presurgical evaluation process is to identify and delimit the region of the brain to be

resected. Since surgical results are best when the excised tissue contains a histopathologic lesion, preoperative testing attempts to detect such an abnormality and establish that it is epileptogenic. The pathologic findings in temporal lobe epilepsy in the absence of tumor are usually confined to mesial temporal structures. The most common abnormality is mesial temporal sclerosis (Ammon's horn sclerosis), which is characterized by gliosis and neuronal loss in the hippocampus (10,11). This is not reliably detected by magnetic resonance imaging (12) and, therefore, physiologic methods must be used to diagnose this condition.

A variety of procedures are utilized to evaluate patients for epilepsy surgery (9). Current diagnostic protocols employ multiple localization techniques. When data from several different tests are concordant, the probability of accurate localization and a favorable outcome increases considerably.

### EEG Techniques

The surface EEG frequently reveals abnormalities in the interictal (interseizure) period (13). These include localized spike discharges, which are a hallmark of hyperexcitable cortex, and focal slow waves in the EEG background, which may indicate an underlying structural abnormality. The intravenous injection of thio-pental may not induce high frequency beta waves in the EEG in the involved temporal lobe, which often indicates gliosis in that region. Studying the EEG during seizures is especially helpful in locating their source, though scalp recording is often inadequate for definitive localization of seizure origin.

Intracranial EEG recording, using electrodes either implanted directly into the substance of the brain or placed in the subdural or epidural spaces, is considered the most accurate means of identifying the region responsible for seizures (14). However, this technique is invasive and carries a small degree of risk (1%-5%), so it is desirable to reserve its use for situations when noninvasive techniques are inadequate for diagnosis.

### Cognitive Testing

Cognitive testing may also help identify an abnormal temporal lobe. Mesial temporal structures are particularly crucial for the registration of new memories, and assessment of verbal and spatial memory, largely subserved by the left and right temporal lobes, respectively, may help lateralize hippocampal damage. The intracarotid amobarbital injection (Wada test) establishes which hemisphere is language dominant, and also can be used to assess memory capabilities of each temporal lobe independently (15).

### Imaging Techniques

Imaging techniques also play an important role in evaluating patients for epilepsy surgery. Magnetic resonance imaging (MRI), positron emission tomography

(PET), and single-photon emission tomography (SPECT) have all been used to identify epileptic tissue for resection.

**MRI.** MRI is especially sensitive for detecting neoplasms in patients with epilepsy. They have been reported in 12%–48% of patients who have undergone surgical treatment (12,16–18). MRI is particularly informative for middle fossa tumors since bone artifacts on computed tomography (CT) images render this region uninterpretable (19). The tumors most commonly reported in MRI series have been indolent, and include low-grade astrocytomas, gangliogliomas, arteriovenous malformations, and hamartomas. The use of paramagnetic contrast agents has not significantly enhanced the sensitivity of MRI in detecting brain tumors in patients with epilepsy (20). While CT scanning frequently reveals atrophy in patients with epilepsy (21), MRI appears to be superior for this purpose because it more readily visualizes the cerebrospinal fluid spaces. MRI can detect hemispheric and temporal lobe atrophy, as well as focal atrophy of the hippocampus (22–26). A nonspecific increase in signal intensity in T2-weighted images in mesial temporal regions has also been reported in patients with refractory partial epilepsy (17, 22–25). It has been suggested that this may indicate mesial temporal sclerosis, but this remains unproven. The increased signal intensity does not always correlate well with the precise location of pathologic changes (22), and has not been noted in some series reporting patients with proven mesial temporal sclerosis (14,16).

**PET.** PET has also proven informative in epilepsy. Most PET studies have examined cerebral metabolism with FDG. Interictally, the most common abnormality in epilepsy is focal cortical decreased FDG uptake (hypometabolism) (12,27–36). Interictal diminished blood flow has been noted in the hypometabolic region (33, 37,38). Single hypometabolic cortical regions occur in 55%–80% of patients with partial epilepsy, though multiple hypometabolic regions are occasionally seen in this population. Subcortical hypometabolism, involving thalamus and basal ganglia, has also been reported (39). While the usual pathologic abnormality underlying the temporal lobe hypometabolism is mesial temporal sclerosis, the area of hypometabolism typically extends well beyond the structural lesion (12,40). The reason for hypometabolism is uncertain. Reduced glucose metabolism may be related to cortical atrophy and the diminished number of cells. The distant hypometabolism may reflect diminished synaptic activity. Though exceptions occur, the hypometabolic region corresponds to the area of seizure origin, so PET-FDG scanning is helpful in selecting patients with partial epilepsy for resective surgery (29,41). The hypometabolism is reversible. Gur and colleagues (42) reported normalization of temporal lobe hypometabolism after corpus callosotomy in a patient with generalized epilepsy. Dashieff and associ-

ates (43) noted increased temporal lobe metabolism after excision of a parietal lobe vascular malformation with relief of seizures. Effects of behavioral activation on the hypometabolic region are still unknown.

During partial seizures, energy requirements are increased. Therefore, increased FDG uptake is noted in previously hypometabolic regions (33,44,45). During seizures, the hypermetabolic zones may be highly restricted or multifocal, involving areas to which seizures propagate. Because of these complex patterns, ictal PET studies are of uncertain value for localizing an epileptic focus for surgery.

PET also has been used in selecting infants with intractable seizures for surgery (46). Abnormal interictal and ictal zones helped identify tissue for resection.

More recently, neurotransmitter receptor imaging studies have been performed in patients with seizure disorders. Savic and colleagues (47) noted diminished benzodiazepine receptor binding in the mesial temporal lobe of patients with partial epilepsy. This could reflect a disturbance of local inhibitory mechanisms, but is also consistent with neuronal loss in that area without impairment of inhibition in remaining neurons. Since the area of abnormality was more restricted than in FDG studies, benzodiazepine studies may offer more precise localization of epileptic foci for surgical intervention. Opiate receptors are also altered in partial epilepsy. They were increased in temporal lobe neocortex but appeared normal in mesial structures (48). The receptor increase was postulated to represent a neuronal response that might limit seizure spread from other temporal lobe structures. Additional studies with these and new receptor ligands should prove informative.

**SPECT.** SPECT findings are similar to those of PET. Interictal cerebral hypoperfusion (and rarely interictal hyperperfusion), and ictal and immediate post-ictal hyperperfusion in partial epilepsy with iodine-123-labeled radiopharmaceuticals or xenon-133 (49–52) have been shown. This has been confirmed with technetium-99-labeled compounds (53–61). Hypoperfused regions are seen in perhaps 50% of patients with partial epilepsy interictally and they often correspond to the EEG focus, though exceptions are not infrequent. Homan and colleagues (62) also found that localized cognitive deficits apparent on neuropsychological testing corresponded to these hypoperfused regions. Interictal hypoperfusion has also been described in West syndrome (63).

Ictal, or rather, immediate post-ictal SPECT scanning with technetium-labeled HMPAO may be more accurate and sensitive for localizing a seizure focus than interictal scanning (61,64). Rowe and associates (61) found focal hyperperfusion in immediate post-ictal scans. The area of hyperperfusion was more restricted, confined to mesial temporal regions, and corresponded more closely to the pathologic lesion than the interictal SPECT abnormality.

## CONCLUSION

As surgery becomes more widely utilized as a treatment for intractable partial epilepsy, the challenge remains to improve methods for accurate localization and prediction of outcome. PET and SPECT have several advantages that make them ideally suited for this purpose. They noninvasively provide physiologic and anatomic information about the seizure focus and are of proven value in the preoperative assessment of patients for epilepsy surgery. The major limitation of perfusion and metabolic studies is that of specificity, since not all abnormal zones are responsible for triggering seizures. However, combining PET or SPECT data with that obtained by other noninvasive tests, such as EEG, MRI, or cognitive tests, may prove to be a powerful approach for determining which patients are suitable for surgery. The potential contributions of PET and SPECT neurotransmitter receptor studies to epilepsy are especially exciting. They may lead to a more precise definition of a seizure focus, and also could provide information regarding the pathophysiology of epilepsy.

## REFERENCES

1. Annegers JF, Hauser WA, Elveback JR, Kurland LT. The risk of epilepsy following febrile convulsions. *Neurology* 1979; 29:297-303.
2. Falconer MA. Genetic and related aetiological factors in temporal lobe epilepsy. *Epilepsia* 1971; 12:13-31.
3. Lindsay J, Ounsted C, Richards P. The long-term outcome in children with temporal lobe seizures. IV. Genetic factors, febrile convulsions, and the remission of seizures. *Dev Med Child Neurol* 1980; 22:429-439.
4. Currie S, Heathfield WG, Henson RA, Scott DR. Clinical course and prognosis of temporal lobe epilepsy. *Brain* 1971; 94:173-190.
5. Juul-Jensen P, Feldspang A. Natural history of epileptic seizures. *Epilepsia* 1983; 24:297-312.
6. Lindsay J, Ounsted C, Richards P. The long-term outcome in children with temporal lobe seizures I. Social outcome and childhood factors. *Dev Med Child Neurol* 1979; 21:285-298.
7. Lindsay J, Ounsted C, Richards P. The long-term outcome in children with temporal lobe seizures. III. Psychiatric aspects in childhood and adult life. *Dev Med Child Neurol* 1979; 21:630-636.
8. Jensen I. Temporal lobe epilepsy. Etiological factors and surgical results. *Acta Neurol Scand* 1976; 53:103-118.
9. Engel J. *Surgical treatment of the epilepsies*. New York: Raven Press; 1987.
10. Margerison JH, Corsellis JAN. Epilepsy and the temporal lobes. *Brain* 1966; 89:499-530.
11. Sagar HJ, Osbury JM. Hippocampal neuron loss in temporal lobe epilepsy: correlation with childhood convulsions. *Ann Neurol* 1987; 22:334-340.
12. Sperling MR, Wilson G, Engel J Jr, et al. Magnetic resonance imaging in intractable partial epilepsy: correlative studies. *Ann Neurol* 1986; 20:57-62.
13. Ajmone-Marsan C. Clinical-electrographic correlations of partial seizures. In: Wada, J, ed. *Modern perspectives in epilepsy*. Montreal: Eden Press; 1978:76-98.
14. Sperling MR, O'Connor MJ. Comparison of depth and subdural electrodes in recording temporal lobe seizures. *Neurology* 1989; 39:1497-1504.
15. Blume WT, Grabow JD, Darley FL, Aronson AE. Intracarotid amobarbital test of language and memory before temporal lobectomy for seizure control. *Neurology* 1973; 23:812-819.
16. Bergen D, Bleck T, Ramsey R, et al. Magnetic resonance imaging as a sensitive and specific predictor of neoplasms removed for intractable epilepsy. *Epilepsia* 1989; 30:318-321.
17. Kuzniecky R, de la Sayette V, Ethier R, et al. Magnetic resonance imaging in temporal lobe epilepsy: pathological correlations. *Ann Neurol* 1987; 22:341-347.
18. Laster DW, Penry JK, Moody DM, et al. Chronic seizure disorders: contribution of MR imaging when CT is normal. *Am J Neuroradiol* 1985; 6:177-180.
19. Aaron J, New PF, Strand R, et al. NMR imaging in temporal lobe epilepsy due to gliomas. *J Comput Assist Tomogr* 1984; 8:608-613.
20. Cascino GD, Hirschorn KA, Jack CR, et al. Gadolinium-DPTA-enhanced magnetic resonance imaging in intractable partial epilepsy. *Neurology* 1989; 39:1115-1118.
21. Gastaut H, Gastaut JL. Computerized transverse axial tomography in epilepsy. *Epilepsia* 1976; 17:325-336.
22. Avrahami E, Cohn DF, Neufeld M, et al. Magnetic resonance imaging (MRI) in patients with complex partial seizures and normal computerized tomography (CT) scan. *Clin Neurol Neurosurg* 1987; 89:231-235.
23. McLachlan RS, Nicholson RL, Black S, et al. Nuclear magnetic resonance imaging, a new approach to the investigation of refractory temporal lobe epilepsy. *Epilepsia* 1985; 26:555-562.
24. Sostman HD, Spencer DD, Gore JC, et al. Preliminary observations on magnetic resonance imaging in refractory epilepsy. *Mag Res Imaging* 1984; 2:301-306.
25. Lesser RP, Modic MT, Weinstein MA, et al. Magnetic resonance imaging (1.5 tesla) in patients with intractable focal seizures. *Arch Neurol* 1986; 43:367-371.
26. Latack JT, Abou-Kahlil BW, Seigel GJ, et al. Patients with partial seizures: evaluation by MR, CT, and PET imaging. *Radiology* 1986; 159:159-163.
27. Theodore WH, Dorwart R, Holmes M, et al. Neuroimaging in refractory partial seizures: comparison of PET, CT, and MRI. *Neurology* 1986; 36:750-759.
28. Swartz BE, Halgren E, Delgado-Escueta AV, et al. Neuroimaging in patients with seizures of probable frontal lobe origin. *Epilepsia* 1989; 30:547-558.
29. Engel J Jr, Crandall PH, Rausch R. Surgical treatment of the partial epilepsies. In: Rosenberg RN, ed. *The clinical neurosciences*. New York: Churchill Livingstone; 1983:1349-1380.
30. Engel J Jr, Kuhl DE, Phelps ME, et al. Interictal cerebral glucose metabolism in partial epilepsy and its relation to EEG changes. *Ann Neurol* 1982; 12:510-517.
31. Engel J Jr, Kuhl DE, Phelps ME, et al. Comparative localization of epileptic foci in partial epilepsy by PCT and EEG. *Ann Neurol* 1982; 12:529-537.
32. Engel J Jr, Rausch R, Lieb JP, et al. Correlation of criteria used for localizing epileptic foci in patients considered for surgical therapy of epilepsy. *Ann Neurol* 1981; 9:215-224.
33. Kuhl DE, Engel J Jr, Phelps ME, et al. Epileptic patterns of local cerebral metabolism and perfusion in humans determined by emission computed tomography of  $^{18}\text{F}$ FDG and  $^{13}\text{NH}_3$ . *Ann Neurol* 1980; 8:348-360.
34. Theodore WH, Brooks R, Sato S, et al. The role of positron emission tomography in the evaluation of seizure disorders. *Ann Neurol* 1984; 15(suppl):S176-S179.
35. Theodore WH, Newmark ME, Sato S, et al. [ $^{18}\text{F}$ ]fluorodeoxyglucose positron emission computed tomography in refrac-

- tory complex partial seizures. *Ann Neurol* 1983; 14:429-437.
36. Holmes MD, Kelly K, Theodore WH. Complex partial seizures. Correlation of clinical and metabolic features. *Arch Neurol* 1988; 45:1191-1193.
  37. Gallhofer B, Trimble MR, Frackowiak R, et al. A study of cerebral blood flow and metabolism in epileptic psychosis using positron emission tomography and oxygen. *J Neurol Neurosurg Psychiatr* 1985; 48:201-206.
  38. Bernardi S, Trimble MR, Frackowiak RS, et al. An interictal study of partial epilepsy using positron emission tomography and the oxygen-15 inhalation technique. *J Neurol Neurosurg Psychiatr* 1983; 46:473-477.
  39. Sperling MR, Gur RC, Alavi A, et al. Subcortical metabolic alterations in partial epilepsy. *Epilepsia* 1990; 31:145-155.
  40. Engel J Jr, Brown WJ, Kuhl DE, et al. Pathological findings underlying focal temporal lobe hypometabolism in partial epilepsy. *Ann Neurol* 1982; 12:518-528.
  41. Cowan JM, Rothwell JC, Wise RJ, Marsden CD. Electrophysiological and positron emission studies in a patient with cortical myoclonus, epilepsy partialis continua and motor epilepsy. *J Neurol Neurosurg Psychiatr* 1986; 49:796-807.
  42. Gur RC, Sussman NM, Alavi A, et al. Positron emission tomography in two cases of childhood epileptic encephalography (Lennox-Gastaut syndrome). *Neurology* 1982; 32:1191-1195.
  43. Dashieff RM, Rosenbek J, Matthews C, et al. Epilepsy surgery improves regional glucose metabolism on PET scan. *J Neurol* 1987; 234:283-288.
  44. Engle J Jr, Kuhl DE, Phelps ME. Patterns of human local cerebral glucose metabolism during epileptic seizures. *Science* 1982; 218:64-66.
  45. Engel J Jr, Kuhl DE, Phelps ME, et al. Local cerebral metabolism during partial seizures. *Neurology* 1983; 33:400-413.
  46. Chugani HT, Shewmon DA, Peacock WJ, et al. Surgical treatment of intractable neonatal-onset seizures: the role of positron emission tomography. *Neurology* 1988; 38:1178-1188.
  47. Savic I, Persson A, Roland P, et al. In-vivo demonstration of reduced benzodiazepine receptor binding in human epileptic foci. *Lancet* 1988; 2:863-866.
  48. Frost JJ, Mayberg HS, Fisher RS, et al. Mu-opiate receptors measured by positron emission tomography are increased in temporal lobe epilepsy. *Ann Neurol* 1988; 23:231-237.
  49. Biersack HJ, Penin H, Hartmann A, et al. Cerebral emission computed tomography (SPECT) with 123-I-labelled amphetamines. *Dtsch Med Wochenschr* 1984; 109:1155-1159.
  50. Bonte FJ, Stokely EM, Devous MD, et al. Single photon tomographic determination of regional cerebral blood flow. *AJNR* 1983; 4:544-546.
  51. Magistretti R, Uren RF, Parker JA, et al. Monitoring of regional cerebral blood flow by single photon emission tomography of <sup>123</sup>I-N-isopropyl-iodoamphetamine in epileptics. *Ann Radiol* 1983; 26:68-71.
  52. Sanabria E, Chauvel P, Askienazy S, et al. Single-photon emission computed tomography (SPECT) using I-123-isopropyl-iodo-amphetamine (IAMP) in partial epilepsy. In: Baldy-Moulinier M, Ingvar DH, Meldrum BS, eds. *Current problems in epilepsy: cerebral blood flow, metabolism, and epilepsy*. London: John Libbey; 1983:82-87.
  53. Ryding E, Rosen I, Elmqvist D, et al. SPECT measurements with <sup>99m</sup>Tc-HM-PAO in focal epilepsy. *J Cereb Blood Flow Metab* 1988; 8:S95-100.
  54. Denays R, Rubinstein M, Ham H, et al. Single-photon emission computed tomography in seizure disorders. *Arch Dis Child* 1988; 63:1184-1188.
  55. Stefan H, Kuhnen C, Biersack HJ, et al. Initial experience with <sup>99m</sup>Tc-hexamethyl-propylene amine oxime (HM-PAO) single photon emission computed tomography (SPECT) in patients with focal epilepsy. *Epilepsy Res* 1987; 1:134-138.
  56. Grasso E, Ambrogio L, Cognazzo A, et al. Single-photon emission computed tomography with <sup>99m</sup>Tc-HM-PAO in the study of focal epilepsy. *Ital J Neurol Sci* 1989; 10:175-179.
  57. LaManna MN, Sussman NM, Harner RN, et al. Initial experience with SPECT imaging of the brain using I-123-p-iodoamphetamine in focal epilepsy. *Clin Nucl Med* 1989; 14:428-430.
  58. English R, Soper N, Shepstone BJ, et al. Five patients with Rasmussen's syndrome investigated by single-photon-emission computed tomography. *Nucl Med Comm* 1989; 10:5-14.
  59. Lee BI, Markand ON, Siddiqui AR, et al. Single-photon emission computed tomography (SPECT) brain imaging using N,N,N'-trimethyl-N'-(2-hydroxy-3-methyl-5-<sup>123</sup>I-isobenzyl)-1,3-propanediamine 2 HCl (HIPDM): intractable complex partial seizures. *Neurology* 1986; 36:1471-1477.
  60. Lee BI, Markand ON, Wellman HN, et al. HIPDM single-photon emission computed tomography brain imaging in partial onset secondarily generalized tonic-clonic seizures. *Epilepsia* 1987; 28:305-311.
  61. Rowe CC, Berkovic SF, Sia STB, et al. Localization of epileptic foci with postictal single-photon emission computed tomography. *Ann Neurol* 1989; 26:660-668.
  62. Homan RW, Paulman RG, Devous MD, et al. Cognitive function and regional cerebral blood flow in partial seizures. *Arch Neurol* 1989; 46:964-970.
  63. Chiron C, Raynaud C, Jambaque I, et al. <sup>133</sup>Xe brain SPECT imaging in cryptogenic West syndrome: correlations between regional CBF defects and neuropsychologic disorder. *J Nucl Med* 1987; 28:592.
  64. Lee BI, Markand ON, Wellman HN, et al. HIPDM-SPECT in patients with medically intractable complex partial seizures: ictal study. *Arch Neurol* 1988; 45:397-402.