

# Reversible Pulmonary Uptake and Hypertrophic Pulmonary Osteoarthropathic Distribution of Technetium-99m Methylene Diphosphonate in a Case of *Pneumocystis Carinii* Pneumonia

Rafael A. Vaquer, Eddy K. Dunn, Subrahmanya Bhat, Albert E. Heurich, Stephan L. Kamholz, and Arnold M. Strashun

Department of Radiology, Division of Nuclear Medicine, Department of Medicine, Division of Pulmonary Medicine, Kings County Medical Center; and SUNY-Health Science Center at Brooklyn, Brooklyn, New York

Diffuse pulmonary deposition of [<sup>99m</sup>Tc]methylene diphosphonate (MDP) as well as abnormalities characteristic of hypertrophic pulmonary osteoarthropathy have been observed in a patient with *Pneumocystis carinii* pneumonia (PCP). The findings of the bone scan together with those in the corresponding scintigraphy, and roentgenograms of the chest and skeletal structures are presented. Parallel reversal of [<sup>67</sup>Ga]citrate and [<sup>99m</sup>Tc]MDP pulmonary uptake with specific treatment for and clinical resolution of PCP implies a causal relationship.

J Nucl Med 30:1563-1567, 1989

Technetium-99m methylene diphosphonate ([<sup>99m</sup>Tc]MDP) bone scintigraphic imaging has been proven to be useful in both the diagnosis and follow-up of medical intervention in secondary hypertrophic pulmonary osteoarthropathy (HPOA) (1-4) because of its ability to delineate the subtleties in progression and disappearance of disease processes, and its high sensitivity in detecting radiographically occult abnormalities. *Pneumocystis carinii* pneumonia (PCP) as a cause of HPOA and increased pulmonary deposition of [<sup>99m</sup>Tc]MDP is described in the following report.

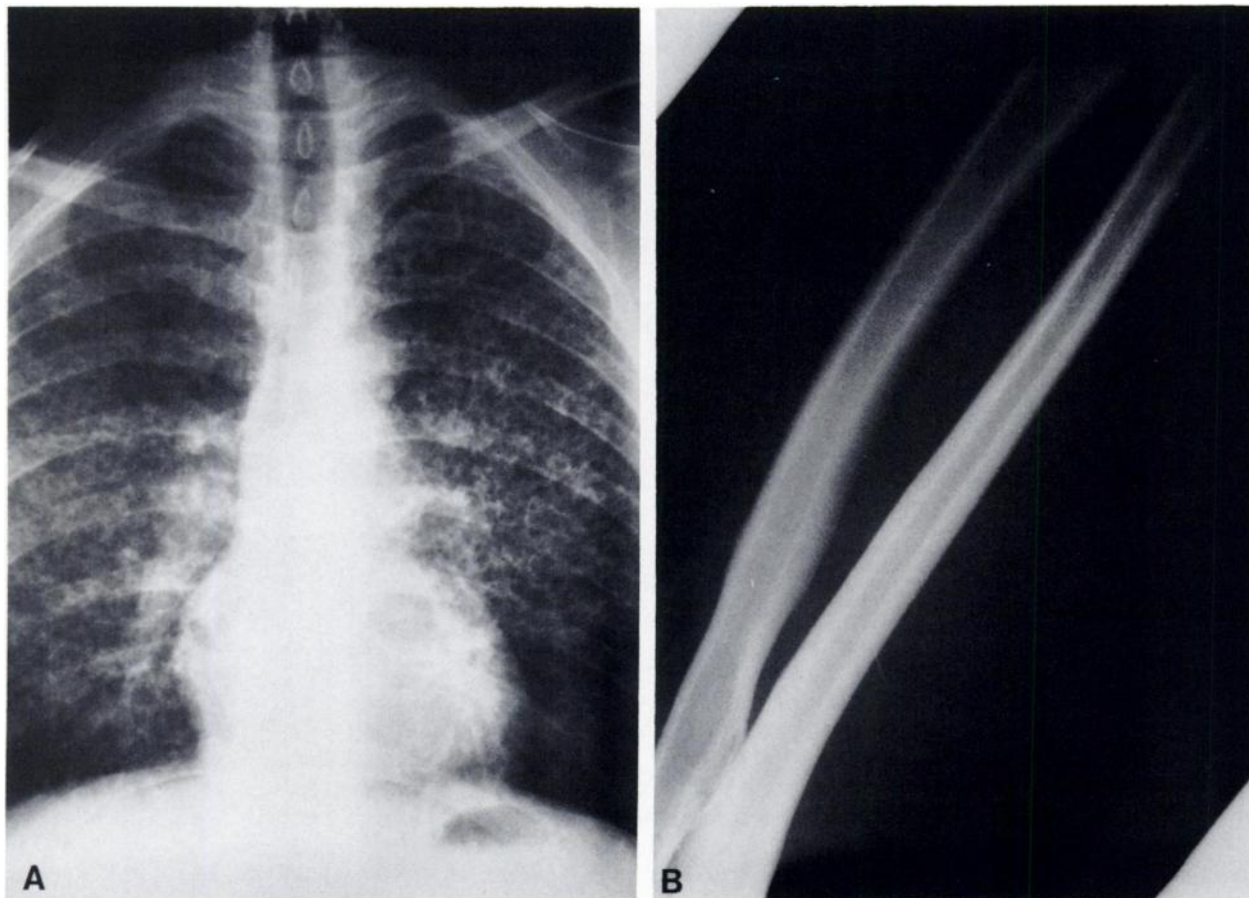
## CASE REPORT

A 37-yr-old black male was admitted to Kings County Hospital Center, March 16, 1988, with chief complaints of progressive weight loss, dyspnea, generalized malaise, diarrhea, fever, and bone pain. The patient had a long history of

more than 10 yr of i.v. drug abuse of heroin and cocaine. On admission, his chest x-ray (CXR) (Fig. 1) showed extensive bilateral coarse reticulo-nodular interstitial infiltrates. At this time, he was found to have a positive (+) HIV titers. Transbronchial lung biopsy, bronchoalveolar lavage, and brushings revealed PCP. Routine Hematoxylin and Eosin stains, as well as Von Kossa stains specific for calcium deposits were performed to exclude histologically evidence of pulmonary calcium deposition or pulmonary fibrosis. The patient was treated with trimethoprim-sulfamethoxazole (TMP-SMX) for 10 days as therapy for PCP. Nevertheless, he clinically deteriorated, remaining febrile and dyspneic. He was then treated with i.v. broad spectrum antibiotics and amphotericin-B for what appeared to be a clinical picture of sepsis. In his tenth day of treatment with TMP-SMX, he developed a dermatitis thought to be secondary to TMP-SMX that led to its discontinuation. Intravenous pentamidine, therapy specific for PCP, was then initiated. Although initially his CXR appeared to worsen, the patient showed immediate and progressive clinical improvement. Blood cultures were negative for bacteria and fungi. The i.v. antibiotics and amphotericin-B were therefore discontinued. Prior to the substitution of Pentamidine for TMP-SMX, a bone scan was performed, March 22, 1988, using 21 mCi (777 MBq) of [<sup>99m</sup>Tc]MDP given intravenously. Bone scintigraphs revealed diffusely increased pulmonary deposition of activity, left lung more than the right lung field (Fig. 2A). Irregular increased pericortical deposition of activity in

Received Sept. 20, 1988; revision accepted Apr. 25, 1989.

For correspondence contact: Rafael A. Vaquer, MD, Dept. of Radiology, Div. of Nuclear Medicine, SUNY-Health Science Center at Brooklyn, 450 Clarkson Ave., Box 1210, Brooklyn, NY 11203 [Reprints are not available from the author].



**FIGURE 1**

**A:** Single chest PA roentgenogram showing a coarse reticulonodular pattern bilaterally, obtained 4 April 1988, during the patient's first admission. **B:** Roentgenographic views of Rt. radius and ulna, obtained 19 March 1988, showing periosteal calcium deposits.

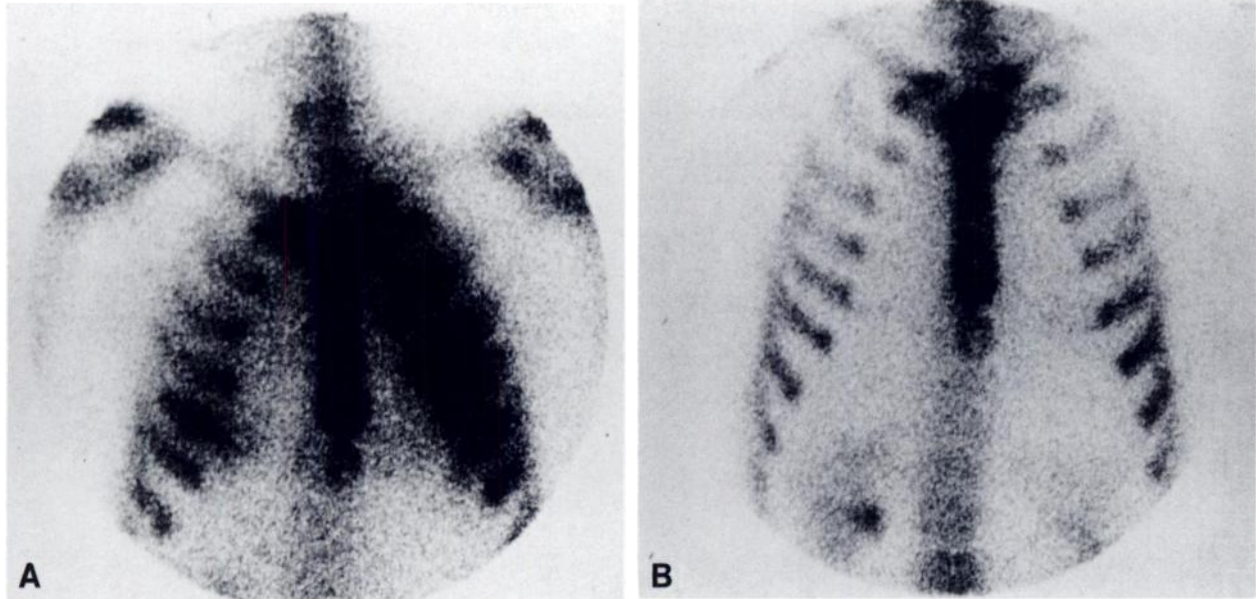
the long bones (femur and tibia) consistent with secondary HPOA was also observed (Fig. 3A). The roentgenograms of the radius and ulna revealed increased periosteal deposition of calcium, most prominently noted in the radius and tibia. These radiographs were obtained 19 March 1988, 4 days prior to the bone scan (Fig. 1B). Also, the anterior thoracic and posterior abdominal bone scintigrams showed evidence of neither abnormal gastric nor renal soft-tissue deposition of [<sup>99m</sup>Tc]MDP as would be seen in metastatic calcification (Fig. 2A and 4). Calcium (Ca<sup>++</sup>), phosphorus (HPO<sub>4</sub><sup>-</sup>) and alkaline phosphatase serum levels were normal. Renal function was normal. A gallium-67 (<sup>67</sup>Ga) citrate scintigraphic study obtained 21 April 1988, was performed using 5 mCi (185 MBq) of [<sup>67</sup>Ga]citrate given intravenously. Gallium scintigraphy demonstrated a bilateral intense (+5) diffuse pulmonary uptake (6) in the same pattern as in the bone scan (Fig. 5A). No other focal gallium abnormalities were identified. Multiple CXRs were obtained and showed waxing and waning of the findings of bilateral coarse reticulo-nodular interstitial infiltrates.

After successful pentamidine therapy for PCP, the patient was discharged and remained clinically stable for 3 mo. He then returned with new complaints of dyspnea and fever, and was found to have clinical bronchitis, successfully treated with a short course of erythromycin. His CXR at that time revealed

significant clearing of the reticulo-nodular infiltration pattern. In addition, he no longer complained of bone pain. A follow-up bone scan done 5 August 1988, using 22.6 mCi (836.2 MBq) of [<sup>99m</sup>Tc]MDP, showed almost complete resolution of HPOA and total reversal (absence) of pulmonary deposition of [<sup>99m</sup>Tc]MDP activity (Fig. 2B and 3B). A gallium scintigraphic study was also repeated 72 hr later, using 10 mCi (370 MBq) [<sup>67</sup>Ga]citrate given intravenously. Gallium scintigraphs now revealed only mild (+1) diffuse increased pulmonary uptake and a few focal areas of slightly greater (+2) uptake in the medial aspect of the right lower lung field (Fig. 5B). This latter finding would be consistent with the concurrent episode of bronchitis that the patient had a week prior to the follow-up gallium scan. The rest of the gallium study was unremarkable.

## DISCUSSION

Bone imaging for the evaluation and follow-up of HPOA has been described (1-4). In hypertrophic pulmonary osteoarthropathy, there is an initial pericortical inflammatory reaction with round cell infiltration and proliferation of vascular connective tissue followed by



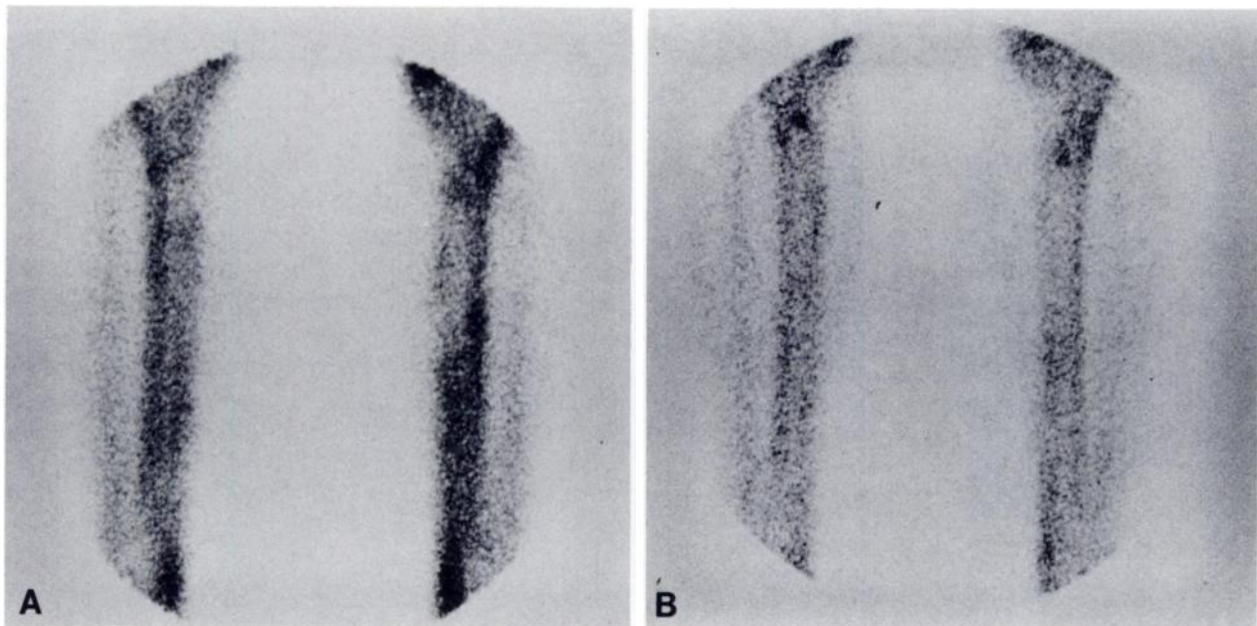
**FIGURE 2**

A: Anterior thoracic bone scintigram revealing diffuse, bilateral increased but asymmetric pulmonary parenchymal uptake, left lung more than the right lung field, obtained 23 March 1988, during his first admission. Note absence of soft-tissue gastric activity. B: Anterior thoracic bone scintigram, obtained 5 August 1988, 4 mo after initial CXR and bone scan shows clearing of lung activity.

osteoid formation and calcification (5). The increased pericortical deposition of [ $^{99m}\text{Tc}$ ]MDP activity, diffuse, or irregular (patchy), corresponds to locations of histologic heterotopic bone formation (6).

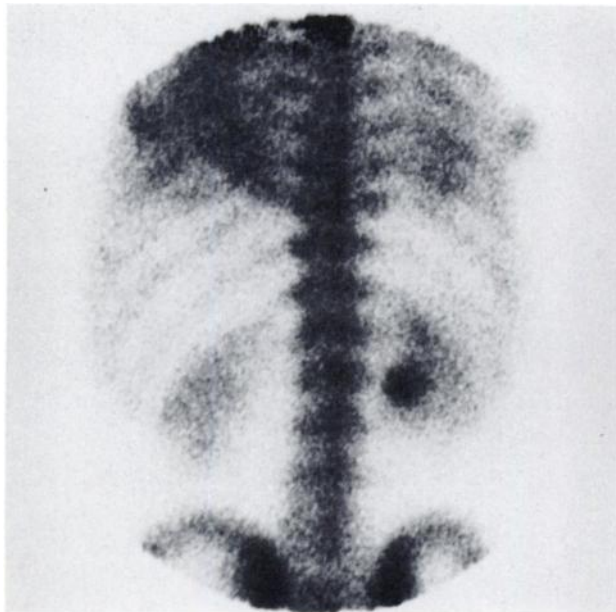
Causes in which diffuse pulmonary uptake with  $^{99m}\text{Tc}$

bone imaging agents has been noted include: chronic renal disease with secondary hyperparathyroidism; primary hyperparathyroidism; hypercalcemia resulting from extensive skeletal metastasis, multiple myeloma, malignant melanoma or non-Hodgkin's lymphoma; hy-



**FIGURE 3**

A: Anterior bone scintigrams of the legs (tibia and fibula), revealing increased irregular and diffuse pericortical deposition of bone scintigraphic agent, [ $^{99m}\text{Tc}$ ]MDP, respectively, obtained 22 March 1988. B: Bone scintigrams of the legs (tibia and fibula) showing complete reversal of skeletal changes consistent with HPOA following successful treatment of PCP with PCP specific therapy with pentamidine.



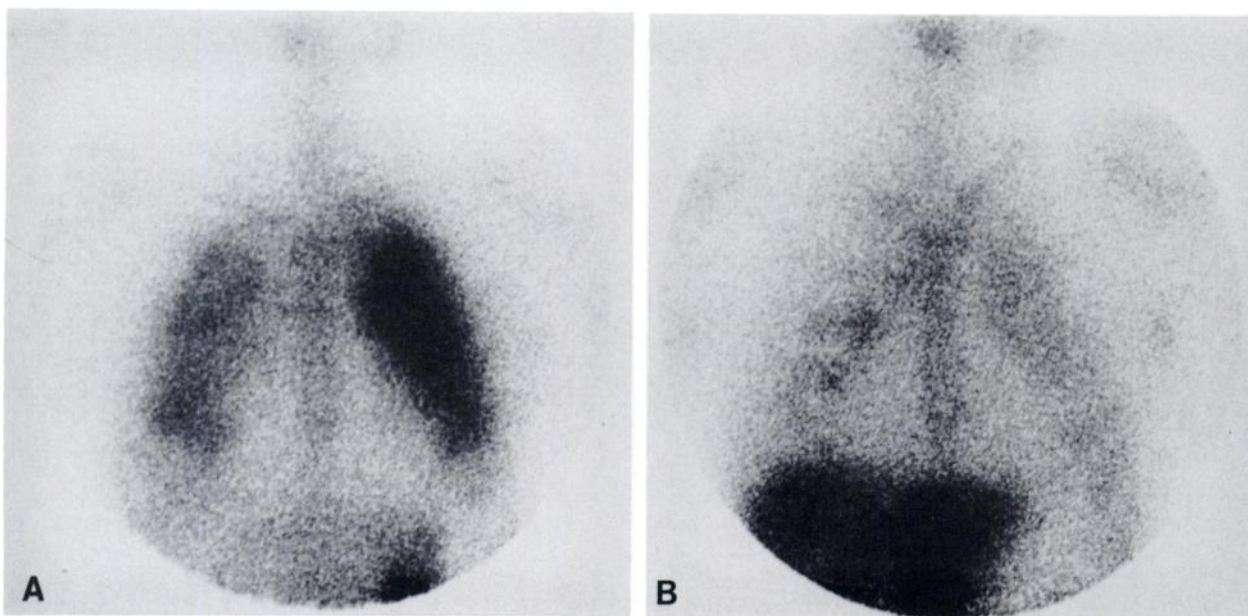
**FIGURE 4**  
Posterior bone scintigram of the abdomen showing no scintigraphic evidence of abnormal gastric fundus or renal deposition of bone imaging agent, [<sup>99m</sup>Tc]MDP, findings typical of metastatic calcification.

pervitaminosis D; prolonged therapy with phosphates, adrenocorticosteroids or calcium infusions; idiopathic alveolar microlithiasis; aspergillosis; tuberculosis; radiation pneumonitis; and berylliosis (7-9).

Causes of diffuse [<sup>67</sup>Ga]citrate pulmonary uptake have also been described and include: sarcoid, bacterial

pneumonitis (pneumococcus, Legionella), tuberculosis, cytomegalovirus, Korean hemorrhagic fever, psittacosis, Pneumocystis carinii, coccidioides, paragonimiasis, aspergilloma, bleomycin, cyclophosphamide, busulphan, radiation pneumonitis, septic microemboli, pneumoconiosis (silicosis, asbestosis), lupus erythematosus, rheumatoid pleuritis, idiopathic pulmonary pneumonitis, fibrosis, eosinophilic granuloma, uremic pneumonitis and bronchitis (9-14).

Auerbach reported <sup>67</sup>Ga uptake in the lung associated with metastatic calcification (15). More recently, a contradictory case report indicating the absence of <sup>67</sup>Ga uptake in metastatic calcification has been reported (16). The authors inferred that in the previous case reported by Auerbach there may be another explanation, other than the metastatic calcium deposits, for the diffuse pulmonary gallium avidity. Both of the patients reported had renal insufficiency, uremia, a high calcium and phosphate product with resultant pulmonary calcium deposits, but Auerbach's patient also had findings on CXR of uremic pneumonitis six weeks prior to admission. It was presumed that uremic pneumonitis and not metastatic calcification was causative. In our case a long history of IVDA, (+) HIV titers, abnormal CXRs and (+) transbronchial biopsy and bronchial brushings for PCP was present. There was neither radiographic nor histologic evidence of pulmonary metastatic calcification. Following specific treatment for PCP with pentamidine, the resolution of pulmonary uptake and almost complete reversal of skeletal changes on the repeated [<sup>99m</sup>Tc]MDP and <sup>67</sup>Ga images suggests



**FIGURE 5**  
A: Anterior thoracic [<sup>67</sup>Ga]citrate scintigram which reveals intense, (+5) diffuse but asymmetric, left more than the right lung field, pulmonary uptake obtained 21 April 1988, 4 wk after commencement of PCP specific therapy with pentamidine. B: Anterior thoracic [<sup>67</sup>Ga]citrate follow-up scintigram, 8 August 1988, obtained 72 hr after the bone scintigram, showing improvement in lung abnormality.

that severe, active PCP is the most likely explanation for the abnormal pulmonary uptake of both radiopharmaceuticals, as well as cause of HPOA. The explanation for deposition of the bone imaging agents in inflammatory foci is unclear. It has been postulated that such ectopic pulmonary [<sup>99m</sup>Tc]MDP uptake is secondary to increased blood flow or secondary to dystrophic calcification as a result of tissue necrosis (6). In addition, in view of the clinical resolution of bronchitis without specific retreatment for PCP, it is presumed by the authors that this focal gallium activity was not a result of active PCP, but rather to the resolving acute bacterial bronchitis.

## SUMMARY

We report an unusual case of reversible HPOA secondary to acute PCP. In addition, we report scintigraphic findings of diffuse and reversible pulmonary parenchymal [<sup>99m</sup>Tc]MDP uptake. The fact that pulmonary uptake paralleled the clinical course of PCP, as well as the typical evolution of [<sup>67</sup>Ga]citrate pulmonary activity in successfully treated PCP suggests that PCP inflammation was causative. This would add another cause, PCP, to the list of clinical conditions causing diffuse pulmonary [<sup>99m</sup>Tc]MDP activity.

## REFERENCES

1. Kroon HM, Pauwels EK. Bone scintigraphy for the evaluation and follow-up of hypertrophic pulmonary osteoarthropathy. *Diag Imag* 1982; 51:47-55.
2. Spencer RP, Daju JA. Bilateral lower limb uptake of bone scanning agents. *Semin Nucl Med* 1980; 10:314-316.
3. Rosenthal L, Kirsch J. Observations of radionuclide imaging in hypertrophic pulmonary osteoarthropathy. *Radiology* 1976; 120:359-362.
4. Donnelly B, Johnson PM. Detection of hypertrophic pulmonary osteoarthropathy of skeletal imaging with Tc99m-labeled diphosphonate. *Radiology* 1975; 114:389-391.
5. Gall EA, Bennet GA, Bauer W. Generalized hypertrophic osteoarthropathy; pathologic study of 7 cases. *Am J Pathol* 1951; 27:349-381.
6. Charkes ND. Mechanisms of skeletal uptake. *J Nucl Med* 1979; 20:794-795.
7. Coolens JL, Devos P, DeRoo M. Diffuse pulmonary uptake of 99mTc bone imaging agents: case report and survey. *Eur J Nucl Med* 1985; 11:36-42.
8. Rosenthal DR, Chandler HL, Azizi F, et al. Uptake of bone imaging agents by diffuse pulmonary metastatic calcification. *Am J Roentgenol* 1977; 129:871.
9. Silberstein EB. Gallium-67. Non-osseous uptake. In: Silberstein EB, McAfee JG, eds. *Differential diagnosis in nuclear medicine*. New York: McGraw-Hill, Inc., 1984: 128-129, 303.
10. Kramer EL, Sanger JJ, Garay SM, et al. Gallium-67 scans of the chest in patients with acquired immunodeficiency syndrome. *J Nucl Med* 1987; 28:1107-1114.
11. Bitran J, Bekerman C, Weinstein R, et al. Patterns of gallium-67 scintigraphy in patients with acquired immunodeficiency syndrome and the AIDS related complex. *J Nucl Med* 1987; 28:1103-1106.
12. Woolfenden JM, Carrasquillo JA, Larson SM, et al. Acquired immunodeficiency syndrome: Ga-67 citrate imaging. *Radiology* 1987; 162:383-387.
13. Graybeal ML Jr, Berens SV, Jurgensen PF. Gallium-67 scintigraphy in acquired immunodeficiency syndrome complicated by *Pneumocystis carinii* pneumonia. *Clin Nucl Med* 1985; 10:669-670.
14. Datz FL. Gamuts in nuclear medicine. Connecticut: Appleton-Century-Crofts, 1986: 124-125.
15. Auerbach JM, Ho J. Gallium-67 uptake in the lung associated with metastatic calcification. *Am J Roentgenol* 1981; 136:605.
16. Lecklitner ML, Foster RW. Absence of gallium-67 avidity in diffuse pulmonary calcification. *Clin Nucl Med* 1985; 10:632-634.