Quantification of Leg Muscle Perfusion Using Thallium-201 Single Photon Emission Computed Tomography

Motoo Oshima, Hiroshi Akanabe, Sadayuki Sakuma, Takashi Yano, Naomichi Nishikimi, and Shigehiko Shionoya

Department of Radiology, Department of Surgery, Nagoya University School of Medicine, Nagoya, Japan

The purpose of this study is to quantify leg muscle perfusion with ^{201}Tl single photon emission computed tomography (SPECT). Six normal controls and 21 patients with peripheral arterial disease underwent this examination. Thallium-201 leg SPECT of both stress and redistribution was performed using a dual-headed digital gamma camera. Each slice of transverse images was normalized with pixels and whole-body counts. In normal controls, the activity of posterior tibial muscle components was significantly higher than that of anterior tibial muscle components ($p < 0.001$). In 14 components, where patients had insignificant lesions, profile curves were normal in 10 (71%). In 62 components, where patients had arteriographically significant lesions, stress profile curves were abnormal in 57 (92%) compared with normal controls. Approximately, in half (28/62) components which had significant lesions, profile curves showed redistribution after 3 hr compared with normal redistribution curves. In three patients who underwent successful bypass graftings, the activity of each muscle component returned to a normal range.

J Nucl Med 30:458–465, 1989

Conventional contrast arteriography has been used for the assessment of peripheral arterial disease. While it offers the anatomic details of vessels, arteriography provides little or no information concerning small-vessel patency, muscle viability, or collateral blood supply (*1,2*). Therefore, in patients with peripheral arterial disease there is a need for information at the microcirculation blood flow level to the muscle prior to therapeutic intervention.

Thallium-201 (^{201}Tl) scintigraphy reflects the local blood flow perfusion and has been performed for the assessment of ischemic heart disease (*3*). At present, ^{201}Tl scintigraphy is used as a noninvasive approach to evaluating peripheral vascular disease (*2,4–10*), especially the healing potential of an ischemic ulcer of the foot (*7,10*). These studies however, have been performed by planar images, hence, it has not been possible to detect leg muscle perfusion with different blood supplies. Therefore, a quantitative method to evaluate leg muscle perfusion is needed. Thallium-201 single photon emission computed tomography (SPECT) provides a three-dimensional image and has been applied as a significant improvement over planar scintigraphy for the detection and localization of myocardial ischemia (*11,12*). We therefore conducted a study to determine whether quantitative ^{201}Tl SPECT of leg could provide an adequate evaluation of transverse leg perfusion in normal control cases and peripheral arterial disease cases, and, hence, relative blood flow.

Received June 16, 1988; revision accepted Nov. 10, 1988.

For reprints contact: Motoo Oshima, MD, Dept. of Radiology, Nagoya University School of Medicine, Showaku Nagoya, 466, Japan.

MATERIAL AND METHODS

Patients

From October, 1985 through January, 1988, 32 patients with peripheral arterial disease were evaluated for peripheral vascular disease using both stress and redistribution ^{201}Tl leg SPECT study at our Institute. Eleven patients were excluded because they had a history of previous bypass graft operations of leg arteries. Therefore, the population studied included 21 males ranging from 34 to 75 yr old [mean 52 ± 13 yr (s.d.)]. All gave informed consent before participating in the study. In this group, ten patients had arteriosclerosis obliterans (ASO) with intermittent claudication in six cases and ischemic ulcers on toes of the feet in four cases. Eleven had Buerger's disease (thromboangiitis obliterans) (*13,14*) with ulcerations on the toes in ten cases and intermittent claudication in one. Three

of the ten ASO patients also underwent this examination before and after bypass graft operations.

Control Group

Six normal volunteers ranging in age from 23 to 24 yr old (mean 24 yr) with no history of peripheral arterial disease also underwent ^{201}Tl leg SPECT study and served as the normal control group. Informed consent was obtained from all volunteers.

Peripheral Arteriography

All patients underwent contrast peripheral arteriography in both the anterior and lateral views. Contrast peripheral arteriography was performed using the Seldinger technique or direct puncture of the femoral artery and 40 to 60 ml of contrast medium was injected manually. Serial exposures lasting 20 sec were obtained using a long cassette changer. Significant arterial disease was defined if any lumen of main arteries such as aortoiliac, iliac, femoral, popliteal, and leg arteries met one of four occlusive patterns (conical, smoothly tapering, irregularly tapering, or cutoff pattern) (*15*). Arteriographic findings were divided into two groups. The first group had a lesion proximal to the popliteal artery. The second had a lesion distal to the leg arteries. Peripheral angiograms were analyzed by two of us without knowledge of the results of the ^{201}Tl SPECT.

Thallium-201 Leg SPECT Imaging

Data acquisition and processing. A stress test was taken by applying a cuff to the thigh of each patient. Ischemia was achieved by raising the manometric pressure to 50 mmHg above systolic pressure for 3 min (*16*). Immediately upon release of the cuff, 4 mCi of ^{201}Tl in a volume of 4 ml was rapidly injected and flushed with 20 ml of saline. Within 10 min after ^{201}Tl injection SPECT imaging of legs was begun in all cases using a dual-headed digital gamma camera (Toshiba GCA-70A dual-headed digital gamma camera dedicated to a Toshiba GMS-55A minicomputer) with two low-energy, parallel holes, all-purpose collimators, and dedicated minicomputer. Energy discriminators were set at 74 keV with a 35% window and 167 keV with a 25% window. Each camera

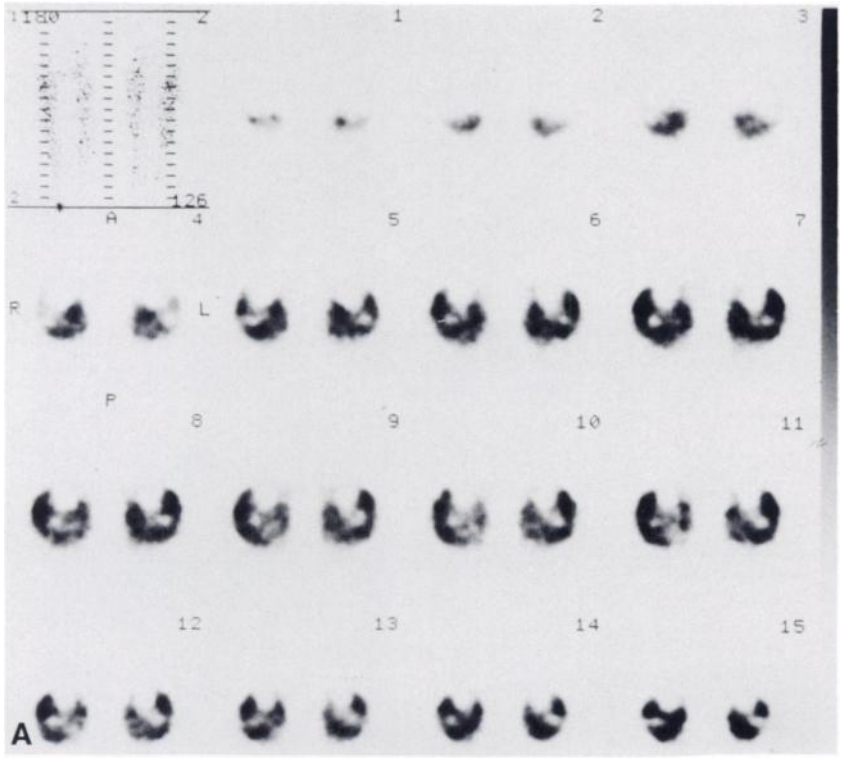

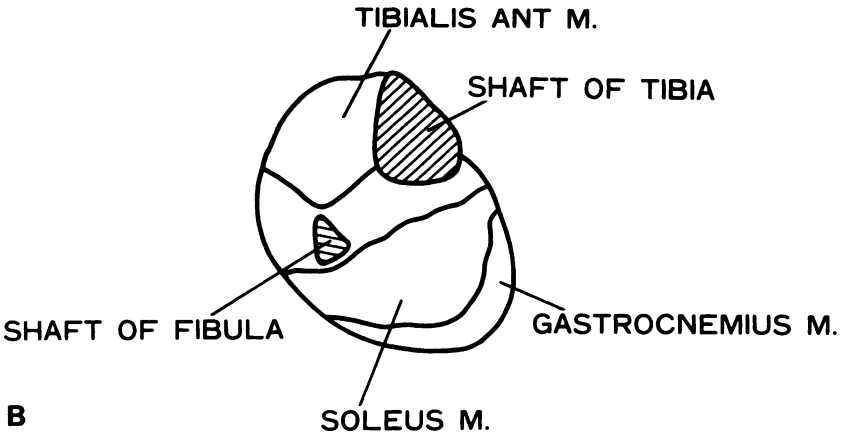

FIGURE 1
Stress ^{201}Tl SPECT image in normal control was shown in (A). SPECT is arranged from knee (No. 1) to the ankle (No. 15). R=right, L=left The anatomic illustration of a transverse image of right lower limb was shown in (B). The anterior defect corresponds to shaft of tibia and the posterior small defect corresponds to shaft of fibula. Tibial anterior muscle is classified to an anterior tibial muscle component, and soleus and gastrocnemius muscle are classified to a posterior tibial muscle component, respectively.

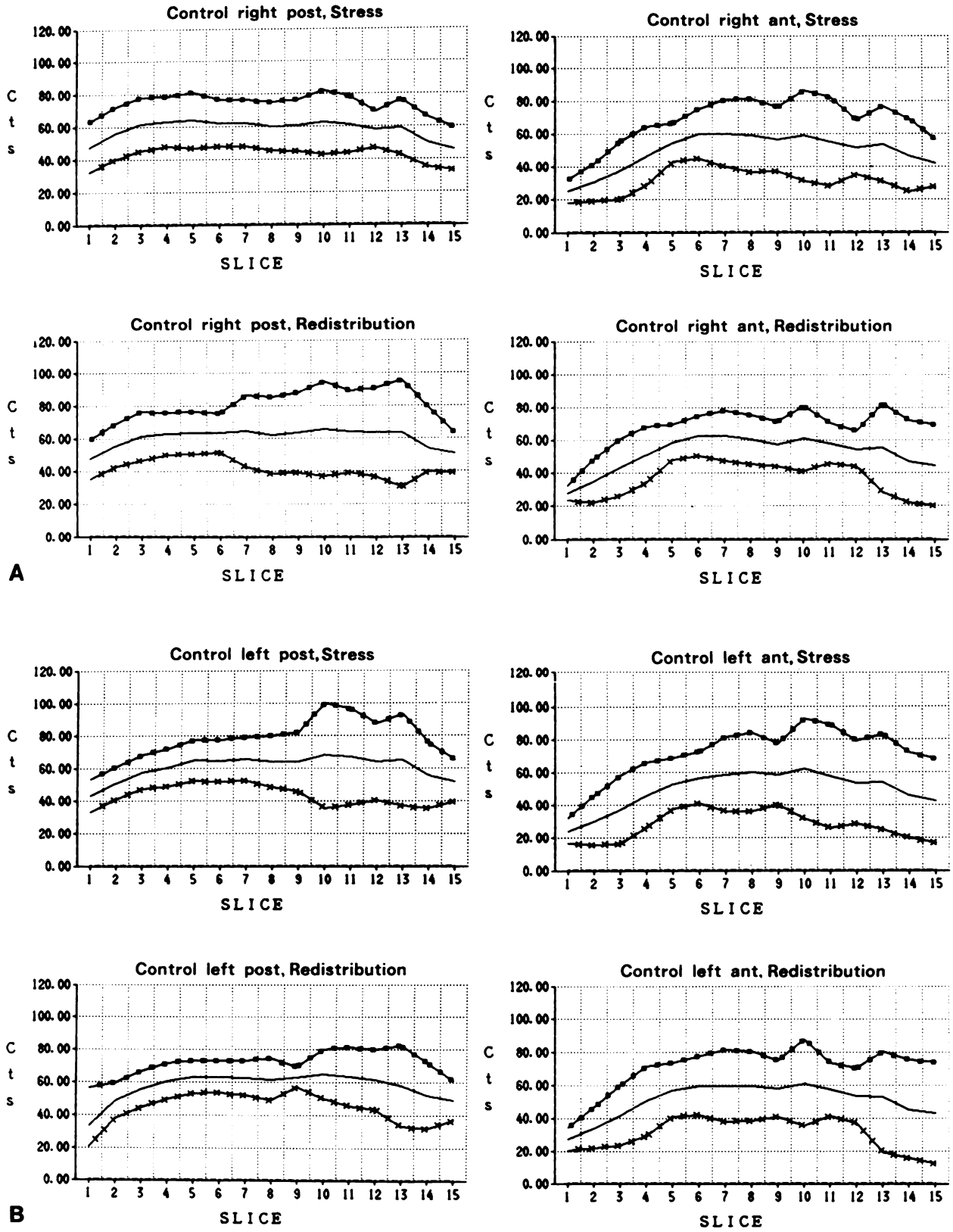

FIGURE 2
Profile curves of controls (mean± 2 s.d.) [Right (A) Left (B)] The profile curve of anterior tibial muscle component showed less activity than posterior tibial muscle component ($p < 0.001$). However, there was no statistical significance between stress and redistribution profile curves in each component. Horizontal axis shows each slice from knee (1) to ankle (15). Longitudinal axis shows a normalized count of each slice (ROI cts/pixels/whole-body cts $\times 10^6$).

took 30 views for 30 sec each rotating around the patient's legs in a 180 arc. All projections were stored in a minicomputer using a 128 × 128, 16-bit matrix. Redistribution imaging was performed 3 hr after injection using the same method. Each data set was reconstructed by filtered backprojection using a Shepp-Logan filter with a cutoff frequency 120% of the Nyquist frequency to reconstruct the transverse axial tomograms encompassing the entire lower legs from knee to ankle. These tomograms were smoothed in depth using a three-point weighted average with weighting factors of 1,2, and 1, respectively, and then magnified by a factor of 1.5 with a 128×128 matrix. From the knee to ankle of both legs, 15 slices were extracted from the transaxial tomograms. Each reconstructed slice was 18.7 mm thick (7 pixels) and was formatted on 8×10 x-ray film to provide the count change between the stress and redistribution studies. All patients had both anterior and posterior planar whole-body images performed following the stress SPECT study using the same dual-headed camera. The table speed was 60 cm/min.

Quantitative analysis. For a quantitative evaluation of ^{201}Tl leg SPECT, each leg was simulated as a spheroid, and the diameter and length of each point was measured patient by patient in advance and the data recorded into a minicomputer. Thus, the border of each leg was decided in each slice. Next, the transverse image of each slice was divided into an anterior tibial and posterior tibial muscle component by delineating a line from the middle of the tibial bone to the fibula. After flagging the right leg, the left leg was flagged by a mirror method. Hence, four regions of interests (ROIs) were flagged. Each ROI was normalized by number of pixels and total whole-body counts as follows:

$$\text{Normalized counts} = \frac{\text{ROI counts/pixels}}{\text{whole-body counts}} \times 10^6.$$

Then, these normalized counts were displayed as "profile" curves from knee to ankle (15 slices). Thus four "profile" curves were obtained from both legs; both the anterior and posterior tibial muscle components. These four profile curves were generated from the stress and redistribution study, respectively. Hence, in total, eight profile curves were obtained from one patient.

Normal limits of profile curve. The profile curves from the group with peripheral vascular disease were compared with those acquired from the six normal volunteers. Their profile curves for stress and redistribution provided reference standards for the quantitative analysis. The curve representing the two s.d.s below the mean was taken as the lower limit of the normal group. Any patient stress profile curve which drops lower than the lower limits of normal stress curve was defined as abnormal. Also, any patient redistribution profile curve which was above the lower limits of the normal redistribution curve was defined as a normal distribution.

Statistics. Student's t-test was used to determine the significance of any difference from the control group.

RESULTS

Normal Thallium-201 Leg SPECT Image

Stress ^{201}Tl leg SPECT image in the normal controls are shown in Figure 1A. In comparison with the anatomy, the transverse SPECT image of the leg revealed that a large anterior defect indicates the tibial bone and a small posterior defect indicates the fibula (Fig. 1B). It is also possible to divide the images into the anterior and posterior tibial muscle components.

Comparison of Thallium-201 SPECT with Planar Image

In 21 patients, stress leg SPECT images were compared with planar whole-body images qualitatively. In ten patients whose planar images showed homogeneous uptakes in anterior and posterior views of both legs, SPECT also showed homogeneous uptakes in both legs with no differences between the distribution of anterior and posterior tibial muscle components. In 11 patients, it was difficult to interpret which component was normal or abnormal when planar images showed inhomogeneous uptakes in one or both legs. However, a distinct uptake was recognized by SPECT in the anterior or posterior tibial muscle components. Additionally, in four patients who had atrophy in one of both legs, SPECT was easier to interpret than the planar images.

Normal Profile Curves

Results of the normal control profile curves (mean ± 2 s.d.) of each component are shown in Figure 2. The activity of the anterior tibial muscle component showed less than that of posterior tibial muscle component toward the knee (No. 1–5) and a widening of the standard deviation was also noted toward ankle (No. 10–15). The normalized activity of the anterior tibial muscle component was significantly less than that of posterior tibial muscle component ($p < 0.001$). However, there was no statistical significance between stress and redistribution counts in each component.

Results of Peripheral Arterial Disease

Results of the correlation between arteriographic findings and leg SPECT in 21 patients (84 components) are shown in Table 1. In 14 components where patients showed insignificant lesions according to arteriography, profile curves were normal in ten cases, and were abnormal in four. In 62 components where patients had significant arteriographically proven lesions, stress profile curves were abnormal in 57 components (92%)

TABLE 1
Correlation Between Arteriographic Findings and Leg SPECT

Arteriographic findings (No. of components)	Leg SPECT (No. of profile curves)		
	Stress		Redistribution
	Abnormal	Normal	Normal
Unknown (N = 8)	6	2	2
Insignificant (N = 14)	4	10	11
Significant (N = 62)			
Proximal lesion (N = 42)	38	4	20
Distal lesion (N = 20)	19	1	8

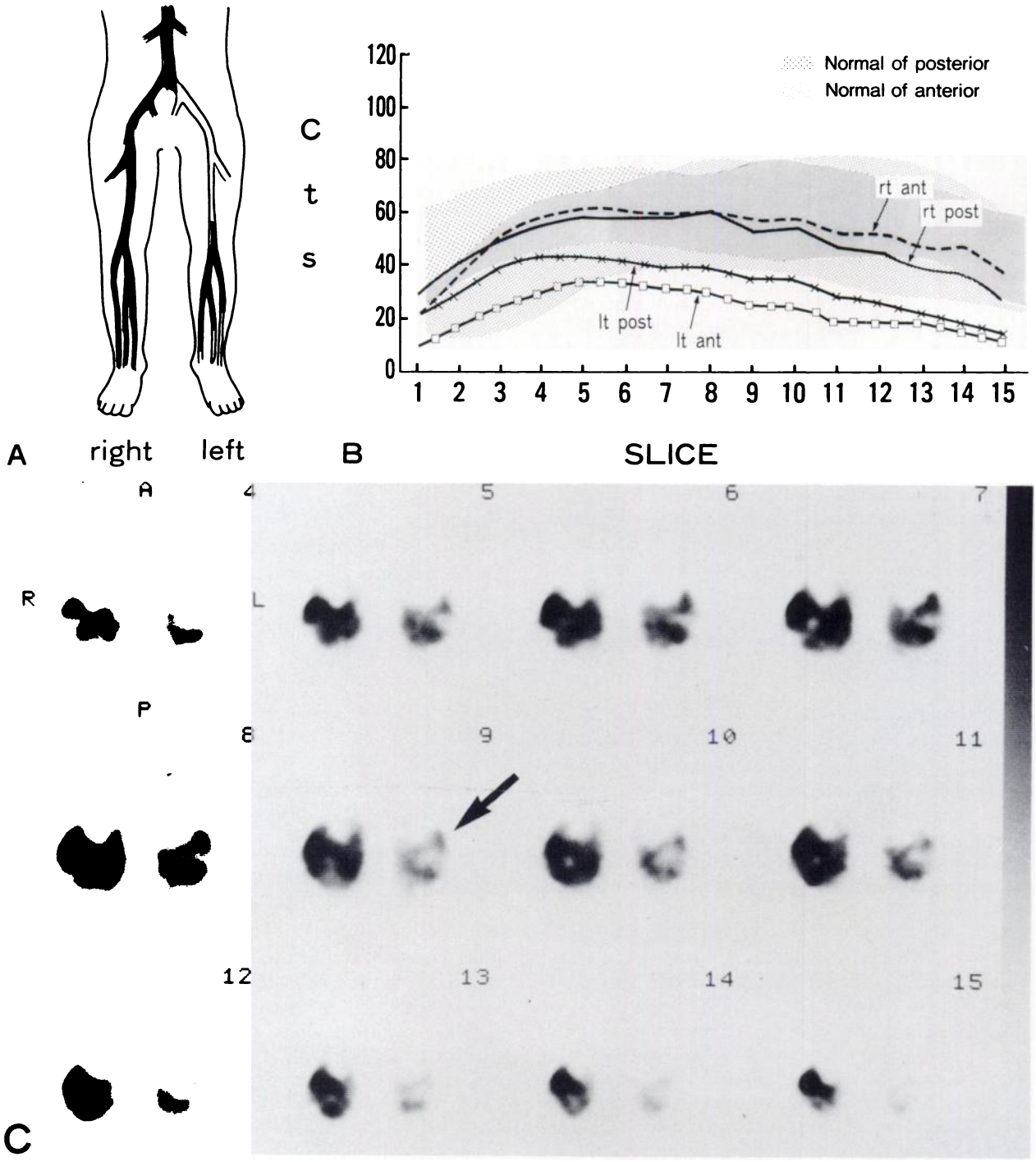

FIGURE 3
A 70-yr-old male with ASO. The patient has an intermittent claudication at left calf for 4 yr. Peripheral arteriography (A) showed an occlusion of left iliac artery and normal in right femoral and leg arteries. Stress profile curves (B) showed abnormal left both anterior and posterior tibial muscle components compared with normal limits (mean−2 s.d.), however, normal in right both components. Redistribution profile curves (not shown) were same as stress curves compared with normal redistribution curves. A decreased uptake was also noted by stress SPECT (C) on left leg (arrow) compared with right leg.

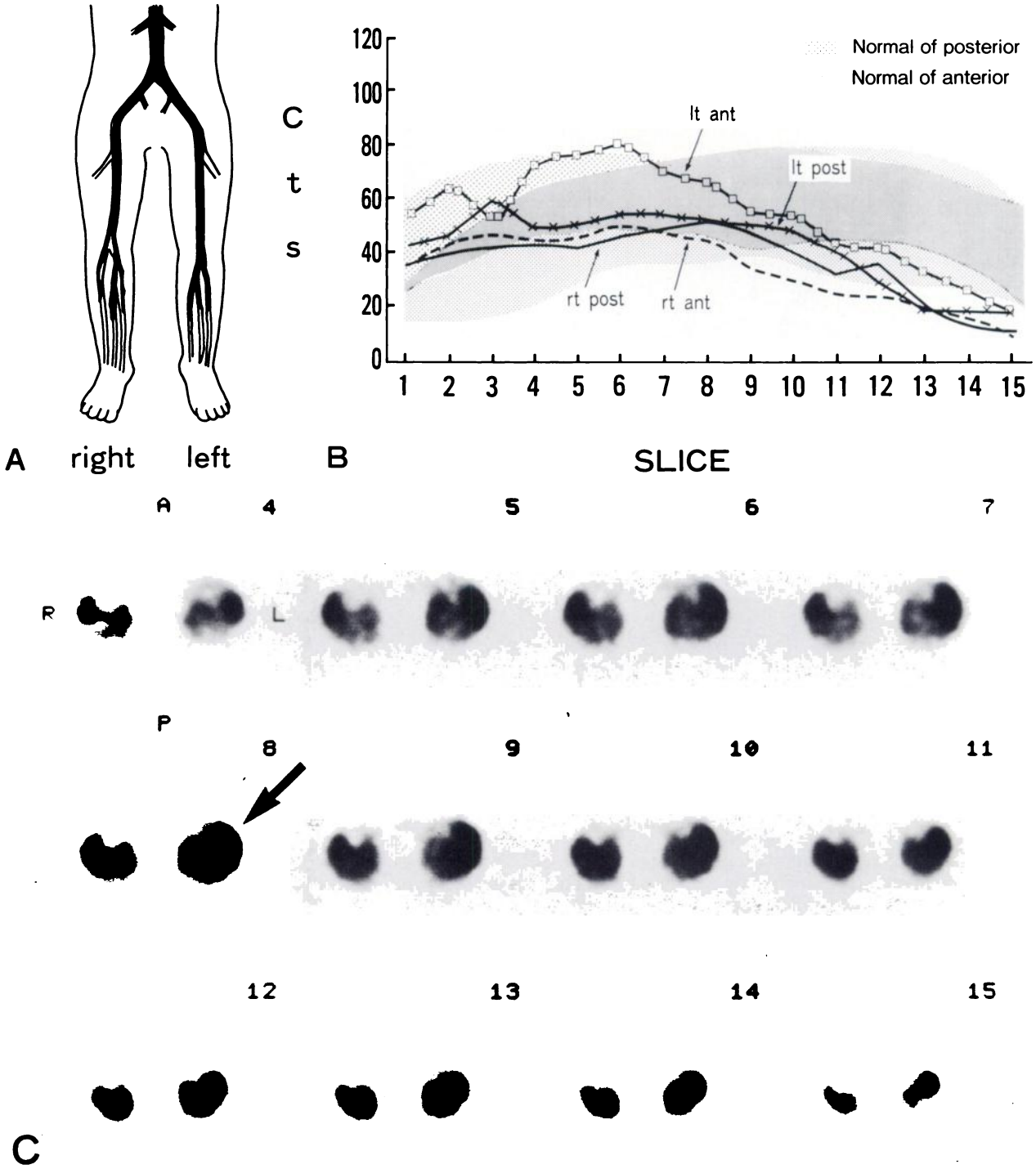

FIGURE 4
A 52-yr-old male with Buerger's disease. The patient has suffered from necrosis of both toes for 10 yr. Peripheral arteriography (A) showed an occlusion on right popliteal artery and also on left leg arteries. Stress profile curves (B) were abnormal compared with normal limits in three components especially right leg and that is consistent with arteriographic findings. However, the left anterior component was normal compared with normal limits. Stress SPECT (C) also revealed that an increased uptake in the left anterior component (arrow) compared with the other three components. Atrophy of the right leg was also noted compared with left leg.

compared to the lower limits of the normal controls (Fig. 3). In the other five components (8%) in four patients, all showed normal profile curves even though there was a significant lesion. Among four patients who showed normal profile curves, two patients had a long-term (4–12 yr) history of symptoms of peripheral vascular disease (Fig. 4) and the other two patients had adequate collaterals in the affected legs. In addition, in 28/62 components, profile curves showed redistribution compared with normal redistribution profile curves. In this group, adequate collateralizations in the leg arteries were recognized in five legs with significant

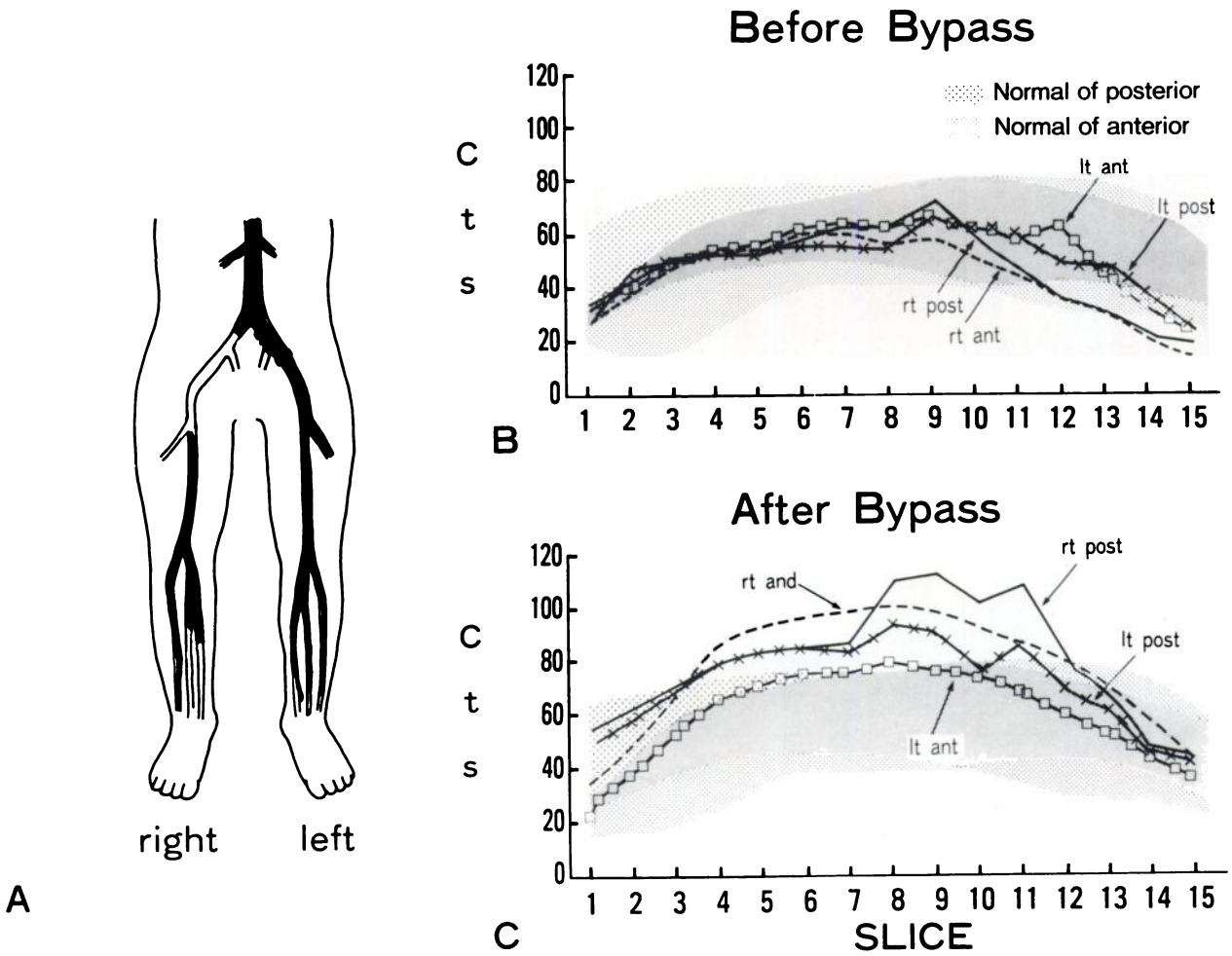

FIGURE 5
A 60-yr-old male with ASO. Peripheral arteriography (A) showed an occlusion of right iliac artery and leg arteries, and an irregularity of left iliac artery as well. Stress profile curves (B) showed below the normal limits in all components except left anterior components towards ankle. After aorto-bifemoral bypass operations, profile curves (C) significantly improved and showed normal as shown below panel.

lesions. In the other 34/62 components, abnormal redistribution curves were noted in collateralizations in two legs.

In all three patients who underwent successful bypass-graftings, the profile curves remarkably improved and showed a normal curve relative to the normal limits (Fig. 5). After the above operations, intermittent claudication was improved in all cases.

Comparison of Findings of Leg Arteries with Profile Curves

Among 21 patients (42 legs), 11 legs (22 components) had lesions of leg arteries and all patients except one had Buerger's disease. Of these, nine legs had significant lesions in both anterior and posterior tibial arteries with or without significant lesions of the peroneal artery. In this group, profile curves in both anterior and posterior components were as follows: same abnormal curves in both components with <3 s.d.s below the mean in six legs; abnormal curves in both components with <3 s.d. and with between 2 to 3 s.d. below the mean in two legs; and normal and abnormal curves in both components in one leg; respectively. In the other two legs, both legs had significant lesions of the posterior tibial arteries and insignificant lesions of the anterior tibial arteries. In this group, one leg showed abnormal profile curves in both components, however, the other leg showed a normal curve in the anterior component and an abnormal curve in the posterior component.

DISCUSSION

In our previous study, we described that the toe study is essential to measure blood flow to the feet in order to evaluate peripheral arterial disease by using first-pass radionuclide arteriography (*17*). However, for the estimation of leg muscle viability or collateral blood supply, a perfusion study such as ^{201}Tl would be more appropriate (*2*). It is commonly accepted that ^{201}Tl is an indicator which distributes proportionally with the myocardial blood flow (*3*). At present, SPECT imaging with ^{201}Tl is used routinely for the diagnosis of ischemic

heart disease because of its improved sensitivity and specificity over planar scintigraphy (*11,12*). The reason is because SPECT with ^{201}Tl can provide a three-dimensional image of the cardiac muscle and exclude the overlapping uptake of the cardiac muscle. For the considerations of bypass graft surgery from femoral or popliteal artery to anterior or posterior tibial artery, it is important to measure local perfusion such as anterior or posterior tibial muscle component, especially in Buerger's disease, since Buerger's disease is mainly localized in the peripheral small vessels (*18*). However, arteriography shows only the morphologic occlusive features and does not reveal the compensatory capacity of the collaterals. In this study, we therefore tried to use ^{201}Tl leg SPECT with dual-headed digital gamma camera, to determine whether it can quantify leg muscle perfusion. It takes 20 min to complete the study and reveals a three-dimensional image of leg muscle. Furthermore, the comparison of the profile curves of each component to control group was more useful in differentiating normal perfusion from abnormal perfusion (Table 1). Whereas ^{201}Tl leg SPECT images would be inferior for spatial resolution in anatomic information to x-ray computed tomography, they reflect local perfusion and enable a transverse image of leg perfusion. Burt et al. also reported on leg perfusion imaging by delayed administration of ^{201}Tl (*2*). They found that muscles supplied by a completely occluded arterial supply had more ^{201}Tl uptake than those supplied normally. However, their study was performed qualitatively by planar image, and the examination was only performed comparing the affected leg to the normal leg in same patient, hence, the increased uptake at the site of occluded area might be found as abnormal if the study was performed quantitatively as shown in our present study. They also corroborated that redistribution did not occur in their qualitative study (*2*). However, our quantitative study revealed that although there was no statistical significance in the control group between stress and redistribution images, redistributions occurred in 28 of 62 components which had significant lesions (Table 1). Those components which showed redistributions were accompanied by many collaterals (five legs) rather than those which did not show redistributions (two legs). Our study showed normal profile curves in 5/62 components (8%) where there was a significant lesion diagnosed arteriographically. It is interesting that 4/5 components with normal curves had proximal lesions. It must be suggested that there would be an adequate blood flow by collaterals to lower legs even in the affected areas. Thus, analysis of ^{201}Tl leg SPECT can provide quantitative information and permit an objective, reproducible test, independent of observed bias in detecting ischemia of leg muscle. Local perfusion was also quantified by this method before and after bypass operations.

REFERENCES

1. Siegel ME, Giargiana FA Jr, White RI Jr, et al. Peripheral vascular perfusion scanning. Correlation with the arteriogram and clinical assessment in the patient with peripheral vascular disease. *Am J Roentgenol* 1975; 125:628–633.
2. Burt RW, Mullinix FM, Schauwecker DS, et al. Leg perfusion evaluated by delayed administration of Tl-201. *Radiology* 1984; 151:219–224.
3. Strauss HW, Harrison K, Pitt B. Thallium-201: noninvasive determination of the regional distribution of cardiac output. *J Nucl Med* 1977; 18:1167–1170.
4. Christenson J, Larson I, Svensson SE, et al. Distribution of intravenously injected thallium-201 in the legs during walking. *Eur J Nucl Med* 1977; 2:85–88.
5. Siegel ME, Siemsen JK. A new noninvasive approach to peripheral vascular disease: thallium-201 leg scans. *Am J Roentgenol* 1978; 131:827–830.
6. Glass EC, DeNardo GL. Abnormal peripheral distribution of thallium-201 due to arteriosclerosis. *Am J Roentgenol* 1978; 131:718–720.
7. Siegel ME, Stewart CA, Wagner W, et al. A new objective criteria for determining, noninvasively, the healing potential of an ischemic ulcer. *J Nucl Med* 1981; 22:187–189.
8. Siegel ME, Stewart CA. Thallium-201 peripheral perfusion scans: feasibility of a single-dose, single day, rest and stress study. *Am J Roentgenol* 1981; 136:1176–1183.
9. Seder JS, Botvinick EH, Rehimtoola SH, et al. Detecting and localizing peripheral arterial disease: assessment of Tl-201 scintigraphy. *Am J Roentgenol* 1981; 137:373–380.
10. Ohta T. Noninvasive technique using thallium-201 for predicting ischaemic ulcer healing of the foot. *Br J Surg* 1985; 72:892–895.
11. Maublant J, Cassagnes J, Le Jeune JJ, et al. A comparison between conventional scintigraphy and emission tomography with thallium-201 in the detection of myocardial infarction: concise communication. *J Nucl Med* 1982; 23:204–208.
12. Starling MR, Dehmer GJ, Lancaster JL, et al. Segmental coronary artery disease: detection by rotating slant-hole collimator tomography and planar thallium-201 myocardial scintigraphy. *Radiology* 1985; 157:231–237.
13. Juergens JL. Thromboangiitis obliterans (Buerger's disease). In: Fairbairn JF II, Juergens JL, Spittel JA Jr, eds. *Peripheral vascular diseases.* 4th ed. Chap. 17. Philadelphia: W.B. Saunders, 1972: 327–349.
14. Shionoya S. What is Buerger's disease? *World J Surg* 1983; 7:544–551.
15. Suzuki S. Arteriography of the extremities with an analysis of the occlusive diseases of the arteries of the lower extremities. *Am J Roentgenol* 1969; 106:400–417.
16. Gerritsen HA, Kazem I, Hasman A, Kuypers PJ. A new approach to the evaluation of peripheral vascular disease using the gamma camera. *Radiology* 1974; 112:115–121.
17. Oshima M, Ijima H, Kohda Y, et al. Peripheral arterial disease diagnosed with high-count-rate radionuclide arteriography. *Radiology* 1984; 152:161–166.
18. Shionoya S, Hirai M, Kawai S, Seko T, Ban I. Pattern of Arterial occlusion in Buerger's disease. *Angiology* 1982; 33:375–384.