
Portal Circulation by Technetium-99m Pertechnetate Per-Rectal Portal Scintigraphy

Susumu Shiomi, Tetsuo Kuroki, Osamu Kurai, Kenzo Kobayashi, Naoko Ikeoka, Takeyuki Monna, and Hironobu Ochi

Third Department of Internal Medicine, Department of Public Health, and Department of Radiology, Osaka City University Medical School, Osaka, Japan

Portal circulation in patients with chronic liver diseases was evaluated by [^{99m}Tc]pertechnetate per-rectal scintigraphy. Technetium-99m pertechnetate (10 mCi) was instilled into the upper rectum, and serial scintigrams were taken. Radioactivity curves for the liver and heart were then recorded sequentially. Through analysis of these curves, the per-rectal portal shunt index (SI) was calculated for six healthy subjects and 228 patients, 59 with chronic hepatitis, seven with idiopathic portal hypertension, six with primary biliary cirrhosis, and 156 with cirrhosis. In the healthy subjects, the SI was 1.9–5.2% (mean 4.1%). In hepatitis, the mean SI was 7.1%, and in cirrhosis, 52.9%. The SI was higher in cirrhotic patients with esophageal varices than in those without ($p < 0.001$), and in cirrhotic patients with encephalopathy than in those without ($p < 0.01$). For some patients with portal hypertension, portal collateral circulation could be depicted, and images of changes in the portal collateral circulation after vascular anastomosis were seen.

J Nucl Med 29:460–465, 1988

In chronic liver disease, collateral circulation may form between the portal vein and the vena cava, depending on the degree of portal hypertension. This change decreases the liver blood flow and may cause hepatic insufficiency or encephalopathy (1). To investigate such abnormalities, various methods to measure the portal circulation have been tried. Portal circulation has been measured noninvasively per rectum with the use of radiopharmaceuticals. It is difficult to demonstrate the portal system in this way, however, so the method is not used widely. Using the method described here, the portal circulation can be seen with technetium-99m (^{99m}Tc) pertechnetate, and a diagnosis of portal hypertension can be made from the images on the basis of the depictions of the liver and heart. We also studied time-activity curves of the liver and heart to examine the usefulness of clinical applications.

PATIENTS AND METHODS

Per-rectal portal scintigraphy was carried out in 59 patients with chronic hepatitis, 156 with cirrhosis of the liver, seven with idiopathic portal hypertension (IPH), six with primary

biliary cirrhosis (PBC), and six persons found to have a healthy liver when examined. Hepatitis, cirrhosis, IPH, and PBC were diagnosed by liver biopsy at the time of laparoscopy. The presence of esophageal varices was confirmed by a barium esophagogram or endoscopy.

The subjects fasted after the evening meal of the day before the test. The rectum was emptied by administration of laxatives. A polyethylene tube (Nelaton's catheter Fr. 18) was inserted deep into the rectum. The tip of the catheter was placed in the upper rectum, 20 cm above the anal region, to avoid absorption via the inferior rectal vein into the systemic circulation in the lower rectum. To generate time-activity curves, a large-field scintillation detector (Technicare-410S, Technicare, Solon, OH) with a low-energy, multipurpose, parallel-hole collimator was used, interfaced to a digital computer (Sopha Simis 4, Baltimore, MD). The collimator was positioned over the patients's abdomen so that the field of view would include the heart, liver, and spleen. Ten millicuries (2 ml) of [^{99m}Tc]pertechnetate, followed by 15 ml of air, was given through the tube. Data were processed by the computer twice every second. For time-activity curves, counts for each 4-sec period (set arbitrarily) were calculated. For the color display, the sum of counts over 0.5-sec periods for 5 min was shown at the end of this time. We called this the summed image.

Calculation of Per-Rectal Portal Shunt Indices

To calculate the percentage of blood that enters the portal system and goes to the heart rather than the liver, which we call the portal shunt index (SI), we first examined the patterns of time-activity curves in our subjects. In pattern I, the curve

Received Mar. 23, 1987; revision accepted Oct. 9, 1987.

For reprints contact: Susumu Shiomi, MD, Third Department of Internal Medicine, Osaka City University Medical School, Asahi-machi 1-5-7, Abeno-ku, Osaka 545, Japan.

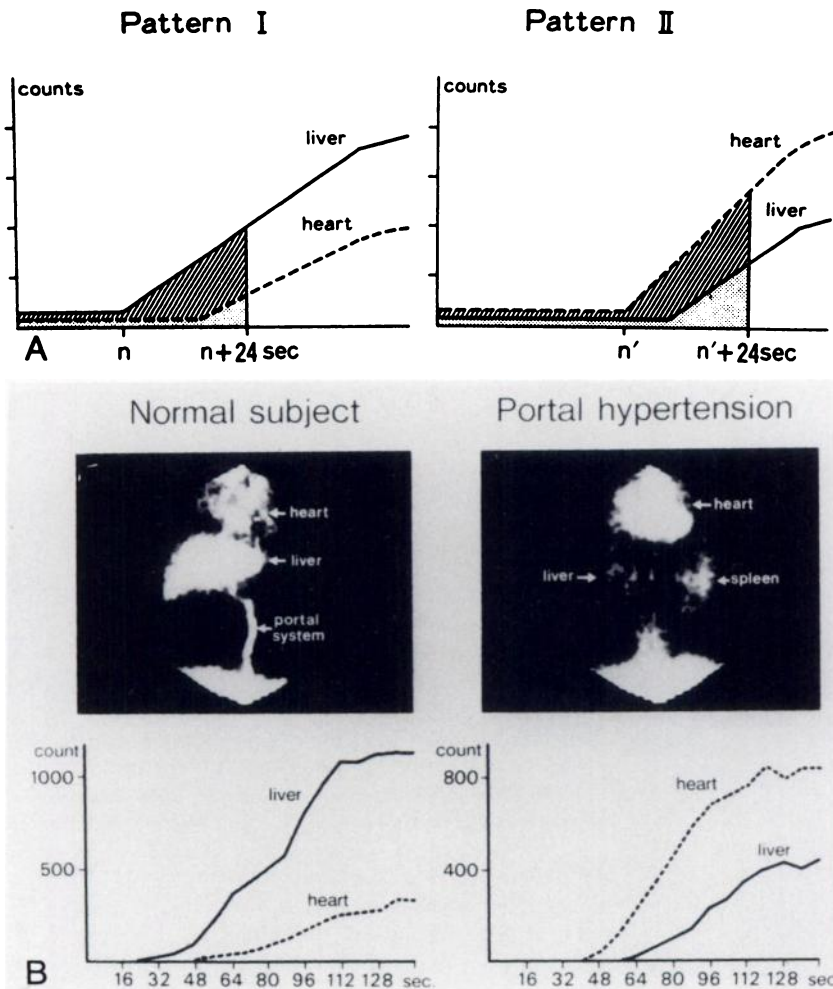


FIGURE 1
A: Shunt index shown in graphic form. Counts are for 4-sec periods. Calculation of the SI for patients with pattern I was by Eq. (1), and that for patients with pattern II was by Eq. (2) (see Methods section). The SI was the triangular area under the heart area divided by the sum of the triangular area under the liver curve and the triangular area under the heart curve, expressed as a percentage. **B:** Per-rectal portal scintigrams in a normal subject and a patient with portal hypertension.

for the liver appeared before that for the heart. In pattern II, the order of appearance was reversed (Fig. 1A). The summed images could readily be classified as patterns I or II. In pattern I, the liver and portal vein were clear and the heart was not. Pattern II showed the opposite; heart was clear, the portal vein and liver were not. Typical summed images and time-activity curves for subjects with patterns I and II are shown in Figure 1B. All subjects could be classified as having one or the other pattern. In the six healthy subjects, the time-activity curve for the liver area had started to rise above the background when a count was made at 20 sec after the radionuclide (RN) administration, so the background up to 20 sec was subtracted. The curve for the heart area appeared a mean of 22.0 ± 3.8 sec after that in the liver area; that is, circulation from the liver to the heart took ~ 22 sec in the healthy subjects. Thus, the RN that reached the heart earlier probably passed through a shunt. Measurements were made for 4-sec periods, so we decided to use data obtained from the beginning of the rise of the liver curve for 24 sec to calculate the SI. Equation (1) was used to calculate the SI for subjects with pattern I curves and Eq. (2) to calculate pattern II, as follows:

$$\text{S.I.} = \frac{\sum_{i=0}^{(n+24)/4} \chi_i(H)}{\sum_{i=0}^{(n+24)/4} \chi_i(L) + \sum_{i=0}^{(n+24)/4} \chi_i(H)} \times 100(\%) \quad (1)$$

$$\text{S.I.} = \frac{\sum_{i=0}^{(n'+24)/4} \chi_i(H)}{\sum_{i=0}^{(n'+24)/4} \chi_i(L) + \sum_{i=0}^{(n'+24)/4} \chi_i(H)} \times 100(\%) \quad (2)$$

where n is the time at which the radionuclide appeared in the area of the liver, n' is the time at which it appeared in the area of the heart, $\chi_i(L)$ is the count per 4 sec over the area of the liver, and $\chi_i(H)$ is the count per 4 sec over the area of the heart.

All results were expressed as means \pm s.d., and Student's t -test was used for the statistical analysis.

RESULTS

The patterns seen in each group of subjects are specified in Table 1. The healthy subjects and the patients with hepatitis all had pattern I. Patients with IPH all had pattern II, and the patients with cirrhosis were not all of one pattern.

The mean SI was higher for disorders that were more severe, increasing in the order of chronic persistent hepatitis, chronic aggressive hepatitis, and cirrhosis. The mean SI in cirrhosis was significantly higher than the healthy subjects or patients with CPH and CAH.

TABLE 1
Patterns of Findings from Per-Rectal Scintigrams

	Normal	CPH	CAH	LC	IPH	PBC
Pattern I	6/6 (100%)	29/29 (100%)	30/30 (100%)	54/156 (35%)	0/7 (0%)	2/6 (33%)
Pattern II	0/6 (0%)	0/29 (0%)	0/30 (0%)	102/156 (65%)	7/7 (100%)	4/6 (67%)

Healthy subjects had a mean SI of 4.1% (range 1.9–5.2%).

The SI was significantly higher in patients with cirrhosis of the liver with esophageal varices than in such patients without varices ($p < 0.001$), and in patients with cirrhosis of the liver and with encephalopathy than in such patients without encephalopathy ($p < 0.01$; Fig. 2).

For a total of 28 patients (20 with cirrhosis of the liver, six with IPH, and two with PBC), the portal pressure was measured by percutaneous transhepatic portography or during surgery. There was correlation between the SI and portal pressure ($r = 0.694$; Fig. 3).

CASE REPORTS

Imaging of Collateral Circulation

Case 1. A 60-yr-old woman was admitted to this hospital for sclerotherapy treatment of esophageal varices. On admission, an endoscopic examination showed esophageal varices (Fig. 4A). In the summed image from per-rectal portal scintigraphy, the RN seemed to reach the heart through collateral circulation after entering the portal system (Fig. 4B). The SI was 72%.

Case 2. A 38-yr-old woman was admitted to this hospital on suspicion of PBC. On admission, an endoscopic examination showed no esophageal varices. However, percutaneous transhepatic portography showed anastomosis of the superior mesenteric vein and ovarian vein (Fig. 5A). In the summed image, the RN was dense at a place corresponding to the shunt site seen in Figure 5B. The SI was 73%.

Case 3. A 49-yr-old woman had been diagnosed as having Eck syndrome 20 years earlier. On admission, the portal vein was examined by use of the venous phase of radiography of the superior mesenteric artery. The x-ray film showed the

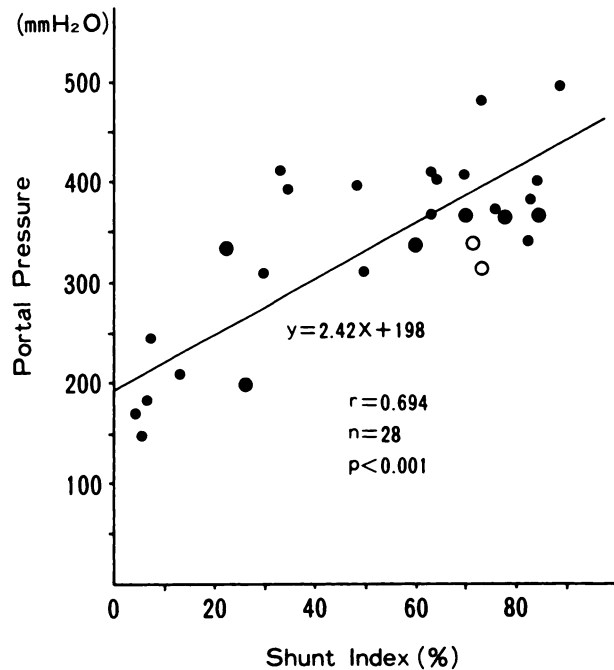


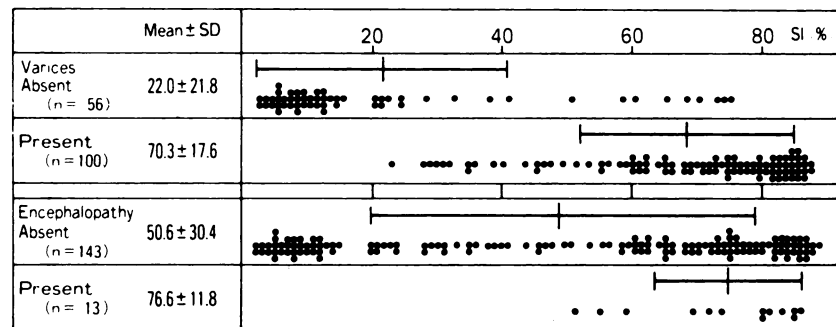
FIGURE 3
Correlation between shunt indices and portal pressure. (●) Cirrhosis of the liver; (○) idiopathic portal hypertension; (◻) primary biliary cirrhosis.

inferior vena cava as well as the portal vein. The anastomotic orifice of the portal vein and inferior vena cava was still present (Fig. 6). In the summed image, the RN seemed to reach the heart through the inferior vena cava from the anastomotic orifice after flowing into the portal system (Fig. 7). The SI was 75%.

DISCUSSION

Reichman et al. (2) used per-splenic injection of iodine-131- (^{131}I) labeled human serum albumin to measure portal circulation, and Nakamura et al. (3) calculated the blood flow through extra-hepatic shunts by use of the same labeled compound. Kashiwagi et al. (4) studied the portal circulation in detail using xenon-133 (^{133}Xe). The advantage of the per-splenic approach is that the exact quantity of RN needed can be injected

FIGURE 2
Relationships of per-rectal portal shunt indices, esophageal varices, and encephalopathy. The shunt index was significantly higher in the cirrhotic patients with esophageal varices than in the patients without ($p < 0.001$). The shunt indices were higher in the cirrhotic patients with encephalopathy than in the patients without ($p < 0.01$).



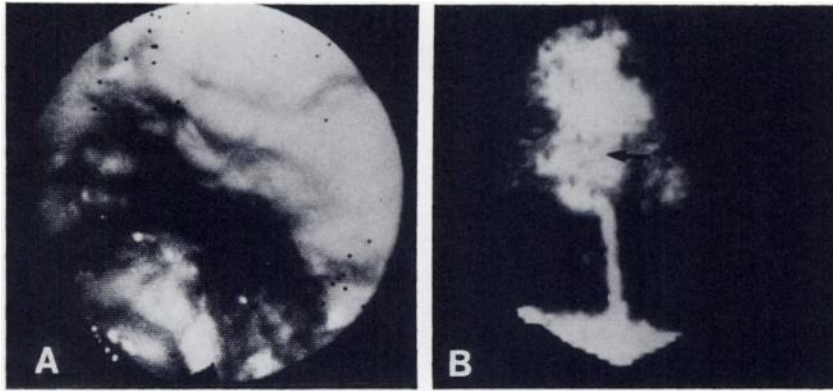


FIGURE 4
 A: Endoscopy of esophageal varices.
 B: Per-rectal portal scintigram for Case 1. Arrow, esophageal varices.

into the splenic and portal vein through the spleen. Use of the method is restricted because of the need for spleen puncture.

The per-rectal portal approach is a noninvasive way to measure the portal circulation. Newman and Cohen (5) injected ether into the upper part of the rectum and regarded the time required to smell ether in the air exhaled by the subject as the gross portal circulation time. Castell et al. (6) injection ^{133}Xe into the upper part of the rectum, and Steinberg et al. (7) used ^{131}I sodium iodide in studies of the portal circulation by use of time-activity curves for the liver and heart after the injection. Tonami et al. (8) used thallium-201, and Yen et al. (9) used iodine-123 iodoamphetamine. The use of these methods is limited by the exposure dose and the cost, so portal circulation cannot always be made visible, and the images of portal circulation are sometimes difficult to analyze.

We have used $^{99\text{m}}\text{Tc}$ pertechnetate, which has a short half-life, making it possible to use a large dose of indicator (10,11). Approximately 20% of a dose of 10 mCi of pertechnetate was absorbed through the blood vessel walls within 5 min of being administered per rectum and entered the blood (data not shown), so measurements of liver curves, etc., were possible with this dose. With this method, portal circulation can be demonstrated noninvasively, and portal hypertension can be diagnosed from the images by use of the pattern

of depiction of the portal vein, liver, and heart. Our healthy subjects all had pattern I, which allowed the portal circulation to be shown. The inferior mesenteric vein, portal vein, and heart were seen, in this order, soon after the injection of $^{99\text{m}}\text{Tc}$ pertechnetate into the upper part of the rectum, so the RN in the rectum probably circulated in the healthy subjects as follows: superior rectal vein \rightarrow inferior mesenteric vein \rightarrow portal vein \rightarrow liver \rightarrow heart. Pattern I was found in all 29 patients with chronic persistent hepatitis and in all 30 patients with chronic aggressive hepatitis. That is, the circulation in hepatitis was through the same pathway as in the healthy subjects. In 54 of the 156 patients (35%) with cirrhosis, pattern I was seen, and in the other 102 patients (65%), pattern II. The pathway of RN circulation in pattern II usually seemed to be as follows: superior rectal vein \rightarrow middle/inferior rectal vein (or a collateral at the periphery of the inferior mesenteric vein) \rightarrow inferior vena cava \rightarrow heart \rightarrow aortic system \rightarrow liver. There were exceptions, of which Case 1 was typical. In these patients, the portal system was demonstrated, although the pattern was that of II. The RN circulated as follows: superior rectal vein \rightarrow inferior mesenteric vein \rightarrow portal vein (visible in the images), and apparently through the portal collaterals to the heart. For this reason, it was possible to depict what seemed to be portal collateral circulation including esophageal varices in the images. It was possible to show

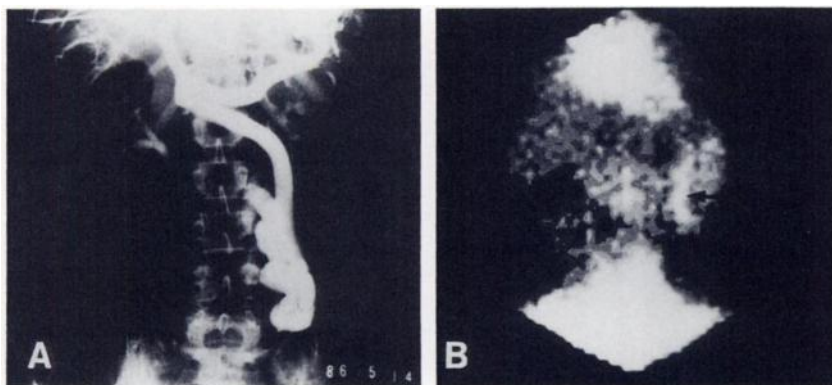


FIGURE 5
 A: Percutaneous transhepatic portogram from Case 2. A collateral is seen between the superior mesenteric and ovarian veins. B: Per-rectal portal scintigram from Case 2. Arrow, collateral between the superior mesenteric and ovarian veins.

culatation were found more easily by our method than by the per-splenic approach, which emphasizes the portal trunk more than the inferior mesenteric vein.

The SI calculated by this method reflected portal hypertension because these indices were correlated with the portal pressure and were significantly higher in patients with esophageal varices and hepatic encephalopathy than in the patients without. This method can be used to examine the portal circulation noninvasively and to express the degree of any abnormalities quantitatively. The method should be useful for the observation of the course of liver diseases because of its simplicity.

ACKNOWLEDGMENTS

The authors thank Yoshihiro Shimonishi and Masahiro Omura for technical assistance. This study was supported in part by a Grant-in-Aid for research into abnormalities in portal blood flow from the Ministry of Health and Welfare, Japan.

REFERENCES

1. Sherlock S, Summerskill WHJ, White LP, et al. Portal-systemic encephalopathy: neurological complications of liver disease. *Lancet* 1954; 267:453-457.
2. Reichman S, Davis WD, Storaasli JP, et al. Measurement of hepatic blood flow by indicator dilution techniques. *J Clin Invest* 1958; 37:1848-1856.
3. Nakamura T, Nakamura S, Kaneko T, et al. Measurement of extrahepatic shunted blood flow in liver cirrhosis. *J Lab Clin Med* 1962; 60:889-901.
4. Kashiwagi T, Kimura K, Suematsu T, et al. Dynamic studies on portal haemodynamics by scintiphotosplenopography: flow patterns of portal circulation. *Gut* 1980; 21:57-62.
5. Newman HF, Cohen IB. Estimation of the portal circulation time in man. *J Lab Clin Med* 1949; 34:674-676.
6. Castell DI, Grace ND, Wennar MH, et al. Evaluation of portal circulation in hepatic cirrhosis: a new method using xenon-133. *Gastroenterology* 1969; 57:533-541.
7. Steinberg M, Marner I, Rasmussen JW. Hepatography patterns following rectal administration of radioiodine as seen in chronic liver disease and other liver disorders. *Scand J Gastroenterol* 1974; 9:73-79.
8. Tonami N, Nakajima K, Hisada K, et al. A noninvasive method for evaluating portal circulation by administration of Tl-201 per rectum. *J Nucl Med* 1982; 23:965-972.
9. Yen C-K, Pollycove M, Crass R, et al. Portasystemic shunt fraction quantification with colonic iodine-123 iodoamphetamine. *J Nucl Med* 1986; 27:1321-1326.
10. Kuroki T, Minowa T, Kawa M, et al. Evaluation of per-rectal portal scintigraphy in hepatic cirrhosis. *Acta Hepatologica Japonica* 1978; 19:669-683.
11. Minowa T. Per-rectal portal scintigraphy for the evaluation of portal circulation in patients with chronic liver diseases. *J Osaka City Med Center* 1983; 32:51-69.
12. Takashi M, Takayasu K, Koen H, et al. Percutaneous transhepatic portography. VI. Extra-hepatic portasystemic shunt and its clinical significance in portal hypertension. *Acta Hepatol Jpn* 1980; 21:857-865.
13. Turner MD, Sherlock S, Steiner RE. Splenic venography and intrasplenic pressure measurement in the clinical investigation of the portal venous system. *Am J Med* 1957; 23:846-859.