

---

# Accuracy of Dual Photon Absorptiometry in Excised Femurs

Juliana Erman and Susan M. Ott

*Departments of Medicine and Radiology, School of Medicine, University of Washington, Seattle, Washington*

We investigated the accuracy of assessment of bone mineral content (BMC) by dual photon absorptiometry (DPA). Measurements were compared between BMC and ashed weight using two related scanners. The BMC in different locations of the femur was determined. Twelve cadaver femurs were cleaned of all soft tissue, divided into four parts (head, neck, trochanteric region, and shaft), and measured for BMC in an ethanol/water solution. The bones were then ashed and weighed. Volumetric density was also determined. The correlation coefficient between ash weight and BMC was 0.99 with an s.e.e. of 0.51 g and relative error of 4.8%. Similar correlations were seen within each region. The correlation between the machines was 0.99. Differences in volumetric density were found, with the density of the shaft greater than other regions, and the neck greater than the head or trochanteric regions.

**J Nucl Med 29:1853-1855, 1988**

---

In order to carefully study the pathophysiology of osteoporosis or other bone disease, accurate methods of assessing bone mass must be used. In addition to standard roentgenograms, the newer methods of measuring bone mass include single and dual photon absorptiometry and quantitated computed tomography (1,2). With the dual energy imaging techniques, the influence of soft tissue is corrected and mineral density can be selectively measured, thus reducing one possible source of error (3). An additional source of error which has been recognized is the variation between scanners (4). In this study, accuracy in vitro of dual photon absorptiometry (DPA) is considered by comparing bone mineral content (BMC) determined by DPA to an independent measure of bone mass, the ash weight. Two related scanners were used; one was a prototype machine for the second, a commercial scanner.

In postmenopausal osteoporosis, fracture of the hip is the most serious clinical consequence and hence, direct measurement of the femur is being done. Some studies show a higher prevalence of trochanteric fractures, others of cervical fractures through the neck (5, 6). We therefore quantitated bone mass of excised femurs. Since the true volumetric density may vary between the head, neck, trochanteric region, and shaft,

each area was measured separately. In addition, we observed that femoral heads contained high amounts of fat, which could influence accuracy.

## MATERIALS AND METHODS

Twelve femurs were removed from cadavers; right and left femurs were obtained from three females and three males. The bones were cleaned of all attached soft tissue and were cut with a bone saw into four parts. The neck was sectioned from the head and also along an oblique line between the most superior points of the greater and lesser trochanters. This provided head and neck pieces. The trochanteric region was defined by a transverse cut just distal to the lesser trochanter. A section of the shaft was also retained by a transverse cut in the proximal fifth of the shaft producing a section ~4 cm long.

The sections of femur were scanned on two scanners. The first was an Ohio-Nuclear Scanner which was modified in house, according to principals described previously (7,8). The second was a Nuclear Data model 2100 scanner, which used software developed for the first machine. A solution of ethanol and water was mixed at a 2:1 ratio; water was added until the solution gave the same density as seen for soft tissue. The sample was then placed in 19 cm of the solution and scanned with a pixel size of 2 × 2 mm. The bone was scanned within a rectangular area of interest that included the entire piece of bone. One scan was made of each piece at a speed of 4 mm/s with a 6-mm collimator. The areas scanned ranged from 30-70 cm<sup>2</sup>. Since the sections had irregular shapes, only the mineral content was measured.

---

Received Dec. 1, 1987; revision accepted June 27, 1988.

For reprints contact: Susan M. Ott, MD, Nuclear Medicine, RC-70, University of Washington, Seattle, WA 98195.

**TABLE 1**  
Measurements in Excised Femurs

	BMC (g)	Ash weight (g)	s.e.e. (g)	%	Volumetric density (g/cm <sup>3</sup> )*
Heads	8.8 ± 3.7	8.9 ± 3.1	0.42	4.8	0.194 ± 0.042
Necks	8.3 ± 2.4	8.0 ± 2.2	0.42	5.0	0.209 ± 0.033
Trochanteric Regions	14.6 ± 3.9	14.3 ± 3.3	0.51	3.5	0.195 ± 0.039
Shafts	10.8 ± 3.0	10.2 ± 2.6	0.27	2.5	0.360 ± 0.074

BMC = Bone mineral content by dual-photon absorptiometry. Measurements are mean ± s.d.; s.e.e. = standard error of estimate for correlation between BMC and ash weight; % is relative error. For each region, n = 12 and the correlation coefficient was 0.99.

\* Necks > heads by paired t-test, p = 0.015, or trochanteric regions, p = 0.03; Shafts > other regions, p < 0.001.

Samples were then measured for volume by displacement of water in a graduated cylinder. They were then soaked in a mixed ether solution (50% ethyl, 50% petroleum) for 24 hr to remove excess fat. Samples were ashed in a muffle furnace at 600°C for 24 hr. Ash weight was measured after cooling in the furnace and density of bone mineral calculated.

Accuracy of measured BMC was determined by linear regression against ash weight. Differences in BMC between the various regions were evaluated by paired t-tests.

## RESULTS

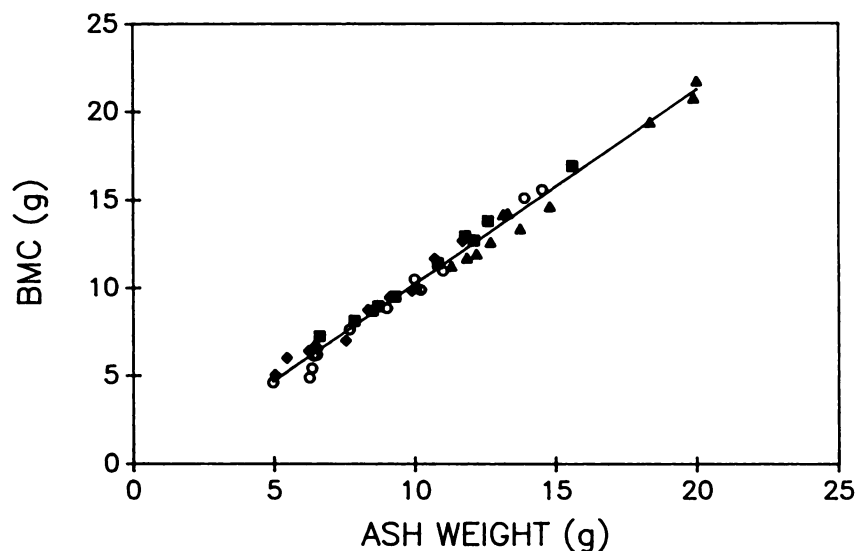
Figure 1 shows the correlation between BMC determined by the first scanner and ash weight. The correlation coefficient was 0.99, with a slope of 1.10, standard error of estimate (s.e.e.) of 0.512 g, and relative error of 4.8%. Similar correlation was seen with the second scanner (r = 0.99, s.e.e. = 0.439 g, relative error 4.0%). The correlation between scanners was also high (r = 0.99, s.e.e. = 0.35 g).

Table 1 shows the results when analyzed according to the region of femur scanned. The correlation coefficients were 0.99 in each region, with errors between 2.5% and 5%. The volumetric density of the neck regions was significantly higher than the femoral heads

or trochanteric regions, and the shafts were more dense than the other regions. In individual femurs, the density of the neck was greater than the head in 11/12 cases and greater than the trochanteric region in 10/12 cases.

## DISCUSSION

In this study of the accuracy in vitro of DPA, a good correlation between BMC as measured by DPA and by ashed weight was found. Previous reports comparing DPA measurements with ash weights of vertebral samples have shown correlation coefficients > 0.98, with s.e.e. of 3–5% (8–11). A study of excised femoral necks showed that DPA correlated well with SPA, with an error of 3.7% (9). The results of this study confirm those of a previous comparison between DPA of the femur and the amount of hydroxyapatite as measured by ashing sections of the femur, where the correlation coefficients were 0.992 for the femoral neck and 0.996 for the shaft (12). The relative error of the measurements in our study was ~5%. The DPA technique is much more accurate than examination of a standard roentgenogram, which may require a 30% change in BMC before demineralization is detected (13).



**FIGURE 1**  
Bone mineral content by dual photon absorptiometry plotted against ash weight. For all samples, r = 0.99, s.e.e. = 0.512, with relative error of 4.8%. Circles are heads, diamonds are necks, triangles are trochanteric regions, and squares are shafts.

Reliability between similar scanners was also supported by our data. Long-term inter-scanner reliability may be partially dependent on energy levels of radioactive sources and on the techniques of scanning used. This problem was not addressed in the current study. We also did not address the error from measuring bone in vitro. Previous authors have shown that in situ measurements of the spine correlate well with measurements of the excised samples, but this does represent an additional error (9,11,14).

The percentage of cortical and trabecular bone differs throughout the femur with a high percentage of trabecular bone in the head, neck, and trochanteric regions and a high percentage of cortical bone in the shaft (1, 12). The rate of decline may differ between cortical and trabecular bone (15), which may lead to different patterns of osteoporosis. Thus, measurements of both cortical and trabecular areas are important for understanding osteoporosis. This study showed that DPA was accurate for both types of bone. DPA in vivo is limited in its imaging capacities by the anatomy of the hip; the head cannot be measured due to overlap of the acetabulum. Our findings of the difference in density of the head and neck imply that direct assessment of the head cannot be made by DPA of the neck. Finally, the femoral head has a high marrow fat content but the DPA was still accurate. This agrees with studies that show that marrow fat content of vertebral bodies does not interfere with accuracy of DPA as much as with single-energy quantitative computed tomography (16).

## REFERENCES

1. Wahner HW, Dunn WL, Riggs BL. Assessment of bone mineral. Part 2. *J Nucl Med* 1984; 25:1241-1253.
2. Health and Public Policy Committee, American College of Physicians. Radiological methods to evaluate bone mineral content. *Ann Intern Med* 1984; 100:908-911.
3. Kalender WA, Perman WH, Vetter JR, et al. Evaluation of a prototype dual energy CT apparatus. *Med Phys* 1986; 12:334-339.
4. Ott SM. Should women get screening bone mass measurements? *Ann Intern Med* 1986; 104:874-876.
5. Lizaur-Utrilla A, Orts AP, del Campo S, et al. Epidemiology of trochanteric fractures of the femur in Alicante, Spain, 1974-1982. *Clin Orthop Rel Res* 1987; 218:24-31.
6. Holmberg S, Thorngren K. Statistical analysis of femoral neck fractures based on 3053 cases. *Clin Orthop Rel Res* 1987; 218:32-41.
7. Ott SM, Kilcoyne RF, Chesnut CH. Longitudinal changes in bone mass after one year as measured by different techniques in patients with osteoporosis. *Calcif Tissue Int* 1986; 39:133-138.
8. Dunn WL, Wahner HW, Riggs BL. Measurement of bone mineral content in human vertebrae and hip by dual photon absorptiometry. *Radiology* 1980; 136:485-487.
9. Wahner HW, Dunn WL, Mazess RB. Dual photon Gd-153 absorptiometry of bone. *Radiology* 1985; 156:203-206.
10. Wilson CR, Madsen M. Dichromatic absorptiometry of vertebral bone mineral content. *Invest Radiol* 1977; 12:180-184.
11. Gotfredsen A, Podenphant J, Norgaard H, et al. Accuracy of lumbar spine bone mineral content by dual photon absorptiometry. *J Nucl Med* 1988; 29:248-254.
12. Bohr H, Schaadt O. Bone mineral content of the femoral neck and shaft: relation between cortical and trabecular bone. *Calcif Tissue Int* 1985; 37:340-344.
13. Lachman E. Osteoporosis: the potentialities and limitations of its roentgenologic diagnosis. *Am J Roent* 1955; 74:712-715.
14. Roos BO, Hansson TH, Skoldborn H. Dual Photon absorptiometry in lumbar vertebrae. *Acta Radiol Oncol* 1980; 19:111-114.
15. Riggs BL, Wahner HW, Seeman E, et al. Changes in bone mineral density of the proximal femur and spine with aging. *J Clin Invest* 1982; 70:716-723.
16. Laval-Jeantet AM, Roger B, Bergot C, et al. Influence of vertebral fat content on quantitative CT density. *Radiology* 1986; 159:463-466.