
Pentavalent [^{99m}Tc]DMSA, [¹³¹I]MIBG, and [^{99m}Tc]MDP—An Evaluation of Three Imaging Techniques in Patients with Medullary Carcinoma of the Thyroid

Susan E.M. Clarke, Colin R. Lazarus, Philip Wraight, Charles Sampson, and Michael N. Maisey

Department of Nuclear Medicine, Guy's Hospital, London; and Department of Nuclear Medicine, Addenbrooke's Hospital, Cambridge, England

Nine patients with histologically proven medullary carcinoma of the thyroid (MCT) were imaged using pentavalent [^{99m}Tc]dimercaptosuccinic acid [(V)DMSA], [¹³¹I]metaiodobenzylguanidine (MIBG) and [^{99m}Tc]methylene diphosphonate (MDP). Technetium-99m (V)DMSA demonstrated most of the tumor sites in eight patients with proven metastases, with an overall sensitivity of 95% in lesion detection. Iodine-131 MIBG showed definite uptake in some of the tumor sites in three of the nine patients imaged, with equivocal uptake seen in a further one patient, with sensitivity of only 11% for lesion detection. Technetium-99m MDP demonstrated bony metastases only, in four of the patients imaged yielding a sensitivity of 61%. Technetium-99m (V)DMSA has been demonstrated in this study to be a useful imaging agent in patients with MCT, showing uptake in significantly more lesions and with better imaging qualities than [¹³¹I]MIBG, and with the ability to detect soft tissue as well as bony metastases.

J Nucl Med 29:33–38, 1988

Patients with medullary carcinoma of the thyroid (MCT) have been imaged using a variety of radionuclide techniques. Primary tumors have been identified as cold areas on technetium-99m (^{99m}Tc) pertechnetate thyroid scans, with the classic pattern of bilateral nonfunctioning nodules (1). Bony metastases and some extraosseous metastases have been visualized using [^{99m}Tc]methylene diphosphonate (MDP) (2,3), and liver metastases have been identified using [^{99m}Tc]colloid (2). Tumor-seeking agents have also been used in MCT patients, with variable success. Thallium-201 chloride has been shown to accumulate in thyroid tumors of various histologic types (4) including MCT, while gallium-67 citrate does not appear to be taken up by MCT tumor (5). Two new radiopharmaceuticals have been developed recently, with reported uptake in patients with MCT. Accumulation of iodine-131 metaiodobenzylguanidine (MIBG), developed as an agent for imaging pheochromocytomata (6), has been dem-

onstrated in some patients with primary and metastatic MCT (7–10), and pentavalent technetium-99m dimercaptosuccinic acid ([^{99m}Tc](V)DMSA) has been shown to accumulate in a variety of head and neck tumors, including MCT (11,12).

In this study, we have therefore evaluated the uptake of [^{99m}Tc](V)DMSA, [¹³¹I]MIBG, and [^{99m}Tc]MDP in eight patients with MCT, and compared the uptake of these agents at sites of known tumor identified by CAT scanning, clinical examination, and surgery.

MATERIALS AND METHODS

Nine patients were studied with a histologic diagnosis of MCT and persistently elevated calcitonin levels. Eight of these patients had metastases visualized on CAT scanning, and the remaining one patient had no evidence of recurrent tumor, including negative radionuclide liver scan, chest x-ray, and CAT scan, despite persistent elevation of calcitonin following the removal of a primary tumor (Table 1).

All patients in the study had an initial whole-body bone scan performed using 15 mCi (550 MBq) [^{99m}Tc]MDP and a standard imaging protocol using a large field-of-view gamma

Received Oct. 17, 1986; revision accepted Aug. 18, 1987.

For reprints contact: Susan E.M. Clarke, MD, Dept. of Nuclear Medicine, Guy's Hospital, St Thomas St., London, SE1 9RT.

TABLE 1
Patient Details

Patient	Age (yr)	Yr since diagnosis	Sx [†]	Calcitonin pg/ml (NR [*] <100 pg/ml)	CT result
1	65	2	+	6,100	Bone skull L2 rib pelvis Soft-tissue paralumbar
2	52	18	+	8,970	Bone ribs vertebrae pelvis Soft-tissue local nodes liver lung
3	53	7	+	3,540	Bone vertebrae right shoulder skull pelvis Soft-tissue local
4	74	10	+	5,310	Bone vertebrae pelvis femora Soft-tissue local
5	52	2	+	2,400	Soft-tissue local
6	45	3	+	6,000	Soft-tissue local liver
7	24	4	-	1,200	Soft-tissue lung
8	38	4	-	995	No tumor visualized
9	86	10	+	1,400	Bone T6 Soft-tissue para-aortic

* NR = Normal range.

† Sx = Symptoms.

camera. Patients then received Lugol's iodine 24 hr prior to the administration of 1 mCi (37 MBq) [¹³¹I]MIBG, and for 7 days after. Patients were imaged at 24 and 48 hr after [¹³¹I]MIBG administration and whole-body images were acquired.

In the final part of the study, [^{99m}Tc](V)DMSA was prepared by adding 4.4 mg DMSA, 120 mg dextrose, and 5.04 mg sodium bicarbonate to a standard DMSA vial[†]. These powders were dissolved in 0.4 ml of 7% sodium bicarbonate solution. A portion (0.1 ml) of the resultant solution was added to 2.5 ml containing 15 mCi (550 MBq) [^{99m}Tc]pertechnetate. Prior to use, the injection was filtered through a 0.22- μ m filter and 10 mCi (370 MBq) [^{99m}Tc](V)DMSA were then injected intravenously within 120 min of preparation. Whole-body images were acquired 2 hr after injection.

RESULTS

A summary of our results is shown in Table 2. All patients with metastases demonstrated by CAT scanning showed [^{99m}Tc](V)DMSA accumulation in both bone and soft-tissue metastases, with 88% of patients with disease identified on imaging. Technetium-99m(V)DMSA detected 94% of all bone metastases and 100% of soft-tissue metastases, both local and distant. One patient with elevated calcitonin levels (Patient 8) failed to demonstrate uptake with [^{99m}Tc](V)DMSA, and was judged a false-negative result despite negative findings with all other imaging techniques. Iodine-131 MIBG showed significant uptake in three patients, with a sensitivity of 38%, but not all known tumor sites were visualized and uptake appeared more pronounced in soft-tissue metastases. Thirteen percent of soft-tissue lesions were detected, compared with 10% of bony metastases (Fig. 1), and uptake was demonstrated in four patients with identified disease (Fig. 2). Technetium-99m MDP was taken up by all known bony metastases, but no uptake in soft-tissue metastases was demonstrated in this study (Fig. 3).

The effective dose equivalent, assuming three hourly bladder emptying, has been calculated in this study to be 3.0 mSv using [^{99m}Tc](V)DMSA.

DISCUSSION

Medullary carcinoma is an uncommon tumor but, like follicular carcinomas of the thyroid, runs a prolonged course, with patients frequently surviving many years following initial diagnosis, despite distant metastases. As these tumors commonly metastasize to bone, [^{99m}Tc]MDP bone scanning has been used routinely to follow-up these patients and, in some individuals, uptake of [^{99m}Tc]MDP has also been observed in soft-tissue metastases. Recent interest has been shown in two other imaging agents, namely [^{99m}Tc](V)DMSA and [¹³¹I]MIBG, that have both been demonstrated to accumulate in some patients with MCT (7,12). We have confirmed that both these radiopharmaceuticals are, indeed, taken up in sites of known recurrent MCT, and we have also shown that [^{99m}Tc](V)DMSA has distinct advantages over both [¹³¹I]MIBG and [^{99m}Tc]MDP in imaging patients with metastatic MCT. Uptake

TABLE 2
% Metastases Identified

	[¹³¹ I]MIBG			[^{99m} Tc]MDP			[^{99m} Tc](V)DMSA		
	Bone	Soft tissue		Bone	Soft tissue		Bone	Soft-tissue	
		Local	Distant		Local	Distant		Local	Distant
Lesion sensitivity	5/52(10%)	2/10(20%)	3/23(13%)	52/52(100%)	0/10 (0%)	0/23(0%)	49/52(94%)	10/10(100%)	23/23(100%)
Overall sensitivity		10/85(12%)			52/85(61%)			82/85(95%)	

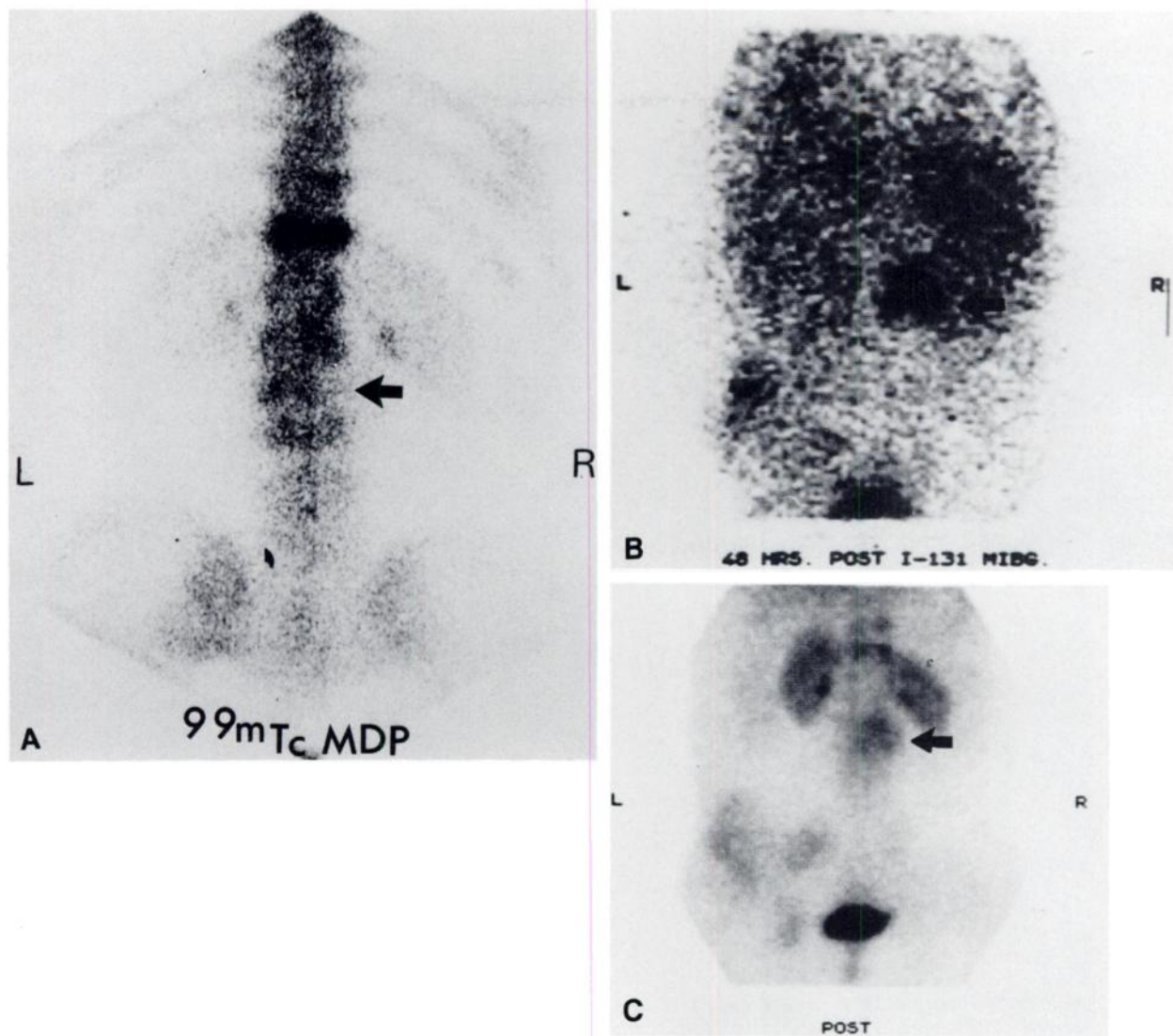


FIGURE 1

A: [^{99m}Tc]MDP bone scan. Posterior view of abdomen, showing linear increased uptake of MDP at level of T12 but with photon deficient area in region of lateral borders of L2, L3 (arrow). B: [^{131}I]MIBG scan. Posterior view of abdomen, showing intense uptake at level of L2 (arrow) and identifying known metastasis in left iliac crest. C: [^{99m}Tc](V)DMSA scan. Posterior view of abdomen, showing uptake at level of T12, and in lesion at level of L2 (arrow). Also diffuse uptake in left iliac crest metastasis.

of [^{99m}Tc](V)DMSA was visualized in all patients with proven metastases, with a sensitivity of lesion detection of 95%, and the images obtained were of high quality with good tumor-to-background ratio. Most known tumor sites were identified, both bony and soft tissue, and no false-positive uptake of [^{99m}Tc](V)DMSA was seen. Only one false-negative scan was obtained, and this was in an asymptomatic patient in whom, although calcitonin levels were elevated, no tumor could be visualized despite extensive investigation.

Technetium-99m(V)DMSA is a low cost radiopharmaceutical, that is easily prepared and is imaged at 2 hr after injection. As a technetium-labeled radiopharmaceutical, the effective dose equivalent of 3.0 mSv is markedly less than that from a diagnostic [^{131}I]MIBG

scan, calculated by Swanson et al. from animal data (13) to be 75 mSv for a 1 mCi [^{131}I]MIBG dose. The method of uptake of [^{99m}Tc](V)DMSA into tumors is not understood. Ohta et al. (11) have postulated that pentavalent DMSA resembles the phosphate ion, and suggest that this is the mechanism by which [^{99m}Tc](V)DMSA accumulates in tumors, particularly in MCT where calcification is a well recognized phenomenon. The observation in this study that [^{99m}Tc](V)DMSA is taken up into more sites than are visualized with [^{99m}Tc]MDP suggests that this may not be the explanation of uptake. Animal work is at present being carried out in an attempt to understand the mode of uptake of [^{99m}Tc](V)DMSA into certain tumors.

The recently reported failure by Hilditch et al. (14)

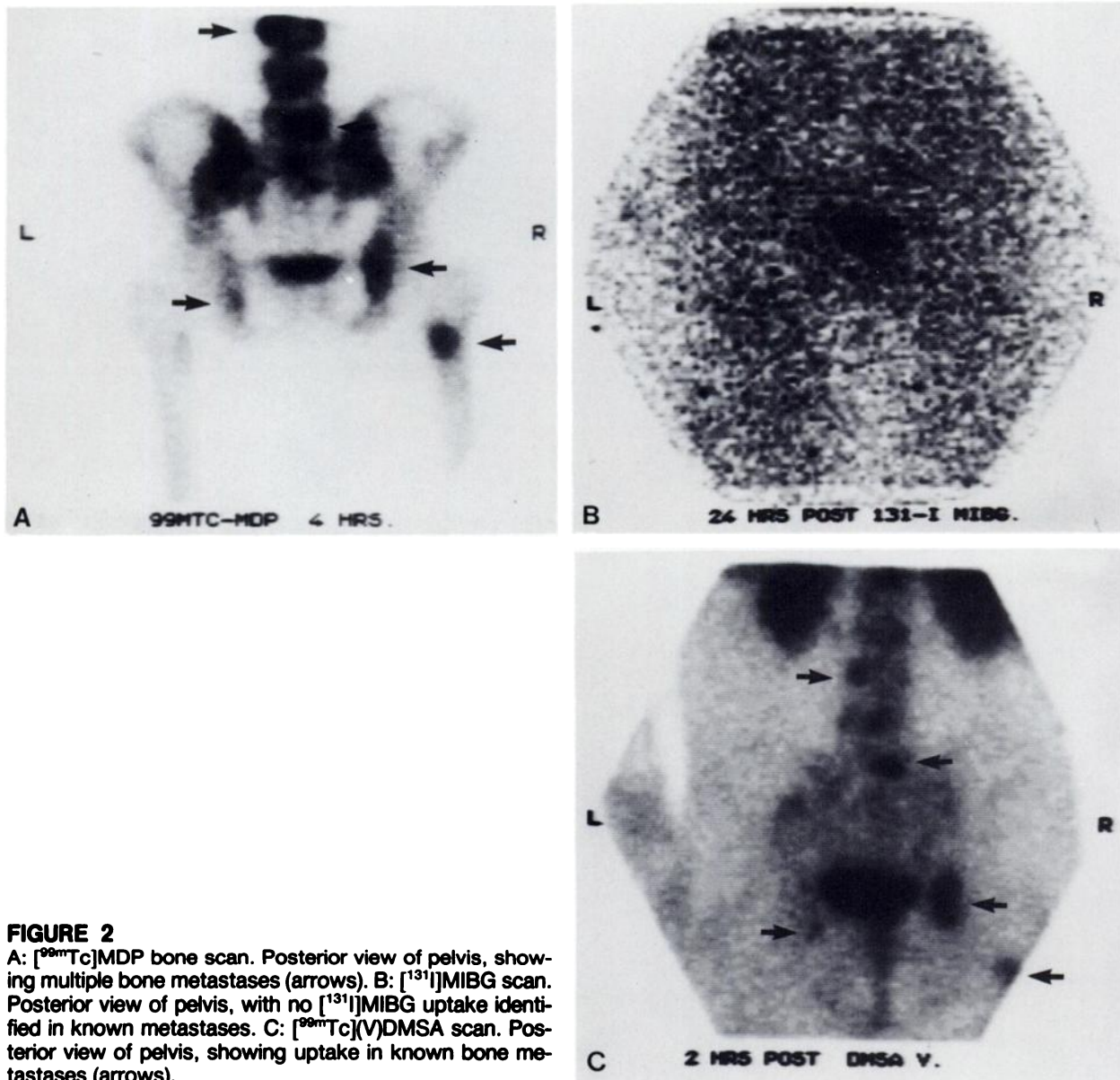


FIGURE 2

A: [^{99m}Tc]MDP bone scan. Posterior view of pelvis, showing multiple bone metastases (arrows). B: [^{131}I]MIBG scan. Posterior view of pelvis, with no [^{131}I]MIBG uptake identified in known metastases. C: [^{99m}Tc](V)DMSA scan. Posterior view of pelvis, showing uptake in known bone metastases (arrows).

to demonstrate uptake of [^{99m}Tc](V)DMSA in six patients with MCT is probably due to kit instability, since the images presented were typical of those achieved with the trivalent form of DMSA rather than the pentavalent form (15,16).

Technetium-99m MDP, while remaining a suitable agent for imaging bony metastases with a sensitivity of bone metastases detection of 100%, failed to demonstrate soft-tissue metastases in any of the patients imaged, and is therefore less satisfactory in the routine follow-up of MCT patients, with an overall sensitivity of 61% for lesion detection.

Iodine-131 MIBG has clearly been shown to be a useful imaging agent in patients with pheochromocytoma (16) and neuroblastoma (17) with a false-negative rate of ~10% to 20% in both tumor types. Since MCT is also neuroectodermally derived, the much higher false-negative rate (56%) demonstrated in this study

and in the study of Poston et al. (10) is disappointing, particularly in view of the therapeutic potential of [^{131}I]MIBG in patients with significant uptake. The failure of some patients with proven metastatic tumour to accumulate [^{131}I]MIBG requires further investigation in order to attempt to identify the factors that predispose to [^{131}I]MIBG uptake. However, the fact that only 11% of lesions were detected indicates that this radiopharmaceutical has no role in primary diagnosis or in the detection of recurrence, but its potential role in therapy in patients with significant uptake warrants further study.

We believe that [^{99m}Tc](V)DMSA has been demonstrated in this study to be an ideal imaging agent for the follow-up of patients with MCT, in whom elevation of the calcitonin levels after thyroidectomy suggest the persistence or recurrence of tumor, facilitating the visualization of local and distant metastases and the as-

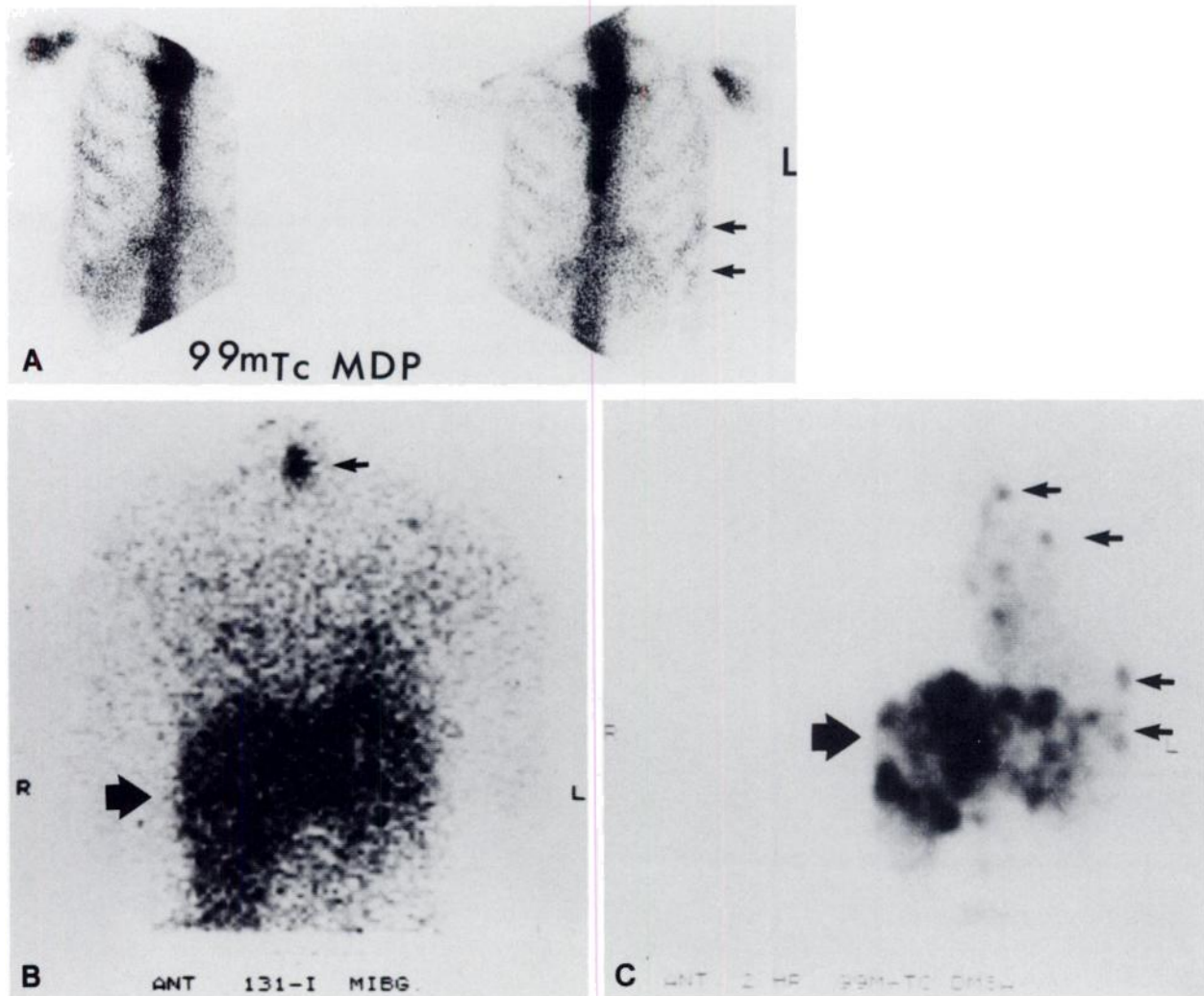


FIGURE 3

A: [^{99m}Tc]MDP bone scan. Anterior views of thorax, showing rib metastases but with no uptake in hepatic metastases (arrows). Faint renal activity is seen. B: [^{131}I]MIBG. Anterior view of thorax, showing diffuse [^{131}I]MIBG accumulation in hepatic metastases and uptake in suprasternal recurrence (arrow). C: [^{99m}Tc](V)DMSA. Anterior view of thorax showing intense uptake in local, rib, and hepatic metastases (arrows).

assessment of response to therapy. Both [^{99m}Tc]MDP and [^{131}I]MIBG have marked disadvantages in the follow-up of this group, but may have a secondary role in management.

NOTE

* Amersham International plc, Buckinghamshire, England.

ACKNOWLEDGMENT

The author thanks Caroline Bishop for her secretarial assistance.

REFERENCES

1. Anderson RJ, Sizemore GW, Wahner HW, et al. Thyroid scintigraphy in familial medullary CA of the thyroid gland. *Clin Nucl Med* 1978; 3:147.
2. Johnson DG, Coleman RE, McCook TA, et al. Bone and liver scans in medullary carcinoma of the thyroid. *J Nucl Med* 1984; 25:419-422.
3. Hartshorne MF, Karl RD Jr, Cawthon MA, et al. Multiple imaging techniques demonstrate a medullary carcinoma of the thyroid. *Clin Nucl Med* 1983; 8:628-629.
4. Parthasarathy KL, Shirmaoka K, Bakshi SP, et al. Radiotracer uptake in medullary carcinoma of the thyroid. *Clin Nucl Med* 1980; 5:45-48.
5. Senga O, Miyakowa M, Shirota H, et al. Comparison of Tl-201 chloride and Ga-67 citrate scintigraphy in the diagnosis of thyroid tumour: concise communication. *J Nucl Med* 1982; 23:225-228.
6. Sisson JC, Frager MS, Valk TN, et al. Scintigraphic localisation of pheochromocytoma. *N Engl J Med* 1981; 305:12-17.
7. Endo K, Shiomi K, Kasagi K, et al. Imaging of medullary thyroid cancer with ^{131}I -MIBG. *Lancet* 1984;

- ii:233.
8. Cannell JMC, Hilditch TG, Elliott A, et al. ¹³¹I MIBG and medullary carcinoma of the thyroid. *Lancet* 1984; ii:273-274.
 9. Sane J, Fukunaga M, Otsuka N, et al. Metastatic medullary thyroid cancer: Localisation with iodine-131-metaiodobenzylguanidine. *J Nucl Med* 1985; 26:604-608.
 10. Poston GJ, Thomas AMK, MacDonald DWR, et al. ¹³¹I MIBG uptake by medullary carcinoma of the thyroid. *Lancet* 1985; ii:560.
 11. Ohta H, Endo K, Fujita T, et al. Imaging of head and neck tumours with Technetium (V)-99m DMSA. A new tumour seeking agent. *Clin Nucl Med* 1985; 10:855-860.
 12. Ohta H, Yamamoto K, Endo K, et al. A new imaging agent for medullary carcinoma of the thyroid. *J Nucl Med* 1984; 25:323-325.
 13. Swanson DP, Carey JE, Brown LE, et al. Human absorbed dose calculations for iodine-131 and iodine-123 labelled meta-iodobenzyl guanidine (MIBG): a potential myocardial and adrenal medullary imaging agent. Proceedings of the Third International Symposium on Radiopharmaceutical Dosimetry, 1980; 1981:213-224.
 14. Hilditch TE, Connell JMC, Elliot YAT, et al. Poor results with technetium-99m(V)-DMS and iodine-131 MIBG in the imaging of medullary thyroid carcinoma. *J Nucl Med* 1986; 27:1150-1153.
 15. Endo K, Ohta H, Torizuka K, et al. Technetium-99m(V)-DMSA in the imaging of medullary thyroid carcinoma. *J Nucl Med* 1987; 28:252-253.
 16. Clarke SEM, Lazarus CR, Fogelman I, et al. Technetium-99m(V)-DMSA in the imaging of medullary thyroid carcinoma. *J Nucl Med* 1987; 28:253.
 17. Trennor J, Feine U, Niethammer D, et al. Scintigraphic imaging of neuroblastoma with ¹³¹I metaiodobenzylguanidine. *Lancet* 1984; i:333-334.