

### Hepatic Scintigraphy of Nodular Regenerative Hyperplasia of the Liver

**TO THE EDITOR:** Nodular regenerative hyperplasia of the liver (NRHL) is a rare disease of unknown etiology characterized by diffuse nodular transformation of the hepatic parenchyma without fibrosis. Patients with NRHL present frequently with hepatomegaly and clinical features of portal hypertension including splenomegaly, bleeding esophageal varices, ascites, and hepatic encephalopathy (1). Consequently, NRHL may closely mimic cirrhosis clinically with potentially life-threatening symptoms. Presented is a case of biopsy proven NRHL in whom planar and tomographic liver-spleen scintigraphy was performed. To my knowledge, this is the first reported case describing the hepatic scintigraphic findings of this clinically important and interesting hepatic disorder.

A 77-yr-old woman with a longstanding history of cardiac arrhythmias and congestive heart failure presented with recent onset of mid-epigastric pain, nausea, and palpable liver enlargement. Serum liver function tests were moderately elevated although serum hepatitis antigen and antibodies were negative. Although the patient denied previous history of heavy alcohol intake, intravenous drug abuse, or receiving blood transfusions, a differential diagnosis of cirrhosis versus hepatitis was considered. Because of the newly detected hepatomegaly and abnormal serum liver function tests, a liver-spleen scintigram was performed. Following i.v. injection of 4 mCi (148 MBq) of technetium-99m sulfur colloid, planar and single photon emission computed tomographic (SPECT) images of the liver and spleen were simultaneously acquired using a dual-headed rotating large field-of-view gamma camera, equipped with a parallel hole collimator. The SPECT data was acquired for 30 min as 128 × 128 images in 90 angular projections over a 360° circular rotation, with the camera rotating around the supine patient. The data was reconstructed by an integrated computer system into transverse images. The planar images were generated from the SPECT data acquisition.

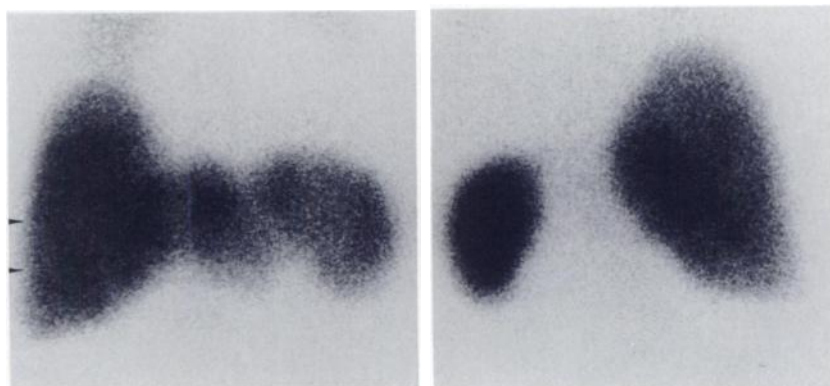
The planar study demonstrated borderline hepatosplenomegaly with essentially homogeneous distribution of radiocolloid activity in the liver and spleen (Fig. 1). The SPECT images, however, demonstrated multiple focal areas of de-

creased hepatic activity (Fig. 2). Subsequently, a liver biopsy was performed and demonstrated regenerating nodules of hepatocytes without fibrous septa, diagnostic of NRHL. In addition, pericentral congestion with sinusoidal dilatation and occasional fat droplets were present, suggestive of passive liver congestion due to longstanding congestive heart failure. Congestive heart failure with secondary liver congestion has been reported to occur in some patients with NRHL (2). Unfortunately, since a blind needle biopsy of the liver was performed, it is not possible to determine whether the biopsy site corresponded to an area of decreased uptake.

The marked discrepancy between the planar images, which demonstrate homogeneous radiocolloid activity and the SPECT images, which demonstrate obvious focal defects, is interesting but should not be surprising. SPECT has been reported to possess a slightly higher sensitivity for detecting focal hepatic disease (range: 86–94%) as compared to planar scintigraphy (range: 81–83%) (3,4). Furthermore Brendel et al. (3) in their study of 98 patients with suspected focal hepatic disease, reported that five of their patients with true-positive SPECT studies had false-negative planar scintigraphic studies. Therefore, SPECT imaging may occasionally demonstrate focal hepatic disease in the absence of abnormal findings on planar scintigraphy.

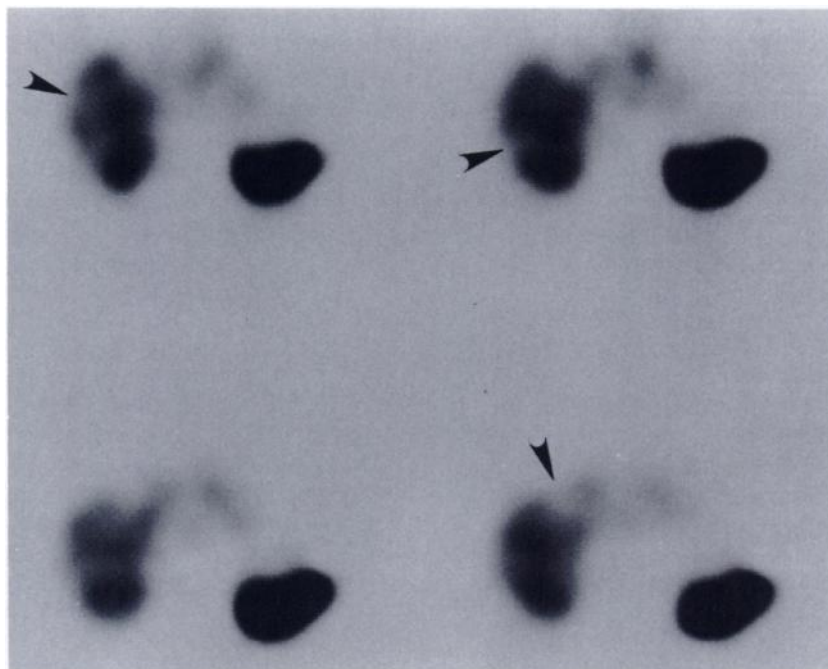
Because NRHL can mimic cirrhosis clinically, the diagnosis is usually established pathologically following liver biopsy. It is distinguished from cirrhosis by the absence of fibrous septa between the hepatic nodules. Because of the relatively high incidence (~50%) of portal hypertension, esophageal varices, and ascites reported in patients with NRHL (5), it is of clinical significance to distinguish this entity from cirrhosis in patients with longstanding liver disease. This case suggests that scintigraphy may be unable to distinguish the two entities.

Scintigraphic findings of multiple focal areas of decreased radiocolloid uptake in the liver were demonstrated on the SPECT study (Fig. 2). These scintigraphic findings may also be present in cirrhosis, due to fatty and fibrotic replacement of hepatocytes resulting in focal areas of decreased activity. Hepatosplenomegaly, which occurs in 70% of patients with NRHL (6), may be present in patients with cirrhosis, particularly when fatty infiltration of the liver occurs in conjunction with portal hypertension. Focal areas of decreased activity in NRHL may be due to deficient Kupffer cell populations in



**FIGURE 1**

Planar liver-spleen scintigram demonstrates homogeneous radiocolloid activity. Arrowheads indicate most superior and inferior levels at which transverse tomographic images shown in Fig. 2 were acquired



**FIGURE 2**

Sequential 1 cm SPECT transverse images (top left: most superior level; lower right: most inferior level) demonstrate multiple photon-deficient defects in liver parenchyma. Arrowheads indicate abnormal regions in right hepatic lobe

the regenerating nodules, and/or regional intrahepatic vascular flow abnormalities caused by venous compression due to adjacent regenerating nodules. Consequently, hepatic scintigraphy may demonstrate similar findings in patients with NRHL or cirrhosis.

However, NRHL may present with other hepatic scintigraphic findings. In their clinicopathologic study of 30 patients with NRHL, Strohmeyer et al. (7) reported that four patients underwent hepatic scintigraphy. Two studies were interpreted as normal (with presumably homogeneous uptake) and two as demonstrating decreased uptake, but no further description of the scintigraphic findings were given. They reported that many cases showed Kupffer cell hyperplasia on histopathologic examination, thus raising the theoretical possibility of focal increased uptake as a scintigraphic finding associated with NRHL. Consequently, NRHL may demonstrate scintigraphic findings of homogeneous uptake, or of heterogeneous uptake with focal regions of decreased and possibly increased activity.

Although this case suggests that NRHL may not have a characteristic scintigraphic appearance, hepatic scintigraphy may have diagnostic value in documenting progression of disease. Planar and SPECT liver-spleen scintigraphy are inexpensive, rapid, and noninvasive imaging procedures that have been demonstrated to possess a high sensitivity for detecting liver disease (3,4). Consequently, scintigraphy can be used to document progression of the pathologic process and to monitor the response of disease to medical therapy. However, further studies involving larger series of patients will be needed to fully evaluate the diagnostic value of scintigraphy in patients with NRHL. Although the etiology of NRHL remains unknown, it has been reported to be frequently associated with Felty's syndrome (6) and other hematologic-lymphoid disorders (7). In patients with Felty's syndrome or other hematologic-lymphoid disorders, such as lymphomatoid granulomatosis or Hodgkin's disease, scintigraphic findings of hepatosplenomegaly with focal areas of decreased or increased

uptake should suggest the possibility of NRHL, particularly in the absence of etiologic factors for cirrhosis.

#### References

1. Mones JM, Saldana MF, Albores-Saavedra J: Nodular regenerative hyperplasia of the liver: report of three cases and review of the literature. *Arch Pathol Lab Med* 108:741-743, 1984
2. Steiner PE: Nodular regenerative hyperplasia of the liver. *Am J Pathol* 35:943-953, 1959
3. Brendel AJ, Leccia F, Drouillard J, et al: Single photon emission computed tomography (SPECT), planar scintigraphy, and transmission computed tomography: a comparison of accuracy in diagnosing focal hepatic disease. *Radiology* 153:527-532, 1984
4. Strauss L, Bostel F, Clorius JH, et al: Single-photon emission computed tomography (SPECT) for assessment of hepatic lesions. *J Nucl Med* 23:1059-1065, 1983
5. Reynolds WJ, Wanless IR: Nodular regenerative hyperplasia of the liver in a patient with rheumatoid arthritis: a morphometric study suggesting a role for hepatic arteritis in the pathogenesis. *J Rheumat* 11:838-842, 1984
6. Guarda LA, Hales MR: Nodular regenerative hyperplasia of the liver: report of two cases and review of the literature. *J Clin Gastroenterol* 3:157-164, 1981
7. Strohmeyer FW, Ishak KG: Nodular transformation (nodular regenerative hyperplasia) of the liver. *Human Pathol* 12:60-71, 1981

Robert Smith  
University Hospital  
Jacksonville, Florida

#### False-Negative Thallium-Techetium Subtraction Scintigraphy

**TO THE EDITOR:** Thallium-201 ( $^{201}\text{Tl}$ ) chloride-technetium-99m ( $^{99\text{m}}\text{Tc}$ ) pertechnetate subtraction scintigraphy has proven to be useful in the localization of parathyroid lesions.