

- cintigraphy in the diagnosis of acute cholecystitis. *Ann Clin Res* 10:227-234, 1978
9. SHUMAN WP, GIBBS P, RUDD TG, et al: PIPIDA scintigraphy for cholecystitis: False positives in alcoholism and total parenteral nutrition. *Am J Roentgenol* 138:1-5, 1982
 10. KALFF V, FROELICH JW, LLOYD R, et al: Predictive value of an abnormal hepatobiliary scan in patients with severe intercurrent illness. *Radiology* 146:191-194, 1983
 11. ARISTOTLE: On the parts of animals. Translated by W. Ogle, London, K. Paul French & Co., 1882
 12. VANDERPOOL D, KLINGENSMITH W, OLES P: Congenital absence of the gallbladder. *Am Surg* 30:324-328, 1964
 13. LEMERY: Observation VIII: Historie de l'Acad Roy des sciences. Annee, 1701, p 54
 14. SANDERS GB, FLORES T, ARRIOLA P: Congenital absence of the gallbladder and cystic duct: A review of the literature and report of a case. *Am Surg* 34:750-754, 1968
 15. MONROE SE: Congenital absence of the gallbladder: A statistical study. *J Int Coll Surg* 21:369-372, 1959
 16. PINES B, GRAYZEL DM: Congenital absence of the gallbladder and cystic duct. *AMA Arch Surg* 77:171-174, 1958
 17. MONROE SE, RAGEN FJ: Congenital absence of the gallbladder. *California M* 85:422-423, 1956
 18. ROGERS AL, CREWS RD, KALSER MH: Congenital absence of the gallbladder with choledocholithiasis. *Gastroenterology* 48:524-529, 1965
 19. DIXON CF, LICHTMAN AL: Congenital absence of the gallbladder. *Surgery* 17:11-21, 1945
 20. BREZING HJ, SANCHEZ SM: Congenital absence of gallbladder. *NY State J Med* 64:914-915, 1964
 21. FREY C, BIZER L, ERNST C: Agenesis of the gallbladder. *Am J Surg* 114:917-926, 1967
 22. WRIGHT E, MADORE P: Congenital absence of the gallbladder. *Can Med Assoc J* 93:123-125, 1965
 23. FLANNERY MG, CASTER MP: Congenital abnormalities of the gallbladder. 101 cases. *Intern Abstr Surg* 103:439-455, 1956
 24. SCHLOSSMAN RE, TARTELL M, WEISSBACH MS, et al: Agenesis of gallbladder associated with mitral annulus prolapse. A possibly unreported entity. *NY State J Med* 82:1249-1251, 1982.

Bone Scintigraphy: Differentiating Benign Cortical Irregularity of the Distal Femur from Malignancy

Michael G. Velchik, Sydney Heyman, P. Todd Makler, Jr., Harold A. Goldstein, and Abass Alavi

Hospital of the University of Pennsylvania, and The Children's Hospital of Philadelphia, Philadelphia, Pennsylvania

Two cases of benign cortical irregularity of the distal femur (BCIDF), which radiologically simulate malignancy, are presented. The use of bone scintigraphy in differentiating this entity from malignancy is described.

J Nucl Med 25: 72-74, 1984

Malignant bone tumors typically appear as abnormal foci of intense radionuclide uptake on bone image, whereas benign cortical irregularity of the distal femur (BCIDF), being more diffuse in nature, characteristically has normal or only minimally increased uptake of the tracer. This dramatic difference in scintigraphic appearance should obviate unnecessary amputations and biopsies in patients with BCIDF, which radiologically masquerades as malignancy. Avulsive cortical irregularity of the distal femur (1) was first described in 1951 by Kimmelstiel and Rapp (2); it is also referred to as cortical desmoid, periosteal desmoid (2), subperiosteal desmoid, subperiosteal abrasion, cortical abrasion, medial distal metaphyseal femoral irregularity (3), and subperiosteal cortical defect. There is very little in the nuclear medicine literature concerning this topic. Conway et al. found normal bone images in several children with this entity and strongly recommended the use of bone scintigraphy in such cases (4).

CASE REPORTS

Case 1. A 10½-yr-old white male had a history of left knee pain

Received May 13, 1982; revision accepted Aug. 8, 1983.

For reprints contact: Michael G. Velchik, MD, Hospital of the University of Pennsylvania, Dept. of Radiology, Division of Nuclear Medicine, 3400 Spruce St., Philadelphia, PA 19104.

beginning approximately 2 mo before admission. Physical examination was remarkable for fullness in the popliteal space of the left knee and about the medial femoral condyle in the region of the adductor tubercle. The impression on admission was a mass in the region of the left knee, possibly from osteosarcoma.

Plain radiographs revealed an area of cortical irregularity and periosteal reaction in the posterior medial aspect of the distal left femur in the region of the adductor tubercle, with a mild degree of associated soft-tissue fullness and no evidence of effusion (Fig. 1). A single-phase bone image, performed with 10 mCi of Tc-99m MDP and including pinhole views of both knees, was normal (Fig. 2). An arteriogram demonstrated normal vascularity.

Since the plain radiographs were suspicious for a malignant tumor of the distal femur, a biopsy of the adductor tubercle was performed. Microscopy revealed normal-appearing bone, cartilage, vascular fibrous tissue, and giant cells suggestive of reactive changes without any evidence of malignancy.

Plain radiographs obtained at the 4-mo follow-up demonstrated healing of the biopsy site without any evidence of bone destruction.

Case 2. A 13-yr-old black male presented with a 3-hr history of pain in the left knee associated with swelling and difficulty in weight-bearing after playing basketball. There was a history of an effusion in this knee 6 mo before admission.

Physical examination of the left knee revealed swelling and

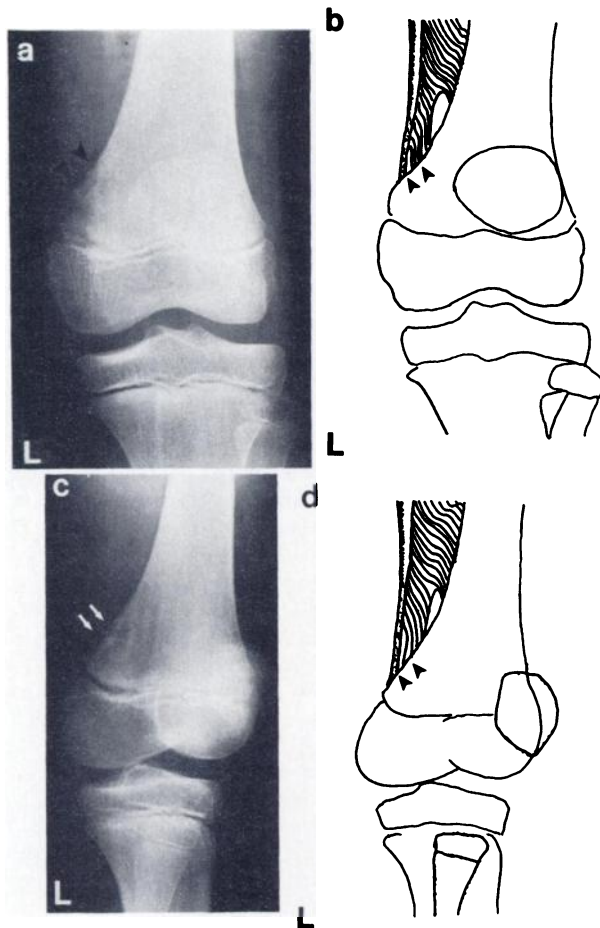


FIG. 1. Case 1: Benign cortical irregularity of distal left femur. (a) AP radiograph of left knee demonstrating cortical irregularity and periosteal elevation along posterior medial aspect of distal femur. (b) Diagram of (a) demonstrating insertion of tendon of adductor magnus muscle just above adductor tubercle in posterior medial aspect of distal femur. (c) Oblique AP radiograph with 30° of external rotation. (d) Diagram of radiograph shown in (c).

tenderness of the distal thigh in its mid aspect, without evidence of an effusion.

Plain radiographs showed a mild degree of cortical irregularity in the posterior medial aspect of the distal left femur in the region of the adductor tubercle, with a slight degree of periosteal elevation (Fig. 3).

The patient was admitted to the hospital with a tentative diagnosis of a tumor involving the distal aspect of the left femur. A bone image was ordered for diagnostic purposes and in order to locate the lesion and mark its extent, should an amputation be necessary. The single-phase bone image demonstrated a minimal increase in activity diffusely throughout the distal left femur, consistent with the history of trauma and with no intense focus to suggest tumor (Fig. 3).

The patient underwent arthroscopy with stress testing under anesthesia. At surgery, all of his intraarticular structures were normal but he had a massive chylous hemarthrosis. The diagnosis was a nondisplaced Salter I fracture of the distal femoral growth plate. The knee was flexed at 45° and placed in a cylinder cast for 3 wk.

Three weeks later, follow-up radiographs of the left knee continued to show a minimal degree of periosteal elevation in the posterior medial aspect of the distal left femur. The secondary diagnosis was a benign lesion of the posterior medial aspect of the

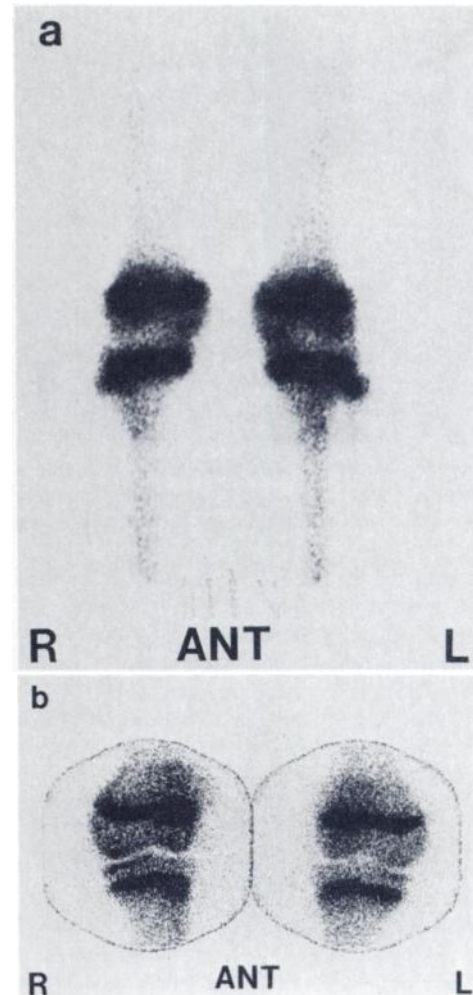


FIG. 2. Case 1: (a) Normal anterior gamma-camera image of knees. (b) Anterior pinhole images of knees for comparison.

distal left femur, most likely representing benign cortical irregularity.

One month later, the patient was progressing well with physical therapy, and follow-up radiographs showed continued resolution.

DISCUSSION

BCIDF occurs in the age range of 3–17 yr, most commonly between 10 and 15 yr (1–3). It is rarely seen in the preschool child, and not at all after epiphyseal closure (3). There is a male-to-female ratio of approximately 3:1 (3,5). It occurs about twice as often in the left femur as in the right (3), and bilaterally in 25–35% of cases (1,5). It is usually asymptomatic, discovered incidentally (1,3,5). In general there is no associated mass, soft-tissue swelling, pain, or loss of soft-tissue planes (3). However, occasionally pain may be present and may be the presenting complaint (5).

Radiographically, the BCIDF may simulate malignancy (1,3,5–9). Kimmelstiel et al. reported a case in which an amputation was performed because BCIDF mimicked a malignant neoplasm (2). Biopsy of the lesion is unnecessary and generally not helpful (1,5,8). Furthermore, it may result in the false-positive diagnosis of malignancy (most commonly osteosarcoma or fibrosarcoma) (1,5,7,8).

BCIDF characteristically occurs in the posterior medial aspect of the distal femur along the medial supracondylar ridge of the linea aspera, just above the adductor tubercle at the insertion of

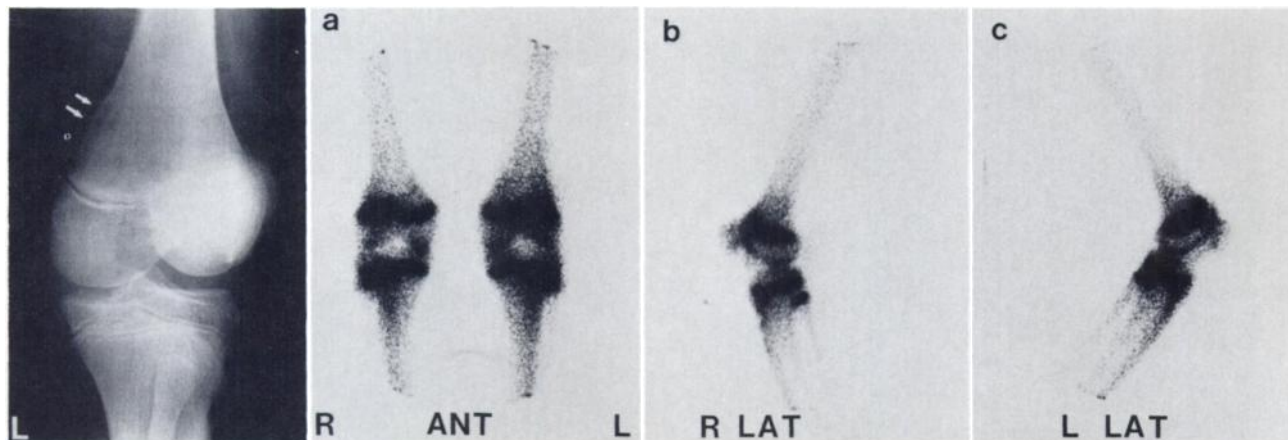


FIG. 3. Case 2: Oblique AP radiograph with 30° of external rotation demonstrating cortical irregularity and periosteal elevation along posterior medial aspect of distal left femur. Bone images with (a) anterior, (b) lateral projection of right knee, and (c) lateral projection of left knee demonstrating slightly increased activity diffusely in left knee.

the adductor magnus (1-3,5,7-9). It is best demonstrated by obtaining an oblique anteroposterior radiograph with 30° of external rotation (Fig. 1C). It measures approximately 1-3 cm in length, with its long axis paralleling the long axis of the femur (3). It appears as a lytic area of cortical irregularity with associated periosteal reaction. Sometimes there is reactive bone formation and spiculation, with small cortical fragments being located in the adjacent soft tissue (5). These features may raise suspicion of malignancy. With healing, a sclerotic margin and cortical thickening may develop along with progressive migration of the lesions away from the epiphysis (1,5).

Benign cortical irregularity has been observed rarely in other locations such as the humerus, tibia, fibula, radius, metatarsus, metacarpus, and distal phalanx (1). Fulton et al. (6) described its counterpart in the proximal humerus at the insertion of the pectoralis major muscle as "ringman's shoulder lesion", occurring primarily in gymnasts.

The knee region is a common area for both benign and malignant neoplasms in children. BCIDF is most often confused with an osteosarcoma. Radiologically, both may have cortical irregularity, periosteal reaction, spiculation, and cortical fragments or bony density within the adjacent soft tissues. However, these features are usually more pronounced in osteosarcoma. In addition, osteosarcomas usually have a significant associated soft-tissue component and loss of soft-tissue planes (3). Frequently, however, the two may be indistinguishable radiologically.

Malignant bone tumors characteristically appear scintigraphically as abnormal foci of intense radionuclide uptake. Of the six patients with BCIDF and scintigraphic correlation reported in the literature, five had normal bone images and one patient had a very slight increase in uptake, minimal in intensity (10).

It is readily apparent from a review of the literature that much confusion has existed about the pathogenesis and histologic nature of the lesion (1,5). Macroscopically, there is periosteal and cortical thickening (1,2,5,9). In addition, fragments of resorbing bone are often found in the adjacent soft tissue (5). Microscopically, there is evidence of fibrous-tissue proliferation and numerous osteoclasts (1,2,5). Thus, the pathologic features are those of reactive process rather than a neoplastic one (4). The periosteal reaction, cortical thickening, reactive bone formation, and bony fragments within the soft tissues may easily be confused with a malignant tumor such as an osteosarcoma or fibrosarcoma (1,3,5,8,9).

Currently the pathogenesis is thought to be related to excessive mechanical stress produced at the insertion of the adductor magnus, resulting in microavulsions, disparity between resorption and formation of reactive bone, hypervascularity, and a fibroblastic

response, stimulating osteoclasts and leading in turn to bony resorption, erosion, and remodeling in an area of rapid bone growth (1,2,5,7,8) (Fig. 1). This has been described as a repetitive cycle of "micro-fracture-resorption-microfracture" (1,5).

If untreated, BCIDF will follow a benign course and resolve spontaneously, as indicated by an absence of this finding after epiphyseal closure (3). Contrarily, the treatment of choice for osteosarcoma is amputation. This marked difference in therapy emphasizes the importance of making the correct diagnosis. In this regard, it is recommended that bone scintigraphy be performed, especially in those cases where a diagnosis cannot be made from the plain film with a high level of confidence. In addition, the bone image will act as a screening procedure for metastasis. Biopsy is unnecessary and may be misleading.

REFERENCES

1. BUFKIN WJ: The avulsive cortical irregularity. *Am J Roentgenol* 112:487-492, 1971
2. KIMMELSTIEL P, RAPP I: Cortical defect due to periosteal desmoids. *Bull Hosp Joint Dis* 12:286-297, 1951
3. SIMON H: Medial distal metaphyseal femoral irregularity in children. *Radiology* 90:258-260, 1968
4. CONWAY JJ, GOONERATNE N, SIMON G: Radionuclide evaluation of distal femoral metaphyseal irregularities which simulate neoplasm. *J Nucl Med* 16:P521-522, 1975 (abst)
5. JACOBSON HG: Cortical desmoid. In *Bone Disease (Second Series) Syllabus*. Theros EG, Ed. Philadelphia, WB Saunders Co. 1976, 239-243
6. FULTON MN, ALBRIGHT JP, EL-KHOURY GY: Cortical desmoid-like lesion of the proximal humerus and its occurrence in gymnasts (ringman's shoulder lesion). *Am J Sport Med* 7(1):57-61, 1979
7. KREIS WR, HENSINGER RN: Irregularity of the distal femoral metaphysis simulating malignancy. Case Report. *J Bone Joint Surg* 59-A:838, 1977
8. BARNES GR JR, GWINN JL: Distal irregularities of the femur simulating malignancy. *Am J Roentgenol* 122:180-185, 1974
9. ALLEN DH: A variation of diaphyseal development which stimulates the roentgen appearance of primary neoplasms of bone. *Am J Roentgenol* 69:940-943, 1953
10. FEINE U, AHLEMANN LM: Periosteal desmoid of the metaphysis; differential diagnosis from malignant bone tumors by bone scintigrams. *Rofo* 135:193-196, 1981