

case presented here, radiorenography immediately after exercise appeared to be more sensitive than the resting scan in detecting asymmetry of renal perfusion. Further studies of patients with significant renal-artery stenosis, but who show no radiorenographic evidence of asymmetrical perfusion at rest, are clearly necessary to fully establish the value of exercise in this situation.

The effects of exercise on renal function are not well documented, but it is clear that blood pressure increases are associated with decrease in glomerular filtration and renal blood flow (6). The latter two changes persist after exercise and may not return to normal for at least 1 hr (7). It is difficult to be certain of the mechanism of the postexercise asymmetry, but if recovery of normal renal blood flow were slower on the stenotic side, clearance of the tracer would remain delayed longer on that side. It is possible that pharmacological agents may also be useful in unmasking asymmetry of renal perfusion, as with thallium-201 myocardial perfusion scanning (8). Drugs such as dipyridamole, or other vasodilator drugs such as diazoxide, may be interesting in this context.

PETER J. FULLER
MICHAEL J. KELLY
JAN R. STOCKIGT
Alfred Hospital
Melbourne, Australia

FOOTNOTE

* See *Seminars in Nuclear Medicine*, Volume XI, No. 2 and 3, 1981.

REFERENCES

1. FARMELANT MH, BURROWS BA: Sensitivity and specificity of radioisotope renography in renovascular hypertension. *Contrib Nephrol* 11:105-109, 1978
2. ARLART I, ROSENTHAL J, ADAM WE, BARGON G, FRANZ HE: Predictive value of radionuclide methods in the diagnosis of unilateral renovascular hypertension. *Cardiovasc Radiol* 2:115-125, 1979
3. STOCKIGT JR, HIGGS EJ, SACHARIAS N: Diazoxide-induced stimulation of renin release in renal vein renin sampling. *Clin Sci Mol Med* 51:233s-237s, 1976
4. SHAMES DM, KOROBKIN M: A simple technique for measuring relative renal blood flow. *J Nucl Med* 17:876-879, 1976
5. BRATT CG, LARSSON I, WHITE T: Scintillation camera renography with ^{99m}Tc -DTPA and ^{131}I -Hippuran. *Scand J Clin Lab Invest* 41:189-197, 1981
6. CASTENFORS J: Renal function during exercise. *Acta Physiol Scand* 70, Suppl 293:1-44, 1967
7. VITTINGHUS E, MOGENSEN CE: Albumin excretion and renal haemodynamic response to physical exercise in normal and diabetic man. *Scand J Clin Lab Invest* 41:627-632, 1981
8. ALBRO PC, GOULD KL, WESTCOTT RJ, et al: Noninvasive assessment of coronary stenoses by myocardial imaging during pharmacologic coronary vasodilatation. III. Clinical trial. *Am J Cardiol* 42:751-760, 1978

Hepatobiliary Imaging: Pyeloureterectasis

The clinical utility of hepatobiliary scintigraphy is well established for the evaluation of acute cholecystitis and patency of the common bile duct. Many reports have shown fortuitous findings in the blood-pool, renal, hepatocytic, and biliary phases of the

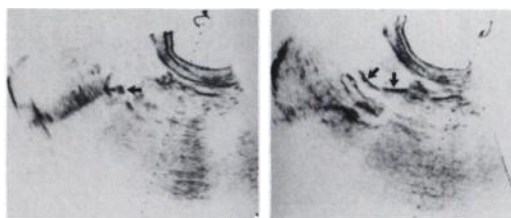


FIG. 1. Biliary ultrasonography. Gallbladder gives a single large internal echo (arrow) with prominent posterior shadowing, compatible with cholelithiasis (left). There may be other associated small stones. Common bile duct (two arrows) measured 12 mm, which indicates moderate dilation (right).

study. We wish to report a case of unilateral ureteral visualization noted during hepatobiliary scintigraphy, and the probable cause of this finding.

An 18-yr-old Mexican American female presented with a 1-wk history of midepigastic and right-upper-quadrant pain. Her past medical history revealed that she had delivered without complications approximately 5 wk before the current presentation. No blood products were used during delivery. She denied a history of hepatitis or known exposure to hepatitis. Admission laboratory values revealed mild leukocytosis and moderate elevation of all liver function tests, but renal function was normal.

Ultrasonic examination was obtained (Fig. 1). Hepatobiliary scintigraphy was likewise obtained to evaluate patency of the common bile duct (Fig. 2). The patient was explored surgically; chronic cholecystitis with cholelithiasis were discovered with an impacted stone at the ampulla.

On the fourth postoperative day urinalysis and urinary culture were unremarkable. The patient was discharged in stable condition.

Pyeloureterectasis during and immediately after pregnancy has been observed urographically for many years, but the cause of the dilatation remains undetermined and controversial; by itself this finding does not constitute proof of urinary-tract disease (1). Some degree of dilatation probably occurs during every pregnancy, but it usually subsides within two months after delivery although some reports document pyeloureterectasis persisting for much longer. The right ureter is dilated more commonly and usually to a greater degree than the left. Proximal ureteral dilatation is more common than distal dilatation. It is often difficult to segregate postpartum women with untreated asymptomatic bacteriuria during pregnancy (2). The interval of 4 to 6 mo is chosen to allow the ureteral dilatation of pregnancy to subside before further evaluation by intravenous pyelography (3).

Few fortuitous renal findings in patients undergoing hepatobiliary scintigraphy have been reported. After a search of the literature, we conclude that this patient represents the first reported hepatobiliary scintigraphic case of unilateral renal-ureteral visualization not representing a pathologic ureteral obstruction. The ureters normally dilate during pregnancy, and thus one should not rely solely on the finding of unilateral ureteral visualization to conclude that an obstruction of the ureter exists, particularly in postpartum females. Because of the high frequency of pyeloureterectasis in the postpartum population, a battery of serum creatinine, BUN, urinalysis, and urine culture is recommended for asymptomatic patients without a history of neoplasm or previous calculus formation. Intravenous pyelography should be used sparingly.

MYRON L. LECKLITNER
JAMES G. FLOURNOY
RAY W. WARE
University of Texas Health Science Center
San Antonio, Texas

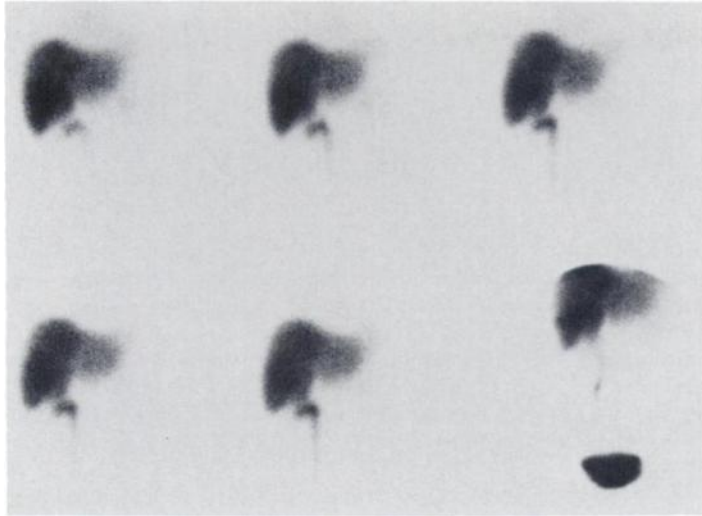


FIG. 2. Hepatobiliary scintigraphy (Tc-99m DISIDA, 8.1 mCi). Anterior hepatic views at 15, 30, and 45 min (top row). Anterior hepatic views at 60, 75, and 150 min (bottom row). All images demonstrate acceptable blood clearance of tracer, non-visualization of the gallbladder and intra- and extrahepatic biliary activity, and visualization of right renal pelvis, most of right ureter, and significant urinary bladder activity. Image at 24-hr (not shown) demonstrated only diffuse hepatic and renal activity. Impression: total biliary obstruction, an element of hepatocellular disease, and abnormal visualization of right ureter representing pyeloureterectasis from recent pregnancy.

REFERENCES

1. TEN CATE HW: Gynecological problems related to the urinary tract. In *Clinical Urography*, Vol. III (4 ed), Witten DM, Meyers GH, Utz DC, Eds. Philadelphia, W. B. Saunders Company, 1977, pp 2130-2204
2. COBBS CG, STRICKLER JC, MCGOVERN HJ, et al: The postpartum renal status of women with untreated asymptomatic bacteriuria during pregnancy. *Am J Obstet Gynecol* 99: 221-227, 1967
3. ELKIN M: *Radiology of the Urinary System*, Vol 1, Boston, Little, Brown and Company, 1980, pp 182-183

BOOKS RECEIVED

Nuclear Power: Health Implications of Transuranium Elements. Report on a Working Group—Brussels, 6-9 November 1979. Copenhagen, Denmark, World Health Organization, 1982, 88 pp, \$7.00

The Synthesis of Carbon-11, Fluorine-18, and Nitrogen-13 Labeled Radiotracers for Biomedical Applications. Joanna S. Fowler, Alfred P. Wolf. Oak Ridge, TN, USDOE Technical Information Center, 1982, 130 pp, \$11.25

Non-Invasive Bone Measurements: Methodological Problems. Jan V. Dequeker, Conrad C. Johnston, Eds. Oxford, England/Washington, D.C., IRL Press Ltd., 1982, 255 pp, \$30.00

Atlas of Sectional Human Anatomy Volume 1: Head, Neck, Thorax Volume 2: Abdomen, Pelvis. J.G. Koritke, H. Sick. Baltimore, MD—Munich, Urban & Schwarzenberg, 1983, 165 pp—Vol. 1, 183 pp—Vol. 2, \$165.00 (\$89.50 per vol.)

X-ray Fluorescence (XRF and PIXE) in Medicine. Roberto Cesareo, Ed. Rome Italy, Field Educationa Italia ACTA MEDICA, 1982, 239 pp, 18,000 Lira

Radionuclide Metabolism and Toxicity. P. Galle, R. Masse, Eds. Paris, France, Masson, 1982, 321 pp, \$36.00

Pediatric Nuclear Medicine (Series—Current Practice in Nuclear Medicine). John R. Sty, Robert J. Starshak, John H. Miller. Norwalk, CT, Appleton-Century-Crofts, 1982, 209 pp, \$42.50

Uroradiology: An Integrated Approach Volume I & II. Gerald W. Friedland, Roy Filly, Michael L. Goris, David Gross, Richard L. Kempson, Melvyn Korobkin, Barton D. Thurber, Joseph Walter, Eds. New York, NY, Churchill Livingstone, Inc., 1982, 1773 pp, \$190.00

A Clinical and Mathematical Introduction to Computer Processing of Scintigraphic Images. Michael L. Goris, Philippe A. Briandet. New York, NY, Raven Press, 1983, 296 pp, \$59.00

Radiation and Cellular Response. George P. Scott, Heinz W. Wahner, Eds. Ames, IA, The Iowa State University Press, 1983, 247 pp, \$9.95