

# Diagnosis of Upper-Abdominal Infections by In-111 Labeled Leukocytes with Tc-99m Colloid Subtraction Technique

Mechelien H. Rövekamp,\* E. A. van Royen, S. C. C. Reinders Folmer, and J. B. van der Schoot

*Academic Hospital, University of Amsterdam, Amsterdam, The Netherlands*

**In 65 patients suspected of upper-abdominal inflammatory disease, indium-111 leukocyte scintigraphy was combined with a Tc-99m(Sn)colloid scan by computer-assisted subtraction. In 84% of these cases, a definite diagnosis would not have been possible without this method of subtraction. Accuracy was found to be 80%, sensitivity 93%, and specificity 59%. False-positive results were due either to noninfectious inflammatory lesions with accumulation of leukocytes or to some pitfalls in the subtraction technique itself.**

**J Nucl Med 24: 212-216, 1983**

Early and accurate diagnosis in patients suspected of upper-abdominal inflammation is of great importance for optimal management (1-3). Conventional radiographs, gallium-67 scintigraphy, and combined liver/lung radionuclide imaging have been used in the diagnosis of subphrenic abscess, but with inconsistent results (4-10). Recently, scintigraphy with autologous leukocytes labeled with indium-111 oxinate has been more successful in diagnosing intra-abdominal inflammatory processes than with Ga-67 (11-14). However, the normal uptake of In-111-labeled leukocytes in the liver and spleen impairs the primary detection of upper-abdominal lesions (15-16).

In subphrenic abscess, the subtraction of a Tc-99m(Sn)colloid image from one made with Ga-67 citrate was found by Damron et al. (17-19) to enhance diagnostic effectiveness. We have explored the use of a similar procedure, with substitution of In-111 leukocytes for the primary image, in upper abdominal inflammatory disease.

Received Oct. 26, 1982; revision accepted Nov. 2, 1982.

For reprints contact: E. A. van Royen, Dept. of Nucl. Med., University Hospital, Wilhelmina Gasthuis, 1e Helmersstraat 104, 1054 EG Amsterdam, The Netherlands.

\* Present address: Dept. of Pediatric Surg., Sophia Kinderziekenhuis, Rotterdam, The Netherlands.

## METHODS

Leukocytes were prepared from 50 ml peripheral blood as described previously (16) and labeled with 300-500  $\mu$ Ci of indium-111 oxinate<sup>†</sup>. Scintigrams were performed 20 to 24 hr after injection of the In-111-labeled leukocytes. A large-field gamma camera was used, with a medium-energy parallel-hole collimator and interfaced on line with a computer.

The pulse-height analyzers were first set on the 173- and 247-keV In-111 peaks, both with 20% windows, and 10-min scintigrams were obtained. Then, with the patient in exactly the same position, the pulse-height analyzer was set to the 140-keV Tc-99m peak. Counts were acquired for 2 min to monitor the scatter from In-111 into the Tc-99m window. Next, 1-2 mCi of Tc-99m(Sn)colloid was injected and, after 5 min, another 2-min scintigram was made with the window set for 140 keV. It is essential that the patient remains in the same position during the whole 10-15 min acquisition period for all three images of liver and spleen.

Subtraction images were obtained, essentially as described by Buraggi et al. (20) for Ga-67 citrate and Tc-99m(Sn)colloid. To start with, the Tc-99m(Sn)colloid scan was corrected for the In-111 crosstalk by simple subtraction of the second scan (In-111 in the Tc-99m window) from the Tc-99m image. Secondly, before

	All cases			Confirmed at operation, needle aspiration, or autopsy			
	D+	D-		D <sup>†</sup> +	D-		
S*+	43	12	55	S+	27	5	32
S-	3	17	20	S-	3	4	7
	46	29	75		30	9	39
Sensitivity P(S+D+) =				27/30 = 0.90			
43/46 = 0.93							
Specificity P(S-D-) =				4/9 = 0.44			
17/29 = 0.59							
* S = Scan finding.							
† D = Final diagnosis.							

subtraction, an almost homogeneous region of interest was chosen over the liver, since in colloidal liver scintigraphy abnormalities are revealed as heterogeneity or focal decrease in count densities. Counts within this region was calculated for both the In-111 and corrected Tc-99m scan. From these a normalization factor was calculated, such that, upon subtraction of the corrected Tc-99m scan from the primary In-111 scan, the counts in normal regions of the liver would fall to zero. In general, this factor was found to be about 0.5. Following the subtraction procedure, the final image was further enhanced by choosing various upper and lower threshold levels. In the absence of focal In-111 accumulation, a uniform, virtually zero image of the liver was produced. Unprocessed original and subtraction images were then photographed from the video display of the computer.

Later all In-111 leukocyte scintigrams were reviewed separately and compared with the Tc-99m(Sn)colloid liver and spleen images without subtraction.

#### PATIENTS AND MATERIALS

Seventy-five scintigrams were performed in 65 patients, who on clinical grounds were suspected of having an upper abdominal inflammatory process. No definite diagnosis had been made in any of them before scintigraphy. Indications for scintigraphy were unexplained

fever or symptoms suggesting an upper-abdominal inflammatory process in 61 patients, 45 of whom were in a postoperative phase. In the remaining four patients, scintigrams were performed to confirm or exclude the inflammatory origin of focal lesions detected by earlier Tc-99m liver and spleen scans, ultrasonography, computerized tomography, or endoscopic retrograde cholecysto- and pancreaticography.

Twenty-eight scintigraphic results were verified at surgery. In nine cases, a needle aspiration was done. Autopsy was performed twice. The remaining 36 scintigrams were related to the clinical follow-up.

#### RESULTS

**Negative scintigrams.** Twenty scintigrams performed in 17 patients showed no focal activity after subtraction. Seven scintigrams (six patients) were followed by either surgical exploration or needle aspiration. Three of these (two patients) had to be considered as false negatives, because an infectious lesion was demonstrated by laparotomy and needle aspiration respectively. The remaining 13 scintigrams in 11 patients were related to clinical followup. All 11 patients survived and none showed any evidence of infection over 20 wk. The final result in this group was that 17 of the 20 scintigrams were clearly true negative (Table 1).

**Positive scintigrams.** Fifty-five scintigrams performed in 48 patients showed focal activity within or outside of liver and spleen areas after subtraction. Scintigraphic information from 32 scintigrams in 29 patients<sup>†</sup> was verified by subsequent surgical exploration (20 patients), needle aspiration (7), or autopsy (2). The scintigraphic impression of inflammatory process was confirmed in 25 patients (27 scans): in 18 patients (20 scans) by surgery, in five by needle aspiration, and in two at autopsy (Table 2, Figs. 1-3). In four patients (five positive scans) the absence of inflammation was confirmed by surgery in two patients (three scans) and by needle aspiration in the other two (Table 3). Only clinical followup was available for the remaining 20 patients (23 scans), all of whom survived. Fourteen (16 scintigrams) showed a course highly characteristic for intra-abdominal in-

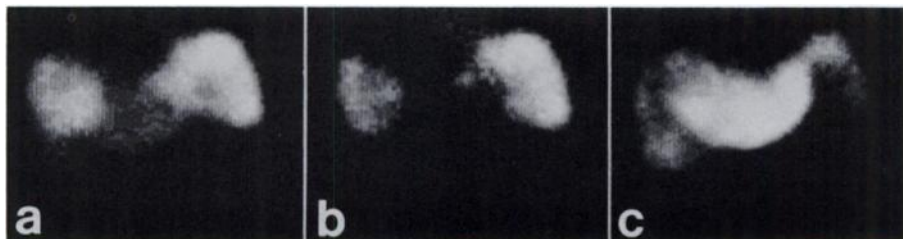

FIG. 1. (a) Indium-111 leukocytes. (b) Subtraction of liver area. (c) Tc-99m(Sn)colloid. Case 1. A 56-yr-old male patient, with recurrent sepsis after closure of a gastric perforation some weeks before. Given this history, a sub-hepatic or lesser-sac abscess was suspected. However, subtraction scintigraphy correctly indicated subphrenic abscess. Dorso-lateral surgical drainage was then performed, with scan findings determining the site of surgical approach.

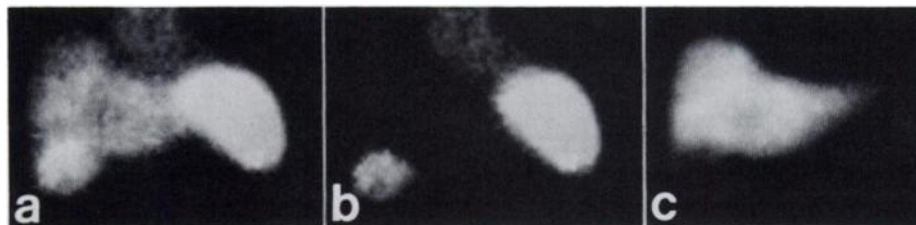


FIG. 2. (a) Indium-111 leukocytes. (b) Subtraction of liver area. (c) Tc-99m(Sn)colloid. Case 2. After a choledocho-duodenostomy for chronic pancreatitis, a 58-yr-old woman presented with upper-abdominal tenderness, fever, and right diaphragmatic elevation of the chest radiograph. Subhepatic or subphrenic abscess was suspected. Subtraction scintigraphy showed confined area of increased activity at right lobe of liver. Empyema of gallbladder was thought likely and was confirmed at subsequent laparotomy.

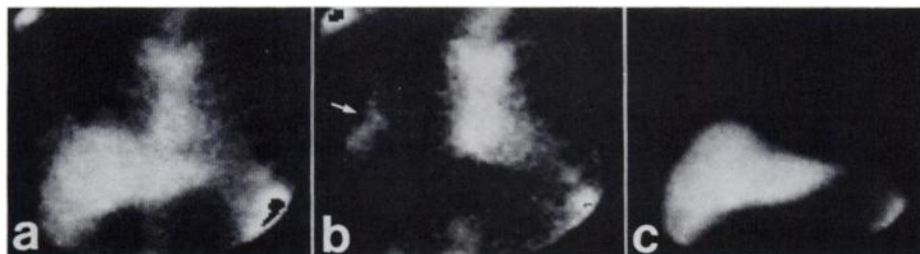


FIG. 3. (a) Indium-111 leukocytes. (b) Subtraction of liver area. (c) Tc-99m(Sn)colloid. Case 3. A 42-yr-old male patient, with pleural effusion by chest radiograph. Lung-liver scintigraphy was normal. Subtraction scintigraphy showed focal activity, more likely in pleural than in subphrenic space. Drainage by high costal resection was carried out.

flammation (Fig. 4) and six (seven scintigrams) did not. In four of the latter group, some inflammatory response, rather than clearly localized inflammation, could be deduced from the clinical course and findings (Table 3). Adding these figures together, 43 true-positive scintigrams were obtained out of a total of 55 showing focal accumulation.

Sensitivity and specificity are given in Table 1.

In surgically proven cases the results as to sensitivity

and specificity did not differ significantly from the results obtained in the group as a whole (sign test).

#### DISCUSSION

The overall scan accuracy obtained in our group of patients was 80% (Table 1). Three false-negative studies accounted for a 93% sensitivity. In one patient, a small infected hematoma was found at laparotomy. In a second patient, two scans failed to demonstrate an infected hepatic cyst. It is known that intrahepatic cyst—and even abscesses—can be encapsulated in a rather thick wall, which may interfere with the migration of leukocytes into the lesion (21,22).

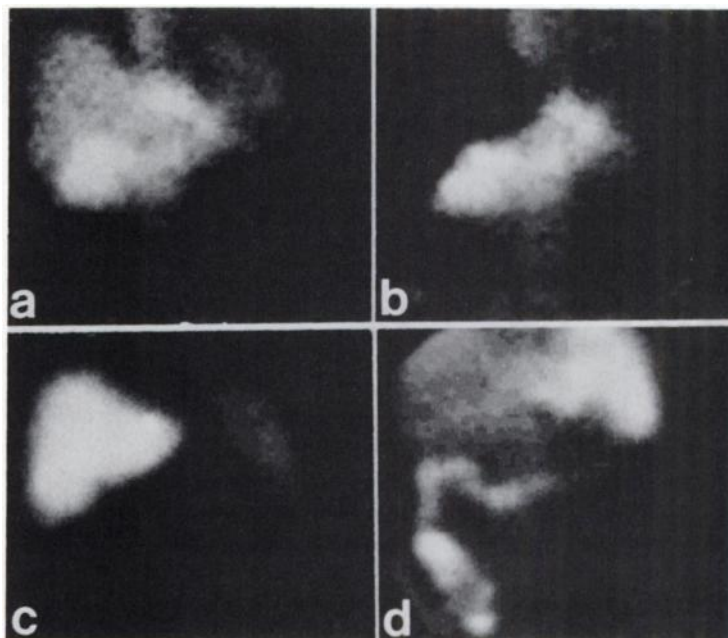
Specificity was found to be 59%. We believe that this

TABLE 2. LOCATION OF INFLAMMATORY LESIONS DIAGNOSED IN 43 TRUE-POSITIVE SCANS.

Lesions	No.	Confirmed at operation, needle aspiration, or autopsy
Subphrenic left	9	5
Subphrenic right	4	3
Subhepatic	11	7
Pancreas	8	4
Intra-hepatic	2	1
Gallbladder	3	2
Pleural sinus right	1	1
Suprarenal	1	1
Right lower quadrant	1	1
Left lower quadrant	2	1
Infected wound	1	1
	43	27

TABLE 3. NONINFLAMMATORY LESIONS DIAGNOSED IN NINE OF THE 12 FALSE-POSITIVE SCANS.

Lesions	No.	Confirmed at operation or by needle aspiration
Intrahepatic metastases or tumor	4	3
Liver-hilus metastases	1	—
Gallbladder carcinoma	1	1
Bile fistula	1	1
Retroperitoneal haematoma	1	—
Colitis	1	—
	9	5



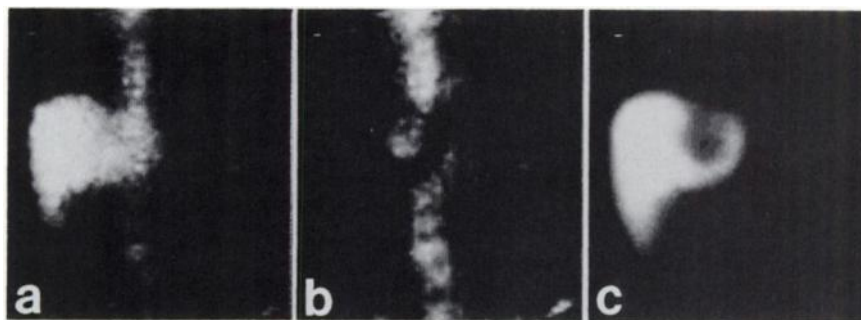
**FIG. 4.** (a) Indium-111 leukocytes. (b) Subtraction of liver area. (c) Tc-99m(Sn)colloid. (d) Repeated scan. Case 4. After endoscopic papillotomy, a 70-yr-old woman presented with upper-abdominal tenderness. Ultrasound was inconclusive. Computerized tomography revealed enlarged pancreas with multiple cysts. Subtraction scintigraphy revealed increased activity over whole pancreatic area, with maximum activity in cephalic part. After conservative treatment and clinical improvement, repeat scan showed less activity in pancreatic area and obvious colonic uptake. Impression: spontaneous drainage into GI tract.

low specificity results because leukocytes are also involved in noninfectious inflammatory reactions to mechanical or chemical stimuli. Table 3 shows the final diagnosis made in nine of the 12 false-positive scintigrams. Some of these lesion—such as a fistula of the biliary tract, a hematoma, and colitis—are known to be accompanied histologically by a mild leukocyte reaction. Indeed, the intensity of accumulated activity observed in these scintigrams was less, in most cases, than that observed in cases of true localized inflammation.

In this series, none of the false-positive scintigrams resulted in unnecessary surgical exploration.

This subtraction technique is based on the assumption that similar distribution of both tracers occurs in healthy liver and spleen tissue, resulting in complete or nearly complete disappearance of the activity in the normal areas after subtraction. In general, a normalization factor of approximately 0.5 was found for the liver area of the Tc-99m(Sn)colloid scan. A different normalization factor had to be used for the spleen. This could be

due to a varying number of labeled platelets or red blood cells contaminating the leukocyte preparation, or to preferential accumulation of labeled leukocytes in the spleen. It must be realized that the final subtraction image is influenced by the difference in emission energy between the two radionuclides, the resulting difference in modulation transfer function, and the difference in background activity. These three factors are a potential source of false subtraction images. The energy difference will result in a difference in attenuation of the radiation, and must be considered especially in cases of intrahepatic or intrasplenic lesions. If a lesion is deep, radiation will be absorbed more from Tc-99m than from In-111, and the subtraction may lead to a false-positive diagnosis. This could account for the false positives in patients with intra-hepatic metastases or tumor (Table 3, Fig. 5). The second factor proved to be limited under the conditions studied, since with our collimator the line spread function was about the same for both radionuclides. Blood background will differ between In-111 leukocytes and



**FIG. 5.** False-positive scintigram: (a) Indium-111 leukocytes. (b) Subtraction of liver area. (c) Tc-99m(Sn)colloid. Case 5. A 68-yr-old woman with history of cholangitis. Earlier liver scan and endoscopic retrograde cholangiography demonstrated a left-sided hepatic process. Subtraction scintigraphy showed focal activity with low intensity in lesion in question. Possibility of old abscess was considered. Exploratory laparotomy revealed leiomyosarcoma with central necrosis.

Tc-99m colloid. The final effect is probably limited since with In-111 the blood activity declined rapidly, falling to less than 30% after 24 hr. Finally, some movement of the patient during scintigraphy could also cause an incomplete disappearance of activity. In three scintigrams subsequently classified as false positives, incomplete disappearance of activity at the cranial or lateral margins of the spleen was observed, probably due to this effect.

#### CONCLUSION

In this series of patients with suspected upper-abdominal inflammatory processes, scintigraphy with In-111 leukocytes, with Tc-99m(Sn)colloid subtraction provided a sensitive diagnostic procedure. Critical scrutiny of clinical signs and symptoms, together with the scintigraphic results, can overcome most of the problems posed by the rather low specificity of the procedure.

In our view, this subtraction technique provides a relatively simple, noninvasive and reliable means of investigation in patients with upper abdominal inflammatory disease.

#### FOOTNOTES

† Manufactured by Byk-Mallinckrodt C.I.L. B.V., Petten, The Netherlands.

‡ In one patient two positive scans performed 5 wk apart, were followed by a surgical followup (false pos) and clinical followup (true pos). Therefore the total number of patients will be 48.

#### REFERENCES

- HALLIDAY P, HALLIDAY JH: Subphrenic abscess: A study of 241 patients at the Royal Prince Edward Hospital, 1950-1973. *Br J Surg* 63:352-366, 1976
- DECOSSE JJ, POULIN TL, FOX PS, et al: Subphrenic abscess. *Surg Gynecol Obstet* 138:841-846, 1974
- FLEISCHER-DJOLETO O, HANNA SS, JIRSCH DW: Surgical management of subphrenic abscess. *Can J Surg* 22: 85-87, 1979
- SANDERS RC, JAMES AE, FISCHER K: Correlation of liver scans and images with abdominal radiographs in perihepatic sepsis. *Am J Surg* 124:346-352, 1972
- LAVENDER JP, LOWE J, BARKER JR, et al: Gallium 67 citrate scanning in neoplastic and inflammatory lesions. *Br J Radiol* 44:361-366, 1971
- FORGACS P, WAHNER HW, KEYS TF, et al: Gallium scanning for the detection of abdominal abscesses. *Am J Med* 65:949-954, 1978
- HOPKINS GB, MENDE CW: Gallium-67 and subphrenic abscesses—Is delayed scintigraphy necessary? *J Nucl Med* 16:609-611, 1975
- BROWN DW: Combined lung-liver radioisotope scan in the diagnosis of subdiaphragmatic abscess. *Am J Surg* 109: 521-525, 1965
- BRIGGS RC: Combined liver-lung scanning in detecting subdiaphragmatic abscess. *Semin Nucl Med* 2:150-156, 1972
- WHITE PH, HAYES M, BENFIELD JR: Combined liver-lung scanning in the management of subdiaphragmatic abscess. *Am J Surg* 124:143-148, 1972
- THAKUR ML, COLEMAN RE, WELCH MJ: Indium-111-labelled leukocytes for the localization of abscesses: Preparation, analysis, tissue. Distribution and comparison with Gallium-67 citrate in dogs. *J Lab Clin Med* 89:217-228, 1977
- MCAFEE JG, GAGNE GM, SUBRAMANIAN G, et al: Distribution of leukocytes labeled with In-111 oxine in dogs with acute inflammatory lesions. *J Nucl Med* 21:1059-1068, 1980
- ASCHER NL, FORSTROM L, SIMMONS RL: Radiolabelled autologous leukocyte scanning in abscess detection. *World J Surg* 4:395-402, 1980
- LANTIERI RL, FAWCETT HD, MCKILLOP JH, et al: Ga-67 or In-111 white blood cell scans for abscess detection: A case for In-111. *Clin Nucl Med* 5:185-188, 1980
- ASCHER NL, AHRENHOLZ DH, SIMMONS RL, et al: Indium-111 autologous tagged leukocytes in the diagnosis of intraperitoneal sepsis. *Arch Surg* 114:386-392, 1979
- RÖVEKAMP MH, HARDEMAN MR, VAN DER SCHOOT JB, et al: <sup>111</sup>Indium-labelled leukocytes scintigraphy in the diagnosis of inflammatory disease—First results. *Br J Surg* 68:150-153, 1981
- BEIHN RM, DAMRON JR, HAFNER T: Subtraction technique for the detection of subphrenic abscesses using <sup>67</sup>Ga and <sup>99m</sup>Tc. *J Nucl Med* 15:371-373, 1974
- DAMRON JR, BEIHN RM, SELBY JB, et al: Gallium-technetium subtraction scanning for the localization of subphrenic abscess. *Radiology* 113:117-122, 1974
- DAMRON JR, BEIHN RM, DELAND FH: Detection of upper abdominal abscesses by radionuclide imaging. *Radiology* 120:131-134, 1976
- BURAGGI GL, LAURINI R, RODARI A, et al: Double-tracer scintigraphy with <sup>67</sup>Ga-citrate and <sup>99m</sup>Tc-sulfur colloid in the diagnosis of hepatic tumors. *J Nucl Med* 17:369-373, 1975
- MARTIN EC, KARLSON KB, FRANKUCHEN E, et al: Percutaneous drainage in the management of hepatic abscesses. *Surg Clin North Am* 61:157-167, 1981
- GOONERATNE NS, IMARISIO JJ: Decreased uptake of <sup>67</sup>Gallium citrate (<sup>67</sup>Ga) by a bacterial hepatic abscess. *Gastroenterology* 73:1147-1148, 1977