

INVESTIGATIVE NUCLEAR MEDICINE

Imaging of Melanoma with I-131-Labeled Monoclonal Antibodies

Steven M. Larson, Joseph P. Brown, Peter W. Wright, Jorge A. Carrasquillo, Ingegerd Hellström, Karl Erik Hellström

US Veterans Administration Medical Center, University of Washington, and Program of Tumor Immunology, Fred Hutchinson Cancer Research Center, Seattle, Washington

Mouse monoclonal antibodies and Fab fragments specific for p97, a melanoma-associated antigen, were used to image metastatic human melanoma. Preclinical studies in athymic mice showed antigen-specific uptake in melanoma xenografts, and toxicity tests in rabbits gave no evidence for tissue damage after injection of up to 100 times the amount of antibody used in humans. Six patients received 1 mg labeled antibody, and one patient received 1 mg of labeled Fab. No toxic side effects were observed. All of the six patients had positive scans, visualizing 22 of 25 (88%) of lesions larger than 1.5 cm. In tumors from two patients, greater uptake of p97-specific, versus control IgG and Fab, respectively, was documented by biopsy. Antibodies to mouse immunoglobulin appeared in three patients receiving 1 mg or more of radiolabeled mouse antibody.

J Nucl Med 24: 123-129, 1983

Radiolabeled antibodies specific for tumor-associated antigens promise to improve diagnostic imaging of tumors. External scintigraphy has been used to image human cancers, using antibodies specific for carcinoembryonic antigen (1-5), alpha-fetoprotein (6,7), human chorionic gonadotropin (8), a kidney carcinoma antigen (9,10), and ferritin (11). Initial reports cited a diagnostic accuracy of about 85% (2,7). Image-enhancement techniques (12) and absorption of xenoserum (13) increase sensitivity. Nonetheless, the amount of radiolabeled antibody localized in the tumor has been low compared with the blood and other organs, particularly the liver, thus limiting the clinical utility of present methods (4). Furthermore, much of the published work lacks controls in which nonspecific immunoglobulin was used, control preparations often consisting of labeled serum albumin. Such studies leave it unclear whether the observed tumor localization was antigen-specific.

The antibodies used in the studies described above were obtained from antisera. By using monoclonal an-

tibodies (14), it should be possible to study the localization of an antibody that is of well-defined specificity and is available in unlimited amounts. In this report we describe the use of radiolabeled monoclonal antibodies for the imaging of human malignant melanoma. We have used mouse antibodies, and Fab fragments, specific for p97, a 97-kilodalton glycoprotein present on the surface of cells from human melanoma biopsies (15-17).

METHODS

Radiolabeled monoclonal antibodies. Five different antibody preparations were used. Two antibodies were specific for p97 (17): Antibody 8.2 (IgG1) and Antibody 96.5 (IgG2a), and three control immunoglobulin preparations were used, IgG1 and IgG2a purified from serum of normal BALB/c mice, and antibody 1.4 (IgG1, specific for murine leukemia virus gp70; J. P. Brown, unpublished work). Antibodies were purified from the ascites fluids of mice bearing hybridoma ascites tumors, by affinity chromatography on protein A-Sepharose as described (17). Fab fragments were prepared as described (16). The affinity for binding of both 8.2 and 96.5 to p97 antigen was measured and was found to be

Received May 24, 1982; revision accepted Oct. 26, 1982.

For reprints contact: Steven M. Larson, MD, Nuclear Medicine NM-115, Veterans Medical Center, 4435 Beacon Ave. So., Seattle, WA 98108.

in the range of 10^{10} LM for both antibodies. Affinity for the Fab preparations appears to be in a similar range.

Purified antibody (1 to 3 mg) was labeled with 3–6 mCi I-131 in 0.5–2 ml phosphate-buffered saline, pH 7.2 (PBS), containing 20 $\mu\text{g}/\text{ml}$ chloramine-T (17). The labeled protein was separated from reagents by gel filtration on a 5-ml column of Sephadex G-25 superfine that had been treated with 1 ml 5% human serum albumin (HSA) and equilibrated with 10 ml PBS. The labeled antibody was adjusted to a volume of 5 ml with saline, 5 ml 25% HSA was added, and the solution was sterile-filtered. The preparation was also tested for sterility and records were kept. No contamination was observed in any of the preparations.

The choice of specific activity for the radiolabeled antibody for human studies (about 1 mCi/mg) was based on previous human studies (data not shown), which showed that for higher specific activities (20 mCi/mg), and smaller amounts of total antibody administered (30 to 50 μg per patient), most of the radioactivity was complexed to circulating antigen and cleared into the liver. At the small amounts of antibody, little if any tumor uptake was observed.

Pyrogen tests. All solutions were prepared with USP pyrogen-free water and were tested for pyrogenicity using *Limulus amoebocyte lysate*. Purified antibodies were tested at a final concentration of 50 $\mu\text{g}/\text{ml}$ and radiolabeled preparations were tested before the addition of HSA.

Assay for antibody to mouse immunoglobulin. Patient samples were assayed for human antibodies against mouse immunoglobulin on blood drawn for a baseline before administering the radiolabeled anti-p97 antibody for imaging. Test sample (10 μl) was incubated with 10 μl I-125-labeled mouse IgG1 (10^4 cpm) for 30 min at 20°C . *S. aureus* (10 mg) was added in 1 ml of 20 mM Tris-HCl buffer, pH 8.0, containing 100 mM NaCl, 1 mM EDTA, and 0.5% Nonidet P40 (TNEN). After a further 5-min incubation, the bacteria were washed three times with 10 ml TNEN and counted for I-125. A comparison was made between the test sample and a control serum that did not contain anti-mouse antibodies. A "positive" that was more than twice the control sample was taken to be I-125 bound to bacteria.

Assay for binding of labeled antibody to melanoma cells. In order to assay the degree of antigen reactivity in labeled preparations or patient samples, SK-MEL 28 melanoma (15) cells (2 million) were suspended in 100 μl test sample. After 30 min at 0°C , the cells were washed three times with 10 ml PBS and counted for I-131. The results were expressed as percent of total added radioactivity that was cell bound. It should be noted that the radiolabeled antibody preparations used for imaging were between 25–35% bound to the cellular fraction. In this assay system, a maximum binding with I-125-labeled anti-p97 of up to 60% has been observed. This

suggests that although some damage had occurred during iodination, a significant fraction of the antibody retained the ability to bind to p97 antigen.

Animal studies. Athymic mice bearing xenografts of human melanoma received I-131-labeled Antibody 96.5 at 4 $\mu\text{g}/\text{g}$ (5 μCi per mouse), and were killed at 1 to 7 days after injection. Radioactivity was assayed in blood, tumor, liver, lung, spleen, lymph nodes, kidney, stomach, brain, and heart muscle. Some animals also simultaneously received I-125-labeled IgG2a purified from mouse serum.

Toxicity studies were performed in specific pathogen-free New Zealand rabbits* weighing ~ 2 kg. Unlabeled Antibody 96.5 in sterile saline was injected by the ear vein. For the acute study, doses of 0.14, 1.4, and 14 mg/kg were tested (3 animals each) corresponding to 10, 100, and 1,000 times the maximum dose used in humans (MHD). A control group of three animals received sterile saline. The rabbits were killed 24 hr later, and gross and microscopic examinations were performed on brain, liver, spleen, lung, kidneys, and heart. For subacute toxicity tests, two animals received 140 $\mu\text{g}/\text{kg}$ (ten times MHD) on each of 10 consecutive days and were killed and examined 24 hr later.

Human studies. Patients with widespread, inoperable melanoma were selected for study after they had given informed consent. In most cases all conventional forms of therapy had failed. All patients had significant amounts of p97 on their tumors, as measured by radioimmunoassay (16). Thyroid uptake was blocked with 10 drops SSKI twice per day, 30 to 60 min before injection and for 14 days thereafter. Baseline laboratory studies were obtained before injection and were repeated at 48 hr, including hemoglobin, WBC count, platelets, serum creatinine, bilirubin, LDH, SGOT, alkaline phosphatase, serum complement, and urinalysis. Before intravenous injection, 100 μl (20 μg) of the labeled antibody preparation was tested intradermally. If the skin test was negative, the antibody or antibodies were each injected over a 2-min period. Serial blood samples were drawn at 5, 15, 30, 45, 60, 90, and 120 min, and at 24 and 48 hr. The plasma samples, standards, and biopsies (when available) were assayed for radioactivity in a gamma counter. Images were obtained at 48 hr with a gamma camera with medium-energy collimator using a Tc-99m HSA (1 mCi) blood-pool subtraction method (12) without injection of pertechnetate. Data processing was performed with a computer.

RESULTS

Animal studies. Radiolabeled antibody 96.5 was injected into athymic mice bearing subcutaneous grafts of human melanoma, KZ2, which expresses large amounts of p97 (16). The dose was 80 $\mu\text{g}/\text{mouse}$, approximately ten times the highest human dose subsequently used. No toxicity was evident, and gross in-

TABLE 1. SUMMARY OF PATIENT DATA

Pt.	Date	Purpose	Ab Preparation*	Findings
1:R.L.	2/2/81	Image tumor uptake	Ab 8.2	+ Tumor uptake in lung bases & liver lesion, 3 of 6 lesions found on autopsy (2/19/81) have + scans (see Fig. 1 and text for Case 1).
2:J.M.	a. 1/2/81	Image tumor uptake	Ab 8.2	3 of 4 known metastases had + uptake. Positive uptake in lesions, subcutaneous abdominal wall, left lung, and left hilum; negative subcutaneous lesion in skull.
	b. 1/17/81	Repeat of above	Ab 8.2	Much liver uptake, less in tumor. Antibodies to mouse immunoglobulin detected. Rapid clearance of labeled antibody from blood.
3:G.A.	2/17/81	Image tumor uptake	Ab 8.2	+ uptake in 2 of 2 sites of recurrent melanoma in leg.
4:Je.M.	a. 3/23/81	Image tumor uptake	Ab 8.2	Scan + in 4 of 6 known metastases. Positive scan in 3 intrathoracic and 1 subcutaneous lesion on back; 2 subcutaneous lesions (skull and L upper arm) were negative.
	b. 4/14/81	Image tumor uptake	Ab 8.2	Much liver uptake and rapid blood clearance. Antibodies to mouse immunoglobulin detected.
5:M.R.	4/14/81	Image tumor uptake and compare uptake in biopsies with that of I-125-labeled nonspecific IgG1.	Ab 8.2	+ uptake in 4/4 lesions in the right leg (see Fig. 2 and text, Case 2). Higher relative uptake of specific antibody in tumor biopsies (Table 2).
6:B.O.	7/14/81	Image tumor uptake and compare uptake in biopsies with that of I-125 labeled nonspecific Fab 1.4.	Fab 8.2	Scan + in 6 of 6 sites, in left cervical area and submandibular area. Much liver uptake (see text, Case 3). Higher relative uptake of specific Fab fragment in tumor biopsies (Table 2).

* Each patient received 0.7–2.5 mCi.

spection of the lungs, kidney, brain, gut, and liver revealed no abnormalities.

Biodistribution of injected antibody was studied at 6 hr and 1, 2, and 7 days after injection. Clearance of I-131 from blood was biphasic, 70% being cleared with a half-time of about 1 day and the remainder with a half-time of ~7 days. Tumors showed a progressive increase in uptake, reaching 8 to 15% of the injected dose per gram at 2 days. Other organs paralleled blood, with initially high values comparable to or exceeding the concentration in tumor at 6 hr, then falling to low values at 7 days. At 7 days, tumor-to-organ concentration ratios were: brain 23, muscle 13, stomach 6.9, spleen 3.9, liver 3.7, kidney 3.2, lymph node 3.0, lung 2.2. The tumor-to-blood ratio was 0.8 (three animals per group).

To assess further the immunological specificity of tumor uptake, we compared uptake of I-131-labeled Antibody 96.5 with I-125-labeled IgG2a purified from normal mouse serum. Uptake of Antibody 96.5 was

comparable to the values given above. The ratio of Antibody 96.5 to control antibody in tumor increased progressively with time: 6 hr 1.4, 4 days 3.5, 6 days 5.0. For organs, however, the ratio was close to unity. For example, at 6 days the ratios of specific to control antibody were: stomach 2.0, brain 1.6, lymph node 1.5, liver 1.2, lung 1.2, kidney 1.2, spleen 1.0, muscle 0.7. Thus, in athymic mice Antibody 96.5 was not concentrated in normal tissues relative to normal IgG2a.

Histological examination of tissues in pathogen-free rabbits showed no changes compared with controls in the subacute studies at 10 times MHD, nor in the acute studies at 10 and 100 times MHD. At 1,000 times MHD a mild, transient interstitial inflammatory change was seen, characterized by increased numbers of macrophages around blood vessels in the lungs.

Melanoma patient studies. Six melanoma patients were imaged with I-131-labeled anti-p97 antibody or Fab fragments to produce a total of 8 scans (Table 1).

TABLE 2. BIODISTRIBUTION OF ANTI-p97 AND CONTROL ANTIBODY PREPARATIONS.*

	Whole antibody (Case 5)		Fab fragment (Case 6)	
	Specific†	Control‡	Specific†	Control§
Blood	7.1	7.9	.3	.9
Tumor 1	10.4	5.6	1.4	.4
Tumor 2	5.7	2.8	1.1	.3
Adjacent tissue	1.4	2.4	.4	.3

* Percent injected dose per gram of tissue times 1000, at 72 hours after injection.

† Antibody 8.2 (IgG1).

‡ IgG1 from normal mouse serum.

§ Antibody 1.4 (IgG1).

Four patients were studied once, two patients twice. One patient was studied with Fab fragments, and the rest of the images were performed with whole antibody. The amount of radioactivity ranged from 1 to 2.5 mCi per patient, and the total amount of antibody injected was 1 mg. Each patient received an intradermal test dose of the radiolabeled immunoglobulin preparation before intravenous injection. Only one skin reaction was observed, and the positive reaction was shown to be due to the carrier HSA. No acute reactions and no statistically significant changes in blood chemistry attributable to antibody injection were observed during the week after administration of antibody.

Studies with Anti-p97 antibody or Fab fragment at 1 mg per patient. Five patients received 1 mg of I-131-labeled Antibody 8.2, and one patient received 1 mg of I-131-labeled Fab 8.2. In all six patients there was positive uptake in documented melanoma in vivo. For those receiving whole antibody, blood clearance of radiolabeled antibody was biphasic, with 90% of the antibody cleared with a half-life of 31 ± 5 (20 to 50) hr, and (19%) more rapidly, with a half-life of 50 ± 8 (35 to 75) min. In these patients, an estimated 50% of the radioactivity was taken up by the liver. In the patient who received Fab 8.2, clearance was much more rapid, with $t_{1/2}$ of 20 min. About 25% was cleared even more rapidly (within a few minutes) into the liver. In the patient who received I-131-labeled Fab 8.2, uptake was noted in 6 of 6 metastatic tumor deposits in the neck. Among 26 documented and two clinically presumed metastases, 22 (80%) were positive. Negative metastases were either less than 1.5 cm in diameter or adjacent to highly vascular areas of high uptake (spleen, heart, stomach). Of lesions greater than 1.5 cm, 22 of 25 (88%) showed positive uptake. There were no false positives. Note that since the patients were not rigorously staged in all instances, we interpret the high detection rate (88%) for lesions greater than 1.5 cm as an indication that the technique shows promise, and not as an absolute figure for its accuracy.

In two patients, specific tumor and tissue uptakes were compared (see Cases 2 and 3 below, and Table 2).

The following three cases are illustrative:

Case 1: Positive antibody scan in a clinically unsuspected hepatic metastasis. R.L. (Patient 1 in Table 1), a 28-yr-old man, underwent a right nephrectomy, 18 mo before admission, for a renal mass diagnosed as amelanotic melanoma, primary unknown. Eight months before admission, bilateral pulmonary metastases were discovered. After a series of pulmonary infections and progressive weight loss, the patient was admitted to the hospital. An antibody scan was performed with injection of 1 mg Antibody 8.2, labeled with 1 mCi I-131. Scans of the chest and upper abdomen were obtained 48 hr after injection, and a PA chest film is shown for comparison (Fig. 1). There was marked bilateral uptake in the lung masses (double arrows) and in an area in the mid portion of the right lobe of the liver (single arrow). Uptake was also noted in the stomach, but most probably this was iodide liberated by breakdown of the I-131-labeled antibody, since the background correction process used (12) corrected for the blood-pool activity but not for free iodide. Six days after injection, the patient died, with progressive tumor and pneumonia. At autopsy, a solitary metastasis, 4 cm in diameter, in the lower right

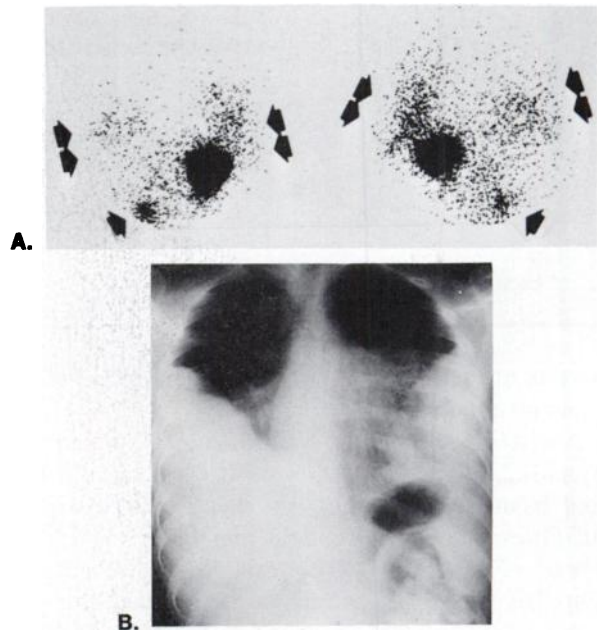


FIG. 1. Patient R.L. (No. 1 in Table 1). (A) Anterior (left) and posterior (right) scintigrams of chest. Images have been corrected for blood-pool activity (12). There is prominent uptake of radioactive antibody in lung (double arrows) and in a discrete focal area at right lower border of liver (single arrow). Largest area of uptake, in left upper quadrant, is in stomach, which concentrated iodide liberated by breakdown of the I-131-labeled IgG. Scintigrams obtained 48 hr after injection. (B) PA chest film. Obtained at time of 48-hr scintigram shown in A. There is massive replacement of lung parenchyma inferiorly by tumor masses. Associated collapse, fluid, and possibly pneumonia, make it difficult to define precise boundaries of pleural-based masses.

lobe of liver was found to have 2.9 times the I-131 content of the uninvolved liver tissue. The location of this liver lesion corresponded to the site of positive uptake on the scan. Two large pleural-based tumors (about $7 \times 10 \times 10$ cm) were found on the lower lateral surfaces of the parietal pleura. Surrounding the masses superiorly, medially and posteriorly there was considerable consolidation and inflammation. The positive uptake on scan corresponded to the more lateral and inferior tumor masses rather than the more central and perihilar inflammatory tissue. Radioactivity in normal lung and in metastatic lesions in the lung was approximately equal on a weight basis. However, since the lung tissues are expanded about four-fold in vivo, the actual concentration ratio, on a volume basis, between the tumor and the surrounding lung would be ~ 4 . Three other lesions were not seen on the scan: a thyroid nodule, which was below the resolution limits of the scanning technique, and a lesion in the tip of the left lobe of liver, which was obscured by the stomach. A third lesion in the spleen was not visualized. Of the normal tissues measured, the liver showed the highest uptake.

Case 2: Antigen-specific uptake of anti-p97 antibody by metastatic melanoma. To determine whether tumor uptake of antibody was specific for p97, experiments were performed following the technique of Pressman (18). M.R., a 50-yr-old female (Patient 5 in Table 1) with widespread melanoma, was found to have metastases to the right popliteal fossa at 3 yr after wide resection of a primary melanoma on the right lower leg, with smaller subcutaneous metastases extending along the posterior lymphatic chain up the thigh. The patient received two immunoglobulin preparations of the IgG1 subclass: I-131-labeled Antibody 8.2 and I-125-labeled IgG1 from normal mouse serum (1 mg each labeled with 1 mCi). Blood clearance and volumes of distribution were very similar for the two preparations. An image of the right posterior popliteal fossa was obtained at 48 hr (Fig. 2). Uptake in the tumor deposits was clearly visible in the unprocessed images. In addition to the uptake in the right popliteal fossa, there was uptake in smaller lesions higher up in the posterior thigh. Using a computer attached to the gamma camera, we compared count ratios for normalized areas over the tumor and corresponding ratios over nontumor-bearing areas on the 48-hr unprocessed camera images. The ratio of uptake in the tumor region to the contralateral popliteal fossa was 2.5, and the ratios of the tumor region to regions above and below the tumor were 1.9. We also performed image processing as described by DeLand et al. (12) (images not shown). For the larger tumors in the popliteal fossa, this technique was not necessary, but the smaller metastases in the posterior lymphatics were more clearly visible in the subtracted images. The patient's tumor was biopsied at 72 hr (Table 2). For the anti-p97 antibody, the ratios of tumor to adjacent tissue were 7.1




FIG. 2. Patient M.R. (No. 5 in Table 1). Posterior scintigram of popliteal fossae. In right popliteal fossa, uptake is seen in metastatic melanoma. Scintigram obtained 48 hr after injection; image is unprocessed.

and 3.7, for Tumors 1 and 2, respectively, and the tumor-to-blood ratios were 1.5 and 0.8. In both lesions, twice as much specific as normal mouse antibody bound to the tumor.

Case 3: Antigen-specific uptake of anti-p97 Fab fragments by melanoma. B.O. (Patient 6 in Table 1) was a 53-yr-old male with melanoma metastatic to the left anterior cervical and submandibular lymph nodes from a primary lesion near the left ear. Despite removal of the left ear and lymph-node resection, with removal of the left parotid gland, extensive recurrence in the left neck was present. The patient received an intravenous injection containing 1 mCi and 1 mg each of two preparations: I-131-labeled Fab fragments of Antibody 8.2, and I-125-labeled Fab fragments of Antibody 1.4. One hour after injection of the I-131-labeled Fab, 50% of the radioactivity that remained in the serum was still able to bind to SK-MEL 28 cells in vitro. Scintiphotos showed significant hepatic and renal uptake, as well as tumor uptake of I-131-labeled Fab 8.2 at 24 and 48 hr after injection. A biopsy of the neck masses was performed at two different sites (Tumor 1 and Tumor 2), and adjacent soft tissue. Results are shown in Table 2. For Tumors 1 and 2, respectively, the following tumor-to-tissue ratios were observed for Fab 8.2: blood 4.6 and 3.7; adjacent tissue 3.5 and 2.8. The ratios of Fab 8.2 to Fab 1.4 in Tumors 1 and 2, respectively, were 3.5 and 3.7. Thus, there was significantly more uptake of p97-specific than control Fab into tumor.

Appearance of antibodies to mouse immunoglobulin. Within several weeks of administration of 1 mg of mouse immunoglobulin, all of three patients tested developed antibodies to mouse IgG. In two of these patients (J.M. and Je.M., Table 1), a comparison of the rate of clearance of anti-p97 antibody was obtained before and after the appearance of the antibodies. In J.M. the half-life of clearance of Antibody 8.2 decreased from 22 hr to 1 hr. In Je.M. it decreased from 20 hr to 4 hr. Neither of the patients had had any skin reaction or untoward clinical

effects subsequent to intravenous injection. However, in both patients the uptake in liver was significantly greater on the second occasion, and the tumor uptake was less marked.

Dosimetry calculations. Based on the kinetic data presented above, the calculated radiation doses, in rads/mCi, for I-131-labeled IgG were as follows: liver 4.9, marrow 2, whole body 0.7, female gonads 0.7, male gonads 0.6 (19). Biodistribution data with Fab fragment are too limited to make adequate calculations at present, but because of the more rapid clearance from blood and whole body, exposures are considerably lower.

DISCUSSION

For several reasons we decided to evaluate the use of monoclonal antibodies to the human melanoma-associated antigen p97 for the diagnostic imaging of melanoma. The antigen is present at the outer surface of the plasma membrane and is accessible to antibody (15-17). It is expressed in much higher concentrations by many melanomas than by normal adult tissues (16,17). Monoclonal antibodies of two different subclasses (IgG1 and IgG2), and against several different epitopes of p97, are available (17). A sensitive radioimmunoassay for p97 has been developed, permitting quantitative determination of the amount of antigen present in tumors and other tissues (16,20). Finally, since malignant melanoma often metastasizes to subcutaneous tissue in noncritical areas where biopsies can readily be made, it provides a good model for assessing specificity and for monitoring the degree of tumor uptake with various antibody preparations.

Previous studies of radiolabeled antibody to p97 *in vitro* have shown 10-200 times higher binding to cells from most melanomas than to normal tissues (15-17). We have now demonstrated the preferential localization of anti-p97 antibody in metastatic melanoma, using both scintigrams and direct measurements of tumor biopsies. Since anti-p97 Antibody 8.2 has homogeneous light chains, we used this preparation preferentially for imaging studies.

The specificity of antibody binding to melanoma *in vivo* was much less pronounced than might have been expected from our *in vitro* studies, with target-to-background ratios at least an order of magnitude lower than they were when tumor biopsy or control material was exposed to the same antibodies *in vitro* (data not shown). This indicates that the distribution *in vivo* is determined by various factors other than an interaction of antigen and antibody at the tumor site. The greatest problem in our present work has been the fact that the liver has taken up most of the antibody, perhaps because processing of foreign or damaged protein occurs there. Through a better knowledge of the pharmacology of intravenously administered mouse antibody, it may be

possible to reduce the uptake into the liver.

A problem with interpreting previous studies on antibody localization into tumors has been the limited evidence of immunological specificity, particularly since proteins are known to penetrate the expanded extracellular space of tumors (21). A useful way to demonstrate immunological specificity is to use the paired labeling technique of Pressman, in which, e.g., I-125-labeled control and I-131-labeled specific immunoglobulin of the same isotype are injected simultaneously and their uptakes into the tumor compared (18). Mach et al. (4) used this approach to detect immune specific uptake, into human colon tumors, of goat antibody to carcinoembryonic antigen. Likewise, we could show that antibodies and Fab fragments specific for p97 (1 mg dose) had a significantly higher uptake in melanoma biopsies than control preparations, which localized to tumor to the same extent as to normal tissues.

The safety of using mouse monoclonal antibodies in humans has raised concern. As one step toward investigating this, we tested specific pathogen-free rabbits with Antibody 96.5. Mild, transient changes were noted only at doses of 1000 times the maximum human dose used for diagnostic imaging, and doses of 100 and 10 times the maximum human dose had no detectable effect. In none of the six melanoma patients was there any evidence of acute or subacute reaction to the antibody, or of any hematological or immunological side effects.

We believe that Fab fragments deserve further consideration for scanning. Animal studies indicate that greater target-to-nontarget ratios can be obtained by using such fragments rather than whole antibody (22). Our preliminary findings support this view, since we found that not only were anti-p97 Fab fragments taken up by tumor but higher tumor-to-blood ratios were obtained than for whole antibody. Also, because tumor localization and blood clearance are more rapid, short-lived emitters, such as Tc-99m or I-123 may be useful labels for Fab fragments. These radionuclides may give images of higher resolution than with I-131 because of more favorable radiation energies and because larger quantities can be administered without increasing the radiation exposure to the patient, thereby reducing the random noise in the images. However, the absolute uptake of Fab into tumor is lower by a factor of 4 to 5, and a corresponding increase of the dose of labeled Fab may be required for good-quality images. For example, in patient B.O. (Case 3), who received only a limited amount of radioactivity (1 mCi), random variation in count rate degraded the image quality.

Antibodies to mouse IgG appeared in the patients' sera after intravenous administration of 1 mg or more of the mouse IgG. Although no clinical effects were evident in subsequent experiments, as expected (23), these patients cleared the labeled mouse antibody much more rapidly into the liver, and tumor uptake was reduced. Fab

fragments may help to overcome this problem. Thus, patient B.O., who received 1 mg Fab 8.2, has not developed antibodies to mouse immunoglobulin. The use of human monoclonal antibody would avoid this problem.

We conclude that monoclonal mouse antibodies to p97 can be given safely to human patients in milligram doses and that immunologically specific uptake into melanomas can be obtained. The fact that tumor uptake of anti-p97 antibody can be observed in humans has important implications for any attempt to use such antibodies for tumor therapy. Also, we are encouraged by our findings suggesting that such monoclonal antibodies may be useful for the diagnosis of occult melanoma in selected patients. We believe, however, that further improvements in in-vivo specificity must be achieved before these methods will become clinically useful in the majority of patients with melanoma. We believe that such improvements will come by controlling factors that degrade the immunoreactivity of the radiolabeled preparations, by improving the stability of the radiolabeled antibodies in vivo, and by understanding better the biology of clearance of immunoglobulin into liver, in order ultimately to limit hepatic uptake and increase in vivo targeting of antibody to tumor. Work is currently under way in our laboratory to investigate these possibilities.

FOOTNOTE

* Dutchland Rabbitry, Denver, Pennsylvania.

ACKNOWLEDGMENTS

We very much appreciate the support of Dr. Robert F. Jones, Department of Surgery, University of Washington, Seattle, Washington, who obtained the biopsy on patient M.R. We thank Dr. M. T. Groudine, of Fred Hutchinson Cancer Research Center, and Drs. T. W. Griffin, and W. B. Nelp, University of Washington School of Medicine, for helpful suggestions regarding the preparation of this manuscript. We also thank Phyllis Harps for assistance in manuscript preparation, and John Ferens and Lisa Dally for technical support.

This work supported by the Medical Research Service of the Veterans Administration and by USPHS Grant #1 ROI CA 29639.

REFERENCES

1. GOLDENBERG DM, DELAND F, KIM E, et al: Use of radiolabeled antibodies to carcinoembryonic antigen for the detection and localization of diverse cancers by external photoscanning. *N Engl J Med* 298:1384-1386, 1978
2. GOLDENBERG DM, KIM EE, DELAND FH et al: Radioimmunodetection of cancer with radioactive antibodies to carcinoembryonic antigen. *Cancer Res* 40:2984-2992, 1980
3. HINE KR, BRADWELL AR, REEDER TA, et al: Radioimmunodetection of gastrointestinal neoplasms with antibodies to carcinoembryonic antigen. *Cancer Res* 40:2993-2996, 1980

4. MACH JP, CARREL S, FORNI M, et al: Tumor localization of radiolabeled antibodies against carcinoembryonic antigen in patients with carcinoma. *N Engl J Med* 303:5-10, 1980
5. DELAND FH, KIM EE, GOLDENBERG DM: Lymphoscintigraphy with radionuclide-labeled antibodies to carcinoembryonic antigen. *Cancer Res* 40:2997-3000, 1980
6. GOLDENBERG DM, KIM EE, DELAND FH et al: Clinical studies on the radioimmunodetection of tumors containing alphafetoprotein. *Cancer* 45:2500-2505, 1980
7. KIM EE, DELAND FH, NELSON MO, et al: Radioimmunodetection of cancer with radiolabelled antibodies to alpha-fetoprotein. *Cancer Res* 40:3008-3012, 1980
8. GOLDENBERG DM, KIM EE, DELAND FH, et al: Clinical radioimmunodetection of cancer with radioactive antibodies to human chorionic gonadotropin. *Science* 208:1284-1286, 1980
9. GHOSE T, NORVELL ST, AQUINO J: Localization of ¹³¹I-labeled antibodies in human renal cell carcinoma and in mouse hepatoma and correlation with tumor detection by photoscanning. *Cancer Res* 40:3018-3031, 1980
10. BELITSKY P, GHOSE T, AQUINO J, et al: Radionuclide imaging of metastases from renal-cell carcinoma by ¹³¹I-labeled antitumor antibody. *Radiology* 126:515-517, 1978
11. ORDER SE, BLOOMER WB, JONES AG, KAPLAN WB, DAVIS MA, ADELSTEIN SJ, HELLMAN S: Radionuclide immunoglobulin lymphangiography: A case report. *Cancer* 35:1487-1492, 1975
12. DELAND FH, KIM EE, SIMMONS G: Imaging approach in radioimmunodetection. *Cancer Res* 40:3046-3049, 1980
13. PRIMUS FJ, GOLDENBERG DM: Immunological considerations in the use of goat antibodies to carcinoembryonic antigen for the radioimmunodetection of cancer. *Cancer Res* 40:2979-2983, 1980
14. KÖHLER G, MILSTEIN C: Continuous culture of fused cells secreting antibodies of predefined specificity. *Nature* 256:495-497, 1975
15. WOODBURY RG, BROWN JP, YEH M-Y, et al: Identification of a cell surface protein, p97, in human melanomas and certain other neoplasms. *Proc Natl Acad Sci* 77:2183-2187, 1980
16. BROWN JP, WOODBURY RG, HART CE, et al: Quantitative analysis of melanoma-associated antigen p97 in normal and neoplastic tissues. *Proc Natl Acad Sci* 78:539-543, 1981
17. BROWN JP, NISHIYAMA K, HELLSTRÖM I, et al: Structural characterization of human melanoma-associated antigen p97 using monoclonal antibodies. *J Immunol* 127:539-546, 1981
18. PRESSMAN D: Radiolabeled antibodies. *Ann NY Acad Sci* 69:644-650, 1957
19. Medical Internal Radiation Dosimetry Committee Pamphlet # 11, Society of Nuclear Medicine Publishers, 1975
20. BROWN JP, HELLSTRÖM KE, HELLSTRÖM I: Use of monoclonal antibodies for quantitative analysis of antigens in normal and neoplastic tissues. *Clin Chem* 27:1592-1596, 1981
21. BAUER FK, TUBIS M, THOMAS HB: Accumulation of homologous radioiodinated albumin in experimental tumors. *Proc Soc Expl Biol Med* 90:140-142, 1955
22. HOUSTON LL, NOWINSKI RC, BERNSTEIN ID: Specific in vivo localization of monoclonal antibodies directed against the Thy 1.1 antigen. *J Immunol* 125:837-843, 1980
23. MANNIK M, AREND W, HALL A, GILLILAND B: Studies on antigen-antibody complexes. I. Elimination of soluble complexes from rabbit circulation. *J Exp Med* 133:713-739, 1971