

- metastases of breast carcinoma detected on ^{99m}Tc -methylene diphosphonate bone scan. *AJR* 134:389-391, 1980
6. CHEW FS, HUDSON TM, ENNEKING WF: Radionuclide imaging of soft tissue neoplasms. *Semin Nucl Med* XI: 266-276, 1981
 7. HOWMAN-GILES RB, GILDAY DL, ENG B, et al: Radionuclide skeletal survey in neuroblastoma. *Radiology* 131: 497-502, 1979
 8. MAGILL HL, STRANG MS: Paraspinal metastasis of Wilms' tumor visualized on bone imaging. *J Nucl Med* 22:481-482, 1981
 9. MCCARTNEY W, NUSYNOWITZ ML, REIMANN BEF, et al: ^{99m}Tc -diphosphonate uptake in neuroblastoma. *Am J Roentgenol* 126:1077-1081, 1976
 10. SHEN AC, JENNINGS RB: Kinetics of calcium accumulation in acute myocardial ischemic injury. *Am J Pathol* 67:441-452, 1972
 11. DEWANJEE MK, KAHN PC: Mechanism of localization of ^{99m}Tc -labeled pyrophosphate and tetracycline in infarcted myocardium. *J Nucl Med* 17:639-646, 1976

Diffuse Lung Uptake of Tc-99m Sulfur Colloid in Infectious Mononucleosis

Diffuse uptake of Tc-99m sulfur colloid is an unusual phenomenon that has been associated with a variety of processes including hepatic disease (1-3), malignancy (4), sepsis (1,2), Type 2 mucopolysaccharidoses (5), collagen vascular disease (1), hematologic disorders (1), liver transplant (6), spleen and bone-marrow transplant (4), amyloidosis (7), and antacid therapy (8). We present a case of marked diffuse lung uptake of Tc-99m sulfur colloid in a patient with infectious mononucleosis.

A 19-yr-old white man was seen for a 10-day course of sharp left upper quadrant abdominal pain, increasing fatigue, appetite loss, and sore throat. Physical examination revealed the spleen tip palpable 6 cm below the costal margin, with mild tenderness, enlarged lymph nodes in the cervical and inguinal chains, and mild enlargement of the pharyngeal tonsils, with erythema. The diagnosis of infectious mononucleosis was confirmed with a positive monospot and a characteristic peripheral blood smear. Chest radiographs were normal.

Because of concern that the abdominal pain may have been due to a splenic subcapsular hematoma, a Tc-99m sulfur colloid liver/spleen study was performed. This showed splenomegaly and marked diffuse pulmonary accumulation of sulfur colloid, the activity in the lungs being as intense as that in the liver (Fig. 1). No evidence of colloid shift in the form of increased bone-marrow or splenic activity was seen.

The quality of the radiopharmaceutical was verified by examining the studies of six other patients injected with the same sulfur colloid preparation for evidence of increased lung uptake. Four showed no lung uptake. Two with severe hepatocellular disease and marked colloid shift to the spleen and bone marrow showed minimal lung uptake; this association has been well described by Steinbach (3). Optimal colloid size and lack of macroaggregation of particles was verified before and after this study, using a hemocytometer with light microscopy. Aluminum ion concentration in the preparation was less than 10 $\mu\text{g}/\text{ml}$ by colorimetric assay. While it has been reported that aluminum ion concentrations as low as 1 $\mu\text{g}/\text{ml}$ can cause formation of a flocculent precipitate in the colloid preparation (9), the minimum detectable aluminum ion concentration with commercial colorimetric assay kits is 10 $\mu\text{g}/\text{ml}$.

After the quality of the radiopharmaceutical has been assured, possible causes of diffuse increased uptake of sulfur colloid in the lungs would include: (a) in vivo macroaggregation or flocculation

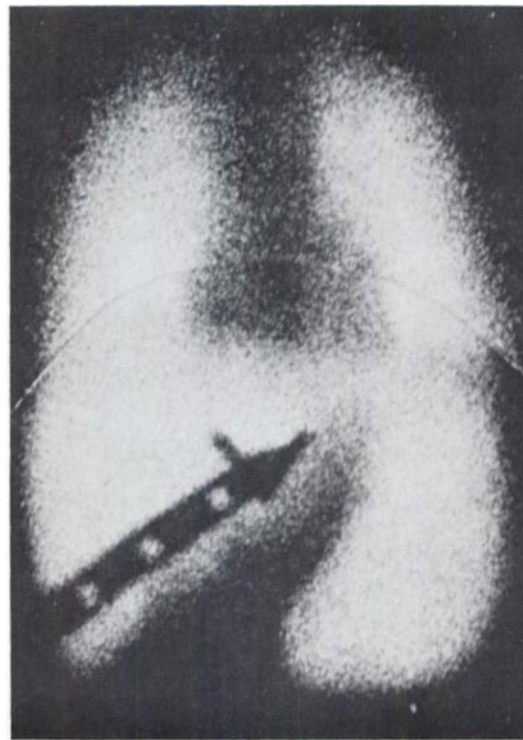

FIG. 1. Composite of identically exposed scintiphotos demonstrating marked diffuse lung uptake of Tc-99m sulfur colloid.

of particles, such as can be caused by excess plasma aluminum ion concentration (9) or by other as yet unknown factors; (b) adherence of the sulfur colloid particles to the endothelial cells of the pulmonary capillaries (1); or (c) increased phagocytic activity due to either increased activity of the small number of macrophages normally present in the pulmonary capillary bed or to an increased number of these macrophages (5). While we have no pathological proof at the present time, we believe that in a patient with infectious mononucleosis and an increase in the number of circulating blood monocytes, the last hypothesis would be most likely (5).

CRAIG S. HAMMES
ALFRED J. LANDRY
STEPHEN R. BUNKER
MICHAEL F. HARTSHORNE
JACK L. LANCASTER
Brooke Army Medical Center
Fort Sam Houston, Texas

ACKNOWLEDGMENT

The opinions or assertions contained herein are the private views of the authors and are not to be construed as reflecting the view of the Department of the Army or the Department of Defense.

REFERENCES

1. KLINGENSMITH WC III, YANG SL, WAGNER HN JR: Lung uptake of Tc-99m sulfur colloid in liver and spleen imaging. *J Nucl Med* 19:31-35, 1978
2. KEYES JW JR, WILSON GA, QUINONES JD: An evaluation of lung uptake of colloid during liver imaging. *J Nucl Med* 14:687-691, 1973
3. STEINBACH HL: Pulmonary accumulation of ^{99m}Tc technetium

sulfur colloid during liver scanning. *Texas Med* 68:137-138, 1972

4. KLINGENSMITH WC III, RYSESON TW: Lung uptake of ^{99m}Tc -sulfur colloid. *J Nucl Med* 14:201-204, 1973
5. KLINGENSMITH WC III, LOVETT VJ JR: Lung uptake of ^{99m}Tc -sulfur colloid secondary to intraperitoneal endotoxin. *J Nucl Med* 15:1028-1031, 1974
6. BROWN DW, STARZL TE: Radionuclides in the postoperative management of orthotopic human organ transplantation.
7. CASTLEMAN B, SCULLY RE, MCNEELY BU: Case records of the Massachusetts General Hospital (case 25-1974). *N Engl J Med* 290:1474-1481, 1974
8. BOBINET DD, SEVRIN R, ZURBRIGGEN MT, et al: Lung uptake of ^{99m}Tc -sulfur colloid in patient exhibiting presence of Al 3+ in plasma. *J Nucl Med* 15:1220-1222, 1974
9. HANEY TA, ASCANIO I, GIGLIOTTI JA, et al: Physical and biological properties of a ^{99m}Tc -sulfur colloid preparation containing disodium edetate. *J Nucl Med* 12:64-68, 1971
10. KLINGENSMITH WC, TSAN MF, WAGNER HN JR: Factors affecting the uptake of ^{99m}Tc -sulfur colloid by the lung and kidney. *J Nucl Med* 17:681-684, 1976

Abnormal Accumulation of Technetium-99m Hepatobiliary Agent in a Case of Idiopathic Bile Peritonitis

Since the publication by Spencer et al (1), iodine-131 rose bengal (2) and the recent Tc-99m IDA derivatives have been used to demonstrate bile leakages following cholecystectomy (3), biliary-intestinal tract anastomosis (4), ductal rupture in hepatic trauma (5), and gallbladder perforation (6). Abnormal accumulation of Tc-99m hepatobiliary agent with idiopathic bile leak has also been described recently (7). In that patient, however, there was no clinical or chemical evidence of jaundice, cholelithiasis, biliary ductal dilatation, cholecystitis, or pancreatitis. Although a small amount of bilious fluid was aspirated, the significance of the abnormal accumulation of hepatobiliary agent is difficult to determine since there was no surgical documentation of a site of leakage.

We recently encountered a patient who had intraperitoneal

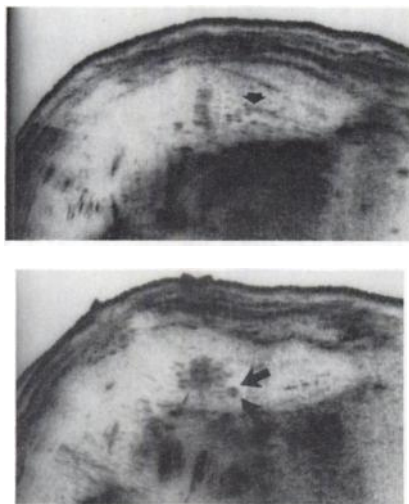


FIG. 1. Ultrasonogram of biliary tree showing dilated duct (top, arrow) with calculus (bottom two arrows) in left lobe of liver.

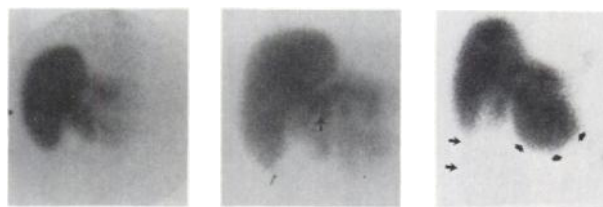


FIG. 2. Anterior hepatobiliary images. Left: 10 min after tracer injection, showing configuration of left lobe of liver. Center: 2 hr after injection; common duct is obstructed (arrow), gallbladder not visible. Right: 7 hr after injection. Increased activity in left lobe (3 arrows); tracer along right side of abdomen (2 arrows); gallbladder still invisible.

extravasation of Tc-99m hepatobiliary agent, with surgical confirmation of idiopathic bile peritonitis.

A 79-yr-old white male was admitted with upper abdominal pain and jaundice of a few days' duration. There was no fever, nausea, vomiting, constipation, or diarrhea. The patient denied alcohol abuse. There was no past history for similar pain.

Physical examination demonstrated marked tenderness in the epigastrium and in both upper quadrants of the abdomen, with guarding. The pertinent laboratory values were: total bilirubin 6.0 mg per dl, direct bilirubin 3.3 mg per dl, and serum amylase 902 units. With the initial impression of obstructive jaundice due to calculus in the common bile duct or acute pancreatitis, an ultrasonogram of the biliary tree was obtained, followed 24 hr later by radionuclide hepatobiliary imaging and TCT examination of the upper abdomen. The ultrasound examination (Fig. 1) demonstrated a moderately dilated, thick-walled gallbladder containing several calculi. There was dilatation of the biliary tract, with a focal density indicating calculus in a dilated duct in the left lobe of the liver. The pancreas was not visualized. There was no abnormal fluid collection in the upper abdomen. The hepatobiliary images (Fig. 2) were obtained with 5.4 mCi (200 MBq) of Tc-99m diisopropyl IDA derivative. Sequential anterior views of the upper abdomen were obtained until 7 hr after injection. The gallbladder was not visualized. The radioactivity was not seen in the gastrointestinal tract until 2 hr after the injection. There was increasing tracer concentration along the left lobe of the liver and a curvilinear collection of the radionuclide was noted along the right abdominal wall. These findings were thought to represent extravasation of bile. In addition, there were multiple small col-

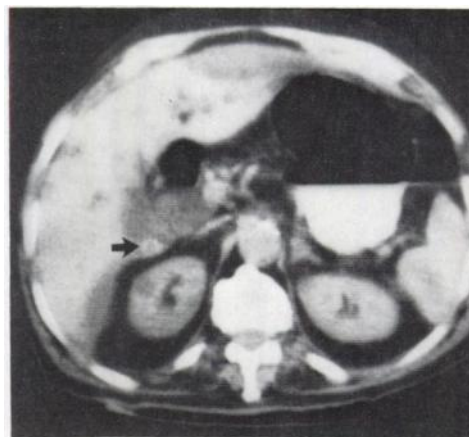


FIG. 3. TCT through liver (not enhanced) demonstrates fluid collection along anterior aspect of left lobe and in subhepatic space. Calculus (arrow) is also seen in gallbladder.