

Reply

Dr. Diksic is correct in his comments pointing out a discrepancy between the formula for compound 12A shown in Table 1A of our article (1) and the reference in the text to this compound as 4-iodoantipyrine. The compound whose in vivo distribution results are shown in Table 1A for compound 12A is 4-iodoantipyrine. However, the formula shown for compound 12A in Table 1A is in error. Indeed, as Dr. Diksic correctly notes, the iodine is on the heterocyclic ring in 4-iodoantipyrine and not on the benzene ring as shown in the formula in Table 1A.

H. S. WINCHELL
R. M. BALDWIN
T. H. LIN
Medi-Physics, Inc.
Emeryville, California

REFERENCE

1. WINCHELL HS, BALDWIN RM, LIN TH: Development of I-123 iodophenylalkyl amines for brain studies: Localization of I-123 iodophenylalkyl amines in rat brain. *J Nucl Med* 21: 940-946, 1980

Council on Cardiovascular Radiology of the American Heart Association

The rapid advances in the use of nuclear medicine for the study of the heart and great vessels make it appropriate for many more in the Society of Nuclear Medicine to participate in the scientific Councils of the American Heart Association. Such participation will give improved opportunities for the exchange of scientific information and in some cases for research support.

The next annual scientific sessions of the American Heart Association will be held in Dallas, Texas on November 16-19, 1981.

B. LEONARD HOLMAN
KENT ELLIS
Council of Cardiovascular Radiology
American Heart Association

Emergency Surgery for Acute Carotid-Artery Occlusion Noted on Radionuclide Dynamic Study

We describe a case in which the radionuclide cerebral dynamic study confirmed carotid occlusion associated with acute neurological deterioration, and thus allowed surgical therapy to be applied promptly and decisively.

A 70-year-old, right-handed machinist had noticed that for 1 mo he could neither use a micrometer with his right hand nor distinguish among coins in his right pants pocket. In the 10 days before admission he experienced three episodes of right arm paralysis, each lasting 10 min. On examination in the office, he walked with diminished swing of his right arm. Muscle tone and reflexes were increased in his right leg and a right Babinski response was present. A left carotid bruit was heard, although it had been inaudible to a cardiologist's ear a day earlier. Thirty minutes after initial examination, while arrangements for hospitalization were being made, the patient suddenly developed a right hemiplegia, an expressive aphasia, and a right homonymous hemianopsia. Retinal emboli were not seen. His left carotid bruit had disappeared.

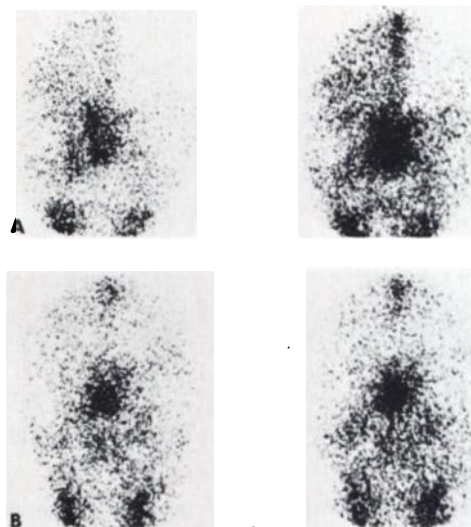


FIG. 1. Anterior cerebral perfusion studies 12 and 15 sec after i.v. injection of 20 mCi of Tc-99m DTPA, after acute occlusion of left carotid. (A) markedly decreased perfusion to left hemisphere is clearly demonstrated. (B) 6 days after thromboendarterectomy, images show symmetrical cerebral perfusion.

Within 30 min, a cerebral dynamic study was performed after intravenous injection of 20 mCi of Tc-99m DTPA. The sequential images revealed decreased perfusion of the upper left carotid artery and the entire left cerebral hemisphere (Fig. 1A). The patient was taken directly to surgery where a fresh thrombus overlying a large ulcerated atheromatous plaque was found to be occluding the left internal carotid artery. In the recovery room his acute deficit had completely cleared. Neurologic examinations at 18 hr and at 1 mo after carotid thromboendarterectomy showed only the mild corticospinal-tract defects noted on his first examination; these were probably residual deficits after a small embolic stroke 1 mo before the carotid occlusion. Dynamic and static radionuclide images were normal 6 days after surgery (Fig. 1B).

It could be argued that there was prominent nasopharyngeal radioactivity beginning in the arterial phase in Fig. 1A. This is suggestive of the "hot nose" that has been associated with internal carotid obstruction and perfusion of the nasopharyngeal region by external carotid supply (1). Such a finding is not specific, however, although it improved somewhat in our patient after surgery (Fig. 1B).

Restoration of carotid perfusion within 2 hr may be associated with recovery of function, whereas a longer delay has often given less favorable results (2). If the cause of a stroke is unclear, emergency carotid surgery would be attempted only when acute carotid occlusion is highly suspected or proven. The time required for confirmatory contrast angiography can delay surgery too long for it to be therapeutic. In addition, angiography after acute stroke has double its usual low morbidity (3). Some patients have been operated upon without angiography, with the disappearance of a carotid bruit as sole evidence that a carotid occlusion has occurred. However, a bruit may become inaudible either if the stenotic area widens (as when a bit of atheromatous debris breaks off), or if the stenosis is further narrowed or occluded so that there is not enough blood flow to produce turbulence.

In the present case, the diagnosis of acute carotid occlusion was suggested by evidence from the clinical presentation and sequential physical examinations. The radionuclide procedure supplied quick, virtually risk-free supportive evidence that our patient had suffered a carotid occlusion. Armed with this crucial diagnostic informa-

tion, prompt surgery was undertaken with reasonable expectation of success.

MAGRUDER C. DONALDSON
JAMES D. DONALDSON
MOZAFARREDDIN K. KARIMEDDINI
RICHARD P. SPENCER
University of Connecticut Health Center
Farmington, Connecticut

ACKNOWLEDGMENT

This work was supported by USPHS CA 17802 from the National Cancer Institute.

REFERENCES

1. MISHKIN FS, DYKEN ML: Increased early radionuclide activity in nasopharyngeal area in patients with internal carotid artery obstruction: "hot nose." *Radiology* 96:77-80, 1970
2. NAJAFI H, JAVID HS, DYE WS, et al: Emergency carotid thromboendarterectomy. Surgical indications and results. *Arch Surg* 103:610-614, 1971
3. GOLDSTONE J, MOORE WS: A new look at emergency carotid artery operations for the treatment of cerebrovascular insufficiency. *Stroke* 9:599-602, 1978

**22nd ANNUAL MEETING
SOUTHEASTERN CHAPTER
SOCIETY OF NUCLEAR MEDICINE**

October 28-31, 1981

**Stouffer's Cincinnati Towers
and Convention Center**

Cincinnati, Ohio

ANNOUNCEMENT AND CALL FOR ABSTRACTS

The Scientific Program Committee of the 22nd Annual Meeting of the Southeastern Chapter of the Society of Nuclear Medicine, chaired by Lawrence R. Muroff, M.D., is requesting the submission of original contributions in nuclear medicine from members and non-members of the Society.

The program will be approved by the Subcommittee on Continuing Education and Course Accreditation of the Society of Nuclear Medicine as one which meets the criteria for AMA Category 1 credit.

Physicians and scientists are encouraged to submit abstracts, as are technologists. Accepted technologist papers will be presented on the Scientific Program and will be eligible for awards.

Abstracts must be prepared in final form for direct photoreproduction on the official abstract form. For abstract forms and additional information, contact:

Robert H. Rohrer, Ph.D.
Administrative Director SEC/SNM
Department of Physics
Emory University
Atlanta, GA 30322
Tel: (404) 321-1241

Deadline for submission of abstracts: July 15, 1981

ABSTRACT BOOKS

Due to the popularity of the 1980 *Abstract Book* the 1981 *Abstract Book*, including all abstracts accepted for the 28th Annual Meeting of the Society, will be available for \$4.00 in advance and \$5.00 at the Meeting June 16-19, 1981 in Las Vegas, NV. Advance copies may be ordered on the Meeting Registration form.

The 1980 *Abstract Book* from the 27th Annual Meeting of the Society of Nuclear Medicine is available at \$4.00 per copy from the Book Order Department of the Society.