

Solitary Autonomous Thyroid Nodules: Comparison of Fluorescent and Pertechnetate Imaging

James H. Thrall*, Kenneth D. Burman, Michael T. Gillin†, Robert J. Corcoran, Merrill C. Johnson, and Leonard Wartofsky

Walter Reed Army Medical Center, Washington, D.C.

Twelve patients with solitary autonomous thyroid nodules were scanned with [^{99m}Tc] pertechnetate and by fluorescent imaging. Nodular dimensions were essentially identical on the two types of scans, but the relative scan densities in the nodular versus extranodular areas demonstrated striking differences. In 11 of the 12 patients, the ratio of nodular-to-extranodular radiotracer accumulation was significantly higher than the ratio of nodular-to-extranodular iodine content. In two patients with no demonstrable extranodular radiotracer accumulation by initial pertechnetate scan, extranodular tissue was demonstrated by fluorescent imaging. In such cases, fluorescent scanning may eliminate the need for a second radionuclide scan following TSH stimulation to visualize the extranodular tissue.

Fluorescent scanning offers a unique new method for aiding the evaluation of patients with suspected autonomous nodules, and can facilitate the diagnosis in some cases. The maintenance of relatively uniform iodine concentration between nodular and extranodular tissues is an intriguing finding that bears further investigation.

J Nucl Med 18: 1064–1068, 1977

The amount of extranodular tissue demonstrated by conventional emission scanning is highly variable in patients with solitary autonomous thyroid nodules (1–5). In some patients, no extranodular tracer uptake is demonstrated initially, and a repeat scan following TSH stimulation is necessary to visualize the extranodular thyroid tissue. In other cases, the entire gland is visualized and the actual limits of the nodule may not be well delineated by the baseline emission scan (1). The reason for these differences is most likely the variability in hormone production by autonomous nodules. The greater the percentage of total hormone requirement that is produced by an autonomous nodule, the greater is the degree of TSH suppression, and as a result extranodular tissues progressively fail to concentrate the radiotracer.

We have had the opportunity to study 12 patients with solitary autonomous thyroid nodules by both conventional emission imaging using [^{99m}Tc] pertechnetate and fluorescent scanning. The pertechnetate scans provide a map of the transport function or trapping function of active follicles. The fluores-

cent technique does not require the administration of a radiotracer, but provides a map of the distribution of iodine in the thyroid gland (6–8). Analysis of the similarities and differences between the radionuclide scans and the fluorescent scans forms the basis of this report.

MATERIALS AND METHODS

Patients with suspected autonomous thyroid nodules were divided into two categories. If the initial pertechnetate scan revealed no functioning extranodular tissue (Fig. 1A), autonomous function was established by failure of the 24-hr radioactive iodine

Received Nov. 22, 1976; revision accepted July 13, 1977.

For reprints contact: James H. Thrall, Nuclear Medicine Sec., Dept. of Internal Medicine, University of Michigan Medical Center, Ann Arbor, MI 48109.

* Current Address: Nuclear Medicine Sec., Dept. of Internal Medicine, University of Michigan Medical Center, Ann Arbor, MI 48109.

† Current Address: Radiation Therapy Dept., Medical College of Wisconsin, Milwaukee, WI 53226.

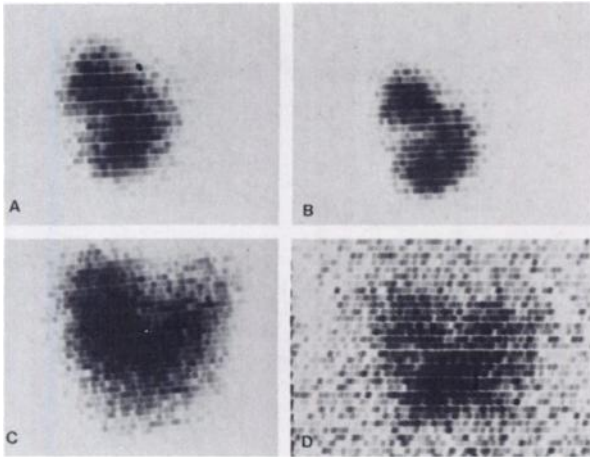


FIG. 1. Case 1. (A) Initial pertechnetate emission scan in patient with lobulated thyroid nodule in right lobe. (B) Pertechnetate scan, repeated after Cytomel suppression, confirms that all tissue visualized initially is non-suppressible. (C) Pertechnetate scan after TSH stimulation reveals left lobe. (D) Fluorescent scan demonstrates little gradient in iodine concentration between nodular and extranodular areas.

uptake to decrease by more than 50% after 10 days of suppression with 100 μg Cytomel daily. Repeat pertechnetate images were also obtained (Fig. 1B) to assess any change in the size or configuration of the apparently autonomous nodule, and repeat scans were obtained after administration of TSH to demonstrate the extranodular tissues (Fig. 1C).

When the initial pertechnetate scan revealed extranodular tissue, autonomous function was considered established if a repeat scan after the same regimen of Cytomel demonstrated relative suppression of extranodular activity with persistent radio-tracer concentration by the nodule (1,2,5).

The emission scans were obtained on a rectilinear scanner with a low-energy, fine-focus, collimator with a 3-in. focal depth. Two to 5 mCi of [$^{99\text{m}}\text{Tc}$] pertechnetate were injected intravenously and imaging was begun in 20–30 min. Scanning was performed with no background subtraction (contrast range differential = 100%). Patients with proven solitary autonomous thyroid nodules were then imaged with a fluorescent scanning system to depict the distribution of iodine within the thyroid gland, and to quantitate total glandular iodine (6–10).

Comparisons were made of the respective nodular dimensions on the emission and fluorescent scans. The two types of scans were submitted to independent observers for nodular measurement. Ratios of nodular-to-extranodular radioactivity and iodine content were also compared in each case by analysis of relative densities on the scans. The qualitative appearances were first assessed, and then the ratio

between maximum film density in the nodular and extranodular tissues was determined with a film densitometer. Nodular and extranodular areas were systematically surveyed, and a minimum of five readings obtained from each area. After correction for film density, the ratios between the maximum readings in the nodular and extranodular areas were calculated.

Nine of the twelve patients had 24-hr radioiodine uptake determinations initially. Two patients demonstrating no extranodular tissue on initial radioiodine scanning had repeat 24-hr radioactive iodine uptake determinations after Cytomel administration. In all patients, the serum T_4 was determined by competitive protein-binding assay, and T_3 resin uptake determinations were also obtained.

RESULTS

In this study, all 12 patients with solitary autonomous thyroid nodules were judged to be euthyroid. Three of them had 24-hr radioactive uptakes above the normal range for the clinic, but had normal serum T_4 and T_3 resin uptakes (Table 1).

In two patients, no extranodular activity was demonstrated on the initial pertechnetate scan (Fig. 1A). (Note: In each case this was confirmed by repeating the scan using factors determined by set-up over a background area outside the nodule.) In each of these cases, the fluorescent scan demonstrated iodine concentration in the extranodular tissues (Fig. 1D). The extent of extranodular tissue seen on the fluorescent scans paralleled that of the extranodular tissues demonstrated by repeat emission scanning after the administration of TSH (Fig. 1C, D).

In the remaining ten patients, the initial emission scans demonstrated faint to moderate extranodular Tc-99m accumulation (Figs. 2, 3). In nine of the ten patients in this group, the ratio of nodular-to-extranodular tracer concentration demonstrated by the emission scans was greater than the ratio of nodular-to-extranodular iodine demonstrated by the fluorescent scans (Table 1). In three of the ten, there was little or no difference in stable iodine concentration between the nodular and extranodular tissue (Fig. 2A, B). On the fluorescent scans the density ratios in these three patients measured 1.1:1 (Table 1, Cases 3, 7, 10). In nine of the ten patients demonstrating some extranodular Tc-99m accumulation on the scan, the extent of the extranodular thyroid tissue demonstrated by fluorescent scanning was greater than that demonstrated by the initial emission scans (Figs. 2, 3). In one patient there was essential agreement between emission and fluorescent scans; nodular dimensions, the extent of extranodular tissue, and the relative densities of the two photoscans in

TABLE 1. CASE SUMMARIES

	Case No	Age	Sex	T ₁ (NI 3.8-10.3 μg)	T ₂ resin uptake (NI 25-35%)	24-hr RAIU (8-30%)	Total thyroidal iodine content (mg)	Av diam: TcO ₄ scan (cm)	Av diam: fluorescent scan (cm)	Scan density ratio by TcO ₄ scan: extra-nodular	Scan density ratio by fluorescent scan: extra-nodular	TcO ₄ scan density ratio/fluorescent scan density ratio		
Group 1: No extranodular tissue demonstrated by baseline emission scan.	1	24	F	8.2	34	41%	3.8	3.9	4.0‡	20.2	2.0	10.1		
	2	52	F	7.4	26	13% (15%)*	4.8	3.5	3.4‡	42.6	1.3	32.8		
Group 2: Extranodular tissue demonstrated by baseline emission scan.	(A) Fluorescent scan	3	16	F	6.5	30	—	15.2	(1.8)†	(—)	14.5	1.1	13.2	
		4	17	F	8.0	28	17%	17.7	4.2	4.4	7.4	1.7	4.4	
		5	35	F	6.2	26	36%	9.0	2.8	2.9	9.1	1.7	5.3	
		6	41	F	7.9	26	40%	4.7	2.6	2.4	5.6	2.6	2.2	
		7	45	F	6.1	28	12%	11.3	3.3	3.4‡	13.2	1.1	12.0	
		8	45	F	5.6	40	—	2.4	3.6	3.8	2.4	1.3	1.8	
		9	46	F	6.2	25	23%	8.6	3.5	3.2	3.1	1.5	2.1	
		10	53	F	6.8	29	20%	11.2	2.6	2.9‡	2.5	1.1	2.3	
		11	54	F	4.9	29	—	5.7	2.8	2.6	11.9	1.7	7.0	
		(B) Fluorescent scan concordant	12	31	F	6.1	35	26%	9.5 8.7 ±4.7 s.d.	3.8 3.3 ±.55 s.d.	4.0 3.4 ±.62 s.d.	6.9	5.8	1.2

* Repeat RAIU after Cytomel.
 † Not included in calculations of mean diameter.
 ‡ Measurement after correlation with emission scan.

the areas of the nodule in contrast to extranodular tissue, were almost identical (Table 1, Case 12). This patient had very little extranodular tissue due to prior surgery and probably for this reason demonstrated the highest nodular-to-extranodular ratio by fluorescent imaging.

In one of 12 patients (Table 1, Case 3), the di-

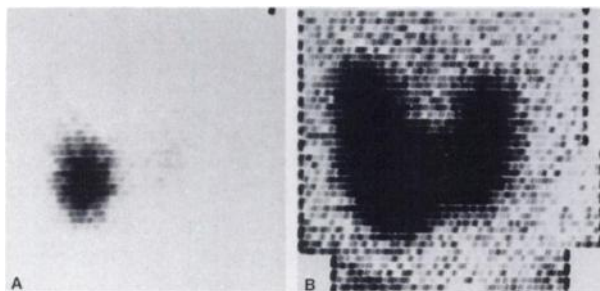


FIG. 2. Case 3. (A) Pertechnetate emission scan demonstrates marked tracer accumulation in solitary autonomous nodule in right lobe. Faint uptake is visualized in extranodular areas, and ratio of nodular-to-extranodular tracer concentration is very high. (B) Fluorescent scan in same case reveals essentially no gradient in concentration of iodine between nodule and extranodular areas.

mensions of the nodule could not be measured on the fluorescent scan. The nodule was in the lower pole of the right lobe and the density gradient was too low to differentiate the nodule from the remainder of the lobe (Fig. 2A, B). In four cases, the nodule comprised essentially all of one lobe (Table 1, Cases 1, 2, 7, 10). Measurement in these cases was possible only after correlation with the emission scans for nodule identification. In the remaining seven cases (one is illustrated in Fig. 3), the nodules were delineated on both types of scans. The size correlation was quite good, with a coefficient of .92 (P < .01). The correlation did not change significantly when Cases 1, 2, 7, and 10 were also included.

Total thyroid gland iodine averaged 8.7 mg ± 4.7 s.d., with a range of 2.4 to 17.7 mg (Table 1).

DISCUSSION

The demonstration by fluorescent scan of significant extranodular iodine concentration in patients with solitary autonomous nodules in this series sup-

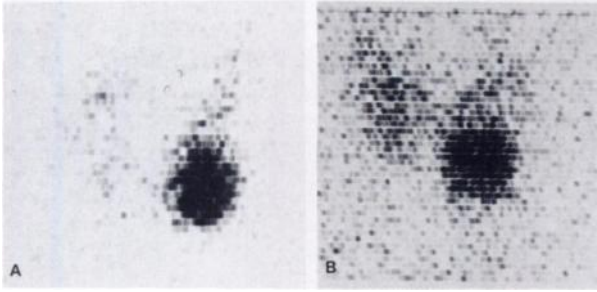


FIG. 3. Case 6. (A) Per technetate emission scan reveals solitary autonomous nodule in lower pole of left lobe, and faint extranodular tracer uptake. (B) Nodule is clearly delineated on fluorescent scan in same case, but extranodular tissues are visualized to significantly greater extent.

ports the previous observations of Hoffer and Gottschalk in three patients with this condition (6). Based on a qualitative evaluation of the fluorescent scans, they judged one of their patients to have normal iodine content in the extranodular tissues, and the other two to have increased iodine content in both nodular and extranodular areas. One of the latter patients was thyrotoxic. Corresponding radionuclide emission scan images were not described.

Although the ratios encountered in the emission scans in our series are undoubtedly influenced by the use of per technetate rather than radioiodine, the relative lack of a concentration difference in iodine between the nodular and extranodular tissues, contrasted with the striking functional difference in the capacity to concentrate radiotracer, remains an interesting finding with both clinical and theoretical implications. In the two patients demonstrating complete suppression of extranodular radiotracer accumulation, the fluorescent scans demonstrated extranodular thyroid tissue. Since the presence of extranodular tissue was readily established by the fluorescent image, scanning studies following TSH stimulation would not be necessary to complete the diagnostic work-up if fluorescent scanning is available. Of direct benefit to the patient is the fact that both the per technetate scan and the fluorescent scan can be performed during the same visit to the clinic, and the risks of injecting TSH, a bovine protein, are eliminated. This will probably not involve a large number of patients, but it does suggest a definite clinical indication for fluorescent scanning.

From a theoretical standpoint, the disparity in ratios between nodular-to-extranodular iodine content and radiotracer uptake is not fully explained, but it is probably because the fluorescent scan reflects iodine concentration in the thyroid gland and does not depend on any short-term TSH-mediated function, such as trapping, which is the basis for the per technetate scan. The presence of iodine in the

extranodular tissues in the patients demonstrating apparently complete functional suppression of the extranodular thyroid tissue may be an indication either of incomplete suppression or of insufficient time of suppression to permit appreciable leakage of iodine from the extranodular tissue.

The first hypothesis (incomplete TSH suppression) is consistent with recent work of Kamiel, Hall, and Nicoloff (11), indicating that T_3 administration in replacement dosages to euthyroid subjects diminishes but does not completely inhibit thyroidal production and secretion of T_4 . Since the T_4 production rate in their study of patients with pituitary and hypothalamic hypothyroidism was significantly lower than in the euthyroid subjects receiving replacement T_3 , they concluded that extrinsic stimulation, presumably by TSH, was responsible for maintaining the T_4 secretion in the latter subjects (11). If this is indeed the case, an analogy may exist with euthyroid patients with autonomous nodules, and failure of the radionuclide scans to demonstrate the extranodular tissues simply indicates their relative insensitivity in distinguishing absent from greatly diminished function. The second hypothesis—of insufficient time for appreciable leakage of iodine—could apply in some cases, particularly those of recent onset. To evaluate this possibility, followup scans and repeat thyroidal iodine quantification are being obtained to assess interval change in selected patients. No change has been observed, however, in one case followed for 14 mo.

In the patients demonstrating some function of the extranodular tissues by radionuclide scan, there is continued stimulation by TSH of the extranodular tissues although at lower than normal levels (1,3). Iodine concentration could be maintained if uptake and excretion remained balanced. It is also interesting, in this regard, that the average total thyroidal iodine content in these patients was 8.7 mg. Although the sample is small, this is not significantly different from the 10.1-mg average for euthyroids in our clinic.

For most of the nodules in this series, the correlation in size determined by the two types of scans was quite good. However, the comparatively low nodular-to-extranodular density ratios obscured recognition of some nodules on fluorescent scans alone. In such cases, the significance of the fluorescent scan pattern will become apparent only when correlated with the emission scan and/or findings by physical examination.

REFERENCES

1. HAMBURGER JI: Solitary autonomously functioning thyroid lesions. *Amer J Med* 58: 740-748, 1975

2. FERRAZ A, MEDEIROS-NETO GA, TOLEDO AC, et al: Autonomous thyroid nodules. I. A clinical classification and the use of a diagnostic index. *J Nucl Med* 13: 733-737, 1972
3. MILLER JM, HAMBURGER JI: The thyroid scintigram. I. The hot nodule. *Radiology* 84: 66-74, 1965
4. SILVERSTEIN GE, BURKE G, COGAN R: The natural history of the autonomous hyperfunctioning thyroid nodule. *Ann Intern Med* 67: 539-548, 1967
5. CHARKES ND: Scintigraphic evaluation of nodular goiter. *Sem Nucl Med* 1: 316-333, 1971
6. HOFFER PB, GOTTSCHALK A: Fluorescent thyroid scanning: scanning without radioisotopes. Initial clinical results. *Radiology* 99: 117-123, 1971
7. HOFFER PB, BERNSTEIN J, GOTTSCHALK A: Fluorescent techniques in thyroid imaging. *Semin Nucl Med* 1: 379-389, 1971
8. PATTON JA, HOLLIFIELD JW, BRILL AB, et al: Differentiation between malignant and benign solitary thyroid nodules by fluorescent scanning. *J Nucl Med* 17: 17-21, 1976
9. GILLIN M, THRALL J, JOHNSON M: Thyroid fluorescent scanning system. *J Nucl Med* 16: 530, 1975 (Abst)
10. PALMER DW, DECONINCK F, SWANN SJ, et al: Low cost intrathyroidal iodine quantification with a fluorescent scanner. *Radiology* 119: 733-735, 1976
11. KAMIEL MB, HALL TD, NICOLOFF JT: Significance of Non-T₄-suppressible thyroxine (T₄) secretion in man. The Endocrine Society, 58th Annual Meeting, San Francisco, California. June 23-25, 1976 (Abst)

CARDIOVASCULAR NUCLEAR MEDICINE: A CLINICAL TRAINEESHIP

The Subcommittee on Continuing Education and Course Accreditation with the Academic Council of the Society of Nuclear medicine will present a program offering a unique approach to the study of heart disease. The program is specially designed in response to the needs of community hospital cardiologists, nuclear medicine physicians, and nuclear medicine technologists.

The course will be offered on three occasions. The first of the programs will be held in Toronto, Ontario, Canada, on November 19, 1977. The next two courses are tentatively scheduled to be held in Denver, Colorado, on February 10, 1978 and in Boston, Massachusetts, on April 15, 1978.

A follow-up hands-on preceptorship covering two days will be made available to physicians and technologists who successfully complete the course.

Programs and registration forms will be available by October 1, 1977. Registration is limited to 400. This meeting has been approved for 24 hours of AMA Category 1 credit. For further information contact:

**Karen Chang
Society of Nuclear Medicine
475 Park Avenue South
New York, NY 10016**