VISUALIZATION OF PLACENTAL ABRUPTION BY BLOOD POOL SCANNING

Phillip H. Weiss and James D. Strong

USAF Medical Center, Wright-Patterson Air Force Base, Ohio

A patient with marginal placental abruption diagnosed by blood pool scanning with ^{99m}Tc-pertechnetate is presented. Scintigraphic findings were different from those reported previously.

Placental blood pool imaging has been widely used for the evaluation of suspected placenta previa in cases of third trimester bleeding (*1*). Although marginal implantation presents a diagnostic problem, identification of the placental blood pool in the fundus excludes the diagnosis of placenta previa. This leaves the obstetrician with the serious consideration of placental abruption if the bleeding remains unexplained. There are few reports of the diagnosis of abruption by placental imaging (*2,3*). This report describes a patient with marginal abruption with findings different from the previous reported cases.

CASE REPORT

The patient, a 33-year-old white woman, gravida 9, para 6, ab 2, was at 7½ months gestation when referred to the department of nuclear medicine for evaluation of painless vaginal bleeding of approximately 20 cc. She was spotting at the time of the examination.

Placental imaging was performed immediately after intravenous injection of 1 mCi of ^{99m}Tc-pertechnetate using the Pho/Gamma HP scintillation camera (Searle Radiographics, Inc.) with a medium-energy diverging collimator.

The first scintiphoto taken almost immediately after injection was centered over the pelvis (Fig. 1). Just below the region of the bladder a vertical midline accumulation of activity was noted (Fig. 1A). In addition, activity was seen in the region of the uterus in the midline (Fig. 1, arrow).

On the second scintiphoto (Fig. 2) the placental blood pool was seen in the fundus (Fig. 2B), and a small accumulation of activity at its inferior edge was identified (Fig. 2, arrow). This persisted throughout the examination and corresponded to the activity seen on the first scintiphoto (Fig. 1, arrow).

It was suggested that this represented a site of marginal placental separation. The patient was managed conservatively and the vaginal bleeding stopped within 24 hr of the study. There were no uterine contractions at this time and the membranes were intact. Clot formation and retraction were normal and maternal and fetal status remained stable. At spontaneous delivery 2 days later of an Apgar 9, 5-lb 2-oz male, the fundal location of the placenta was confirmed. A 3-cm organized hematoma indicative of premature separation was found on the in-

Received Aug. 6, 1973; revision accepted April 18, 1974.

For reprints contact: Phillip H. Weiss, Dept. of Radiology, Mount Sinai Hospital, Cleveland, Ohio 44106.

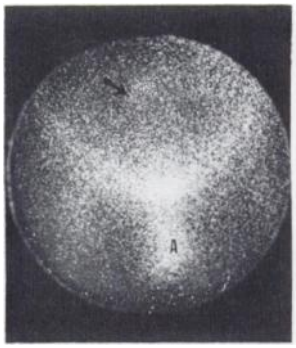

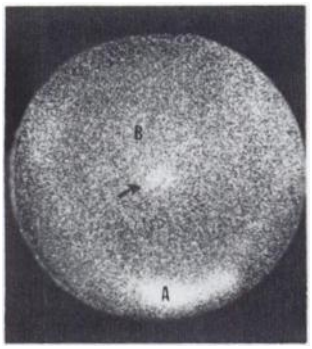

FIG. 1. (Left) Anterior scintiphoto taken almost immediately after injection of ^{99m}Tc-pertechnetate. Note midline activity in region of vulva (A). Small collection of activity is present in region of fundus (arrow). Placental blood pool is not yet visualized.

FIG. 2. (Right) Anterior scintiphoto taken shortly after view in Fig. 1. Bladder is now well seen (A). Placental blood pool is seen in the fundus (B), and small collection of activity seen earlier is noted to be at inferior edge of placental blood pool (arrow).

ferior edge, corresponding to the small region of increased activity seen on the scintiphotos.

DISCUSSION

It is reasonable that the findings in this case represent the actual site of placental separation. This is supported by the correlation between the scan appearance of the activity at the lower edge of the placental image and the location of the separation at delivery.

In previous reports, scintigraphic demonstration of placental abruption has been based on areas of diminished activity in the placental image representing infarcts (*2*) or separation of the placental image from that of the uterine wall (*3*). In the present case, the area of separation appeared hyperactive, probably representing extravasation with trapping of pertechnetate in a small pocket.

The midline activity in the region of the vulva (Fig. 1A) was initially thought to represent active vaginal bleeding. However, the patient was only spotting at the time of examination and it was considered unlikely that this could account for the activity seen. Pooling of urine in the vagina might give this appearance; however, the first scintiphoto was completed during the first few minutes after injection prior to significant renal excretion. The patient was not incontinent nor was there a history of stress incontinence. It was concluded that this represented a vascular "blush" resulting from the gross venous engorgement of the vaginal barrel known to exist during the third trimester of pregnancy (*4*). A similar blush has subsequently been observed in a number of patients who were not bleeding at the time of examination. This finding may represent the scintigraphic correlate of Chadwick's sign, a characteristic violet hue of the vaginal walls seen during early pregnancy and thought to be due to increased vascularity (*5*).

The findings in this case almost certainly resulted from the fortuitous presence of active bleeding at the time of the examination with relative sequestration in a confined area. Meticulous evaluation of unexplained findings on placental blood pool scans may allow one the opportunity to diagnose placental abruption with more confidence, although we suspect the opportunities will be rare.

ACKNOWLEDGMENT

The views expressed in this paper are those of the authors and do not necessarily reflect the views of the United States Air Force or the Department of Defense.

REFERENCES

1. James AE, Strauss HW, Fischer K, et al: Placental imaging with ^{113m}In transferrin and ^{99m}Tc serum albumin. *Obstet Gynecol* 37: 602–611, 1971

2. Rosenthall L: Radionuclide visualization of the placenta with the gamma-ray scintillation camera. *Can Med Assoc J* 97: 212–217, 1967

3. Moss ML, Freeman LM: Scintiphotographic diagnosis of abruptio placentae. *J Nucl Med* 14: 297–298, 1973

4. Masters WH, Johnson VE: *Human Sexual Response*, Boston, Little, Brown and Co, 1966, pp 145–148

5. Eastman NJ, Hellman LM: *Williams Obstetrics*, 13 ed, New York, Appleton-Century-Crofts, 1966, pp 228–229