

LIVER-SPLEEN SCANNING: THE LEFT LATERAL DECUBITUS POSITION IS BEST FOR LATERAL VIEWS

Donna C. Crandell, Marcia Boyd, James R. Wennemark, and Ben I. Friedman

University of Tennessee, Memphis, Tennessee

Positioning of the patient for liver and spleen scanning was not a problem in the past. Using single-probe detectors the patient was usually scanned with the side of interest uppermost (1). With the advent of dual-probe detectors the question arose as to which side of the patient should be dependent. La-Rose advocated that the side of interest be dependent, thereby minimizing respiratory motion (2). In our laboratory, using a dual-probe detector for simultaneous liver-spleen scanning, we noted an altered appearance of the liver and spleen depending upon which lateral decubitus view was used. This stimulated the described investigation.

MATERIALS AND METHODS

Simultaneous anterior and posterior scans were performed with the patient supine. Simultaneous lateral scans were then obtained with the patient in both the left lateral decubitus and right lateral decubitus positions. The detector was a dual-probe Ohio Nuclear Model 84 F.D. One millicurie of ^{99m}Tc -sulfur colloid was given intravenously with the patient in the supine position, and scanning was begun 10 min after injection. Markings used for localization were the xiphoid with a mark at the same level over the spine, the costal margin in the mid-clavicular and anterior axillary line, and the umbilicus.

RESULTS

It is readily apparent that with the patient in the left lateral decubitus position (Fig. 1A) the posterior liver border is well removed from the spine and clearly demarcated from splenic activity. The liver in this position conforms to the textbook description with the anterior border being convex and

the posterior border straight. Using the lower probe the spleen is readily visualized in this position (Fig. 1B).

When the patient is studied in the right lateral decubitus position (Fig. 2A), there tends to be straightening of the anterior superior margin of the liver which at times suggests a mass in this area (large arrow in Fig. 2). The area of radioactivity is increased with consequent decreased distance from the spine. Considerable difficulty was encountered in separating splenic from hepatic activity with the upper probe when the patient was in this position (Fig. 2B). A comparison of Fig. 1B and 2B suggests that a contributing factor to this distortion is a shift of the posterior splenic border away from the spine when the patient is in the right lateral decubitus position.

Measurements which were performed in 24 cases support these impressions. Separation of splenic from liver radioactivity was not possible in 12 of the 24 patients when they were scanned in the right lateral decubitus position.

DISCUSSION

It has been recommended that a complete liver scan should include anterior, posterior, and right lateral views (3,4). Spleen studies should include left lateral, posterior, and, occasionally, oblique, and anterior views (5,6). With single-probe detectors this has been very time-consuming.

Petasnick, et al have stated that as the spleen en-

Received June 30, 1971; revision accepted Apr. 22, 1972.

For reprints contact: James R. Wennemark, Sec. of Nuclear Medicine, Dept. of Radiology, University of Tennessee College of Medicine, 800 Madison Ave., Memphis, Tenn. 38103.

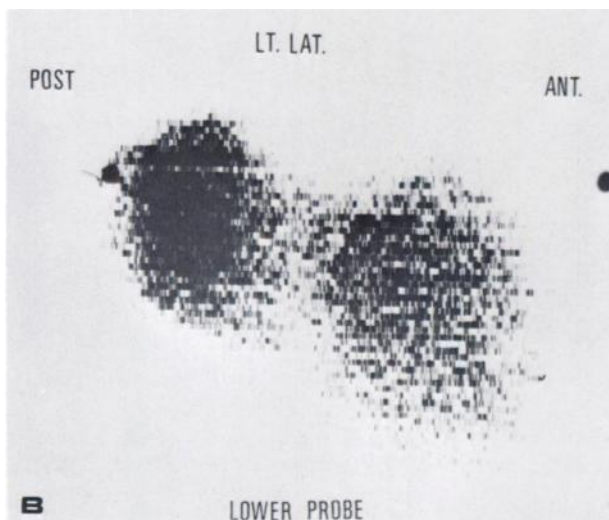
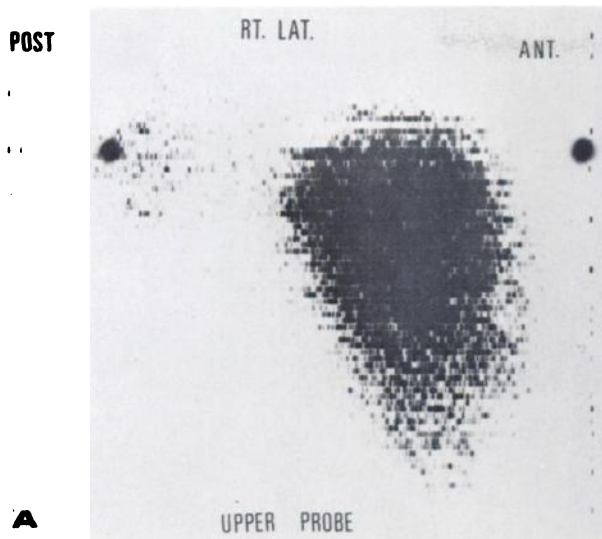


FIG. 1. Patient CMH No. 307865—SNM No. 14602. A, left lateral decubitus position. Liver has triangular appearance with convexity of anterior border. B, left lateral decubitus position. Note well-delineated spleen posteriorly.

larges it extends anteriorly and inferiorly (7). In almost all instances of splenomegaly, the spleen and liver could not be separated from each other on the lateral views. Our study may partially explain why there was no separation; namely, their patients were in the right lateral decubitus position. Anatomically, the spleen is loosely attached so that when the patient is placed in the right lateral decubitus position it has a tendency to move medially, anteriorly, and inferiorly. In the left lateral decubitus position it may move posteriorly. In 50% of our cases radioactivity in the spleen could not be separated from that in the liver when the patient was scanned in the right lateral decubitus position. When the spleen was scanned with the patient in the left lateral decubitus position, it could always be separated from the liver and therefore measured. No definite spleno-

megaly was apparent in any of our cases according to the criteria of Larson, et al (8).

The original reason for becoming interested in this study was the appearance of the liver when patients were scanned in the right lateral decubitus position. Several scans were interpreted as a possible mass lesion in the anterior-superior aspect of the liver (Fig. 2A, large arrow).

The appearance of the lateral liver scan as performed in the left lateral decubitus position is somewhat triangular with convexity of the anterior border

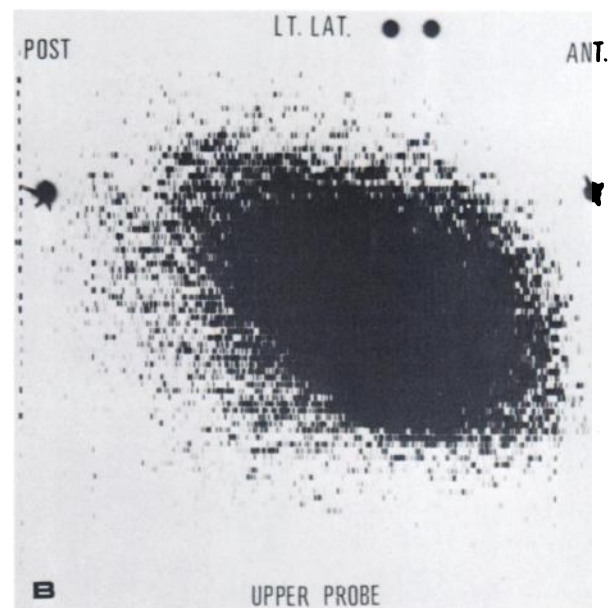
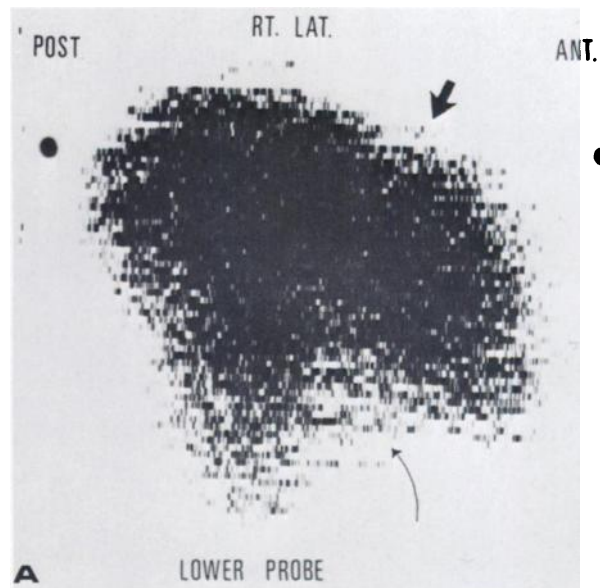


FIG. 2. Patient CMH No. 307865—SNM No. 14602. A, right lateral decubitus position. Note increased thickness of liver, with concavity of anterior superior border (large arrow) and concavity of lower border (small arrow). B, right lateral decubitus position. There is apparent fusion of liver and splenic radioactivity.

of the liver. When the patient is in the right lateral decubitus position the posterior border of the liver is more posteriorly placed which appears to be the result of liver rotation so that it assumes somewhat the shape of a parallelogram. This causes the area of decreased radioactivity in the anterior-superior aspect of the liver.

SUMMARY

Liver and spleen scans have been performed with a dual-probe rectilinear scanner on 24 patients. In the right lateral decubitus position, there is apparent anterior and medial displacement of the spleen so that it cannot readily be separated from the liver and there may appear to be a mass lesion in the anterior-superior portion of the liver. Since these problems have not been encountered in the left lateral de-

cubitus position, it should be used for combined liver-spleen scanning.

REFERENCES

1. Freeman LM, Johnson PM, eds: *Clinical Scintillation Scanning*. New York, Harper & Row, 1969, p 266
2. LaRose JH: Personal communication
3. MAYNARD CD: *Clinical Nuclear Medicine*. Philadelphia, Lea and Febiger, 1969, p 115
4. WILKERSON RH: Liver "imaging" with radionuclide tracers. *N C Med J* 30: 320-326, 1969
5. WAGNER HN: *Principles of Nuclear Medicine*. Philadelphia, WB Saunders, 1968, p 851
6. SORSDAHL OA, BRUNO FP, WILLIAMS CM: Spleen scanning with indium-113m labeled colloid. *Amer J Roentgen* 104: 674-677, 1968
7. PETASNICK JP, GOTTSCHALK A: Spleen scintiphotography with technetium-99m-sulfur-colloid and the gamma-ray scintillation camera. *J Nucl Med* 7: 733-739, 1966
8. LARSON SM, TUELL SH, MOORES KD, et al: Dimensions of the normal adult spleen scan and prediction of spleen weight. *J Nucl Med* 12: 123-126, 1971

WORLD FEDERATION OF NUCLEAR MEDICINE AND BIOLOGY

First World Congress of Nuclear Medicine and Biology

September 30-October 5, 1974

Tokyo and Kyoto, Japan

The First World Congress of Nuclear Medicine and Biology will be held in Tokyo and Kyoto, Japan, from September 30 to October 5, 1974, under the auspices of the World Federation of Nuclear Medicine and Biology (WFNMB).

The Congress is the first international event to be organized following the official foundation of WFNMB in Mexico on October 26, 1970. This meeting represents one of the most authoritative scientific projects ever planned in the field of nuclear medicine based on the Foundation Charter of 1970, and similar meetings are to be held every four years.

The Organizing Committee for the Congress is now making extensive preparations and has selected a meeting date that will not conflict with other international congresses in related fields scheduled for that time of year. Since a large number of participants from all over the world are expected, the Organizing Committee would appreciate information from every country on the number of persons who might attend.

A second progress report on the meeting will be mailed out soon. If you have any questions concerning the congress, please contact:

Hideo Ueda, M.D., President
First World Congress
of Nuclear Medicine and Biology
c/o Japanese Society of Nuclear Medicine
The Second Department of Medicine
Faculty of Medicine, University of Tokyo
7-3-1, Hongo, Bunkyo-ku, Tokyo 113, Japan

Cable Address "WORFEDNUC" Tokyo
Telephone 03-814-0530