

IDENTIFICATION OF CASES OF "ACQUIRED" FUNCTIONAL ASPLENIA

Richard P. Spencer, Howard A. Pearson and Henry J. Binder

Yale University School of Medicine, New Haven, Connecticut

We recently described a state of "functional asplenia" in children with sickle cell anemia. This term was used to describe the failure of the anatomically enlarged spleens of these children to clear intravenously administered radiocolloid (^{99m}Tc -sulfur colloid). The majority of young patients with sickle cell anemia have functional asplenia when studied by this technique (1,2). It is possible that other diseases may also be associated with functional asplenia, a condition which would have certain immediate clinical implications. First, the functionally hyposplenic or asplenic individual may have hematologic abnormalities which might otherwise be of obscure origin. Second, such patients might be susceptible to severe and overwhelming sepsis. Third, since the functional asplenia of sickle cell disease is transiently reversed by blood transfusions in some cases (2) techniques might be devised for reversing the disorder if present in other diseases.

We wish to present three recent cases of functional asplenia in diseases other than sickle cell anemia. We have referred to these as "acquired" functional asplenia to distinguish them from cases found in the genetically determined disease, sickle cell anemia. In addition, because of reported lymphoreticular dysfunction in celiac-sprue disease (3) and the hyposplenic blood smear found in some cases (4), we have examined six patients with celiac-sprue disease in remission.

BACKGROUND

Two criteria were required for establishing a diagnosis of functional asplenia:

1. The spleen had to be anatomically present. Clear evidence was considered to be the presence of a spleen by palpation or its presence by radiographic criteria. In one case we had additional information that the spleen was not only present, but had a blood flow (^{99m}Tc -DTPA blood pool scan). In only one of the cases reported below had an abdominal operation been performed.

2. The ^{99m}Tc -sulfur colloid was standardized. Variations in particle size, resulting from the preparative steps, might hypothetically produce altered splenic uptake. Hence we standardized the particular preparation used to diagnose functional asplenia by showing that it was taken up and distributed normally in at least two other patients.

A commercially available kit (E. R. Squibb) was used for preparing the colloid. A ^{99m}Tc dose of 0.015 mCi/kg body weight in children and 1 mCi in adults was used. Scans were taken with 3 or 5-in. Picker Magnascanners (3-in. focusing collimator). The counts over the liver and spleen were recorded from the most active region of each organ from both anterior and posterior views. Lengths of the liver and spleen were measured to the nearest centimeter on the posterior view (when the spleen was visualized).

Hematologic criteria for deficient splenic function have been described by Crosby (5) and included the presence of intra erythrocytic inclusions such as Howell-Jolly and Heinz bodies as well as abnormally shaped erythrocytes (burr cells, spherocytes and target cells). Celiac-sprue disease was diagnosed in the six patients studied by evidence of malabsorption, the histological appearance of jejunal mucosal biopsies consistent with the diagnosis, and clinical and histopathological response to a gluten free diet.

CASE REPORTS

Case 1. This 26-year-old female (Para 5, Gravid 5) had an uncomplicated pregnancy and delivery. Postpartum chest films revealed a small radiopaque area in the left upper quadrant of the abdomen. Abdominal radiographs showed a pattern consistent with thorotrast (thorium dioxide) in both the spleen and in regional lymph nodes. Past medical history revealed that at age $2\frac{9}{12}$ an arteriogram had been

Received June 19, 1970; original accepted Sept. 30, 1970.

For reprints contact: Richard P. Spencer, Yale University School of Medicine, 333 Cedar St., New Haven, Conn. 06510.

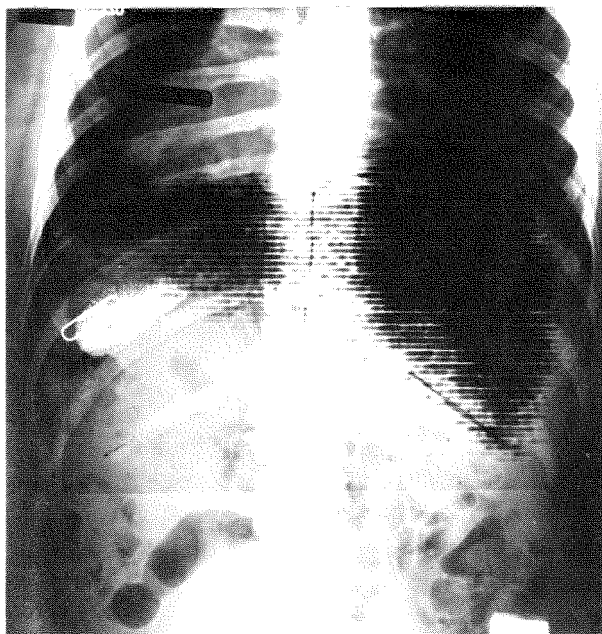


FIG. 1. Posterior scan superimposed on radiograph of Case 1. No ^{99m}Tc activity can be seen in region corresponding to thorotrast-filled spleen. Paper clip is $1\frac{1}{2}$ in. long.

performed because of a facial hemangioma and episodes of left sided paralysis (suggesting an intracranial hemangioma). A ^{99m}Tc -sulfur colloid scan of the abdomen did not reveal any uptake in the region corresponding to the radiographically outlined spleen (Fig. 1), but good accumulation occurred in the liver. The patient's peripheral blood smear revealed Howell-Jolly bodies, spherocytes, burr cells, ovalocytes and other abnormally shaped erythrocytes. Because of the predominance of the retained thorotrast in the spleen, a splenectomy was performed. The spleen weighed 10 gm (we have been able to detect spleens this size when uptake of the radiocolloid occurred).

Case 2. At age 33 months, this girl had a supradiaphragmatic splenic transposition performed at another hospital for Chiari's disease. For 18 months she had been asymptomatic; there were no episodes suggesting infarction of the spleen. Blood smears then showed Howell-Jolly bodies for the first time. The spleen could be clearly seen in the thorax on a chest film. The ^{99m}Tc -sulfur colloid scan revealed uptake by the liver with some activity in the bone marrow. There was no uptake by the transposed spleen. This case will be reported in greater detail by the referring physician.

Case 3. This 25-year-old Negro woman entered the hospital for evaluation of lymphadenopathy, sweating and abdominal enlargement. Biopsy of a node established the diagnosis of reticulum cell sar-

coma. The course was progressively downhill despite chemotherapy (Cytoxan®) and irradiation (1,930 rads to the anterior and posterior abdomen via three ports that included the spleen). Her blood smear reportedly showed burr cells but no detailed hematologic examination was performed. Within 1 year of the initial hospital entry, the patient expired. During the course of her workup, polycystic disease of the kidney was found. A ^{99m}Tc -DTPA scan, taken from the posterior (2 months after irradiation), revealed activity in the liver and kidneys as well as decreased but real activity in the spleen (Fig. 2). A ^{99m}Tc -sulfur colloid scan did not reveal any accumulation in the spleen on the anterior view (Fig. 3) or by posterior counting. The spleen was present and enlarged radiographically. At autopsy the spleen was present and weighed 200 gm. Results of the six cases of celiac-sprue are summarized in Table 1.

DISCUSSION

The functional asplenia accompanying sickle cell anemia can be considered to be a consequence of a genetically determined disease. The cases discussed in the present report may be viewed as "acquired." In the first patient, the functional asplenia was undoubtedly the result of the introduction of thorotrast 24 years previously. The combination of prolonged irradiation, as well as reticuloendothelial blockade due to the thorotrast, probably resulted in splenic




FIG. 2. Posterior scan following injection of 1 mCi of ^{99m}Tc -DTPA in Case 3. Aorta and polycystic kidneys can be seen as well as liver and splenic blood pool. Spleen was present radiographically and weighed 200 gm at autopsy.




FIG. 3. Anterior abdominal scan (dot scan) in Case 3. No splenic activity could be detected on this view or by posterior counting.

hypofunction. The altered blood picture of the "thorotrast spleen" has been described (6). The present case, however, is the first in which it has been shown that the spleen in this disease not only lacks the ability to prevent erythrocyte abnormalities, but also fails to accumulate the radioactive ^{99m}Tc -sulfur colloid. It is uncertain, however, whether these two functions always occur simultaneously.

The second case involved supradiaphragmatic splenic transposition. Since the first report of this type of operation (7), there have been experimental (8) and clinical (9) observations of the beneficial results of the procedure in at least the short-term course of portal hypertension. The rationale is that portasystemic venous collaterals may occur between the transposed spleen and systemic veins in the thorax. An altered blood picture has not been reported as a consequence of the procedure, but this required further study.

The third case, with reticulum cell sarcoma, had at least three conceivable contributions to the functional asplenia. First, the disease itself might be associated with loss of reticuloendothelial activity due to replacement of normal tissue by malignant cells. Second, the patient was receiving radiation therapy and the field included the spleen. Third, she was receiving cyclophosphamide (Cytosan®). It is not yet possible to separate out the respective importance of each of these factors. However, we have seen four other cases of reticulum cell sarcoma, all of which had normal uptake of ^{99m}Tc -sulfur colloid, so malignancy *per se* may not be the cause (all of the other cases studied were more slowly progressing than the reported case).

A blood picture of hyposplenia has been reported in some cases of celiac disease (4), but it is unclear

whether these hematologic changes were observed during the active phase of the disorder. Six cases of celiac-sprue disease reported here (all in remission) had normal splenic uptake of the radiocolloid. It will be of interest to follow cases of this disease through exacerbations and remissions, and to determine whether functional asplenia also appears and disappears and whether it parallels the hematologic changes. If functional asplenia can be reversed by a gluten free diet or other treatment in this disease, it would represent a second distinct type of reversible functional asplenia. The first of these was the transfusion reversible functional asplenia seen in young children with sickle cell anemia.

Cases of functional asplenia can be sought among individuals who have been exposed to agents known to damage the lymphoreticular system (radiation, cytotoxins, various hematological disorders, among others) or who have had surgical intervention on the abdominal blood vessels. The hematological picture of splenic hypofunction should suggest that a spleen scan be performed. Exceedingly helpful has been the recording of the counting rate of activity, after ^{99m}Tc -sulfur colloid administration, over the liver and spleen; this should be part of each liver or spleen scan. Functional asplenia may emerge as a more common disorder than is presently recognized.

SUMMARY

Functional asplenia, defined as the presence of the spleen (by palpation or by radiographic evidence) that fails to accumulate standardized ^{99m}Tc -sulfur colloid has been identified in three individuals with diseases other than sickle cell anemia.

A case of "acquired" functional asplenia was found in a woman 24 years after the injection of thorotrast. The combination of reticuloendothelial blockade and prolonged irradiation may have produced this effect. A second case was noted in a child

TABLE 1. SUMMARY OF ^{99m}Tc -SULFUR COLLOID LIVER-SPLEEN SCANS ON SIX PATIENTS WITH CELIAC-SPRUE DISEASE (IN REMISSION)

Unit no.	Sex	Age (yr) at time of scan	Posterior length (cm)		Posterior spleen/liver count ratio
			Spleen	Liver	
69-1188	F	33	12	17	1:1
69-2089	M	58	12	15	1:0.7
68-113	F	62	8	19	1:2.2
66-400	F	55	24	16	1:1.1
70-394	F	49	11	18	1:1.2
70-390	M	15	13	17	1:0.7

who had surgical transposition of the spleen (the lack of function being due perhaps to vascular alterations). A third case was found in a woman with rapidly progressing reticulum cell sarcoma receiving antineoplastic agents and radiation therapy (although four other cases of reticulum cell sarcoma had normal splenic uptake of the radiocolloid).

Criteria in attempting to identify such individuals (on the basis of hematologic findings or past history) were discussed. Recording of counts over the liver and spleen, from anterior and posterior views, should be a routine part of liver and spleen scans to identify these patients. Although it has been reported that hematologic evidence of hyposplenism can occur in celiac-sprue disease, six cases of this disorder (in remission) all had normal splenic uptake of the radiocolloid. It may also be of value for patients with celiac-sprue to have spleen scans made during remission and exacerbation of the disease to determine whether accumulation of the radiocolloid changes as the disease waxes and wanes.

ACKNOWLEDGMENT

This work was supported by T-492 from the American Cancer Society and by USPHS CA 06519.

REFERENCES

1. PEARSON HA, SPENCER RP, CORNELIUS EA: Functional asplenia in sickle-cell anemia. *New Eng J Med* 281: 923-926, 1969
2. PEARSON HS, CORNELIUS EA, SCHWARTZ A, et al: Transfusion reversible functional asplenia in young children with sickle cell anemia. *New Eng J Med* 283: 334-337, 1970
3. McCARTY CF, FRASER ID, EVANS KT, et al: Lymphoreticular dysfunction in idiopathic steatorrhea. *Gut* 7: 140-148, 1966
4. FERGUSON A, HUTTON MM, MAXWELL JD: Adult coeliac disease in hyposplenic patients. *Lancet* 1: 163-196, 1970
5. CROSBY WH: Hyposplenism: an injury into the normal functions of the spleen. *Ann Rev Med* 14: 349-370, 1963
6. LANGLANDS AO, WILLIAMSON ERD: Late changes in peripheral blood after thorotrast administration. *Brit Med J* 3: 206-208, 1967
7. NYLANDER PEA, TURUNEN M: Transposition at the spleen into the thoracic cavity in cases of portal hypertension. *Ann Surg* 142: 954-956, 1955
8. McCLELLAND RN, BOSHOUR FA: Supradiaphragmatic transposition of the spleen in portal hypertension. *Arch Surg* 98: 175-179, 1969
9. TURUNEN M, PASILA M, SULAMAA M: Supradiaphragmatic transposition of the spleen for portal hypertension: a clinical study. *Ann Surg* 157: 127-133, 1963