

## SCANNING MEDIASTINAL LYMPH NODES

H. Langhammer, G. Hör, H. W. Pabst and E. Hertel

*Institute and Polyclinic for Physical Therapy and Roentgenology of the University of Munich  
and the Orthopedic Clinic of the University of Munich, Munich, Germany*

Isotopic lymphography or radioactive lymphadenography is a recognized method in clinical medicine for the visualization of abdominal lymph nodes. It contributes to the detection of primary lymphonodular destructive disorders (such as Hodgkin's disease) and lymphonodular manifestations of metastatic cancer but provides no information on lymphatic vessels such as can be achieved by roentgenologic lymphangiography.

Visualization of mediastinal lymphatics by radioactive isotopes imposes certain technical difficulties. Previous studies of this area have been concerned largely with scanning retrosternal lymph nodes (1-4). Höfer and Benzer (5) developed a scanning technique for demonstrating hilar and paratracheal lymph nodes. They injected colloidal  $^{198}\text{Au}$  into the mucous membrane of a lower lobe bronchus, but the results were unsatisfactory because of considerable overlap of mediastinal radioactivity and local radioactivity at and near injection sites. Similar experiences were reported by Sahavendan (6) who injected  $^{198}\text{Au}$  intraperitoneally and obtained scans of mediastinal lymphatics in special cases. Ho Choi *et al* (7) chose the intrapulmonary route of introduction of the radionuclide in rabbits and dogs and

succeeded in demonstrating accumulation of radioactivity in the mediastinum. Gold-198 uptake by the liver was significant, and mediastinal areas were not clearly delineated.

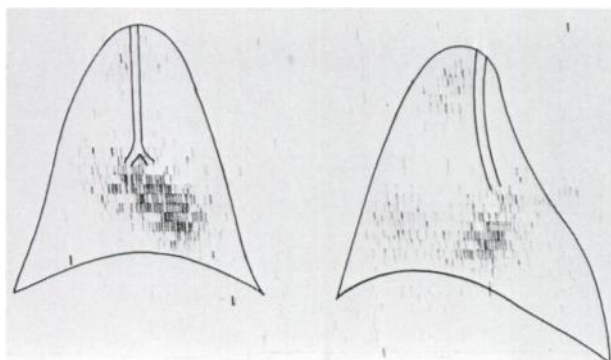
We have performed scans of the mediastinum after *intrapleural* injection of colloidal  $^{198}\text{Au}$ . It was also our intention to compare the results of *intrapulmonary* and *intrapleural* injection of the colloidal radionuclide suspension and to study the different routes of reabsorption and organ distribution within the mediastinum. The results are presented below. We believe that our method is more convincing than this preliminary report indicates.

### ANATOMICAL CONSIDERATIONS AND METHODS

The visceral pleura of the lung contains a very fine capillary network from which lymph drains to deeper lymphatic vessels along the bronchi, eventually reaching hilar and paratracheal lymph nodes. Based upon these anatomical considerations, it seemed practical to use the intrapleural route of administration of the radionuclide instead of injecting it into the lungs as others have done (Ho Choi *et al*). We injected rabbits with  $15\ \mu\text{Ci}$  of  $^{198}\text{Au}$ -colloid in the lungs and pleura simultaneously under fluoroscopic control. Seventy-five units of hyaluronidase (Kinetin®) as a spreading agent were administered concomitantly with the radiogold (injection volume = 1.0 ml). Particle size of the colloids averaged about 50 Å.

Injections of  $15\ \mu\text{Ci}$   $^{198}\text{Au}$ -colloid were made as follows:

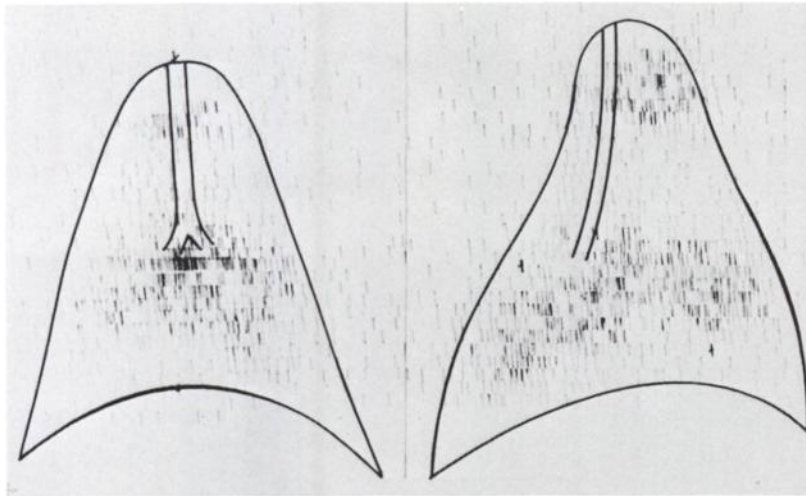
1. into the left basal lung area;
2. into the right basal pleura superior to the right costophrenic sinus;
3. into both lungs and pleura basally.



**FIG. 1.** Scan in supine (left) and right-lateral (right) positions 48 hr after left-sided intrapulmonary injection of  $15\ \mu\text{Ci}$   $^{198}\text{Au}$ .

Received July 15, 1969; revision accepted Sept. 15, 1969.

For reprints contact: Heinz Langhammer, Institut und Poliklinik für Physikalische Therapie und Roentgenologie der Universität München, 8 München 15, den Ziemssenstrasse 1, Germany.



**FIG. 2.** Scan in supine (left) and lateral (right) position 48 hr after right-sided intrapleural injection of 15  $\mu\text{Ci}$   $^{198}\text{Au}$ .

Twenty-four hours later scans were performed in both the anterior and lateral positions of anesthetized animals, and serial scans were made during the next 6 days.

Mediastinal lymph nodes and specimens of mediastinal organs were counted in a twin scale probe and well counter.

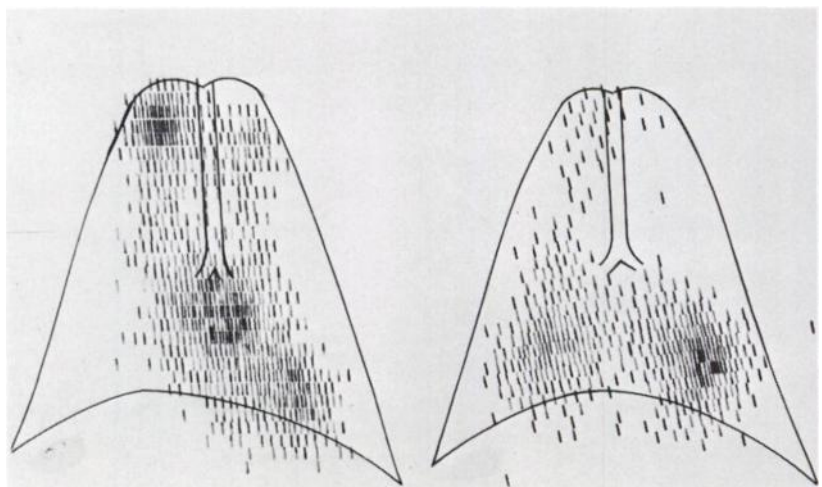
#### RESULTS AND DISCUSSION

There were marked differences in the distribution pattern of radiogold depending upon the route of application. This was first confirmed while scanning the mediastinum. When  $^{198}\text{Au}$  was injected into the left lower area of the *lung*, a broad line of radioactivity terminating in the hilum was recognized (Fig. 1). This scintigraphic picture remained unchanged in control studies performed between 24 and 120 hr postinjection. In the right lateral position a focal accumulation of radioactivity of minor in-

tensity was evident in the area of the upper mediastinum around the *apertura thoracis superioris*. This was due to concentration of radioactive material in mediastinal lymph nodes as will be shown later. A similar accumulation of radioactivity was observed in the region of the inferior thorax (lower mediastinum).

When  $^{198}\text{Au}$  was injected into the *pleura*, we found a focal accumulation of radioactivity in the region of the hilum and the upper mediastinum (Fig. 2). The total amount of injected radioactivity was reabsorbed from the site of inoculation, and there was complete permeation of the radiopharmaceutical. This was also ascertained by comparing scans in the lateral position.

Identical results were obtained by simultaneous injection of  $^{198}\text{Au}$  into both lungs and pleura basally (Fig. 3). Distribution of  $^{198}\text{Au}$  differed depending upon the mode of application. When  $^{198}\text{Au}$  was injected into the lungs most of the radioactivity was



**FIG. 3.** Comparison of scintigraphic pictures after bilateral injection of  $^{198}\text{Au}$ . Left: intrapleural injection; right: intrapulmonary injection.

detected at the point of the injection. A lesser accumulation was visualized in the right upper mediastinum, indicating that only a small fraction of the tracer was reabsorbed by lymphatic vessels. Concentration of  $^{198}\text{Au}$  was restricted to the hilar regions and upper mediastinum when the colloid was injected into the pleurae. Accurate injection into the pleura is the most decisive factor for exact visualization of mediastinal lymphatics.

The radioactivity measurements of the different organs confirmed the selective accumulation of  $^{198}\text{Au}$  within mediastinal lymph nodes after intrapleural injection. Measurements also revealed insignificant amounts of radioactivity in mediastinal lymph nodes when  $^{198}\text{Au}$  was injected into the lungs. Heart and visceral pleura were free of  $^{198}\text{Au}$ . Some radiogold uptake was observed in the liver after intrapleural injection, but no hepatic uptake was registered when  $^{198}\text{Au}$  was injected into the lungs.

#### CONCLUSIONS AND SUMMARY

These experiments show that visualization of mediastinal lymphatics, including hilar lymph nodes, may be obtained by accurate injection of colloidal  $^{198}\text{Au}$  into the pleural space (indirect isotope lymphadenography). Our method is superior to previously devel-

oped procedures based upon intrapulmonary injection. Further studies in man seem to be encouraging.

#### REFERENCES

1. MICHAILOV, V. G.: Mitrov und Chr. Mlatschkov: Indirekte Isotopenlymphographie der parasternalen Lymphknoten mit radioaktivem Au-198. *Rad. biol. Ther.* 3:229, 1968.
2. ROSSI, R. AND FERRI, O.: La Visualizzazione della catena mammariae interna con  $^{198}\text{Au}$ . Presentazione di una nuova metodica: la linfoscintigraphia. *Minerva med.* 57: 1,151, 1966.
3. SCHENCK, P.: Szintigraphische Darstellung des parasternalen Lymphsystems. *Strahlentherapie* 130:504, 1966.
4. SCHENCK, P., ZUM WINKEL, K. AND BECKER, J.: Die Szintigraphie des parasternalen Lymphsystems. *Nucl. Med.* 5:388, 1966.
5. HÖFER, R. UND BENZER, H.: Die indirekte Lymphographie der Lungen. VIII. Symposium Radioaktive Isotope in Klinik und Forschung. Bad Gastein, Januar, 1966.
6. SAHAVENDAN, V.: Das mediastinale Lymphknoten-scanning. Radioisotope in der Lokalisationsdiagnostik. 4. Jahrestagung der Gesellschaft für Nuclearmedizin, Heidelberg, 1966. Schattauer Stuttgart, 1967 S. 519.
7. HO CHOI, S., GORDON, W., SHEEHAN, F. R. AND BENDER, M. A.: Radioisotope scanning of the mediastinal lymphatics in animals. *Acta Radiol.* 52:229, 1964.
8. MAGNENAT, P. ET DELALOYE, B.: La Lymphographie Hepatique Isotopique. Radioaktive Isotope in Klinik und Forschung. Band VI. Hrsg. K. Fellinger und R. Höfer, Urban & Schwarzenberg, München, Berlin, 1963.