Journal of Nuclear Medicine, published on February 14, 2020 as doi:10.2967/jnumed.119.238071

Multi-phasic ^{68}Ga-PSMA PET/CT in detection of early recurrence in prostate cancer patients with PSA < 1 ng/ml: a prospective study of 135 cases.

Mohsen Beheshti[1,2,3], Reyhaneh Manafi-Farid[4], Hans Geinitz[5], Reza Vali[6], Wolfgang Loidl[7], Felix M Mottaghy[1,8], Werner Langsteger[3]

[1] Department of Nuclear Medicine, University Hospital, RWTH University, Aachen, Germany

[2] Department of Nuclear Medicine, Paracelsus Medical University, Salzburg, Austria

[3] Department of Nuclear Medicine & Endocrinology, PET-CT Center LINZ, St. Vincent's Hospital, Linz, Austria

[4]Research Center for Nuclear Medicine, Shariati Hospital, Tehran University of Medical Sciences, Tehran, Iran

[5] Department of Radiation-Oncology, St. Vincent's Hospital, Linz, Austria

[6]Department of Diagnostic Imaging, The Hospital for Sick Children, University of Toronto, Toronto, Canada

[7] Department of Urology, St. Vincent's Hospital, Linz, Austria

[8]Department of Radiology and Nuclear Medicine, Maastricht University Medical Center, Maastricht, Netherlands

Correspondence:

Mohsen Beheshti, MD, FEBNM, FASNC

Department of Nuclear Medicine

University Hospital, RWTH University

Pauwelsstrasse 30

52074-Aachen, Germany

Tel.: +49-241-8085194

E-Mail: mbeheshti@ukaachen.de

ABSTRACT

Purpose: The main objective of this prospective study was to determine the impact of multi-phasic acquisition of ^{68}Ga-PSMA PET/CT in the detection of recurrent prostate cancer (PCa) in the early stage of biochemical recurrence (BR) with prostate-serum-antigen (PSA) level <1ng/ml. Also, ^{68}Ga-PSMA PET/CT positivity was correlated with clinical parameters for the assessment of predictive markers.

Methods: A prospective monocentric study was conducted on 135 PCa patients with BR and PSA<1ng/ml. All patients have undergone initial prostatectomy with additional radiation therapy in 19.3% and androgen-deprivation therapy (ADT) in 7.4% of patients.

Dynamic acquisition [1–8min. post-injection (p.i.)] from the prostate bed, standard whole-body (60min. p.i.) and limited bed positions of delayed studies (120-150min. p.i.), were performed. Studies were reviewed by two board-certified nuclear medicine specialists, independently. A combination of visual and semi-quantitative analyses and correlation with morphological (e.g. MRI) and/or clinical follow-up findings was used for the final interpretation of abnormal lesions as benign or malignant. ^{68}Ga-PSMA PET/CT positivity was also correlated with primary clinical findings.

Results: Incorporating the information of all phases, 116 lesions were detected in 49.6% of patients (22 local recurrences, 63 lymph nodes, and 31 distant metastases). The detection rates were 31.8%, 44.9%, and 71.4% for PSA<0.2ng/ml, 0.2≤PSA<0.5, and 0.5≤PSA<1, respectively. Additional dynamic and/or delayed phases resulted in better determination of equivocal lesions and a higher diagnostic performance in 25.9% of patients. Stand-alone dynamic and delayed

images led to better interpretation of equivocal findings in the prostate bed (31.4%) and other (lymph node/bone) lesions (20%), respectively.

Conclusion: ^{68}Ga-PSMA PET/CT revealed promising results for the early detection of recurrent disease in patients with PSA level of 0.5-1.0ng/ml. However, it showed limited value in cases with PSA<0.5ng/ml. Multi-phasic 68Ga-PSMA PET/CT led to better determination of equivocal findings. Although, dynamic images may provide helpful information in assessment of the prostate bed; however, delayed acquisitions seem to have higher impact in clarifying of the equivocal findings.

Key words:

Prostate cancer recurrence, ^{68}Ga-PSMA PET/CT, multi-phasic imaging, Low PSA

Running title:

Multi-phasic PSMA-PET/CT in Prostate Cancer

INTRODUCTION

Prostate cancer (PCa) is the second most common cancer worldwide, responsible for 6.7% of cancer-related mortality among men *(1*). Biochemical recurrence (BR) after initial treatment is a common phenomenon *(2*), reported in 20–30% of patients after radical prostatectomy, and up to 60% after external radiation-therapy *(3*). Therefore, the early detection of recurrent disease may provide a chance for salvage therapy and improve prognosis *(3,4*). The 5-year-survival drops to 30% in cases with distant metastases indicating the importance of discrimination between the locoregional, oligometastatic or distant spread of the disease *(5*).

Several clinical parameters and imaging techniques are used to diagnosis the recurrent disease, among which prostate-specific-antigen (PSA) is of particular relevance *(6*). The impact of molecular imaging using positron emission tomography/computed tomography (PET/CT) in the detection of the recurrent PCa disease seems bolder with the advent of specific PET tracers. However, the detection of early recurrence in patients with low PSA (e.g. <1.0ng/ml) remains a matter of challenge *(4,7,8*).

Prostate-specific-membrane-antigen (PSMA) is expressed particularly in prostatic cells and is one of the main targets for depicting the cancerous tissues *(9,10*). Various PSMA-radioligands are employed in PET imaging, such as e.g. ^{68}Ga-PSMA-11, ^{68}Ga-PSMA I&T, and ^{18}F-PSMA-1007 *(11,12*). These agents demonstrate different characteristics. Longer half-life, better physical spatial resolution, and lower urinary excretion are the prominent advantages of eg ^{18}F-–PSMA-1007 comparing to ^{68}Ga-labeled PSMA. Low urinary activity of ^{18}F-labeled PSMA may overcome the limitation of ^{68}Ga-ligand PSMA in the assessment of pelvic lesions due to high tracer accumulation in urinary bladder *(12,13*).

Despite the advantages of ^{68}Ga-PSMA PET/CT, as one of the most commonly used radiotracers in the assessment of BR, it showed limited value in patients with PSA <1.0ng/ml *(8,14-16*). This may be related to urinary excretion and the intense activity in the bladder which may obscure small locoregional lesions. Multiple studies using early images have been conducted to overcome the impact of intense physiologic activity in the bladder *(17,18*). Early or delayed imaging has revealed an additive value in improving the detection rate *(11,18,19*).

In this prospective study, we evaluated the impact of early dynamic and delayed images on diagnostic performance of ^{68}Ga-PSMA PET/CT in early assessment of BR in PCa patients with PSA<1.0ng/ml. Also, we correlated relevant predictive clinical factors with scan results to study when ^{68}Ga-PSMA PET/CT would be of maximal benefit.

MATERIALS AND METHODS

Patients

This prospective single-center study was performed in accordance with the principles of the 1964 Declaration of Helsinki and its later amendments or comparable standards and approved by the institutional review board with trial number of "EKS 10/19/EC-2017-005078-20" in the course of the clinical diagnostic workup of PCa patients. Signature of the written informed consent was obtained from all individual participants included in the study.

In this study, 135 consecutive PCa patients (mean age: 66.8±8.0) with evidence of early biochemical recurrence and PSA<1.0ng/ml were included (Table 1). They all were referred to PET-CT Center, St. Vincent's Hospital, Linz, Austria from July 2017 to February 2019. In 19.3% (26/135) and 7.4% (10/135) of patients, radiation therapy and androgen-deprivation therapy (ADT) has been performed after recurrence, respectively. The interval between primary treatment and ^{68}Ga-PSMA PET/CT studies were 2-266 months (median:42).

Radiotracer Preparation

^{68}Ga-PSMA-11 was prepared using a lyophilized sterile cold kit (ANMI SA, Liege, Belgium) using a commercial GMP manufactured ^{68}Ge/^{68}Ga generator. The feasibility of this preparation method in clinical practice is demonstrated in our previous study *(15)*.

PET/CT Acquisition and Image Reconstruction

The study was performed with a dedicated PET/CT scanner (Discovery 710; GE Healthcare) with an extended field-of-view (FOV) full-ring high-resolution LSO PET component and a 128-slice spiral CT. Images were acquired at two (in all patients) and three (in 97 patients) time-points after a bolus injection of ^{68}Ga-PSMA-11 (2MBq/kg body-weight). Early dynamic images started at the first

minute (min.) post-injection (p.i.). The acquisition field was targeted on the prostatic bed (15.6cm axial-FOV). The early dynamic phase was continued for 8 minutes, 60 seconds/frame with low-dose CT. Standard whole-body images were performed for 2.5min/bed position, 60min. p.i., from the skull-base to the proximal thigh alongside diagnostic contrast enhanced-CT. Finally, the delayed images were obtained - at least 2 bed-positions - covering the pelvic and lower abdominal regions, as well as upper abdominal or thoracic regions in some cases, 120-150 min. p.i. accompanied by low-dose CT.

In 38 (28%) cases delayed examination was not performed because of clear PET findings in the pelvis and/or lack of patient's compliance in continuing the examination. Moreover, those studies that were not obtained in the scheduled time-frame were excluded from the study.

In case of equivocal or unclear findings in the other parts of the body, additional images were obtained for further clarification. Images were reconstructed identically using the ordered-subsets expectation maximization algorithm (4 iterations, 18 subsets) followed by a post-reconstruction smoothing Gaussian filter (4.0mm full-width at half-maximum). In all patients, a contrast enhanced-CT scan with a high beam tube-current modulation (120–330mA, 0.6s/rotation, 5.0mm reconstructed section thickness, 0.5mm overlap, 512×512 matrix, pitch index 1.5) was performed.

Image Interpretation

Independent consecutive blinded reading of each examination phase was performed by two experienced board-certified nuclear medicine specialists who were only aware of the clinical information (e.g. PSA value). In case of equivocal findings or discrepancies between the two readers, the lesions were discussed for final interpretation in a consensus meeting. Finally, a combination of visual and semi-quantitative analyses and correlation with morphological (e.g. magnetic resonance imaging) and/or clinical follow-up findings was used for ultimate classification of the abnormalities as benign or malignant.

Every frame of dynamic phase images was examined separately. Advanced PET/CT software (AW-4.6; GE Medical Systems) was used for reading. Respecting substantially high specificity of ^{68}Ga-PSMA *(2*), we speculated that every clear abnormal tracer uptake, which cannot be explained by

physiologic ^{68}Ga-PSMA activity was positive for tumoral involvement. The final interpretation was based on the findings of all 3 acquisition phases. The finding was considered equivocal when the presence of urinary activity was suspected in the typical anatomical localizations, or lesions with an abnormal tracer accumulation showing mild intensity without definite morphologic findings, especially in the prostate bed or iliac regions. In such lesions, the findings of dynamic or delayed acquisition were used for better classification of the equivocal lesions as benign or malignant. Considering the anatomical location, lesions were categorized into four groups: local recurrence in prostate bed, pelvic lymph nodes (internal, external, common iliac, and presacral regions), bone and visceral metastases.

Maximum standardized uptake values (SUVmax) was calculated by drawing a volume-of-interest over suspicious areas in each phase. SUVmax of the lesions in the dynamic phase was evaluated at the 4thmin. of the study. This was due to previous experiences and the visualization of the lesions on dynamic images at mean time of 2.9±1.9min. (median: 3.0) and the urinary activity appreance at mean time of 6.1±1.2min. (median: 6.0). To maintain unity, those lesions not visualized up to the 4thmin. were excluded from the semi-quantitative analysis by means of SUV.

Furthermore, background tracer uptake in soft tissue was evaluated by drawing a standard reference volume-of-interest on the right gluteus muscle sparing intramuscular vessels in each phase.

Statistical Analysis

Numerical data are presented as median or mean±SD. Statistical analysis was conducted with dedicated software (SPSS 23.0; IBM Corp., Armonk, NY). The relationship between PET/CT positivity and clinical parameters were evaluated. Data which showed normal data distribution on Kolmogorov–Smirnov test were analyzed using the independent t-test with 95% confidence intervals. Also, data which did not show a normal data distribution were compared using the nonparametric tests, such as initial PSA and current PSA using Mann-Whitney test; history of radiation therapy and ADT using Chi-square test; and numbers and SUV of the lesions using Wilcoxon test. A p-value<0.05 was considered significant.

RESULTS

Patient-Based Analysis

The patients were categorized into three groups based on PSA level at the day of examination (trigger-PSA): PSA<0.2ng/ml (16.3%; 22/135), 0.2≤PSA<0.5 (57.8%; 78/135), and 0.5≤PSA<1 (25.9%; 35/135).Considering the results of all three phases, at least one pathologic lesion was detected in 49.6% (67/135) of patients.

The dynamic, standard whole-body and delayed images were positive in 27.4% (37/135), 48.1% (65/135), and 43.3% (42/97) of the patients, respectively.

^{68}Ga-PSMA PET/CT showed a detection rate of 31.8%, 44.9%, and 71.4% in patients with PSA<0.2ng/ml, 0.2≤PSA<0.5 and 0.5≤PSA<1, respectively (Table 2).
There was a significant correlation between ^{68}Ga-PSMA PET/CT positivity and trigger-PSA level ($p<0.001$), even after evaluation of each phase separately ($p<0.003$). Moreover, considering the final interpretation, the history of ADT was found to be a predictive factor for positive scans ($p=0.008$). However, no significant correlation was observed between ^{68}Ga-PSMA PET/CT positivity and primary clinical parameters, such as initial PSA, Gleason score, disease grade, T-stage, surgical margin, the history of radiation-therapy, and the time interval from initial treatment.

Given the fact that the FOV of standard whole-body scan provides a general overview on the examined structures compared to the limited views of dynamic and delayed images, only the similar FOV of the pelvic region was considered in correlation analyses between different phases. Therefore, only 81 studies were relevant for the comparative analysis. The overall detection rates in the same FOV were 28.4%, 39.8%, and 35.5% for dynamic, standard whole-body, and delayed phases, respectively. Standard whole-body images showed significant superiority in comparison to only dynamic phase ($p=0.012$).

Lesion-Based Analysis

A total number of 25, 42 and 39 tumoral lesions were detected in the identical FOV in the pelvic area on dynamic, standard whole-body and delayed images, respectively (Table 3). There was a

significantly higher detection rate of lymph nodes on standard whole-body compared to dynamic phase (p=0.004). However, no superiority was seen in the depiction of local recurrences (p=0.37). Additionally, standard whole-body and delayed images demonstrated similar performance in revealing suspicious lesions in the same FOV, regarding both local recurrences and lymph node metastases (p=0.37). There were only a few numbers of bone and visceral metastases in the pelvic area to draw a clinical statement (Table 3).

Semi-quantitative analysis by means of SUVmax showed a significant increasing pattern from dynamic to standard whole-body acquisition in lymph nodes (p=0.006), while there was no significant change in SUVmax in local recurrent lesions, as well as between standard whole-body and delayed images (p=0.50) (Table 4).

SUVmax of detected lymph nodes was lower in sub-centimetric lesions on standard whole-body (p=0.023) and delayed (p=0.005) images. However, there was no significant difference of SUVmax of local recurrent lesions in sub-centimetric versus larger lesions (Table 4).

Impact of Multi-Phasic Scanning

In 25.9% (35/135) of patients, equivocal findings or discrepancies were observed in at least one lesion between different phases of scanning. In order to confidently differentiate positive from negative results, we defined a general interpretation, according the study protocol, considering all phases and looked for possibly more information provided by dynamic and delayed images. We encountered two patients (1.5%) with negative standard whole-body studies, in whom obvious positive lesions were present, one on dynamic and the other on delayed images (Fig. 1 and 2). Nevertheless, the impact of additional studies was mainly by clarifying equivocal findings in the remainder of patients.

Additional images (i.e. dynamic, delayed, or both of them) provided more data for better delineation of the equivocal findings resulting in positive final interpretation in 13.3% (18/135) and negative final reading in 12.6% (17/135) of patients (Table 5; Fig. 3). In these cases, stand-alone dynamic images were informative in 31.4% of patients, stand-alone delayed in 20.0%, either dynamic or delayed in 37.1%, and both dynamic and delayed in 11.5%. Overall, additional delayed scans were more helpful in better determination of the equivocal lesions.

DISCUSSION:

In the current prospective study, we focused on 3 aspects: first, the impact of ^{68}Ga-PSMA PET/CT in recurrent PCa; second, the value of early dynamic and delayed studies on the diagnostic performance of ^{68}Ga-PSMA PET/CT compared to standard whole-body images; and finally, the correlation between clinical parameters (i.e. initial PSA, Gleason score, etc.) and ^{68}Ga-PSMA PET positivity in BR.

^{68}Ga-PSMA PET/CT has demonstrated promising results in the assessment of PCa recurrence *(14,15,20*). Although previous studies have reported a close correlation between PSA values and the ^{68}Ga-PSMA PET/CT positivity, its diagnostic accuracy in patients with low PSA levels has been discussed controversially *(2,19,21*). In an early study, Eiber et al. retrospectively examined the value of ^{68}Ga-PSMA PET/CT in 248 PCa patients with BR. They found sensitivities of 57.9% and 72.7% for PSA levels of 0.2 to <0.5ng/ml and 0.5 to <1ng/ml, respectively *(21*). In a study with a large patient's population, Afshar-Oromieh et al. reported an overall detection rate of 79.5% in 1007 PCa patients with BR and a median PSA level of 2.2ng/ml; and sensitivities of 46%, 46%, and 73% for PSA≤0.2ng/ml, 0.21-0.5ng/ml, and 0.51-1.0ng/ml, respectively *(2*). The findings of our study were in consistence with previous retrospective reports showing detection rates of 31.8%, 44.9%, and 71.4% for PSA<0.2ng/ml, 0.2≤PSA<0.5 and 0.5≤PSA<1, respectively. Furthermore, distant metastases were detected in 3% of patients even with very low PSA levels (≤0.5ng/ml), which was of great clinical relevance for therapeutic decision making.

The impact of early dynamic and multiple time-point acquisition of ^{68}Ga-PSMA PET/CT has been investigated in previous studies *(15,19,22*). Uprimny et al. reported a detection rate of 62.1% for ^{68}Ga-PSMA PET/CT in 203 recurrent PCa patients with median PSA level of 1.44ng/ml *(19*). However, only 20.2% of patients had a PSA level less than 0.5ng/ml. Additionally, the dynamic imaging was started about 5 minutes after tracer injection. Low number of patients with PSA<1.0ng/ml and performing the dynamic imaging 5min. p.i.. Based on our experience, renal excretion of ^{68}Ga-PSMA is usually seen 4–6min. after tracer injection; thus, performing the dynamic acquisition after 5 minutes may affect the interpretation of the pelvic lesions. Furthermore, it has been reported that the tumoral lesions are commonly visualized in the first 3 minutes of the study when no urinary activity is present in the bladder *(18,19*). However, in our

study, some lesions (6 small recurrent lesions and 7 lymph nodes) were detected after the 3rd minute. This mainly contributes to the considerable presence of the tracer in iliac vessels in initial frames, obscuring the adjacent lymph nodes.

In the current study, performing dynamic images provides better performance in the detection of local recurrence, which was consistent with the findings of other reports *(18*). Additional dynamic and delayed images led to the better classification of lesions in 26% of patients with indeterminate or negative findings on standard whole-body scans. These additional acquisitions changed equivocal findings into positive final interpretations in 13.3% of patients and negative final reading in 12.6% (Table 5). Standard whole-body phase alone seems unsatisfactory in a considerable number of patients with low PSA levels for an accurate interpretation.

Furthermore, three local recurrent lesions and one lymph node observed on dynamic or standard whole-body were not visible on delayed images, when considering the same FOV. The considerably small size of lesions and lower tumor-to-background ratio, may justify this observation. The rapid washout phenomenon can be another reason for falsely negative delayed images in certain cases. Slow internalization and moderate affinity to PSMA in some tumor cells may lead to a rapid activity wash out from tumors *(23*).

The correlation between clinical parameters (e.g. trigger-PSA and ADT) with ^{68}Ga-PSMA PET/CT positivity in recurrent PCa patients has been discussed controversially; mostly showing a correlation with shorter PSA doubling time *(2,9,21*). Our results were compatible with previous reports showing higher detection rates corresponding with trigger-PSA, which seems to be an invariable factor *(2,24*). However, our data additionally showed a correlation between ^{68}Ga-PSMA PET/CT positivity and history of receiving ADT (at any time point). This finding may be related to the primary stage of disease, as administrating ADT after prostatectomy may imply more advanced disease which may cause higher rates of recurrence. Nevertheless, we found no correlation between Gleason score and positive PET/CT results.

The main limitation of our study was the lack of histopathological verification. This was mainly due to the small lesion size and challenging access of the lesions. Moreover, it was not ethical to obtain a biopsy when a consensus existed among the scan results, anatomical imaging (e.g. MRI),

and clinical findings. Furthermore, small common FOV in various phases of PET/CT acquisition limited the number of analyzed lesions available for accurate comparative assessment. Various FOV of different phases (e.g. one bed-position in dynamic versus 2 or more on delayed or whole-body acquisitions) may cause a bias in the results of this study. In addition, the cost effectiveness of ^{68}Ga-PSMA PET/CT in patients with low PSA value (i.e. <1ng/ml) and its impact on patient's management is an important issue, which should be evaluated in future studies. In our opinion, there is also an unmet need for optimization of the ^{68}Ga-PSMA PET/CT imaging protocols to improve its diagnostic performance in individual cases (e.g. early recurrence and low PSA value), who are being considered for salvage treatment.

Finally, the small number of patients who had a history of receiving ADT limits the statistical power of the result in this group. Studies with larger number of patients are needed to further evaluate the correlations between ^{68}Ga-PSMA PET/CT positivity and history of receiving ADT.

CONCLUSION

Multi-phasic imaging, by clarifying equivocal findings, seems to improve the diagnostic performance of ^{68}Ga-PSMA PET/CT in prostate cancer patients with early BR and low PSA (i.e. <1.0ng/ml), where early detection of recurrent disease provides better chance for salvage therapy and prognosis. Furthermore, trigger-PSA and history of ADT seem to be predictive of ^{68}Ga-PSMA PET/CT positivity.

DISCLOSURE

No potential conflicts of interest relevant to this article exist.

KEY POINTS

QUESTION: Does multi-phasic acquisition improve the diagnostic performance of ^{68}Ga-PSMA PET/CT in PCa patients with PSA<1ng/ml?

PERTINENT FINDINGS: This prospective study assessed the impact of multi-phasic acquisition on diagnostic performance of ^{68}Ga-PSMA PET/CT in 135 PCa patients with BR and PSA<1ng/ml. The detection rates were 31.8%, 44.9%, and 71.4% for PSA<0.2ng/ml, 0.2≤PSA<0.5, and 0.5≤PSA<1, respectively.

Reviewing the findings in all phases resulted in better determination of the undetermined lesions leading to higher diagnostic performance in 25.9% of patients.

IMPLICATIONS FOR PATIENT CARE: Multi-phasic imaging seems to improve the diagnostic performance of ^{68}Ga-PSMA PET/CT in early BR and low levels of PSA (i.e. <1.0ng/ml), where early detection of recurrent disease provides better chance for salvage therapy and prognosis.

REFERENCES

1. Bray F, Ferlay J, Soerjomataram I, Siegel RL, Torre LA, Jemal A. Global cancer statistics 2018: GLOBOCAN estimates of incidence and mortality worldwide for 36 cancers in 185 countries. *CA Cancer J Clin.* 2018;68(6):394-424.
2. Afshar-Oromieh A, Holland-Letz T, Giesel FL, et al. Diagnostic performance of 68 Ga-PSMA-11 (HBED-CC) PET/CT in patients with recurrent prostate cancer: evaluation in 1007 patients. *Eur J Nucl Med Mol Imaging.* 2017;44(8):1258-1268.
3. Witkowska-Patena E, Mazurek A, Dziuk M. 68Ga-PSMA PET/CT imaging in recurrent prostate cancer: Where are we now? *Cent European J Urol.* 2017;70(1):37-43.
4. Castellucci P, Ceci F, Graziani T, et al. Early biochemical relapse after radical prostatectomy: which prostate cancer patients may benefit from a restaging 11C-Choline PET/CT scan before salvage radiation therapy? *J Nucl Med.* Sep 2014;55(9):1424-1429.
5. National Cancer Institute S, Epidemiology, and End Results Program. Cancer Stat Facts: Prostate Cancer. n.d.; https://seer.cancer.gov/statfacts/html/prost.html. Accessed March 15, 2019.
6. European Association of Urology. Prostate Cancer. http://uroweb.org/guideline/prostate-cancer/#7. Accessed March 15, 2019.
7. Beheshti M, Haim S, Zakavi R, et al. Impact of 18F-choline PET/CT in prostate cancer patients with biochemical recurrence: influence of androgen deprivation therapy and correlation with PSA kinetics. *J Nucl Med.* 2013;54(6):833-840.
8. Schwarzenboeck SM, Rauscher I, Bluemel C, et al. PSMA ligands for PET imaging of prostate cancer. *J Nucl Med.* 2017;58(10):1545-1552.
9. Perera M, Papa N, Christidis D, et al. Sensitivity, Specificity, and Predictors of Positive (68)Ga-Prostate-specific Membrane Antigen Positron Emission Tomography in Advanced Prostate Cancer: A Systematic Review and Meta-analysis. *Eur Urol.* 2016;70(6):926-937.
10. Cuccurullo V, Di Stasio GD, Mansi L. Nuclear medicine in prostate cancer: a new era for radiotracers. *World J Nucl Med.* 2018;17(2):70-78.
11. Schmuck S, Mamach M, Wilke F, et al. Multiple time-point 68Ga-PSMA I&T PET/CT for characterization of primary prostate cancer: value of early dynamic and delayed imaging. *Clin Nucl Med.* 2017;42(6):e286-e293.
12. Kesch C, Kratochwil C, Mier W, Kopka K, Giesel FL. 68Ga or 18F for prostate cancer imaging? *J Nucl Med.* 2017;58(5):687-688.
13. Rahbar K, Afshar-Oromieh A, Seifert R, et al. Diagnostic performance of 18 F-PSMA-1007 PET/CT in patients with biochemical recurrent prostate cancer. *Eur J Nucl Med Mol Imaging.* 2018;45(12):2055-2061.
14. Caroli P, Sandler I, Matteucci F, et al. 68 Ga-PSMA PET/CT in patients with recurrent prostate cancer after radical treatment: prospective results in 314 patients. *Eur J Nucl Med Mol Imaging.* 2018;45(12):2035-2044.
15. Beheshti M, Paymani Z, Brilhante J, et al. Optimal time-point for 68 Ga-PSMA-11 PET/CT imaging in assessment of prostate cancer: feasibility of sterile cold-kit tracer preparation? *Eur J Nucl Med Mol Imaging.* 2018;45(7):1188-1196.
16. von Eyben FE, Picchio M, von Eyben R, Rhee H, Bauman G. 68Ga-labeled prostate-specific membrane antigen ligand positron emission tomography/computed tomography for prostate cancer: a systematic review and meta-analysis. *Eur Urol Focus.* 2018;4(5):686-693.
17. Sachpekidis C, Pan L, Hadaschik BA, Kopka K, Haberkorn U, Dimitrakopoulou-Strauss A. 68Ga-PSMA-11 PET/CT in prostate cancer local recurrence: impact of early images and parametric analysis. *Am J Nucl Med Mol Imaging.* 2018;8(5):351-359.

18. Uprimny C, Kroiss AS, Decristoforo C, et al. Early dynamic imaging in 68 Ga-PSMA-11 PET/CT allows discrimination of urinary bladder activity and prostate cancer lesions. *Eur J Nucl Med Mol Imaging.* 2017;44(5):765-775.
19. Uprimny C, Kroiss AS, Fritz J, et al. Early PET imaging with [68] Ga-PSMA-11 increases the detection rate of local recurrence in prostate cancer patients with biochemical recurrence. *Eur J Nucl Med Mol Imaging.* 2017;44(10):1647-1655.
20. Uprimny C, Kroiss AS, Decristoforo C, et al. 68 Ga-PSMA-11 PET/CT in primary staging of prostate cancer: PSA and Gleason score predict the intensity of tracer accumulation in the primary tumour. *Eur J Nucl Med Mol Imaging.* 2017;44(6):941-949.
21. Eiber M, Maurer T, Souvatzoglou M, et al. Evaluation of Hybrid (6)(8)Ga-PSMA Ligand PET/CT in 248 Patients with Biochemical Recurrence After Radical Prostatectomy. *J Nucl Med.* 2015;56(5):668-674.
22. Afshar-Oromieh A, Hetzheim H, Kübler W, et al. Radiation dosimetry of 68 Ga-PSMA-11 (HBED-CC) and preliminary evaluation of optimal imaging timing. *Eur J Nucl Med Mol Imaging.* 2016;43(9):1611-1620.
23. Mitran B, Varasteh Z, Abouzayed A, et al. Bispecific GRPR-Antagonistic Anti-PSMA/GRPR Heterodimer for PET and SPECT Diagnostic Imaging of Prostate Cancer. *Cancers (Basel).* Sep 14 2019;11(9).
24. Afshar-Oromieh A, Avtzi E, Giesel FL, et al. The diagnostic value of PET/CT imaging with the (68)Ga-labelled PSMA ligand HBED-CC in the diagnosis of recurrent prostate cancer. *Eur J Nucl Med Mol Imaging.* 2015;42(2):197-209.

Table 1. Detail regarding patients data			
		Percent	Number
T stage			135 patients
	1a	1.5%	2
	2 (not specified)	4.4%	6
	2a	4.4%	6
	2b	3.7%	5
	2c	30.4%	41
	3 (not specified)	3.0%	4
	3a	32.6%	44
	3b	16.3%	22
	4	3.0%	4
	Tx	0.7%	1
N stage			**135 patients**
	0	81.5%	110
	1	15.5%	21
	Nx	3.0%	4
M stage			135 patients
	0	97.8%	132
	1	0.7%	1
	Mx	1.5%	2
Gleason score			135 patients
	5	1.5%	2
	6	8.9%	12
	7	42.2%	57
	8	28.9%	39
	9	14.0%	19
	10	1.5%	2
	Not available	3.0%	4
Stage			135 patients
I	T1a N0 M0 T2a N0 M0	5.2%	7
II	T2b N0 M0 T2c N0 M0	32.6%	44
III	T3 N0 M0 T4 N0 M0	40.7%	55
IV	any T N1 M0 any T any N M1	17.1%	23
	Not available	4.4%	6
Grade			135 patients
	1	1.5%	2
	2	18.5%	25
	3	30.4%	41
	4	6.7%	9
	5	3.7%	5
	Not available	39.2%	53
Surgery Margins			135 patients
	Free	54.8%	74
	Involved	39.3%	53
	Not available	5.9%	8
Risk Stratification			135 patients
	Low	2.3%	3
	Intermediate	20.7%	28
	High	67.4%	91
	Not available	9.6%	13

Table 2. Detection rates regarding PSA category			
	PSA<0.2ng/ml	0.2≤PSA<0.5ng/ml	0.5≤PSA<1.0ng/ml
Number of patients	16.3% (22/135)	57.8% (78/135)	25.9% (35/135)
Overall positive results	31.8% (7/22)	44.9% (35/78)	71.4% (25/35)
Dynamic	13.6% (3/22)	24.4% (19/78)	42.9% (15/35)
Standard whole-body	31.8% (7/22)	43.6% (34/78)	68.6% (24/35)
Delayed	18.8% (3/16)	41.8% (23/55)	61.5% (16/26)
Standard whole-body and dynamic phases were obtained in all 135 patients. Delayed images were available in only 97 patients and the percent of positive results are provided in 97 patients.			

Table 3. Numbers of detected lesions on each phase as well as in the same FOV.				
		Dynamic	Standard whole-body	Delayed
Total number of lesions		50	114	57
	local recurrences	16	21	10
	Lymph nodes	28	62	42
	Bone Metastases	4	21	5
	Visceral Metastases	2	10	-
Total number of lesions in the same FOV†		25	42	39
	local recurrences	10	13	10
	Lymph nodes	15*	29	29
	Bone Metastasis	-	3	1
	Visceral Metastasis (penis)	1	1	n
	Overall detection rate	28.4%*	39.5%	35.8%

* Standard whole-body images showed statistically significant superiority.
† Data analysis from 97 patients with dynamic, standard whole-body and delayed images in the same FOV.
n: not - performed.

Table 4. SUVmax of the detected lesions in in the same FOV regarding all three phases.				
		Dynamic	Standard whole-body	Delayed
local recurrence	Number	10	13	10
	SUVmax	6.1±4.8 (2.5-17.6)	6.4±5.9 (2.0-23.2)	7.5±5.8 (2.3-20.3)
	SUVmax T/BG	3.5±2.8 (1.7-8.4)	7.9±9.5 (2.5-29.0)	5.1±4.6 (2.0-11.9)
	Size	10.0±2.9mm (7-14mm)	10.2±2.7mm (6-16mm)	10.5±3.5mm (5-15mm)
Lymph nodes	Number	15	29	29
	SUVmax	6.4±3.5 (2.0-13.0)	8.0±6.3 (1.9-30.4)	7.8±5.6 (3.1-29.3)
	SUVmax T/BG	2.7±1.3 (1.3-5.5)	7.6±5.3 (0.7-26.1)	4.1±2.3 (1.5-9.1)
	Size	9.7±3.0mm (6-15mm)	9.5±3.0mm (5-16mm)	9.2±3.1mm (5-16mm)

Table 5. Additional data provided by dynamic and/or delayed images			
	Phase	Case Number	Percent
Resulted in Positive interpretation	Only Dynamic*	7	20.0% (7/35)
	Only Delayed*	6	17.1% (6/35)
	Dynamic and Delayed	1	2.8% (1/35)
	Dynamic or Delayed	4	11.5% (4/35)
Resulted in Negative interpretation	Only Dynamic	4	11.5% (4/35)
	Only Delayed	1	2.8% (1/35)
	Dynamic and Delayed	3	8.6% (3/35)
	Dynamic or Delayed	9	25.7% (9/35)
*In one patient the standard whole-body study was clearly negative.			

Figure legends

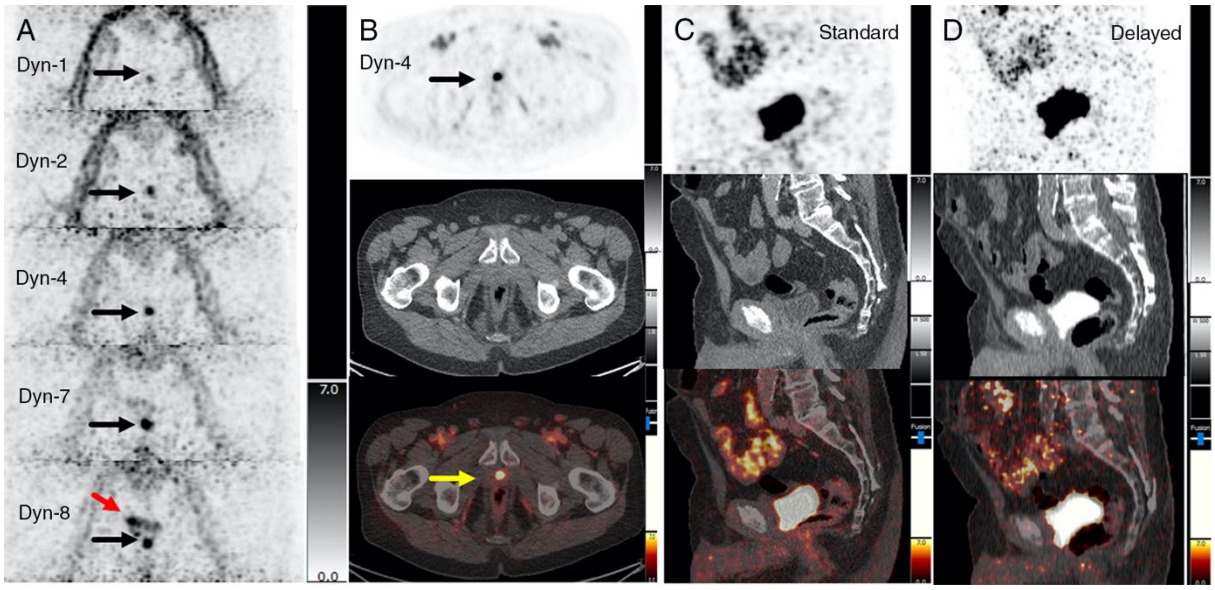

FIGURE 1.

Impact of dynamic ^{68}Ga-PSMA PET/CT. Prostate cancer patient with biochemical recurrence (PSA: 0.50ng/ml). A. Dynamic phase: A focal tracer uptake (arrow) is perceived in the prostate bed from the first minute. The urinary activity in the bladder (red arrow) is visible from the 7th min.. B. dynamic phase, axial-view (PET:upper, CT:middle, fusion PET/CT: lower) from the 4th min. showing focal uptake in the prostate bed (arrows) suggestive of local recurrence. C and D. Standard and delayed acquisitions: the suspicious focal uptake in prostate bed is completely masked with physiologic urinary activity in the bladder. MIP: Maximum Intensity Projection.

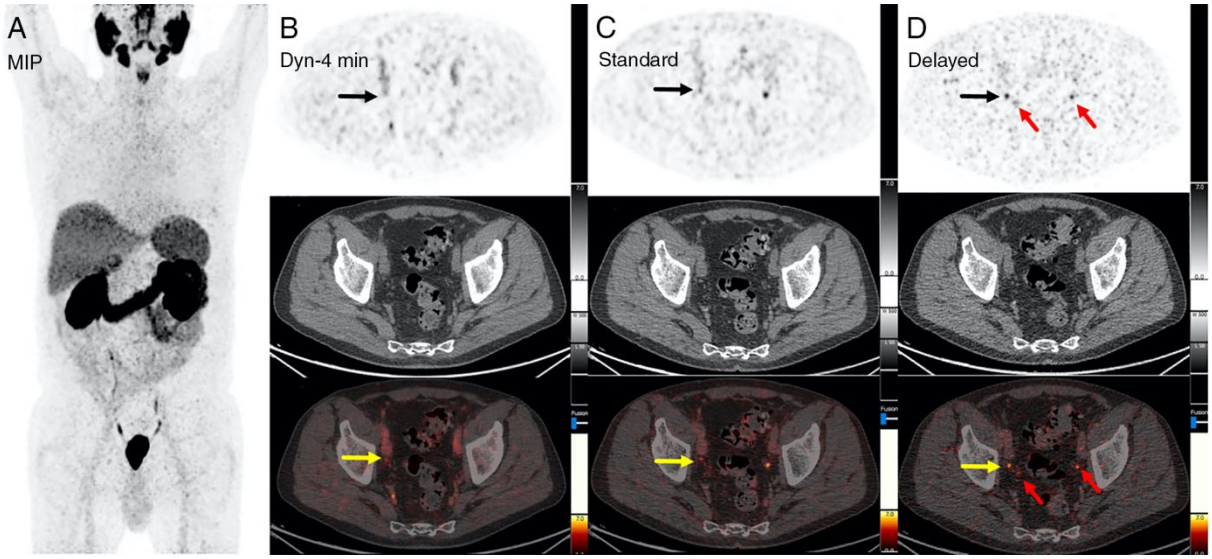

FIGURE 2.

Impact of delayed ^{68}Ga-PSMA PET/CT. Prostate cance patient with biochemical recurrence (PSA: 0.34ng/ml). A. (standard whole-body, MIP), B (dynamic-acquisition, 4th min., axial-view, PET:upper, CT:middle, fusion PET/CT lower) and C (standard-acquisition, axial-view): no abnormal tracer uptake is seen in the pelvic lymph nodes (A,B&C, arrows). D. Delayed phase: focal tracer uptake is seen on a small external iliac lymph node (black & yellow arrows). Urinary uptake is seen in both ureters (red arrows) MIP: Maximum Intensity Projection.

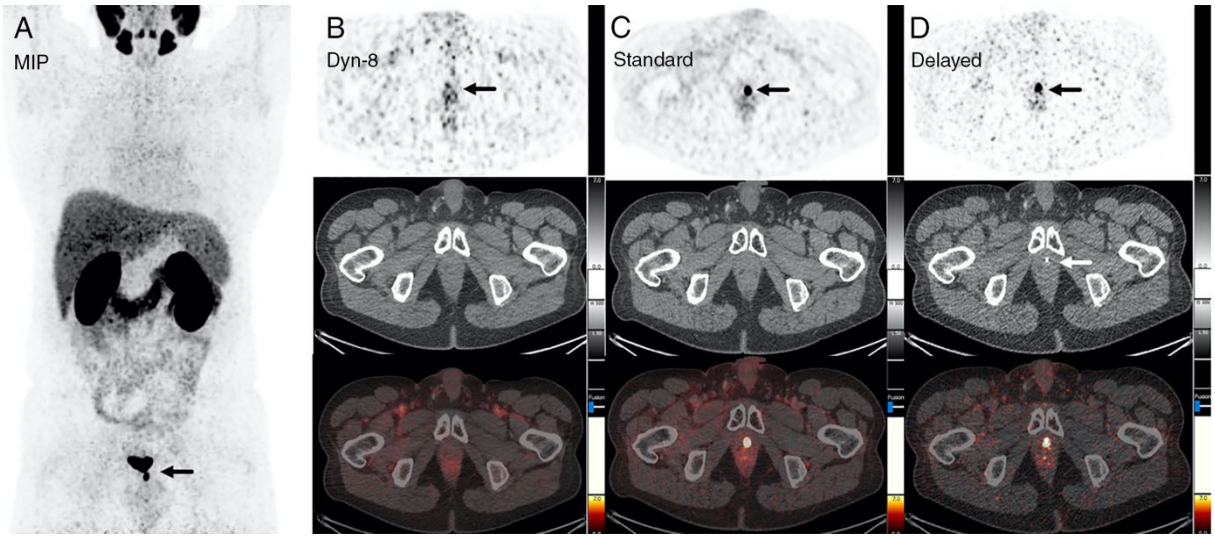

FIGURE 3.

Impact of dynamic and delayed ^{68}Ga-PSMA PET/CT. Prostate cancer patient with biochemical recurrence (PSA: 0.28ng/ml). A (standard whole-body, MIP) and C (dynamic-acquisition, 4th min., axial-view, PET:upper, CT:middle, fusion PET/CT lower): an abnormal tracer accumulation is seen in the prostate bed, suggestive of local recurrence (A&C, arrows). B. Dynamic phase: No abnormal activity is seen in the prostate bed (arrow). D. Delayed phase: Contrast-medium (white arrow) is present in the suspicious region visualized on standard image concomitant with the urinary activity in the bladder. MIP: Maximum Intensity Projection.