

Salivary gland toxicity of PSMA Radioligand Therapy: relevance and preventive strategies

Thomas Langbein¹, Guillaume Chaussé² and Richard P. Baum¹

¹Theranostics Center for Molecular Radiotherapy and Molecular Imaging, Zentralklinik, Bad Berka, Germany

² Division of Nuclear Medicine, Department of Radiology, McGill University, Montreal, Canada

Since the first clinical use of I-131 labeled PSMA (1), xerostomia has been identified as a relevant side effect of PSMA radioligand therapies (PRLT) for metastatic castration-resistant prostate cancer (mCRPC). Given the remarkable progress when using Lu-177 labeled compounds and the impressive results of Ac-225 PSMA PRLT (2), we believe that effective preventive strategies for salivary gland (SG) toxicity need to be developed to preserve the extremely attractive side effect profile of PRLT (3) as compared to standard treatments. Although the highest off-target uptake is seen in the SG (3), multicenter data on Lu-177 PSMA PRLT revealed only mild to moderate reversible xerostomia in 8 % of patients (4). In a systematic analysis our group confirmed these findings (5).

The largest available data on Ac-225 PSMA were published by Kratochwil *et al.* (2). In the Heidelberg cohort, severe xerostomia occurred frequently and became the dose-limiting toxicity. Among the 40 patients, treatment had to be discontinued in 4 cases despite initial response. Our group's first clinical results of 6 patients treated with Ac-225 PSMA are in line with those findings. Following a first treatment cycle, one out of three patients with sufficient follow-up data had experienced (tolerable) mouth dryness while another one treated with 5 MBq Ac-225 PSMA (83 kBq/kgBW), had subsequent markedly decreased uptake in all SG (Fig 1).

With respect to the potential survival benefit of PSMA-directed radionuclide therapies, we believe that severe reduction in quality of life will gain more significance in the future. Recently, Taïeb *et al.* focused on SG toxicity from PRLT and discussed several approaches (6), including a reference to xerostomia after external beam radiotherapy (EBRT) of patients with head and neck cancer. Although the exact molecular principles of tracer accumulation, in particular the ratio of non-specific over specific uptake in SG are still insufficiently understood, PRLT, unlike EBRT, offers potential routes to prevent radiation exposure to SG tissue by avoiding or reducing radionuclide uptake. In multicycle therapy, declining tumor volume, and thus target PSMA binding, increases off-target uptake (7) which greatly burdens the dose-limiting SG. Reduction of administered activity to limit xerostomia hence comes at the expense of tumor dose, especially in responding patients.[GC1][GC2]

[[GC3]Alternatively, labeling of PSMA-targeting antibodies like J591 instead of small molecules like PSMA-617 might be able to lower the sialotoxicity of Ac-225 PSMA PRLT since there is no significant SG uptake on Zr-89-J591 or Lu-177- J591 imaging (8,9). It unfortunately comes at the cost of increased myelotoxicity due to longer blood circulation. The difference in molecular weight of PSMA targeting antibodies vs. small molecules (around 150 kD vs. 1.4 kD) could explain some of the variation in SG uptake. [[GC4][TL5]Along these lines, ionic charge of PSMA radioligands might also play a role in SG distribution, though changing molecular electronegativity risks impacting tumor affinity.

External cooling of the SG by using icepacks was initially expected to reduce PSMA radioligand uptake due to vasoconstriction but it failed to prove helpful in a systemic analysis (10). Considering the intense blood supply of organs in proximity to the head, insufficiency might be explained by a reflex hyperperfusion.

Preclinical animal data on potential radioprotective substances injected to the SG like botulinum toxin A, short-acting anticholinergic agents and local anesthetics appear promising (11). Other radioprotectors have also been tested, such as histamine, vitamin E, statins, amifostin, etc., exploiting mechanisms of radiation resistance. In humans, Teymoortash *et al.* investigated the effect of botulinum toxin injections to the SG with head and neck cancer undergoing EBRT (12). Earlier this year our group translated that approach into tracer uptake blockade and achieved 64 % Ga-68 PSMA uptake decrease in an injected parotid, leading to the first proof-of-concept publication on the topic (13) and heralding hypothesis of non-specific tracer accumulation. [[GC6] Given the possibility of some specific binding of PSMA radioligands in the SG, local application of cold compounds or inhibitors of PSMA such as PMPA (14) are also being investigated. However, the potential inhibition of PSMA targeted tumor caused by systemic absorption from intraparenchymal application of PMPA (due to the relevant blood supply, esp. of the parotid glands) warrants careful consideration [[GC7][GC8].

[[GC9]Sialendoscopy data of thyroid cancer patients suffering from radioiodine-induced sialadenitis suggest another outlook. Therapy-refractory xerostomia could be explained by duct stenosis and mucous plugs in 86% of occurrence; sialendoscopy intervention resulted in 89 % of partial or complete resolution of symptoms (15). Of note, time does matter since better results were obtained for earlier endoscopic treatment when compared to intervention for chronic symptoms (16).

Another salvage approach might be regeneration of the SG. In a clinical trial of head and neck cancer patients after radiotherapy, ultrasound-guided transplantation of adipose tissue-derived mesenchymal stem cells (ASC) to the submandibular glands for treatment of radiation-induced

xerostomia achieved an increase in salivary flow of 33% after 1 month and 50 % after 4 months (17).

The reasons why SG take a bigger hit than most of the other organs exposed could lie in the biology of the glands themselves. A high propensity to trigger apoptosis and the myriad of secretory granules that potentiate formation of radiation-induced free radicals are promising hypotheses (18). [TL10] Perhaps current radiopharmaceuticals hit the SG "sweet spot" of low-dose hyperradiosensitivity. Whether by optimized doses, compounds with better biodistribution, new radioprotectors, blockers of PSMA binding, better post-therapy management or cellular transplantation, PRLT requires us to solve the SG enigma.

References:

1. Zechmann CM, Afshar-Oromieh A, Armor T, et al. Radiation dosimetry and first therapy results with a (124)I/ (131)I-labeled small molecule (MIP-1095) targeting PSMA for prostate cancer therapy. *Eur J Nucl Med Mol Imaging*. 2014;41:1280-1292.
2. Kratochwil C, Bruchertseifer F, Rathke H, et al. Targeted Alpha Therapy of mCRPC with 225Actinium-PSMA-617: Swimmer-Plot analysis suggests efficacy regarding duration of tumor-control. *J Nucl Med*. 2018 (epub).
3. Baum RP, Kulkarni HR, Schuchardt C, et al. 177Lu-Labeled Prostate-Specific Membrane Antigen Radioligand Therapy of Metastatic Castration-Resistant Prostate Cancer: Safety and Efficacy. *J Nucl Med*. 2016;57:1006-1013.
4. Rahbar K, Ahmadzadehfar H, Kratochwil C, et al. German Multicenter Study Investigating 177Lu-PSMA-617 Radioligand Therapy in Advanced Prostate Cancer Patients. *J Nucl Med*. 2017;58:85-90.
5. T. Langbein, H. R. Kulkarni, A. Singh, R. P. Baum. Functional imaging of the salivary glands for evaluation of radiation-induced sialadenitis before and after Lu-177 PSMA radioligand therapy. *Eur J Nucl Med Mol Imaging*. 2017;44 (Suppl 2):328.
6. Taïeb D, Foletti J-M, Bardiès M, Rocchi P, Hicks R, Haberkorn U. PSMA-Targeted Radionuclide Therapy and salivary gland toxicity: Why does it matter? *J Nucl Med* 2018 (epub).
7. Gaertner FC, Halabi K, Ahmadzadehfar H, et al. Uptake of PSMA-ligands in normal tissues is dependent on tumor load in patients with prostate cancer. *Oncotarget*. 2017;8:55094-55103.
8. Michael J. Morris, Neeta Pandit-Taskar, Jorge A. Carrasquillo et al. Phase I trial of zirconium 89 (Zr89) radiolabeled J591 in metastatic castration-resistant prostate cancer (mCRPC). *J Clin Oncol*. 2013;31:6_suppl,31-31.
9. Bander NH, Milowsky MI, Nanus DM, Kostakoglu L, Vallabhajosula S, Goldsmith SJ. Phase I trial of 177lutetium-labeled J591, a monoclonal antibody to prostate-specific membrane antigen, in patients with androgen-independent prostate cancer. *J Clin Oncol*. 2005;23:4591-4601.
10. van Kalmthout L., Lam M., de Keizer B., Braat A. Impact of external cooling on PSMA uptake in salivary glands. *Eur J Nucl Med Mol Imaging*. 2017;44 (Suppl 2):328.
11. Hakim SG, Benedek GA, Su Y-x, et al. Radioprotective effect of lidocaine on function and ultrastructure of salivary glands receiving fractionated radiation. *Int J Radiat Oncol Biol Phys*. 2012;82:e623-30.
12. Teymoortash A, Pfestroff A, Wittig A, et al. Safety and Efficacy of Botulinum Toxin to Preserve Gland Function after Radiotherapy in Patients with Head and Neck Cancer: A Prospective, Randomized, Placebo-Controlled, Double-Blinded Phase I Clinical Trial. *PLoS ONE*. 2016;11:e0151316.
13. Baum RP, Langbein T, Singh A, et al. Injection of Botulinum Toxin for Preventing Salivary Gland Toxicity after PSMA Radioligand Therapy: An Empirical Proof of a Promising Concept. *Nucl Med Mol Imaging*. 2018;52:80-81.
14. Kratochwil C, Giesel FL, Leotta K, et al. PMPA for nephroprotection in PSMA-targeted radionuclide therapy of prostate cancer. *J Nucl Med*. 2015;56:293-298.
15. Canzi P, Cacciola S, Capaccio P, et al. Interventional sialendoscopy for radioiodine-induced sialadenitis: quo vadis? *Acta Otorhinolaryngol Ital*. 2017;37:155-159.
16. Luers JC, Grosheva M, Reifferscheid V, Stenner M, Beutner D. Sialendoscopy for sialolithiasis: early treatment, better outcome. *Head Neck*. 2012;34(4):499-504.
17. Grønhøj C, Jensen DH, Vester-Glowinski P, et al. Safety and Efficacy of Mesenchymal Stem Cells for Radiation-Induced Xerostomia: A Randomized, Placebo-Controlled Phase 1/2 Trial (MESRIX). *Int J Radiat Oncol Biol Phys*. 2018 (epub).

18. Grundmann O, Mitchell GC, Limesand KH. Sensitivity of salivary glands to radiation: from animal models to therapies. *J Dent Res.* 2009;88(10):894-903.

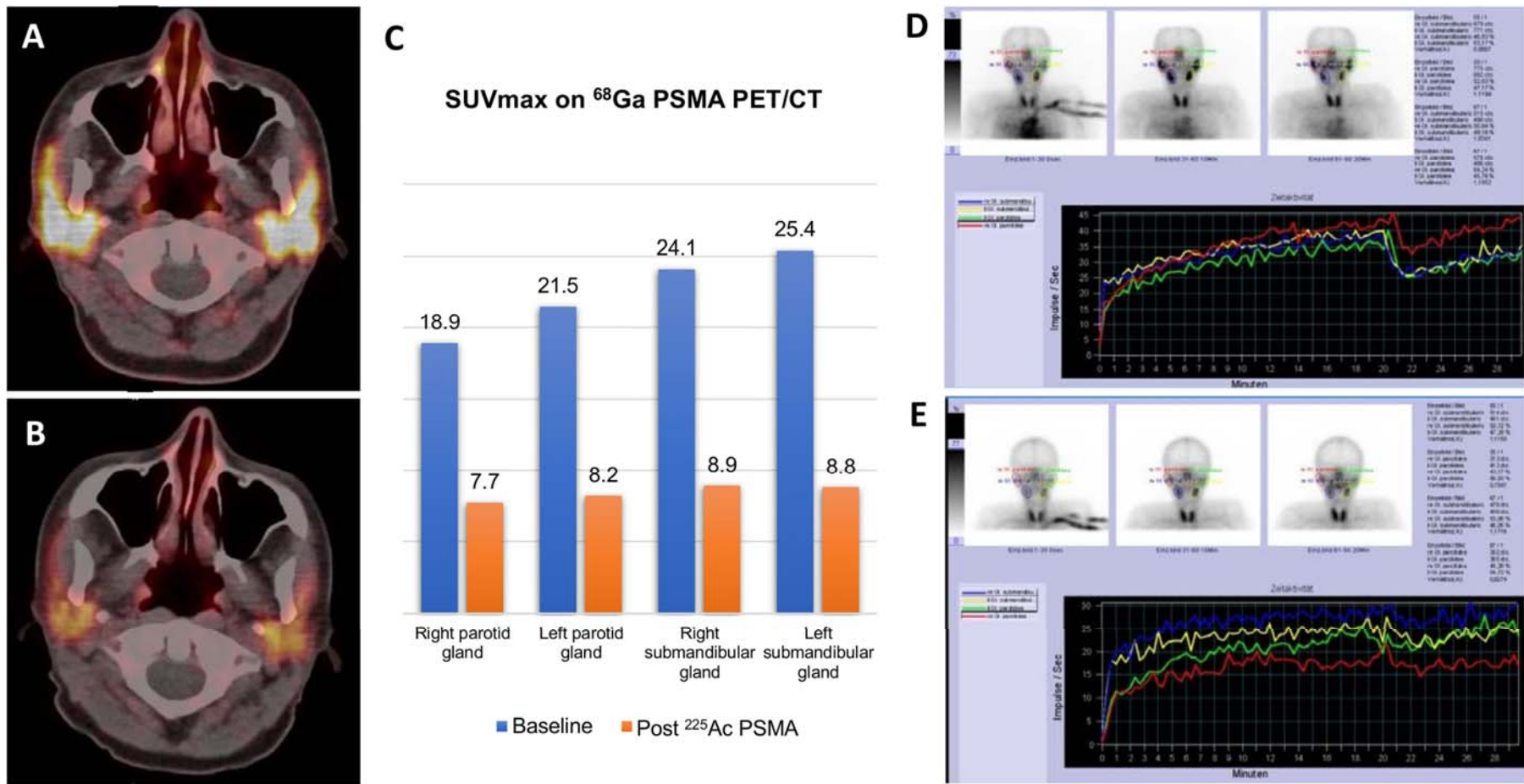


Figure 1. Physiologic tracer uptake is detected in the SG of a 59-year-old mCRPC patient on the pre-therapeutic Ga-68 PET/CT study (A) while PSMA uptake in the SG declines by up to 65 % on follow-up imaging (B,C) after PSMA radioligand therapy using Ac-225. Dynamic SGS demonstrates regular baseline function (D); however, the post-therapeutic study reveals functional impairment despite absence of clinical symptoms of xerostomia (E).