

Clinical Use and Utility of Amyloid Imaging

Henryk Barthel and Osama Sabri

Department of Nuclear Medicine, University of Leipzig, Leipzig, Germany

Running title:

Use and Utility of Amyloid Imaging

Contact:

Prof. Dr. med. Henryk Barthel, Department of Nuclear Medicine, University of Leipzig Hospital, Liebigstr. 18, 04103 Leipzig, Germany, Email: henryk.barthel@medizin.uni-leipzig.de

ABSTRACT

Currently, three amyloid positron emission tomography (PET) tracers are approved and commercially available for clinical use. They allow for the accurate *in vivo* detection of amyloid plaques, one hallmark of Alzheimer's disease (AD). Here, we review the current knowledge on the clinical use and utility of amyloid imaging. Appropriate use criteria for the clinical application of amyloid imaging are established, and most currently available data point to their validity. Visual amyloid image analysis is highly standardized. Disclosure of amyloid imaging results is desired by many cognitively impaired subjects, and seems to be safe once appropriate education is delivered to the disclosing clinicians. Regarding clinical utility, increasing evidence points i) to a change of diagnosis via amyloid imaging in ~30% of cases, ii) to an increase of diagnostic confidence in ~60% of cases, iii) to a change of patient management in ~60% of cases, and specifically iv) to a change of medication in ~40% of cases. Also, amyloid imaging results seem to relevantly impact care-givers. Further, initial simulation studies point to a potential positive patient outcome effect and cost-effectiveness of amyloid imaging. These features, however, will require confirmation in prospective clinical trials. More work is also required to determine the clinical utility of amyloid imaging specifically in subjects with mild cognitive impairment, and in comparison/conjunction with other AD biomarkers. Taken together, the clinical use of amyloid imaging is being studied, and the currently available data point to a relevant clinical utility of this imaging technique. Ongoing research will determine whether this accurate and non-invasive approach to amyloid plaque load detection will translate into a benefit to cognitively impaired subjects.

KEY WORDS

Amyloid, imaging, PET, dementia, utility

NOTEWORTHY

- ✓ Clinical use of amyloid imaging is well defined and safe
- ✓ Amyloid imaging changes diagnosis in ~30% of cases
- ✓ Amyloid imaging increases diagnostic confidence in ~60% of cases
- ✓ Amyloid imaging changes patient management in ~60% of cases
- ✓ Impact of amyloid imaging on patient outcome is currently under investigation

INTRODUCTION

With the successful development and subsequent clinical approval of 18F-Florbetapir, 18F-Florbetaben, and 18F-Flutemetamol, the nuclear imaging community has a set of beta-amyloid aggregate-targeting PET tracers in hand for clinical use. They allow the *in vivo* detection or exclusion of neuritic beta-amyloid plaques, one histopathological hallmark in the neocortex of patients with AD which so far could only be histopathologically diagnosed *post mortem*. Of note, brain beta-amyloid accumulation is known to be an early event in this disease (1), and considered by many as the initial trigger of a cascade of other pathobiochemical and pathophysiological alterations finally leading to neurodegeneration and related cognitive decline in AD (2).

The emergence of amyloid imaging technology is hoped to fill a relevant diagnostic gap in the clinics in cognitively impaired subjects, and in AD in particular. Most people would like to get a diagnosis when cognitive symptoms are identified (3). Conversely, dementia diagnosis is often missed and delayed (4,5). With regard to therapeutic implications of an AD diagnosis, it was reported that older people are willing to accept relevant side-effects of AD-modifying therapies (6). Also of interest, more than 80% of dementia specialists reported in 2013 that they would like to complement their portfolio of AD diagnosis tools by amyloid imaging (7).

However, the clinical approval of the above amyloid tracers was based on convincing results from phase 1-3 development programs. Here, the phase 2 studies (comparison between patients with clinical diagnosis and healthy controls) were rather similar in their design to the anticipated clinical use scenarios of these tracers. The phase 3 studies (comparison between *in vivo* PET imaging and *post mortem* histopathology), however, were - mainly due to the end of life situation of the study cohorts - limited in the applicability of their results to clinical routine scenarios. Thus, it is necessary to investigate the clinical utility of amyloid imaging in separate studies in clinical cohorts. On a further level and with imperative importance for re-imburement

discussions, cost-efficacy analyses and data on the impact of amyloid imaging on clinical outcome are required.

Chiotis et al. (2017) have recently summarized the current knowledge on the clinical validity of amyloid PET imaging as an AD biomarker. For that purpose, they adapted a 5-phase oncology biomarker development framework. From their amyloid imaging literature review the authors concluded that the aims of phases 1 (rational for use) and 2 (discriminative ability) of clinical validity testing have been achieved, and that of phase 3 (early detection ability) in parts. Phase 4 (performance in representative mild cognitive impairment subjects) research was estimated to be at the ongoing state, and that of phase 5 (quantification of impact and costs) as still outstanding (8).

We have identified a number of recently published studies which have investigated the clinical use and utility of amyloid imaging. It is the aim of this present review to provide an overview and a critical discussion on the current knowledge in this important field.

CLINICAL USE OF AMYLOID IMAGING

Amyloid imaging should in principle be able to provide an early AD diagnosis. Based on the amyloid cascade theory, amyloid buildup is the initial event in AD, which results in a cascade of other processes that ultimately lead to neurodegeneration and dementia (2). Furthermore, as many other dementia disorders such as most forms of frontotemporal dementia are amyloid-negative, amyloid imaging might contribute to the differential dementia diagnosis. This might even have therapeutic consequences, as it is known for instance that the *N*-methyl-D-aspartate receptor-blocking memantine has no systematic benefit in frontotemporal dementia (9). Of interest with regard to the amyloid cascade theory and the fact that there exist alternative theories of AD pathogenesis, like the one claiming tau aggregation being the cascade trigger, it was recently reported that the interpretation of amyloid images is not affected by the belief about the pathogenic role of amyloid (10).

Appropriate Use Criteria for Amyloid Imaging

Bearing the above discussed potential of amyloid imaging together with the ethical implications of potentially revealing a significant diagnosis without a cure in mind, there were quite early in the emerge of respective tracers attempts to define scenarios in which amyloid imaging might be appropriate in future clinical use (11,12). Vandenberghe et al. (2013) stated that, to define appropriate use for amyloid imaging in a clinical setting, (i) the clinical context, (ii) the healthcare system, and (iii) the societal perception of AD needs to be considered in a joint fashion (12). Latest with the regulatory approvals of the discussed amyloid tracers and the perspective of upcoming coverage decisions, it was felt that clear definitions must be made for the appropriate and inappropriate clinical use of amyloid imaging. As a consequence, “appropriate use criteria” (AUCs) were published in 2013 in a joint effort by the SNMMI and the Alzheimer’s Association.

Here, it was stated that amyloid imaging is appropriate in subjects fulfilling all of the following three prerequisites: (1) “Cognitive complaint with objectively confirmed impairment”, (2) “AD as a possible diagnosis, but when the diagnosis is uncertain after a comprehensive evaluation by a dementia expert”, and (3) “When knowledge of the presence or absence of A β pathology is expected to increase diagnostic certainty and alter management”. After a comprehensive literature review and expert discussion, this was filtered into three appropriate use scenarios given in Supplemental Tab. 1. Also, six inappropriate use scenarios were formulated (Supplemental Tab. 1)(13). This was soon afterwards updated by a clarification of the dementia expert definition and of other aspects (14).

Of interest, Grundman et al. (2016) investigated the clinical utility of amyloid imaging depending on whether the AUCs are met or not. They investigated 229 subjects imaged with Florbetapir. While the impact of amyloid imaging on management plans was high in this study regardless of whether AUC-like or non-AUC-like subjects were taken into account (88 vs. 86%), a change of diagnosis via amyloid imaging was observed significantly more often in AUC-like as compared to non-AUC-like subjects (62 vs. 45%) (15). In contrast, Apostolova et al. (2016) found change of diagnosis via amyloid imaging to occur less often in (AUC-consistent) early-onset cases as compared to late-onset cases, while treatment changes occurred more often in the early-onset group (16).

Nevertheless, the current AUCs seem to provide a reasonable framework for current clinical use of amyloid imaging. It is certainly necessary to further investigate this feature, and to adapt the AUCs once new evidence on the usefulness/non-usefulness of amyloid imaging in certain scenarios emerges. For instance, Zwan et al. (2017) reported that patients might benefit from amyloid imaging even if diagnostic confidence does not increase (17). Further, given a certain likelihood that disease-modifying anti-amyloid drugs will be available in the future, AUCs might need to be expanded then to cases in which clinical testing reveals typical AD features

(“probable AD dementia”). This is to say that this patient cohort likewise comprises of a relevant portion of amyloid-negative cases, which would not benefit from respective treatment (18).

Amyloid Image Analysis

The PET data of all three approved amyloid tracers are, in clinical routine, assessed visually. This is accomplished on a binary level, i.e. the brains imaged are either interpreted as amyloid-positive or -negative. It is a requirement by the regulatory authorities that future amyloid PET readers first pass a tracer-specific training. As the amyloid tracers share similar uptake patterns, the respective training programs share some similarities: They are all focused on teaching the identification of neocortical grey vs. white matter contrast, while the loss of this contrast points to amyloid-positivity, and vice versa. The feasibility, accuracy, and reproducibility of the respective training programs were recently confirmed for all three tracers (19-21). One interesting question recently asked in this context relates to the potential incremental value of semiquantitative image analysis (22). In this regard, Pontecorvo et al. (2017) showed that the consideration of standardized uptake value ratios during visual read increases accuracy, especially in “below average” readers (21). More research on this topic is thus justified to fully understand the potential of combined visual/semiquantitative amyloid image analysis in a clinical routine scenario.

Disclosure of Amyloid Imaging Results

There is an interesting ethical discussion ongoing regarding the disclosure of amyloid imaging results. This discussion aims at finding a much desired balance between the “value of knowing” (23) and the principle of non-maleficence (“avoiding potential harms of disclosure given the currently unproven clinical utility” (24)). Positive aspects of amyloid imaging result disclosure

refer to the possibility to adapt life planning and keeping autonomy, while negative aspects relate to fear of upsetting patients without therapeutic options. However, in support of disclosure, a general questionnaire study carried out by Sullivan et al. (2001) showed that 97% of more than 300 patients asked responded “I want to be told of serious, life-threatening diagnosis” (23). More specifically, 67% of more than 2600 adults in the USA and in Europe responded in a survey that they would make use of a test for early AD diagnosis once such a test becomes available (25). In accordance, a meta-analysis of 23 studies in more than 9000 subjects revealed that, in case of the cognitive impairment subgroup, 84% of the participants were in favor of the dementia diagnosis being disclosed to them (Fig. 1)(26). Regarding amyloid imaging, the majority of Alzheimer's Disease Neuroimaging Initiative investigators who were surveyed in 2013 responded that they would, once respective tracers were approved by the Food and Drug Administration, disclose the results. This was paralleled by the notion that respective disclosure standards and training are required, together with respective outcome research (27). Other authors raised the concern that disclosing amyloid imaging results in binary categories as currently done might not provide the full picture (24), or pointed to the need for adequate education (24,28,29). For cognitively impaired participants of research studies, Lingler et al. argued in 2013 that it is time to disclose the respective amyloid imaging results, again providing adequate pre-post disclosure management (30).

As a consequence, the same group recently developed and successfully tested information material for standardized pre-test counseling and post-test disclosures in subjects with mild cognitive impairment (MCI, Supplemental Tab. 2)(31). Regardless, a recent investigation into the safety and tolerability of disclosing amyloid PET imaging results in 11 healthy older adults who took part in an AD biomarker trial revealed that disclosure did not significantly affect mood, subjective sense of memory impairment, perceived risk of developing AD, or emotion. Also of note, amyloid-positive subjects were more likely to make positive lifestyle changes after disclosure as compared to amyloid-negative subjects (32). In good accordance, a similar study

in 97 healthy older adults found no significant effect of disclosure on depressive symptoms or anxiety, despite a slight disclosure-related distress (33).

CLINICAL UTILITY OF AMYLOID IMAGING

The question of clinical utility of amyloid imaging is of utmost importance for the establishment of this new imaging technique in a clinical routine scenario. In principle, different levels of clinical utility of diagnostic tests exist, with different degrees of appreciation by patients/caregivers, medical doctors, and payers. These include change of diagnosis by the test, change of general diagnostic confidence by adding the test to the diagnostic regime, change of management, impact on care-givers, impact on patient outcome, and associated costs.

Concerning clinical utility of amyloid PET imaging, 16 studies were found in literature (17,34-47,48). Supplemental Tab. 3 summarizes these studies. Three studies address cost efficacy and will be discussed later in this article. Since 2012, altogether 1360 subjects were investigated either prospectively or retrospectively, in either mono- or multi-center settings. While the earlier studies focused on 11C-PIB, in the following years the 18F-labeled amyloid tracers were in the spotlight. In most studies, subjects with cognitive impairment (either of pre-dementia or dementia degree) were included in whom a certain diagnostic uncertainty was evident after the standard diagnostic testing. Most cases included clinical testing and morphological imaging, while some studies incorporated 18F-FDG brain PET imaging, cerebrospinal fluid sampling for amyloid/tau, and/or APOe4 genotyping. PET-positivity ranged from 39-90% in these studies. In three of these studies, the clinical value of amyloid imaging was studied together with that of 18F-FDG brain PET imaging, and in one of these three studies this was further combined with repeated neuropsychological testing (Supplemental Tab. 3).

Impact of Amyloid Imaging on Diagnosis

One hint for a clinical impact of amyloid imaging would be evidence of change of diagnosis via imaging in a relevant portion of subjects investigated. Twelve studies with a total case number of

1159 dealing with this question were found in the literature, the results of which are summarized in Tab. 1. In all these studies, a relevant portion of subjects showed a diagnosis change via amyloid imaging, ranging from 9 to 72%. The weighted (weighted by the study cohort size) change of diagnosis was 29% of cases across all studies. For example, Grundman et al. (2013) found in their 18F-Florbetapir multi-center study in 229 cognitively impaired subjects with mid-range pre-scan diagnostic confidence of AD between 15% and 85% that amyloid imaging changed the diagnosis in all pre-scan diagnosis groups (due to AD, indeterminate, not due to AD) to a similar degree, obviously with different accentuation for the amyloid-positive vs. -negative subjects (Fig. 2)(39). Further information on interesting studies of this topic is provided in the Supplemental Material.

Impact of Amyloid Imaging on Diagnostic Confidence

The fact that amyloid imaging changes diagnosis in a relevant number of cases does, in the absence of a diagnostic gold standard in the clinical routine scenario, not necessarily imply a significant benefit. Thus, it is of interest to also investigate how and to what degree amyloid imaging impacts diagnostic confidence. Ten studies with a total of 1297 cases were identified dealing with this matter, seven of which reporting the results on a case frequency, and three on a 0-100% scale base. All studies reported a gain of diagnostic confidence via amyloid imaging. On a case frequency base, the study results ranged from 8 to 90%, while on a 0-100% the gain of diagnostic confidence was reported to equal 16, 22, and 21%, respectively (Tab. 1). Further information on interesting studies of this topic is provided in the Supplemental Material. Taken all relevant studies together, the weighted (weighted by the study cohort size) gain of diagnostic confidence was 63% on a case frequency base, and 20% on a 0-100% scale base.

Impact of Amyloid Imaging on Patient Management

While the impact on diagnosis establishment and the gain of diagnostic confidence by amyloid imaging is mainly of relevance to the patients/care-givers (“value of knowing”) and to the referring doctors, it is not regarded as sufficient evidence justifying reimbursement by many payers who require evidence on a patient outcome effect. Of the different levels of evidence on clinical utility of amyloid imaging, impact on patient management assumes a medium degree. We found eight studies with a total case number of 1068 in the literature investigating the effect of amyloid imaging on patient management. Five of these reported the effect on general management, and seven of these more specifically reported the effect on medication management. The respective study results are also summarized in Tab. 4. In all studies, a relevant management impact of amyloid imaging was found. It ranged between 37-87% of cases for the overall change of management, and between 24-60% of cases for the change of medication, respectively. Weighted (weighted by the study cohort size) change of overall management via amyloid imaging equaled 64% of cases, and weighted change of medication 38% of cases (Tab. 1). Further information on interesting studies of this topic is provided in the Supplemental Material.

Impact of Amyloid Imaging on Care-Givers

Apart from the above discussed impact of amyloid imaging to the patients and to their medical professionals, it is relevant to understand how this imaging directly (other than the above discussed indirect effects related to care plan changes) affects the patients’ care-givers. Surprisingly, the direct impact of amyloid imaging on care-givers has not been systematically addressed so far. The only publication addressing this question we managed to identify so far was that by Bensaidane et al. (2016). Here, in a mono-center 18F-NAV4694 study in 28 atypical (in the opinion of expert behavioral neurologists after review of history, basic lab, magnetic

resonance imaging (MRI), and 18-F-FDG PET) dementia patients (PET-positivity=50%), their care-givers were given a questionnaire together with an interview. As a result, all domains explored (anxiety, depression, disease perception, future anticipation, quality of life) were positively affected - independent of the PET result - by disclosing the amyloid imaging finding with a global impact of $\sim 3.6 \pm 0.4$ on a 1-5 Likert scale. Impressively, for the particular questions raised, "I appreciate every instant with my beloved one even more since we know the precise diagnosis" was most markedly acknowledged (45).

Impact of Amyloid Imaging on Clinical Outcome

The question of whether and to what extent amyloid imaging influences the clinical outcome of the subjects investigated is of great relevance, especially concerning reimbursement decisions. Providing respective positive evidence is, like with most other neurodegenerative disorders, complicated by the fact that there is still no cure available for AD. Instead, interventional efforts currently focus on drugs with potential symptomatic effects, change of life-style, and reduction of cardiovascular risk factors.

Up to now, there are no clinical studies available in the literature addressing a potential clinical outcome effect of amyloid imaging. Instead, three model simulation studies were so far published on that topic: Guo et al. 2012 modeled the outcome effect of 18F-Florbetaben in predementia and dementia subjects. Here, gains of quality-adjusted life years (QALYs; a measure combining the quality and the quantity of life lived) by amyloid imaging (as compared to a scenario without amyloid imaging) of 0.27 and 0.03 were estimated for both subgroups. Also, in the predementia group, amyloid imaging was associated with better outcome regarding time staying in predementia phase, care giver time and other parameters (36). Hornberger et al. 2015 and 2017 performed two similar simulations for 18F-Florbetapir PET in Spanish and French dementia cohorts. The QALY gains by amyloid imaging (likewise as compared to a scenario

without amyloid imaging) estimated in these modeling studies equaled 0.008 and 0.021, respectively (43,48). However, it will clearly be necessary in future studies to also investigate the above simulation parameters in “real world” clinical patients.

COST-EFFECTIVENESS OF AMYLOID IMAGING

From the health-economic point of view it is important to investigate the costs by which the above discussed clinical utility of amyloid imaging is achieved. Relevant parameters in this context are cost saving by the procedure, the costs per QALY, the cost efficiency ratio (portion of subjects in whom amyloid imaging is cost-effective based on national willingness-to-pay thresholds for one QALY), and the incremental cost-effectiveness ratio (another parameter describing the relation between the costs and the effect of amyloid imaging). The three previously cited model simulation studies dealing with outcome effects of amyloid imaging also dealt with these matters: While Guo et al. (2012) simulated the cost-effectiveness of 18F-Florbetaben for the USA, Hornberger et al. (2015) and Hornberger et al. (2017) carried out a respective modeling for 18F-Florbetapir in Spain and France (36,43,48). In the Guo et al. (2012) study, cost saving by amyloid imaging was estimated to equal \$13,018 or \$11,389 per subject over lifetime in predementia or dementia subjects, respectively. With a willingness-to-pay threshold of \$50,000 for one QALY, amyloid PET was cost-effective in 58% and 98% of the simulated predementia and dementia cases, respectively (36). In the two Hornberger et al. (2015 and 2017) studies, it was estimated that amyloid imaging does not lead to a cost saving. However, the incremental cost-effectiveness ratios were €4,769 and €21,888, respectively. Further, with willingness-to-pay thresholds of €30,000 or €40,000 for one QALY, amyloid PET was cost effective in >82% or >95% of the simulated dementia cases, respectively (43,48). Similarly to the above patient outcome data, it will be the task of the next years to investigate these simulated parameters also on a clinical patient base.

FUTURE PERSPECTIVES

The current literature on the clinical utility of amyloid imaging mainly focusses - in keeping with the AUCs - on clinically uncertain dementia cases, both of early-onset and late-onset. More work is required to systematically determine the clinical benefit of amyloid imaging also in MCI subjects. This further work should also take the recently published Canadian consensus guidelines on the use of amyloid imaging into consideration, which stated that “As a general rule, amyloid PET could be considered in MCI patients from whom the dementia expert has determined that greater certainty about the underlying pathology would alter management.”(49).

It will also be necessary to investigate the impact of special education for clinicians who handle amyloid imaging information, an important topic as recently pointed out by different groups (50-52). This education should contain lines of arguments on why both PET imaging outcome scenarios (amyloid-positivity and -negativity) have clinical utility.

For discussions with payers concerning reimbursement, more evidence from clinical outcome research is likewise required. The US Centers for Medicare and Medicaid Services (CMS) decided in 2013 to restrict amyloid imaging coverage by arguing that the evidence for a clinical use was insufficient at that time-point. While this decision was acknowledged by some authors (53), it was criticized by others as an example of a misbalance in the Medicare coverage criteria between drugs and diagnostics (54). However, instead of Medicare broadly covering amyloid imaging it decided to cover one amyloid scan per patient for those enrolled in a Coverage of Evidence program. This led to the roll out of the so-called IDEAS (Imaging Dementia - Evidence For Amyloid Scanning) study, which aims at providing systematic evidence of high quality for a positive outcome effect of amyloid imaging. In this open-label, longitudinal cohort study, subjects fulfilling the AUCs will be imaged. Two primary objectives will be tested, namely the change of management via amyloid PET imaging, and the impact of amyloid state knowledge as obtained via PET imaging on hospital admission/emergency room visits. As of May 4th, 2017, 911 sites

are active in this study, and 9,615 PET scans were carried out. It is aimed to complete study data analysis by 2020, hoping for a revised CMS coverage decision in case of a positive study outcome by 2022 (55). As a European multi-center initiative with similar aims, the so-called AMYPAD (Amyloid imaging to prevent Alzheimer's disease) study will soon also address the clinical relevance of amyloid imaging. Amongst a number of different study objectives, AMYPAD will - in MCI subjects and dementia patients - determine the impact of amyloid imaging on change of diagnosis depending on whether PET is utilized early or late in the diagnostic process. Interestingly, this will be paralleled by a change of management investigation in so-called "SCD Plus" (subjective cognitive decline with additional evidence for preclinical AD) subjects (56). All these above efforts will provide the missing evidence on the clinical validity of amyloid imaging (8).

Finally, it would be very interesting to combine clinical utility research for amyloid PET imaging with that of MRI. This is of relevant value, as brain MRI often represents the first line imaging in cognitive impairment, and as hybrid amyloid PET/MRI might be employed more often - where available - instead of MRI alone in the future (57,58). Also, as soon as tau PET imaging will be more broadly available, research should investigate the gain of clinical value by adding this technique to amyloid imaging. Last but not least, and with major relevance regarding cost efficacy discussions, the clinical utility of amyloid imaging should be systematically compared with that of amyloid cerebrospinal fluid measurements.

SUMMARY AND CONCLUSION

In summary, AUCs for the clinical application of amyloid imaging are established, and the currently available literature points to their validity. Also, visual amyloid image analysis is highly standardized. A disclosure of amyloid imaging results is desired by many cognitively impaired subjects, and seems to be safe once appropriate education is delivered to the disclosing clinicians. Regarding clinical utility, increasing evidence points i) to a change of diagnosis via amyloid imaging in ~30% of cases, ii) to an increase of diagnostic confidence in ~60% of cases, iii) to a change of patient management in ~60% of cases, and specifically iv) to a change of medication in ~40% of cases. Also, amyloid imaging results seem to relevantly impact caregivers. Further, initial simulation studies point to a potential positive patient outcome effect and cost-effectiveness of amyloid imaging. These features, however, will require confirmation in prospective clinical trials. More work is also required to determine the clinical utility of amyloid imaging specifically in MCI subjects, and in comparison/conjunction with other AD biomarkers.

Taken together, the clinical use of amyloid imaging is subject to ongoing investigations, and the currently available data point to a relevant clinical utility of this imaging technique. Ongoing research will tell whether this will translate into a benefit to the patients. This research will by that answer the question of whether this accurate approach to non-invasively determine amyloid plaque load will be able to fully tap its potential in the clinical field.

ACKNOWLEDGEMENT

We would like to thank Damian McLeod for proofreading the manuscript.

DISCLOSURES

HB and OS received research support, consultant honoraria, and travel expenses from Piramal Imaging, Berlin, Germany.

REFERENCES

- 1) Braak H, Braak E. Neuropathological staging of Alzheimer-related changes. *Acta Neuropathol.* 1991;82:239-59
- 2) Jack CR Jr, Knopman DS, Jagust WJ, et al. Hypothetical model of dynamic biomarkers of the Alzheimer's pathological cascade. *Lancet Neurol.* 2010;9:119-28
- 3) Alzheimer Europe. Public attitudes about diagnosis: Value of knowing. www.alzheimer-europe.org/Research, Accessed on May 1st, 2017
- 4) Bradford A, Kunik ME, Schulz P, Williams SP, Singh H. Missed and delayed diagnosis of dementia in primary care: prevalence and contributing factors. *Alzheimer Dis Assoc Disord.* 2009;23:306-14.
- 5) Bradford A, Upchurch C, Bass D, et al. Knowledge of documented dementia diagnosis and treatment in veterans and their caregivers. *Am J Alzheimers Dis Other Demen.* 2011;26:127-33
- 6) Hauber AB, Johnson FR, Fillit H, et al. Older Americans' risk-benefit preferences for modifying the course of Alzheimer disease. *Alzheimer Dis Assoc Disord.* 2009;23:23-32
- 7) Klein EP, Kaye J. Dementia specialists and early adoption of amyloid imaging. *J Alzheimers Dis.* 2013;33:445-50
- 8) Chiotis K, Saint-Aubert L, Boccardi M, et al. Clinical validity of increased cortical uptake of amyloid ligands on PET as a biomarker for Alzheimer's disease in the context of a structured 5-phase development framework. *Neurobiol Aging.* 2017;52:214-27
- 9) Boxer AL, Knopman DS, Kaufer DI, et al. Memantine in patients with frontotemporal lobar degeneration: a multicentre, randomised, double-blind, placebo-controlled trial. *Lancet Neurol.* 2013;12:149-56
- 10) Boccardi M, Altomare D, Ferrari C, et al. Do beliefs about the pathogenetic role of amyloid affect the interpretation of amyloid PET in the clinic. *Neurodegener Dis.* 2016;16:111-7
- 11) Laforce R Jr, Rabinovici GD. Amyloid imaging in the differential diagnosis of dementia: review and potential clinical applications. *Alzheimers Res Ther.* 2011;3:31
- 12) Vandenberghe R, Adamczuk K, Dupont P, Laere KV, Chételat G. Amyloid PET in clinical practice: Its place in the multidimensional space of Alzheimer's disease. *Neuroimage Clin.* 2013;2:497-511

- 13) Johnson KA, Minoshima S, Bohnen NI, et al. Appropriate use criteria for amyloid PET: a report of the Amyloid Imaging Task Force, the Society of Nuclear Medicine and Molecular Imaging, and the Alzheimer's Association. *J Nucl Med.* 2013;54:476-90
- 14) Johnson KA, Minoshima S, Bohnen NI, et al. Update on appropriate use criteria for amyloid PET imaging: dementia experts, mild cognitive impairment, and education. *J Nucl Med.* 2013;54:1011-3
- 15) Grundman M, Johnson KA, Lu M, et al. Effect of amyloid imaging on the diagnosis and management of patients with cognitive decline: Impact of appropriate use criteria. *Dement Geriatr Cogn Disord.* 2016;41:80-92
- 16) Apostolova LG, Haider JM, Goukasian N, et al. Critical review of the appropriate use criteria for amyloid imaging: Effect on diagnosis and patient care. *Alzheimers Dement.* 2016;5:15-22
- 17) Zwan MD, Bouwman FH, Konijnenberg E, et al. Diagnostic impact of [18F]flutemetamol PET in early-onset dementia. *Alzheimers Res Ther.* 2017;9:2
- 18) Barthel H, Seibyl J, Sabri O. The role of positron emission tomography imaging in understanding Alzheimer's disease. *Expert Rev Neurother.* 2015;15:395-406
- 19) Buckley CJ, Sherwin PF, Smith AP, Wolber J, Weick SM, Brooks DJ. Validation of an electronic image reader training programme for interpretation of [18F]flutemetamol β -amyloid PET brain images. *Nucl Med Commun.* 2017;38:234-41
- 20) Seibyl J, Catafau AM, Barthel H, et al. Impact of training method on the robustness of the visual assessment of 18F-Florbetaben PET scans: Results from a phase-3 study. *J Nucl Med.* 2016;57:900-6
- 21) Pontecorvo MJ, Arora AK, Devine M, et al. Quantitation of PET signal as an adjunct to visual interpretation of florbetapir imaging. *Eur J Nucl Med Mol Imaging.* 2017;44:825-37
- 22) Barthel H, Seibyl J, Sabri O. Yes we can analyse amyloid images - Now what? *Eur J Nucl Med Mol Imaging.* 2017;44:822-4
- 23) Sullivan K, O'Connor F. Should a diagnosis of Alzheimer's disease be disclosed? *Aging Ment Health.* 2001;5:340-8
- 24) Roberts JS, Dunn LB, Rabinovici GD. Amyloid imaging, risk disclosure and Alzheimer's disease: ethical and practical issues. *Neurodegener Dis Manag.* 2013;3:219-29
- 25) Wikler EM, Blendon RJ, Benson JM. Would you want to know? Public attitudes on early diagnostic testing for Alzheimer's disease. *Alzheimers Res Ther.* 2013;5:43

- 26) van den Dungen P, van Kuijk L, van Marwijk H, et al. Preferences regarding disclosure of a diagnosis of dementia: a systematic review. *Int Psychogeriatr*. 2014;26:1603-18
- 27) Shulman MB, Harkins K, Green RC, Karlawish J. Using AD biomarker research results for clinical care: a survey of ADNI investigators. *Neurology*. 2013;81:1114-21
- 28) Leuzy A, Zimmer ER, Heurling K, Rosa-Neto P, Gauthier S. Use of amyloid PET across the spectrum of Alzheimer's disease: clinical utility and associated ethical issues. *Amyloid*. 2014;21:143-8
- 29) Grill JD, Apostolova LG, Bullain S, et al. Communicating mild cognitive impairment diagnoses with and without amyloid imaging. *Alzheimers Res Ther*. 2017;9:35
- 30) Lingler JH, Klunk WE. Disclosure of amyloid imaging results to research participants: has the time come? *Alzheimers Dement*. 2013;9:741-4
- 31) Lingler JH, Butters MA, Gentry AL, et al. Development of a standardized approach to disclosing amyloid imaging research results in mild cognitive impairment. *J Alzheimers Dis*. 2016;52:17-24
- 32) Lim YY, Maruff P, Getter C, Snyder PJ. Disclosure of positron emission tomography amyloid imaging results: A preliminary study of safety and tolerability. *Alzheimers Dement*. 2016;12:454-8
- 33) Burns JM, Johnson DK, Liebmann EP, Bothwell RJ, Morris JK, Vidoni ED. Safety of disclosing amyloid status in cognitively normal older adults. *Alzheimers Dement*. 2017;pii: S1552-5260(17)30048-1
- 34) Frederiksen KS, Hasselbalch SG, Hejl AM, Law I, Højgaard L, Waldemar G. Added diagnostic value of (11)C-PiB-PET in memory clinic patients with uncertain diagnosis. *Dement Geriatr Cogn Dis Extra*. 2012;2:610-21
- 35) Schipke CG, Peters O, Heuser I, et al. Impact of beta-amyloid-specific florbetaben PET imaging on confidence in early diagnosis of Alzheimer's disease. *Dement Geriatr Cogn Disord*. 2012;33:416-22
- 36) Guo S, Getsios D, Hernandez L, et al. Florbetaben PET in the early diagnosis of Alzheimer's disease: A discrete event simulation to explore its potential value and key data gaps. *Int J Alzheimers Dis*. 2012;2012:548157

- 37) Degerman Gunnarsson M, Lindau M, Santillo AF, et al. Re-evaluation of clinical dementia diagnoses with Pittsburgh compound B positron emission tomography. *Dement Geriatr Cogn Dis Extra*. 2013;3:472-81
- 38) Ossenkoppele R, Prins ND, Pijnenburg YA, et al. Impact of molecular imaging on the diagnostic process in a memory clinic. *Alzheimers Dement*. 2013;9:414-21
- 39) Grundman M, Pontecorvo MJ, Salloway SP, et al. Potential impact of amyloid imaging on diagnosis and intended management in patients with progressive cognitive decline. *Alzheimer Dis Assoc Disord*. 2013;27:4-15
- 40) Mitsis EM, Bender HA, Kostakoglu L, et al. A consecutive case series experience with [18F]florbetapir PET imaging in an urban dementia center: impact on quality of life, decision making, and disposition. *Mol Neurodegener*. 2014;9:10
- 41) Sánchez-Juan P, Ghosh PM, Hagen J, et al. Practical utility of amyloid and FDG-PET in an academic dementia center. *Neurology*. 2014;82:230-8
- 42) Zannas AS, Doraiswamy PM, Shpanskaya KS, et al. Impact of ¹⁸F-florbetapir PET imaging of β -amyloid neuritic plaque density on clinical decision-making. *Neurocase*. 2014;20:466-73
- 43) Hornberger J, Michalopoulos S, Dai M, Andrade P, Dilla T, Happich M. Cost-effectiveness of Florbetapir-PET in Alzheimer's disease: A Spanish societal perspective. *J Ment Health Policy Econ*. 2015;18:63-73
- 44) Boccardi M, Altomare D, Ferrari C, et al. Assessment of the incremental diagnostic value of Florbetapir F18 imaging in patients with cognitive impairment: The incremental diagnostic value of amyloid PET with [18F]-Florbetapir (INDIA-FBP) Study. *JAMA Neurol*. 2016;73:1417-24
- 45) Bensaïdane MR, Beauregard JM, Poulin S, et al. Clinical utility of amyloid PET imaging in the differential diagnosis of atypical dementias and its impact on caregivers. *J Alzheimers Dis*. 2016;52:1251-62
- 46) Weston PS, Paterson RW, Dickson J, et al. Diagnosing dementia in the clinical setting: Can amyloid PET provide additional value over cerebrospinal fluid? *J Alzheimers Dis*. 2016;54:1297-1302
- 47) Schönecker S, Prix C, Raiser T, et al. Amyloid positron-emission-tomography with [18 F]-florbetaben in the diagnostic workup of dementia patients. *Nervenarzt*. 2017;88:156-61

- 48) Hornberger J, Bae J, Watson I, Johnston J, Happich M. Clinical and cost implications of amyloid beta detection with amyloid beta positron emission tomography imaging in early Alzheimer's disease - the case of florbetapir. *Curr Med Res Opin.* 2017;33:675-85
- 49) Laforce R, Rosa-Neto P, Soucy JP, Rabinovici GD, Dubois B, Gauthier S. Canadian consensus guidelines on use of amyloid imaging in Canada: Update and future directions from the specialized task force on amyloid imaging in Canada. *Can J Neurol Sci.* 2016;43:503-12
- 50) Zhong Y, Karlawish J, Johnson MK, Neumann PJ, Cohen JT. The potential value of β -amyloid imaging for the diagnosis and management of dementia: A survey of clinicians. *Alzheimer Dis Assoc Disord.* 2017;31:27-33
- 51) Ganz ML, Tawah AF, Guo S, et al. The impact of β -amyloid positron emission tomography on the diagnostic and treatment decisions of dementia experts. *Neurodegener Dis Manag.* 2017;7:107-17
- 52) Witte MM, Foster NL, Fleisher AS, et al. Clinical use of amyloid-positron emission tomography neuroimaging: Practical and bioethical considerations. *Alzheimers Dement.* 2015;1:358-67
- 53) Steinbrook R. The Centers for Medicare & Medicaid services and amyloid- β positron emission tomography for Alzheimer disease. *JAMA Intern Med.* 2014;174:135
- 54) Cohen JP, Dong J, Lu CY, Chakravarthy R. Restricting access to florbetapir: Medicare coverage criteria for diagnostics and drugs are inconsistent. *BMJ.* 2015;351:h3333
- 55) IDEAS study. www.ideas-study.org, Accessed on May 1st, 2017
- 56) AMYPAD study. www.amypad.eu, Accessed on May 1st, 2017
- 57) Teipel S, Drzezga A, Grothe MJ, et al. Multimodal imaging in Alzheimer's disease: validity and usefulness for early detection. *Lancet Neurol.* 2015;14:1037-53
- 58) Schütz L, Lobsien D, Fritsch D, et al. Feasibility and acceptance of simultaneous amyloid PET/MRI. *Eur J Nucl Med Mol Imaging.* 2016;43:2236-43

FIGURE LEGENDS

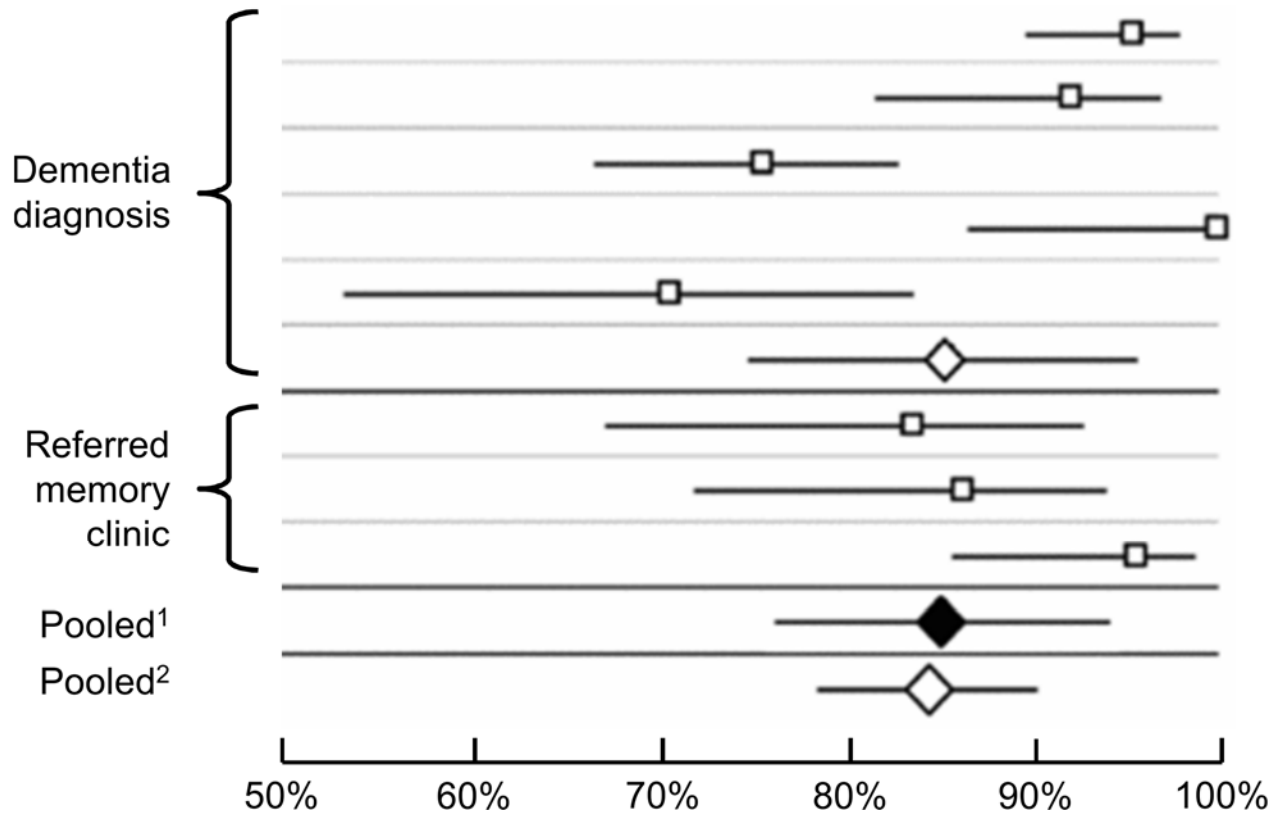


Figure 1

Results of a meta-analysis investigating the preference regarding disclosure of a dementia diagnosis in subjects with cognitive impairment. ¹Pooled percentage in favor, studies with a response rate $\geq 75\%$, ²Pooled percentage in favor, all studies. Figure adapted from (26).

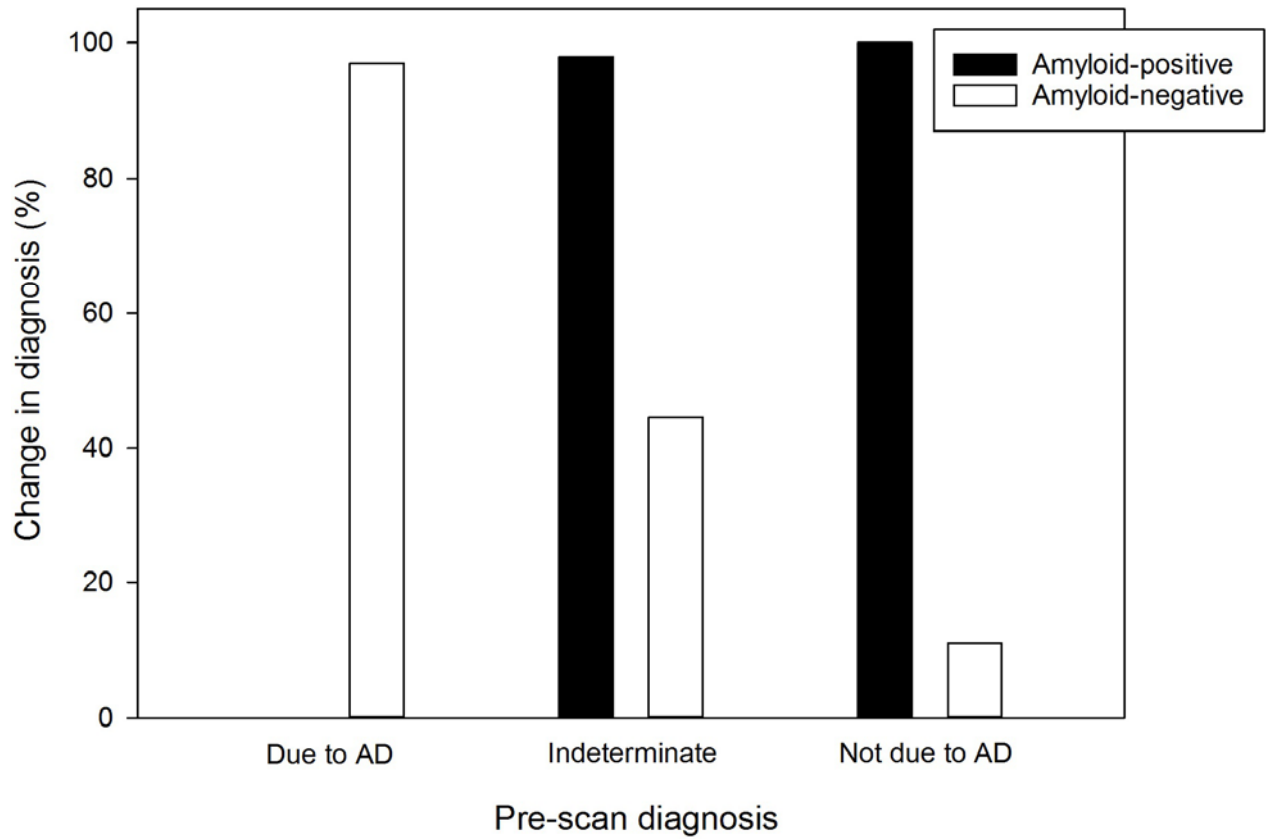


Figure 2

Change of diagnosis via amyloid imaging depending on pre-scan diagnosis and binary imaging outcome. The data to create this graph were taken from (39). AD=Alzheimer's disease.

TABLES**Table 1: Clinical Utility of Amyloid PET Imaging**

Reference	Change of diagnosis [% cases]	Gain of diagnostic confidence [% cases]	Gain of diagnostic confidence [on 0-100% scale]	Overall change of management [% cases]	Change of medication [% cases]
Frederiksen et al. 2012 (34)	23	49	-	-	-
Schipke et al. 2012 (35)	-	83	-	68	-
Degerman Gunnarsson et al. 2013 (37)	30	-	-	-	-
Ossenkoppele et al. 2013 (38)	23	-	16	-	-
Grundman et al. 2013 (39)	55	-	22	87	31
Mitsis et al. 2014 (40)	33	-	-	-	-
Sanchez-Juan et al. 2014 (41)	9	8	-	-	35
Zannas et al. 2014 (42)	72	36	-	-	45
Boccardi et al. 2016 (10)	27	-	21	-	60
Bensaïdane et al. 2016 (45)	32	44	-	71	39
Weston et al. 2016 (46)	35	90	-	40	30
Schönecker et al. 2016 (47)	21	-	-	-	-
Zwan et al. 2017 (17)	19	87	-	37	24
<i>Weighted* mean</i>	29*	63*	20*	64*	38*

*By study cohort size

Supplemental text

Impact of Amyloid Imaging on Diagnosis

In some of the related studies, a change of diagnosis occurred more often in (amyloid-negative) subjects with a pre-scan diagnosis of AD as compared to (amyloid-positive) non-AD subjects. This underpins the clinical usefulness of high negative predictive value of amyloid imaging to exclude amyloid pathology, following the widely accepted rule of “no AD without amyloid load”. Also of interest, in the study by Ossenkoppele et al. (2013) a change of diagnosis was only observed in cases with a pre-scan diagnostic confidence <90% (38). Similarly, Sanchez-Juan et al. 2014 reported a higher diagnosis change impact in a subgroup of subjects with a pre-amyloid scan diagnostic dilemma (41). Also, in accordance to the above results, Weston et al. 2016 noted amyloid imaging-related change of diagnosis especially in atypical (young-onset) dementia, or borderline cerebrospinal fluid cases (46), results which can be regarded as evidence supporting the current amyloid imaging AUC concept outlined above.

Impact of Amyloid Imaging on Diagnostic Confidence

Across the related studies, the pre-scan diagnosis or the amyloid PET result did not significantly impact the diagnostic confidence gain obtained, i.e. in most circumstances both a positive and a negative amyloid PET scan result increased diagnostic confidence regardless of the pre-scan diagnosis. This is apart from a recent ¹⁸F-Flutemetamol bi-center study by Zwan et al. (2017), who included 211 subjects with early-onset cognitive impairment and a diagnostic confidence <90%. In this study, no gain in diagnostic confidence was - somewhat surprisingly - found in subjects with a pre-scan diagnosis of AD and a negative PET, as well as in subjects with the pre-scan diagnosis of other dementia (17). It was further reported by Boccardi et al. (2016) that

the gain of diagnostic confidence by amyloid imaging is independent from whether the imaging result impacted diagnosis (10,34).

Impact of Amyloid Imaging on Patient Management

Changes in planned diagnostic follow-up after amyloid imaging was reported in three related studies for 10-26% of cases (17,39,46), and changes of care plans via amyloid imaging for 11% and 39% of cases, respectively (17,45). Finally, Grundman et al. (2016) observed changes in the plan to refer subjects to clinical trials in 16% of cases (39). Also of interest, it was noted in two studies that the impact of amyloid imaging on patient management was higher for PET-positive vs. -negative subjects (17,44), and that medication changes occurred more often in PET-positives vs. -negatives, while the opposite was the case for care plan changes (45).

Supplemental Tables

Supplemental Table 1: Criteria for appropriate and inappropriate use of amyloid imaging

Amyloid imaging appropriate	Amyloid imaging inappropriate
Persistent or progressive unexplained MCI	Core clinical criteria for probable AD with typical age of onset
Core clinical criteria for possible AD because of unclear clinical presentation*	To determine dementia severity
Progressive dementia and atypically early age of onset	Solely positive family history of dementia or presence of APOE4
	Solely subjective cognitive complaint
	In lieu of genotyping in suspected autosomal mutation carriers
	Nonmedical use**

Adapted from (13). MCI= Mild cognitive impairment, AD=Alzheimer's dementia, APOE4= Apolipoprotein ε4. *Either atypical clinical course or etiologically mixed presentation, **Legal, insurance coverage, employment screening etc.

Supplemental Table 2: Recommendations for disclosure of amyloid imaging results to MCI subjects

Offer pre-test counseling
Use clear graphics
Review the brain PET images during disclosure
Offer take-home materials
Call post-disclosure to address emerging questions
Communicate seamlessly with primary care providers

As proposed by (31). MCI=Mild cognitive impairment.

Supplemental Table 3: Studies on Clinical Utility of Amyloid PET Imaging

Reference	Cases [n]	Pre-amyloid PET diagnosis	Amyloid tracer	PET-positivity [% cases]	Comments
Frederiksen et al. 2012 (34)	57	Cognitive impairment with diagnostic uncertainty	11C-PIB	47	-
Schipke et al. 2012 (35)	201	Probable AD vs. HC	18F-Florbetaben	56	Retrospective "intended change" survey of phase 2 clinical tracer development study
Degerman Gunnarsson et al. 2013 (37)	18	Probable AD vs. FTD	11C-PIB	39	Amyloid PET + FDG + repeated NEUROPSYCH
Ossenkoppele et al. 2013 (38)	154	Cognitive impairment with diagnostic uncertainty	11C-PIB	48	Amyloid PET + FDG
Grundman et al. 2013 (39)	229	Cognitive impairment (diagnostic confidence of AD=15-85%)	18F-Florbetapir	49	-
Mitsis et al. 2014 (40)	30	Cognitive impairment with diagnostic uncertainty	18F-Florbetapir	50	-
Sanchez-Juan et al. 2014 (41)	140	Cognitive impairment (19% with diagnostic uncertainty)	11C-PIB	49	Amyloid PET + FDG
Zannas et al. 2014 (42)	11	Cognitive impairment (diagnostic confidence of AD=15-85%)	18F-Florbetapir	55	Subset of cohort in [39]
Boccardi et al. 2016 (10)	228	Cognitive impairment (diagnostic confidence of AD=15-85%)	18F-Florbetapir	60	-
Bensaïdane et al. 2016 (45)	28	Atypical* dementia	18F-NAV4694	50	-
Weston et al. 2016 (46)	20	Different dementia syndromes	18F-Florbetapir	90	-
Schönecker et al. 2016 (47)	33	Cognitive impairment	18F-Florbetaben	52	-
Zwan et al. 2017 (17)	211	Cognitive impairment (diagnostic confidence <90%)	18F-Flutemetamol	63	Early-onset or mild dementia

AD=Alzheimer's disease, HC=Healthy control, FTD=Frontotemporal dementia, NEUROPSYCH=Neuropsychological testing, *In the opinion of expert behavioral neurologists after review of history, basic lab, MRI, and 18-F-FDG PET