

# CHARACTERISTICS OF THYROID SCANS IN NORMAL PERSONS, HYPERTHYROIDISM AND NODULAR GOITER

Fevzi Renda, Richard A. Holmes, Wendy A. North and Henry N. Wagner, Jr.

*The Johns Hopkins Medical Institutions, Baltimore, Maryland*

Since Cassen first introduced the use of automatic radioisotope scanning for the study of the thyroid gland, many reports have appeared describing the importance and value of this procedure in the diagnosis of various disorders of the thyroid gland (1-7). The avidity of the thyroid gland for radioiodine has permitted visualization of its size, shape, position and uniformity of function. Because of the continual improvement in scanning instruments and the introduction of new radionuclides, we believed that it would be of value to reexamine as quantitatively as possible the usefulness of thyroid scanning in the detection of thyroid disease.

## METHODS

One group of 44 patients included those referred to the Division of Nuclear Medicine to have brain scans. They received  $^{99m}\text{Tc}$  pertechnetate (200  $\mu\text{c}/\text{kg}$  body weight) and, after the brain scan was obtained, a thyroid scan was performed. The approximate time of scanning was 2 hr after administration of the original pertechnetate dose. No additional radioactivity was given. The youngest patient in this group was 13 years old and the oldest was 69 years old. A second group included 54 patients whose ages ranged from 17 to 55 years, diagnosed as having hyperthyroidism on the basis of clinical signs and symptoms, elevated protein bound iodine and increased radioiodine uptake values. These patients received oral sodium  $^{131}\text{I}$  (20-25  $\mu\text{c}$ ). A third group of 20 patients was diagnosed as being normal with respect to thyroid function on the basis of clinical and laboratory data. Their ages ranged from 26 to 79 years. A fourth group of 29 patients aged 15 to 63 years had clinically obvious nodular goiters.

Uptake of radioiodine was measured using a 3  $\times$  2-in. NaI(Tl) crystal with a flat-field collimator;

measurements were made at 2, 24 and, occasionally, 6 hr after administration of the dose. The values were expressed as a percentage of the administered dose measured in an Oak Ridge Institute of Nuclear Studies phantom.

Thyroid scans were performed using a moving detector scanner with an 8  $\times$  4-in. NaI(Tl) crystal. With pertechnetate, a 1,045-channel collimator\* focusing at a depth of 3.5 in. from the collimator face was used. Care was taken to be sure that the thyroid gland was in the focal plane of the collimator. A 439-channel collimator focusing at 3.5 in. was used in the iodine studies. The scanning speed was 40 in./min. Hyperextension of the neck minimized motion artifacts by greatly reducing the frequency of swallowing.

After obtaining the scanning image of the thyroid, the area of the entire gland, as viewed on the scan, as well as the area of each lobe, was measured by two observers using a planimeter. The scans were also classified on the basis of appearance as described in the next section.

## RESULTS

In the 44 patients who had brain scans, the total area of the thyroid ranged from 10 to 30  $\text{cm}^2$  with a mean value of 19  $\text{cm}^2$  and a standard deviation of  $\pm 5.3$  (Fig. 1 and Table 1). The ratio of the areas of the left and right lobes (L/R) ranged from 0.55 to 1.3 with a mean value of 0.80 and a standard deviation of  $\pm 0.35$ . In the group of 20 referred for thyroid evaluation and found to be normal, the total area of the thyroid gland

Received April 6, 1967; accepted Nov. 15, 1967.

\* Obtained from Brookhaven Laboratory, Upton, New York.

varied from 12 to 26 cm<sup>2</sup> with a mean value of 16 cm<sup>2</sup> and a standard deviation of  $\pm 3.3$ . The ratio of L/R lobe areas ranged between 0.64 and 1.3 with a mean value of 0.90 and standard deviation of  $\pm 0.20$ .

In the 54 patients who had hyperthyroidism, planimetric measurements of the total area of the glands ranged between 16 and 45 cm<sup>2</sup>, with a mean value of 26 cm<sup>2</sup> and standard deviation of  $\pm 6.9$ . The ratio of L/R lobe areas varied from 0.35 to 1.4 with a mean value of 0.9 and a standard deviation of  $\pm 0.38$ .

In the 29 patients with nodular goiters the total frontal plane area of the thyroid was 13 to 53 cm<sup>2</sup> with a mean value of 28 cm<sup>2</sup> and a standard deviation of  $\pm 9.9$ .

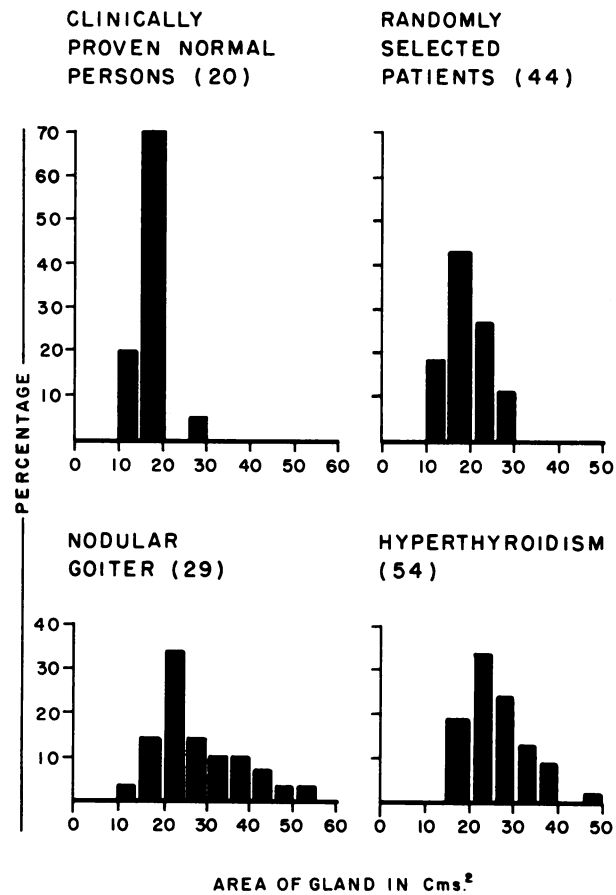
In the group of patients who had brain scans, the lobes of the thyroid appeared positionally symmetrical in 70% of the patients; in 70% of this entire group of 44 patients, the lobes of the thyroid gave a continuous rounded or convex border throughout (Fig. 2). The remaining 30% had irregular contours, at times with straightening and concavitation of the borders of either one or both lobes (Fig. 3). In 91% of the patients of this group, radioactivity was uniformly distributed throughout the gland.

In the second group of normal patients, 60% of the glands had convex borders throughout, while the remaining 40% had irregular and, at times, concave borders. In 65% of these patients, a uniform distribution of radioiodine was observed.

In the group of patients proven to have hyperthyroidism, 89% of the thyroids had convex contours as compared to 11% who had thyroid glands with irregular borders. The radioactivity was evenly distributed in 63% of the patients in this group. In all of the patients with nodular goiter, the glands were asymmetrical with irregular borders and numerous concavities (Fig. 4). There were often multiple areas of decreased activity within the gland.

#### DISCUSSION

The role of thyroid scanning in the diagnosis of ectopic thyroid tissue such as substernal goiter (Fig. 5) and in the diagnosis of "hot" nodules of the thyroid is well established. Other uses of thyroid scanning are less well defined. For example, scanning has been used only occasionally to obtain objective data concerning the size of the thyroid. Myhill and his associates found a good correlation between the scanning image and the frontal view of the gland after surgical removal (8). Such data are useful because it is often difficult to obtain an accurate estimation of the true size of the gland by physical examination alone. Most observers agree that if a

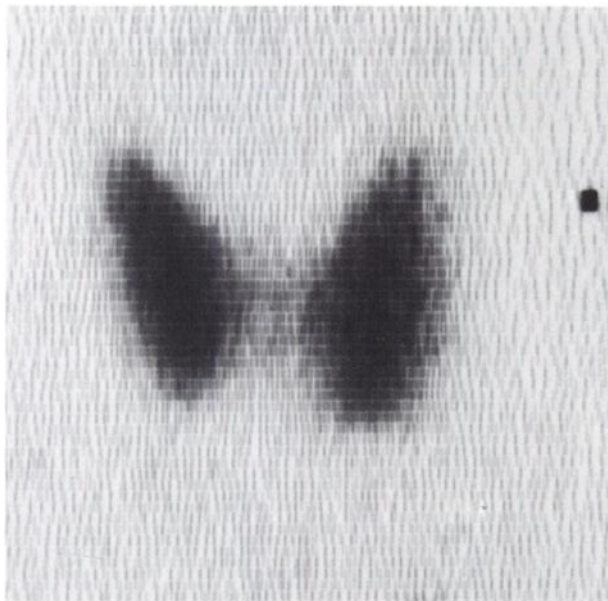


**FIG. 1.** Frontal plane area of thyroid as determined by scanning four groups of subjects. Numbers in parenthesis correspond to number of subjects. Percentage refers to percentage of number of persons in each group.

gland is visible and palpable, it is a goiter, although discrepancies between observers concerning the degree of enlargement are often found (9-11).

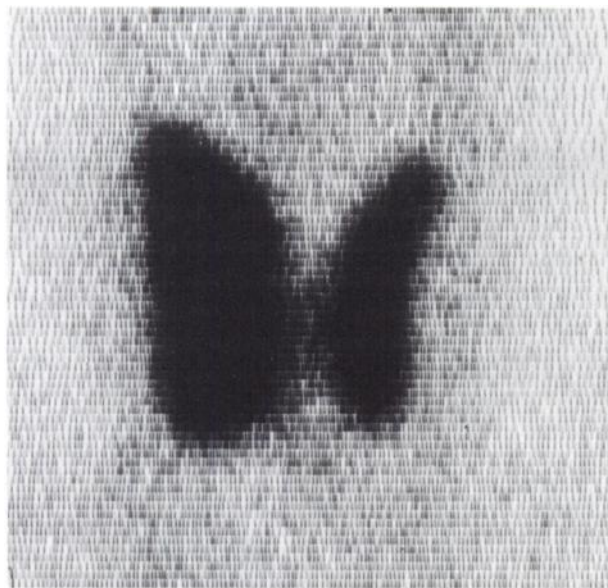Our data indicate that the frontal plane area of the thyroid scan is significantly less in normal per-

Groups	Number	Total area (cm <sup>2</sup> ) (mean $\pm$ sd)	Ratio L/R (mean $\pm$ 2sd)
Randomly selected patients	44	19 $\pm$ 5.3	0.8 $\pm$ 0.35
Clinically normal patients	20	16 $\pm$ 3.3	0.9 $\pm$ 0.20
Hyperthyroidism	54	26 $\pm$ 6.9	0.9 $\pm$ 0.38
Nodular goiter	29	29 $\pm$ 9.9	—



**FIG. 2.** Thyroid scan of normal person; all borders are convex.

sons than in patients with nodular goiter and hyperthyroidism. Most of the normal persons had areas less than 20 cm<sup>2</sup> while only about 17% of the nodular and hyperthyroid group had thyroids that were less than 20 cm<sup>2</sup>. No normal patient had a thyroid that measured greater than 30 cm<sup>2</sup>. The ratio of the areas of the two lobes was approximately the same in all three groups. The two lobes were not compared in the patients with nodular goiter because



**FIG. 3.** Thyroid scan illustrating concave defect on lateral border of left lobe.

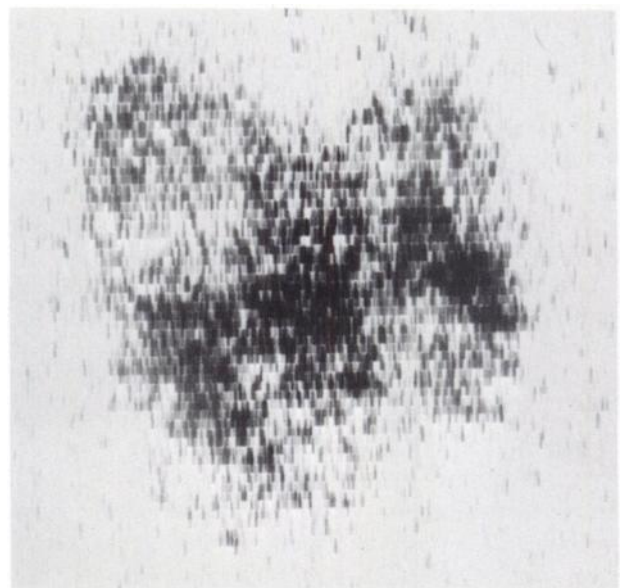
gross asymmetry was obvious and nonuniform distribution of the isotope, in many cases, made estimations of the exact borders impossible.

In Mortensen's series of 1,000 consecutive autopsy studies (12), in about 20% of the subjects, the thyroid contained a solitary nodule, despite the fact that no abnormality of thyroid structure and function had been suspected during life. These data point out the difficulty of detecting the presence or absence of nodules by physical examination alone. Nodules that were not clinically detected varied from 2 mm to 7 cm in diameter when specimens were examined at autopsy. Quinn's recent data based on scans of thyroids of randomly selected brain scan patients also revealed a high incidence of nodularity within the thyroid glands of normal individuals as age increased (13). He concluded therefore that the presence of multinodularity was as high as 26%, a figure similar to Mortensen's.

In our group of normal patients, approximately 30% had irregularities of the borders of the scan image, suggesting a possible thyroid abnormality. Only 9% showed nonuniform distribution of radioactivity within the gland. In the group with hyperthyroidism, 11% of the glands had irregular borders and 37% showed nonuniform distribution within the gland. All the nodular goiters had irregular margins and nonuniform distribution of the radioactivity.

#### CONCLUSIONS

1. Thyroid scanning may be useful in detecting occult thyroid disorders that are not apparent by other means.



**FIG. 4.** Thyroid scan illustrating patchy decrease in activity indicative of multiple nodules.

ACKNOWLEDGMENT

This work was aided by U.S. Public Health Service grant #GM10548.

REFERENCES

1. CASSEN, B., CURTIS, L., REED, C. AND LIBBY, R.: Instrumentation for I-131 use in medical studies. *Nucleonics* 9: No. 8, 46, 1951.
2. GOODWIN, W. E., BAUER, F. K., BARRETT, T. F. AND CASSEN, B.: A method using I-131 for determination of abnormal thyroid morphology. *Am. J. Roentgenol. Radium Therapy Nucl. Med.* 68:963-970, 1952.
3. ALLEN, M. C., JR., LIBBY, R. L. AND CASSEN, B.: Scintillation counter in clinical studies in human thyroid physiology using I-131. *J. Clin. Endocrinol.* 11:492, 1951.
4. KUHL, D. E.: Radiiodine scanning in disease of the thyroid gland. *Radiol. Clin. North Amer.* 1:101, 1963.
5. THOMSON, J. A.: The normal thyroid scan. *Lancet* 2:308, 1966.
6. JOHNSON, P. C. AND BEIERWALTES, W. H.: Reliability of scintiscanning nodular goiters in judging presence or absence of carcinoma. *J. Clin. Endocrinol. Metab.* 15:865, 1965.
7. MEADOWS, P. M.: Scintillation scanning in the management of the clinically single thyroid nodule. *J.A.M.A.* 177: 229, 1961.
8. MYHILL, J., REEVE, T. S. AND FIGGIS, P. M.: Measurement of the mass of the thyroid gland in vivo. *Am. J. Roentgenol. Radium Therapy Nucl. Med.* 44:828, 1965.
9. KELLY, F. C. AND SNEDDEN, W. W.: Prevalence and geographical distribution of endemic goiter. *Bull. World Health Org.* 18:5, 1958.
10. TERPSTRA, J. AND QUERIDO, A.: The endemic goiter in the Netherlands. *Acta Endocrinol.* 31:433, 1959.
11. HADJIDAKIS, S. G., KOUTRAS, D. A. AND DAIKOS, G. K.: Endemic goiter in Greece. *Family Studies J. Med. Genetics* 1:82, 1964.
12. MORTENSEN, J. D., WOOLNER, L. B. AND BENNETT, W. A.: Gross and microscopic findings in clinically normal thyroid glands. *J. Clin. Endocrinol.* 15:1,270, 1955.
13. QUINN, J. L., III AND BRAND, W. N.: Technetium<sup>99m</sup> pertechnetate thyroid scans obtained incidental to brain scanning. *J. Nucl. Med.* 5:342, 1966.

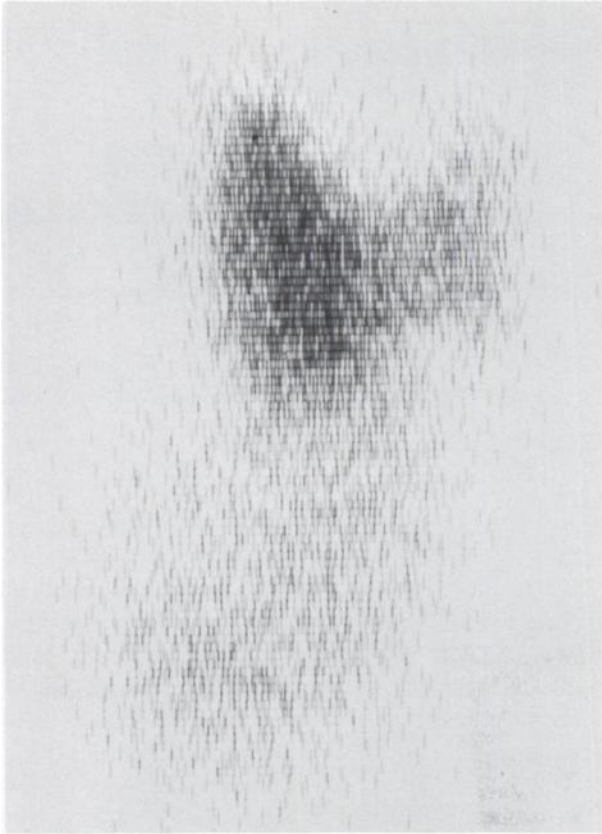


FIG. 5. Thyroid scan with substernal extension of goiter.

2. A thyroid gland has a high probability of being normal if it has a frontal plane area less than 20 cm<sup>2</sup>, if all borders of both lobes are convex and if the radioactivity is uniformly distributed.

3. In a gland with a frontal area greater than 30 cm<sup>2</sup>, or with irregular borders or with nonuniform distribution of activity within the gland, the thyroid is probably abnormal.