
Intraoperative Imaging for Sentinel Node Identification in Prostate Carcinoma: Its Use in Combination with Other Techniques

Lenka Vermeeren¹, Renato A. Valdés Olmos¹, Willem Meinhardt², and Simon Horenblas²

¹Department of Nuclear Medicine, Antoni van Leeuwenhoek Hospital, Netherlands Cancer Institute, Amsterdam, The Netherlands; and ²Department of Urology, Antoni van Leeuwenhoek Hospital, Netherlands Cancer Institute, Amsterdam, The Netherlands

We evaluated a portable γ -camera for sentinel node identification during laparoscopic sentinel lymphadenectomy for prostate cancer. **Methods:** We analyzed the portable γ -camera for intraoperative sentinel node visualization in 55 patients after ^{99m}Tc injection, preoperative planar lymphoscintigraphy, and SPECT/CT. **Results:** Sixteen percent of 178 nodes seen on SPECT/CT could not be detected with the portable γ -camera. A seed pointer was useful for localizing sentinel nodes intraoperatively in 27% of patients. Seventeen additional sentinel nodes (2 tumor-positive nodes) were removed by monitoring after excision. The location of each sentinel node was significantly associated with the ability to detect it intraoperatively. **Conclusion:** Intraoperative imaging leads to excision of more radioactive nodes and can determine the residual radioactivity after excision. The use of a radioactive source as a pointer enables efficient identification of nodes in difficult locations (para-aortic nodes) and in patients with a high body mass index.

Key Words: prostatic neoplasms; sentinel lymph node biopsy; radionuclide imaging; gamma cameras

J Nucl Med 2011; 52:741–744

DOI: 10.2967/jnumed.110.085068

Sentinel lymphadenectomy for staging of prostate cancer has been validated by several authors (1–3). Detection of sentinel nodes has been optimized by performing preoperative sentinel node imaging, including planar lymphoscintigraphy and SPECT/CT (4,5). To further improve intraoperative detection, we introduced a portable γ -camera to guide laparoscopic localization of sentinel nodes in prostate cancer (6).

Portable γ -cameras have been developed to provide intraoperative radioguidance, and a recent application has been intraoperative identification of radioactive lymph nodes (7–10). In urologic malignancies, sentinel nodes

could be visualized in 90% of the patients and the use of a pointer enabled exact localization of the hot nodes (6).

The goal of the current study was to establish the value of intraoperative sentinel node imaging with a portable γ -camera in patients with prostate cancer. We evaluated whether intraoperative detection rates improved by additional intraoperative imaging.

MATERIALS AND METHODS

At our institute, patients with intermediate-prognosis prostate cancer who elect to be treated with radiotherapy are offered a sentinel node biopsy to determine the therapeutic regimen (2). These patients are clinical stage T2b or higher or have a prostate-specific antigen (PSA) level above 10.0 ng/mL or a Gleason sum score of 6 or more.

Fifty-five patients with prostate cancer in whom preoperative lymphoscintigraphy had shown lymphatic drainage were prospectively included after giving informed consent. Their characteristics are shown in Table 1. The patients underwent surgery at The Netherlands Cancer Institute between February 2007 and April 2010.

Lymphoscintigraphy

^{99m}Tc-nanocolloid (GE Healthcare) was injected into the prostate in 4 deposits (1 in each quadrant), guided by transrectal ultrasonography. The aimed injected dose was 225 MBq, and each deposit of 0.1 mL was flushed with 0.7 mL of saline. Distribution of the radioactivity was evaluated by anterior and lateral planar lymphoscintigraphy (SymbiaT; Siemens) at 15 min and 2 h after injection of the radiotracer. A SPECT/CT scan was generated with the same γ -camera, to localize the sentinel nodes.

The first nodes in each station appearing on early planar imaging were considered to be the sentinel nodes. Nodes appearing later in the same stations were considered to be second-echelon nodes. If SPECT/CT showed additional hot spots in caudal areas or on a side with no other drainage or without previous drainage, those hot spots were also considered to be sentinel nodes. Four patients in whom planar lymphoscintigraphy had not shown lymphatic drainage were not included in this study.

Sentinel Lymphadenectomy

Patients underwent surgery 4–6 h after injection of the radiotracer. For sentinel node identification, a laparoscopic frontal γ -ray detection probe (Europrobe; Euro Medical Instruments) was used in combination with a portable γ -camera (Sentinella; Oncovision). Technical details of this portable γ -camera have

Received Nov. 8, 2010; revision accepted Feb. 7, 2011.

For correspondence contact: Renato A. Valdés Olmos, Antoni van Leeuwenhoek Hospital, Netherlands Cancer Institute, Plesmanlaan 121, Amsterdam 1066 CX, The Netherlands.

E-mail: r.valdes@nki.nl

COPYRIGHT © 2011 by the Society of Nuclear Medicine, Inc.

TABLE 1
Characteristics of Patients ($n = 55$)

Characteristic	Value
Mean age (y)	65 (range, 52–78)
Median PSA (ng/mL)	15 (range, 3.3–388)
Mean Gleason score	7.6 (range, 5–10)
T category	
T1	2 patients
T2	9 patients
T3	42 patients
T4	2 patients

been published before (6,7). A seed source (^{125}I) was placed on the tip of the collimator of the laparoscopic γ -probe. The arm of the portable γ -camera was sterile-wrapped, and the detector was placed 1–5 cm above the skin of the lower abdomen (Fig. 1). Acquisition of the $^{99\text{m}}\text{Tc}$ signal was started, and the detector was replaced if necessary to show both the injection area and the sentinel nodes, for optimal spatial orientation. Continuous imaging was performed, and every 1–3 min a new image was made to show the actual situation. The iodine source was depicted separately on the screen of the portable γ -camera, thus functioning as a pointer in the search for the nodes. After excision of each node, a new image was compared with the situation before excision (Fig. 2) (6). If focal radioactivity remained at the same location or more proximal to the prostate, it was concluded that another possible sentinel node was still in place. Not all hot nodes were removed; remaining hot spots farther from the injection area, considered second-echelon on preoperative images, were not removed. All removed nodes were examined by experienced pathologists.

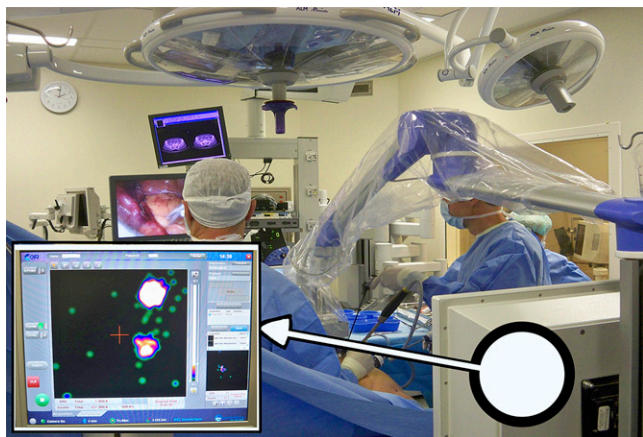


FIGURE 1. Intraoperative use of portable γ -camera. Camera is positioned at patient's head, with sterile wrapped detector above pelvic area. γ -probe and other surgical instruments are introduced through laparoscopic ports. Two screens caudal to patient show view from laparoscopic camera and preoperative SPECT/CT. On screen of portable γ -camera, cranial to patient, radioactivity within surgical field is displayed (inlay). Detector can be moved to display injection area or nodes on 1 side of pelvis selectively. Tip of laparoscopic probe (^{125}I -seed) is seen as green circle, which moves on screen as probe is moved in search of sentinel node.

Data Collection and Analysis

We evaluated whether, and how many, sentinel nodes were visualized intraoperatively. For several factors, a possible correlation with intraoperative sentinel node detection was analyzed (Pearson correlation and Student t test; SPSS software [SPSS Inc.] for Windows [Microsoft]). These factors included preoperative detection on planar images and SPECT/CT, age, learning curve, tracer dosage, previous treatment, N-stage (node positivity on pathologic examination), PSA, Gleason sum score, and T-stage. Learning curve was defined by numbering each case in consecutive order.

Intraoperative visualization was compared with preoperative conventional planar images and SPECT/CT. A score was assigned to indicate whether the pointer was used for localization of the sentinel nodes and whether extra nodes were excised because of the images obtained after excision of each node. Data on the visualized versus not visualized nodes were compared with analysis predictors of intraoperative nonvisualization (Student t test and χ^2 analysis; SPSS software for Windows).

RESULTS

Reproducibility of Preoperative Images

A total of 8 nodes of 142 (6%) visualized on planar images could not be detected intraoperatively, whereas for SPECT/CT this number was 29 of 178 (16%). Sixteen nodes seen on SPECT/CT could not be seen intraoperatively because they were too weak, and 13 because they were near the prostate. In these latter patients, the prostate injection area overshadowed the activity within the nodes.

Factors That Influence Intraoperative Visualization

Factors that were correlated with the number of sentinel nodes detected intraoperatively with the portable γ -camera are presented in Table 2. Expectedly, preoperative detection of sentinel nodes on planar images and SPECT/CT was a strong predictor for intraoperative detection of sentinel nodes with the portable γ -camera. Higher Gleason sum score correlated positively with the number of nodes detected with the portable γ -camera. Patients with a Gleason sum score of 7 or less showed a mean of 2.5 sentinel nodes on intraoperative images, whereas in patients with a Gleason sum score above 7 a mean of 3.5 sentinel nodes was depicted with the portable γ -camera (Student t test, $P = 0.007$). Other tumor characteristics (PSA, T-stage, and N-stage) did not correlate with the number of sentinel nodes found during operation.

The location of a preoperatively defined sentinel node appeared to be an important determinant of whether it could also be seen intraoperatively. All preoperatively detected paraortic sentinel nodes were clearly visualized on the screen of the portable γ -camera, whereas pelvic nodes along the external and internal iliac vessels could not be seen in 15% of the patients (Table 2).

Extra Sentinel Nodes

Seventeen additional sentinel nodes were removed in 15 patients by monitoring after excision. In 2 cases, the additionally found sentinel node was tumor-positive, but

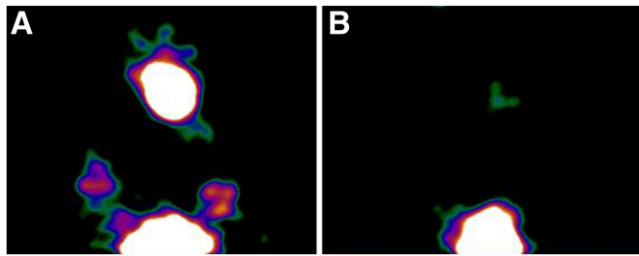


FIGURE 2. Intraoperative portable γ -camera images. (A) Image obtained before excision, with injection area (prostate) seen caudally and radioactive signal seen in sentinel nodes on both sides in obturator fossa and in active paraaortic node. (B) Image obtained after excision of each node, showing injection area and weak activity in paraaortic area. Image confirms adequate excision of sentinel nodes.

in both cases a previously excised sentinel node had also been found to be positive.

Localization of Sentinel Nodes

The iodine seed pointer was useful to localize a sentinel node intraoperatively in 15 patients (27%), because localization with the γ -probe only was not successful. In these patients the sentinel nodes were identified on preoperative images but were difficult to localize intraoperatively. One node was localized close to the prostate, and even after localization no separate signal could be depicted with the γ -probe because of overprojection by the prostate injection area. Excision of this node was based purely on localization information provided by the seed pointer. Nodes localized with the seed pointer were tumor-bearing in 3 patients; in 2 patients these were the only tumor-positive nodes.

Pathology and Postoperative Regimen

Forty percent of the patients had one or more positive nodes. These patients were offered 3 y of hormonal treatment instead of only 6 mo. Node-positive patients furthermore received external-beam radiation therapy to the prostate (70 Gy) and pelvic area (50 Gy), instead of only prostate irradiation (78 Gy).

DISCUSSION

Our results show that intraoperative imaging of sentinel nodes with a portable γ -camera leads to excision of more sentinel nodes. We were, however, not able to demonstrate an effect on upstaging and therapeutic regimen, because none of the extra found nodes were the only tumor-positive ones. The use of a pointer on the screen of the intraoperative γ -camera simplifies sentinel node localization, particularly if the nodes cannot easily be localized with the probe. Intraoperative imaging cannot replace preoperative images, however. Sequential conventional planar images after tracer injection show successive steps of lymphatic drainage and thus enable sentinel nodes to be distinguished from nodes farther downstream. Furthermore, intraoperative images cannot provide adequate anatomic information on the structures surrounding the sentinel node.

In our population, all patients received preoperative SPECT/CT. This facilitates intraoperative tracing of the sentinel nodes, because the location of the nodes is known beforehand (4). Intraoperative localization by means of the γ -probe only may be challenging in patients with a high body mass index. The use of an on-screen pointer can then be useful for guiding localization. If SPECT/CT is not

TABLE 2
Factors Influencing Intraoperative Sentinel Node Detection

Parameter	Significant factors	Nonsignificant factors
Number of sentinel nodes visualized intraoperatively	Number of sentinel nodes on planar images ($P < 0.001$)* Number of sentinel nodes on SPECT/CT ($P < 0.001$)* Gleason sum score ($P = 0.03$)*	Age* Learning curve* Tracer dosage* Previous treatment† N-stage [‡] (node positivity on pathologic examination) PSA* T-stage*
Detection of preoperatively identified sentinel nodes (SPECT/CT)	Detection on planar images ($P < 0.001$)‡ Location of sentinel node ($P < 0.001$)¶ Pelvic (obturator fossa): 85% detected Paraaortic and common iliac [§] : 100% detected Inguinal: 64% detected Presacral: 75% detected	Age† Learning curve† Tracer dosage† Previous treatment‡ Presence of tumor in node¶ Tumor characteristics (T-stage‡, Gleason sum score†, PSA‡)

*Pearson correlation.
†Student *t* test.
‡ χ^2 .
¶Fisher exact test.
§All sentinel nodes cranial to crossing of ureter over common iliac artery.

available, the use of this pointer will be even more valuable and the number of additional sentinel nodes detected intraoperatively will be much higher.

Nodes farther from the prostate injection area are better reproduced than inguinal and presacral nodes. Overprojection can cause difficulty in visualizing these latter nodes intraoperatively. Interestingly, patients with high Gleason scores showed more sentinel nodes intraoperatively. An explanation might be that less differentiated, more advanced tumors lead to more distinct and visible lymphatic drainage. This phenomenon has not been described before, however, and other tumor characteristics such as PSA, T-stage, and nodal involvement did not significantly correlate with intraoperative visualization of more sentinel nodes.

The portable γ -camera can display the distribution of remaining activity after excision of parailiac and paraaortic nodes. Its use besides the γ -probe appears valuable in providing certainty on whether sentinel nodes have been adequately removed. Removing extra nodes that probably receive direct lymph drainage from the tumor ought to be outweighed by the fact that operation time is elongated. Additional draining time might be another reason for visualization of more hot nodes intraoperatively. The second echelon, farther downstream, may more clearly be visualized, but these need not be removed in view of sentinel node mapping.

To our knowledge, intraoperative imaging of prostate sentinel nodes has not been reported in the literature, apart from our previously mentioned pilot experience (6). Its application has, however, recently been evaluated in cervical cancer, using a similar approach (11). The authors of that study concluded that intraoperative real-time images provide high detection rates in cases of difficult sentinel node localization (11). Reports of intraoperative imaging of sentinel nodes in breast cancer and head and neck tumors have also shown favorable results (8–13). In prostate cancer, many direct draining nodes have been reported to be localized outside the obturator fossa (2,12) and even outside the area of extended pelvic lymphadenectomy (4). Because these sentinel nodes can be exclusive tumor-positive nodes, intraoperative harvesting is important for accurate staging.

CONCLUSION

Intraoperative sentinel node imaging leads to excision of more radioactive nodes and can be used to evaluate remaining

radioactivity after sentinel node excision in prostate cancer. SPECT/CT visualizes more sentinel nodes, because weak nodes and nodes near the injection area cannot always be depicted with a portable γ -camera. The intraoperative use of a radioactive source as a pointer facilitates identification of nodes in difficult locations.

DISCLOSURE STATEMENT

The costs of publication of this article were defrayed in part by the payment of page charges. Therefore, and solely to indicate this fact, this article is hereby marked “advertisement” in accordance with 18 USC section 1734.

REFERENCES

1. Holl G, Dorn R, Wengenmair H, Weckermann D, Sciuk J. Validation of sentinel lymph node dissection in prostate cancer: experience in more than 2,000 patients. *Eur J Nucl Med Mol Imaging*. 2009;36:1377–1382.
2. Meinhardt W, Valdes Olmos RA, van der Poel HG, Bex A, Horenblas S. Laparoscopic sentinel node dissection for prostate carcinoma: technical and anatomical observations. *BJU Int*. 2008;102:714–717.
3. Jeschke S, Beri A, Grüll M, et al. Laparoscopic radioisotope-guided sentinel lymph node dissection in staging of prostate cancer. *Eur Urol*. 2008;53:126–132.
4. Vermeeren L, Valdés Olmos RA, Meinhardt W, et al. Value of SPECT/CT for detection and anatomic localization of sentinel nodes before laparoscopic sentinel node lymphadenectomy in prostate carcinoma. *Eur J Nucl Med Mol Imaging*. 2009;36:1029–1036.
5. Warncke SH, Mattei A, Fuechsel FG, Z’Brun S, Krause T, Studer UE. Detection rate and operating time required for gamma probe-guided sentinel lymph node resection after injection of technetium-99m nanocolloid into the prostate with and without preoperative imaging. *Eur Urol*. 2007;52:126–132.
6. Vermeeren L, Valdés Olmos RA, Meinhardt W, et al. Intraoperative radioguidance with a portable gamma camera: a novel technique for laparoscopic sentinel node localization in urological malignancies. *Eur J Nucl Med Mol Imaging*. 2009;36:1029–1036.
7. Sanchez F, Fernandez MM, Gimenez M, et al. Performance tests of two portable mini gamma cameras for medical applications. *Med Phys*. 2006;33:4210–4220.
8. Motomura K, Noguchi A, Hashizume T, et al. Usefulness of a solid-state gamma camera for sentinel node identification in patients with breast cancer. *J Surg Oncol*. 2005;89:12–17.
9. Mathelin C, Salvador S, Bekaert V, et al. A new intraoperative gamma camera for the sentinel lymph node procedure in breast cancer. *Anticancer Res*. 2008;28:2859–2864.
10. Tsuchimochi M, Hayama K, Oda T, Togashi M, Sakahara H. Evaluation of the efficacy of a small CdTe gamma-camera for sentinel lymph node biopsy. *J Nucl Med*. 2008;49:956–962.
11. Vidal-Sicart S, Paredes P, Zanon G, et al. Added value of intraoperative real-time images in searches for difficult-to-locate sentinel nodes. *J Nucl Med*. 2010;51:1219–1225.
12. Scopinaro F, Tofani A, di Santo G, et al. High-resolution, hand-held camera for sentinel-node detection. *Cancer Biother Radiopharm*. 2008;23:43–52.
13. Vermeeren L, Valdés Olmos RA, Klop WMC, Balm AJM, van den Brekel MWM. A portable gamma-camera for intraoperative detection of sentinel nodes in the head and neck region. *J Nucl Med*. 2010;51:700–703.