

# Neuroblastoma: A Disease Requiring a Multitude of Imaging Studies\*

Brian H. Kushner, MD

Department of Pediatrics, Memorial Sloan-Kettering Cancer Center, New York, New York

Neuroblastoma stands out among pediatric solid tumors because of its relative frequency, intriguing natural history, prognostic biologic features, and therapeutic challenges. It is the most common extracranial pediatric solid tumor and the most common neoplasm in infancy; >90% of the ~600 cases diagnosed annually in the United States are in children ≤5 y old. Screening programs of infants show that many cases escape detection because of spontaneous regression or maturation into benign lesions. Origin from precursors of the sympathetic nervous system accounts for (a) primary sites in adrenal glands and in paraspinal locations from neck to pelvis and (b) high urinary levels of catecholamines in >90% of cases. This embryonal neoplasm often encases vascular structures and, unlike most solid cancers, usually presents with substantial metastatic disease (bone, bone marrow, lymph nodes, liver; spread to lung or brain is rare). Hence, defining disease status requires CT (or MRI), bone scan, metaiodobenzylguanidine (MIBG) scan, bone marrow tests, and urine catecholamine measurements. The natural history is strikingly variable but is largely predictable from clinical and biologic features. The latter are critical for distinguishing low-risk (90% survival) from high-risk (~25%–30% survival) subsets, allowing identification of patients who, despite a favorable clinical profile (e.g., localized tumor), are likely to develop lethal metastatic disease, versus patients who have an ominous clinical profile (e.g., widespread disease) but are likely to survive, sometimes with little or no cytotoxic therapy.

**Key Words:** neuroblastoma; embryonal neoplasm; metaiodobenzylguanidine; pediatrics

**J Nucl Med 2004; 45:1172–1188**

**N**euroblastoma arises from precursors of the sympathetic nervous system—hence, the presence high urinary levels of catecholamines such as vanillylmandelic acid (VMA), homovanillic acid (HVA), or dopamine in >90% of cases. It is the most common extracranial solid tumor of childhood (1) and the most common neoplasm in the first

year of life (2). More than 90% of the ~600 cases diagnosed annually in the United States are in children ≤5 y old, with a peak incidence at age 2–3 y (1); many more cases escape detection because of spontaneous regression or spontaneous maturation into benign lesions (3–9).

Epidemiologic studies have failed to identify exogenous causes (10). The antioncogene or suppressor gene theory of tumorigenesis appears applicable to neuroblastoma (11). Particular attention has been focused on the short arm of chromosome 1 because chromosome 1p36 deletions are common in neuroblastoma cells and because neuroblastoma was reported in patients with constitutional abnormalities of chromosome 1p36 (12). Recent studies, however, favor chromosome 16p12-13 as a more likely predisposition locus (13). The synchronous occurrence of neuroblastoma and other neurocristopathies (entities of neural crest origin), such as Hirschsprung disease (aganglionic colon) (14), are intriguing with regard to a possible common genetic origin, but rarity and absence of shared genetic defects point to random associations. In fact, neuroblastoma is not part of any developmental, congenital, or inherited syndrome, nor is it associated with any other malignancy (10).

The most common primary site is the retroperitoneum (adrenal gland more often than paraspinal ganglia); less common sites of origin are the posterior mediastinum (~20%), pelvis (<5%), and neck (<5%), while rarely no primary site is identified. Multiple primaries can occur and may reflect an inherited predisposition (11,14,15). This embryonal neoplasm often encases major blood vessels and, unlike most solid cancers, usually presents with substantial metastatic disease. About 60% of patients have metastases in cortical bone, bone marrow, lymph nodes, and liver (16), but spread to lung (17) or brain (18) is rare despite hematogenous dissemination (19). These clinical characteristics make assessment of disease status dependent on a multitude of studies: CT (or MRI), <sup>99m</sup>Tc-methylene diphosphonate (<sup>99m</sup>Tc-MDP) bone scan, <sup>131</sup>I- or <sup>123</sup>I-metaiodobenzylguanidine (<sup>131</sup>I- or <sup>123</sup>I-MIBG) scintigraphy, bilateral bone marrow histochemical examinations, and urine catecholamine levels. Carrying out this complex battery of tests in the young children who comprise the large majority of neuroblastoma patients can be a daunting ordeal for medical staff, family, and patient.

Received Jan. 13, 2004; revision accepted Apr. 23, 2004.

For correspondence contact: Brian H. Kushner, MD, Department of Pediatrics, Memorial Sloan-Kettering Cancer Center, 1275 York Ave., New York, NY 10021.

Email: kushnerb@mskcc.org

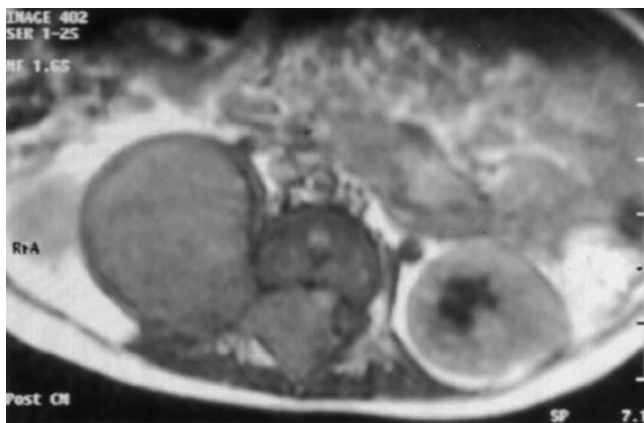
\*NOTE: FOR CE CREDIT, YOU CAN ACCESS THIS ACTIVITY THROUGH THE SNM WEB SITE ([http://www.snm.org/ce\\_online](http://www.snm.org/ce_online)) THROUGH JULY 2005.

The natural history of neuroblastoma is highly variable but is usually predictable from clinical and biologic prognostic markers (20). The latter are critical for distinguishing low-risk from high-risk forms of neuroblastoma, allowing identification of patients who, despite a favorable clinical profile (e.g., localized tumor), are likely to develop lethal metastatic disease, versus patients who have an ominous clinical profile (e.g., widespread disease) but are likely to survive.

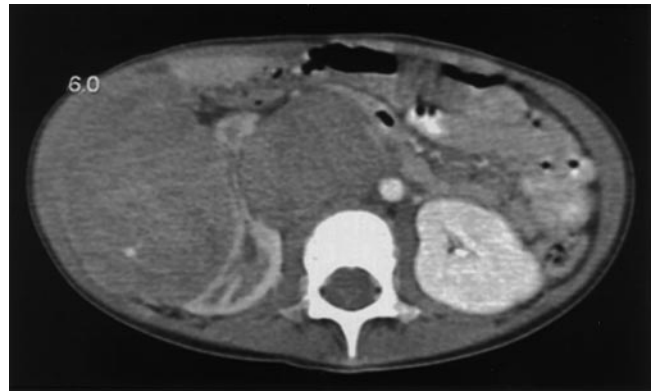
### CLINICAL PRESENTATION

Neuroblastoma is diagnosed by (a) characteristic histopathologic findings—that is, neural or ganglionic features; or (b) tumor-cell clumps or syncytia in bone marrow, plus high urinary levels of one or more catecholamines (21). Patients usually present with symptoms and signs attributable to local effects of primary or metastatic tumor. Paraspinal neuroblastomas tend to extend through intervertebral foramina (“dumbbell” tumors), endangering the spinal cord (Fig. 1) (22). Large abdominal or pelvic neuroblastomas may compress kidney, causing renin-associated hypertension (Fig. 2). Cervical or apical thoracic masses result in Horner’s syndrome (Fig. 3) (23). Infants often come to medical attention due to abdominal distention from extensive liver involvement (Figs. 4 and 5), less often due to subcutaneous tumor nodules, which are rare in older patients (16). Ecchymotic orbital proptosis (“raccoon eyes”) results from metastatic involvement of periorbital bones and soft tissue (spread to skull is common probably because cranial bones comprise a high proportion of the skeleton in young persons). Arthritic symptomatology (limping or refusal to walk) is common with long bone involvement. Pallor or anemia can result from hemorrhage within large, partially necrotic tumors.

Unsuspected neuroblastomas may be detected during routine physical examination, when imaging studies are performed for other reasons (for example, antenatal ultrasonog-

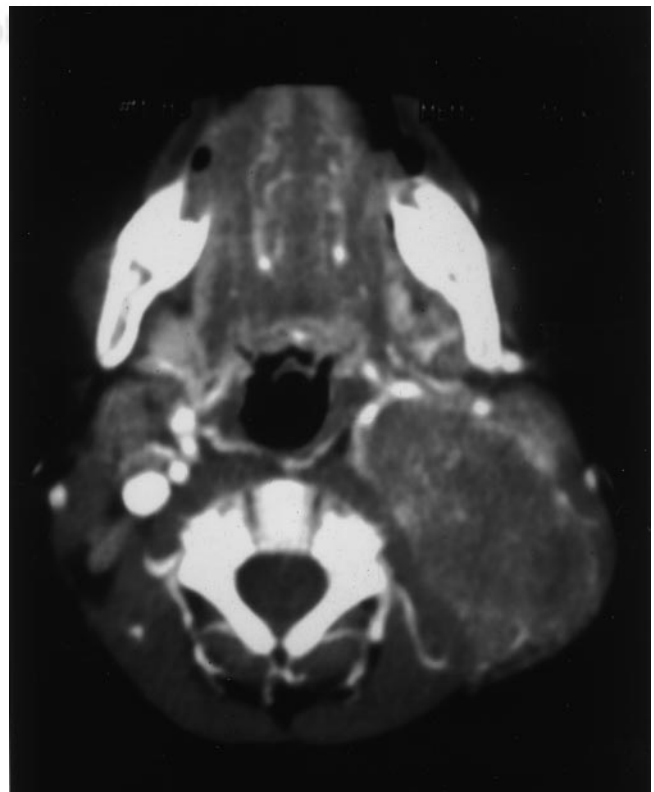


**FIGURE 1.** MRI of large-stage 2A paraspinal neuroblastoma with epidural extension (“dumbbell”) causing paraplegia in infant. Paraparesis was still present 34 mo after partial tumor resection.

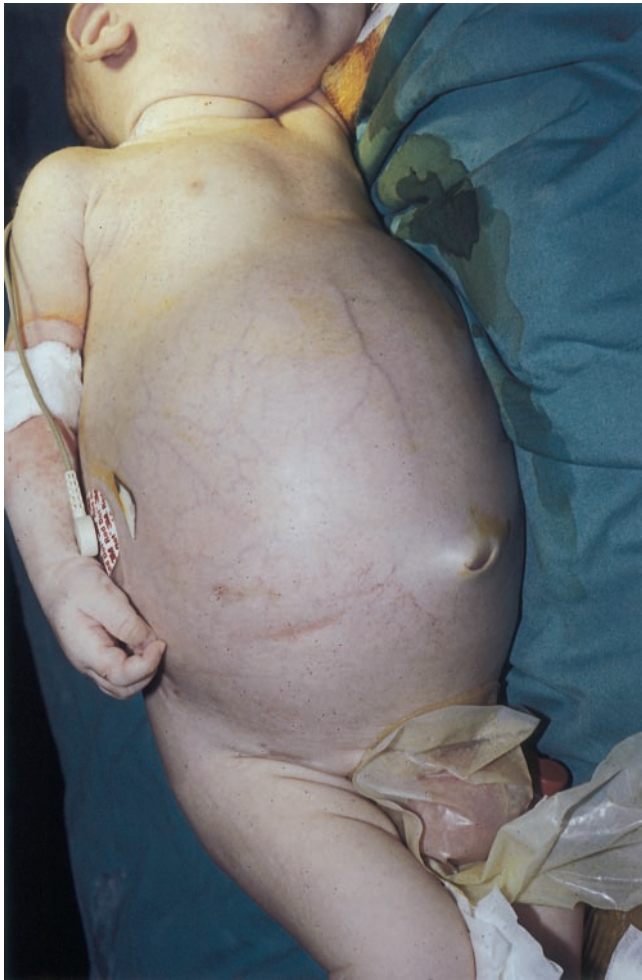

**FIGURE 2.** CT image of abdominal neuroblastoma compressing right kidney in nearly 3-y-old child who presented with convulsion from malignant hypertension. Patient is in remission from stage 4 disease 28+ mo later.

raphy (24) or radiography for suspected pneumonia) or in screening programs checking urine VMA and HVA levels in infants (4,5,7–9). These incidentally discovered neuroblastomas are usually prognostically favorable forms, as are those in the small subset of patients (~2%) who present with paraneoplastic syndromes—that is, clinical findings not directly resulting from mass effect. These “remote effects” include watery diarrhea and opsoclonus-myoclonus-



**FIGURE 3.** CT image of cervical neuroblastoma causing Horner’s syndrome. Tumor was only partially resected to avoid damage to brachial plexus. Residual tumor spontaneously regressed but Horner’s syndrome was still present 8+ y later.



**FIGURE 4.** One-month-old child with life-threatening abdominal distension from massive liver involvement (stage 4S). Patient was treated with 1 cycle of chemotherapy and is disease-free 7+ y later.

ataxia syndrome. The diarrheal problem, which mimics intestinal malabsorption disease, results from vasoactive intestinal peptide production by tumor cells and resolves after complete tumor removal (25). The encephalopathic symptoms are nonspecific (26) and are thought to result from an autoimmune response to the neuroblastoma (27). The neurologic deficits may actually develop after tumor resection and long-term developmental problems affect >50% of these patients (28).

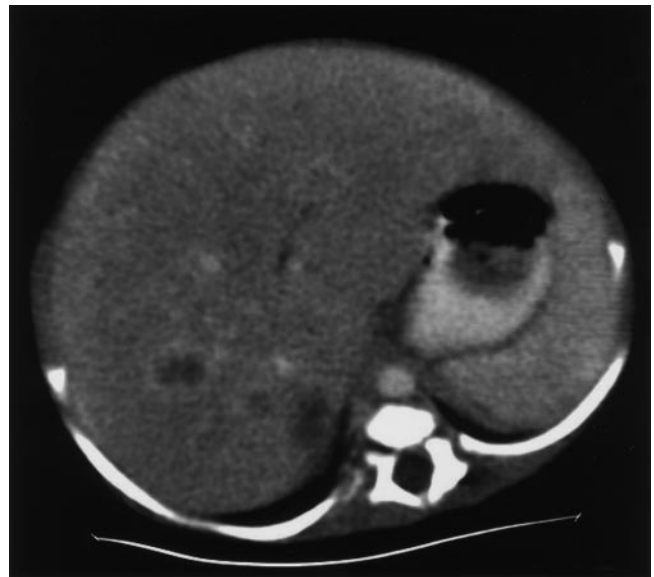
#### CLINICAL STAGING

The clinical factors of age and stage (extent of the primary tumor, sites of distant disease) are long-established independent prognostic indicators for neuroblastoma: in infants, localized and widespread forms are highly curable (3,29–32); in children 2–5 y old, who comprise the largest subset of patients, localized forms are highly curable (29,30,33) but metastatic spread heralds a lethal outcome (34–37); and in older patients, especially adolescents and

adults, the prognosis with both localized and metastatic forms is poor, although the clinical course may be protracted (38,39).

As with other cancers, a formal system for clinical staging of neuroblastoma is useful for prognostication and for comparing results of treatments. The International Neuroblastoma Staging System (INSS) uses clinical patterns of disease, as determined by radiographic and scintigraphic studies, surgical findings, and bone marrow status (Table 1) (21). Localized tumors are divided into stages 1, 2, and 3, based on regional lymph node status and whether the tumor infiltrates across the midline or is resectable. All patients diagnosed at  $\geq 12$  mo of age with neuroblastoma in distant sites have stage 4. Widespread disease in infants is divided into 2 categories, stage 4 and stage 4S (“special”), with the latter defined by a small (stage 1 or stage 2) primary tumor, a rarity (<10%) of tumor cells in bone marrow, and no distant osseous metastases.

Adverse clinical prognostic factors include osseous metastases, substantial involvement of bone marrow in infants, and any degree of distant bone marrow invasion in older patients. Clinical findings of less certain prognostic import include tumor resectability and regional or distant lymph node involvement. Infiltration across the midline (currently defined as the contralateral end of vertebral bodies (21)) is often considered synonymous with a large, locally invasive tumor that encases or entraps vital structures and is not resectable. This situation most typically occurs with retroperitoneal neuroblastomas and major blood vessels, including the aorta, the inferior vena cava, renal arteries and veins, the celiac axis, and the superior mesenteric artery (Figs. 2 and 6). Some tumors, however, displace rather than encase



**FIGURE 5.** CT of neonate showing diffuse infiltration of liver with multiple focal low-density lesions treated emergently with radiotherapy (400 cGy). A small right adrenal mass spontaneously resolved and patient is well at age 49 mo.

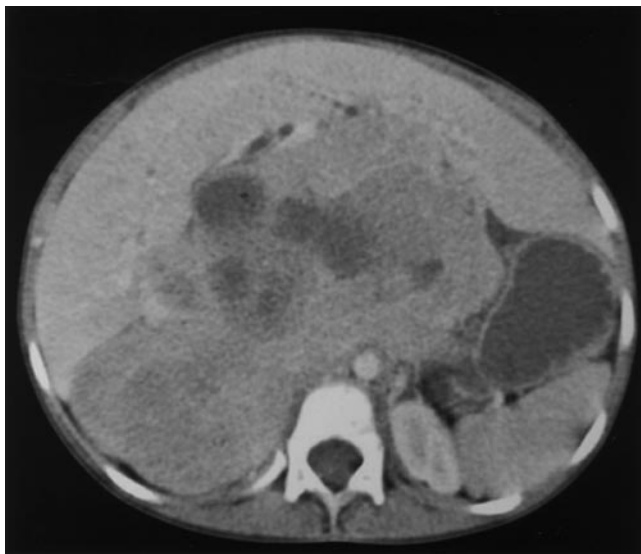


**TABLE 1**  
International Neuroblastoma Staging System

Stage	Description
1	Localized tumor with complete gross excision, with or without microscopic residual disease; representative regional lymph nodes negative for disease (nodes attached to and removed with primary tumor may be positive).
2A	Localized tumor with incomplete gross excision; identifiable ipsilateral and contralateral lymph nodes negative microscopically.
2B	Localized tumor with complete or incomplete gross excision; ipsilateral regional lymph nodes positive for tumor. Contralateral lymph nodes negative microscopically.
3	Unresectable tumor infiltrating across midline with or without regional lymph node involvement or localized tumor with contralateral regional lymph node involvement; or midline tumor with bilateral extension by infiltration (unresectable) or by lymph node involvement.
4	Any primary tumor with dissemination to distant lymph nodes, cortical bone, bone marrow, liver, or other organs (except as defined in stage 4S).
4S	Localized primary tumor as defined for stage 1 or stage 2 with dissemination limited to liver, skin, or bone marrow. Only applies to infants <1 y old.

Data are from (21).

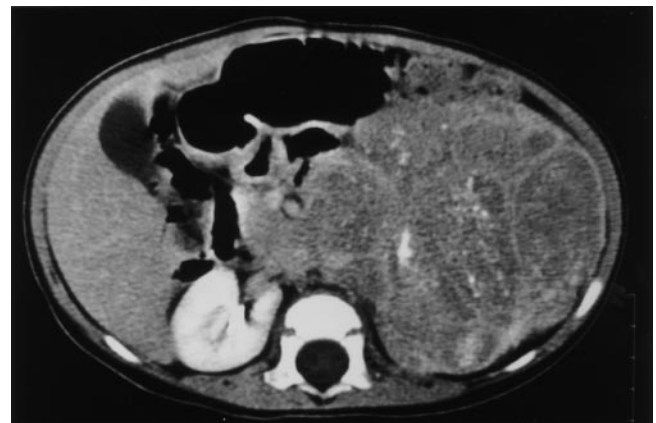
major blood vessels—a clinical finding that may supercede extension across the midline (a defining feature of stage 3) as a critical factor regarding resectability (Fig. 7). Resectability is also problematic when tumors invade the spinal canal, upper thoracic tumors encase carotid vessels, cervical tumors entrap the brachial plexus, and pelvic tumors surround ureters and major nerve roots. Two thirds of localized neuroblastomas involve regional lymph nodes. The INSS distinguishes between involved lymph nodes adherent to and surgically removed with the primary tumor (stage 1) versus involved regional lymph nodes that are apart from the primary tumor (stage 2B or stage 3).



**FIGURE 6.** CT image of enormous abdominal mass in 5 y old with stage 4 neuroblastoma. Tumor shrank with chemotherapy and was successfully resected. Patient is in complete remission 16+ mo later.

### BIOLOGIC PROGNOSTIC FACTORS

Neuroblastoma is associated with numerous biologic findings that correlate with outcome (Table 2) (20,40). The independent prognostic significance of most of these findings is uncertain because they occur together and actually help to define specific subsets of patients. These subsets have markedly divergent natural histories (Table 3): The preponderance of cases have either a propensity for spontaneous resolution at one extreme (type 1) or a lethal resistance to treatment at the other (type 3) (20). Further, screening programs of infants provide convincing evidence that biologically favorable neuroblastomas rarely, if ever, evolve into lethal, biologically unfavorable metastatic forms (4,5,7–9).



**FIGURE 7.** CT image of large abdominal neuroblastoma in 13-mo-old child. Mass crossed midline and encased major blood vessels—findings typical for high-risk neuroblastoma. However, mass (and regional lymph nodes) proved to be resectable, making this stage 2B, as previously described (29). Patient remains well 9+ y later without having received any cytotoxic therapy.

**TABLE 2**  
Selected Biologic Prognostic Factors

Biologic parameter	Adverse finding
Tumor cell features	
<i>MYCN</i> oncogene	>10 copies
Chromosome 17q	Gain
Chromosome 1p36	Loss of heterozygosity
Chromosome 11q14-22	Loss of heterozygosity
Chromosomal ploidy	Near diploid or near tetraploid
<i>trkA</i>	Absent or low expression
<i>trkB</i>	High expression
<i>trkC</i>	Absent or low expression
Telomerase	Increased activity or high expression
CD44	Low expression
Shimada histopathology	Unfavorable by Shimada criteria
Biochemical marker	
Serum lactate dehydrogenase	>1,500 U/L
Serum neuron-specific enolase	>100 ng/mL
Serum ferritin	>142 ng/mL
Urine VMA:HVA ratio	<1

Data are from (20,40).

Chromosomal features in particular have proven value for prognostication (20). Thus, the presence of >10 copies, or amplification, of the *MYCN* oncogene (found in ~20% of cases) correlates with rapidly progressive disease. A poor outlook is also seen with gain of genetic material at the 17q locus (~50% of cases) and allelic loss at 1p36 (~35% of cases) and at 11q14-22 (~40% of cases). Chromosomal hyperdiploidy is predictive of a favorable outcome for infants regardless of stage, and results from whole chromosome gains. In contrast, hyperdiploidy has no prognostic

import in advanced-stage disease in patients beyond 2 y of age, probably because the tumors also have chromosomal structural rearrangements. The basis for the relationship between chromosomal abnormalities and tumor-cell behavior awaits elucidation.

Histologic variability of neuroblastomas, ranging from small round blue cells with no neural features to large ganglionic cells, has long spurred efforts at defining prognostic correlates. The International Neuroblastoma Pathology System (41) (adopted from the histopathologic classification system of Shimada) provides a valuable prognostic system using age and histologic features such as nuclear morphology (aggressive tumors have a high mitotic or karyorrhexis index).

Prognosis correlates with the presence on neuroblasts of the Trk family of tyrosine kinases (20). These cell surface molecules mediate neuronal cell survival or senescence, growth, and differentiation. High expression of *trkA* and *trkC* is characteristic of favorable subsets of neuroblastoma. Laboratory studies suggest that activation of *trkA* when its ligand, nerve growth factor, is present in the tumor micro-environment leads to differentiation or maturation (which may explain ganglioneuroma in patients), whereas the absence of nerve growth factor, or inhibition of the *trkA* receptor, leads to apoptosis (a possible pathway for spontaneous regression in patients). High expression of *trkB* and its ligand, brain-derived neurotrophic factor, is seen with unfavorable neuroblastoma and points to a possible autocrine or paracrine loop as a contributing factor to a survival or proliferative advantage.

Other cellular features of high-risk neuroblastoma include expression of telomerase, which is a reverse transcriptase involved in preventing chromosomal degeneration and, hence, in promoting cell survival; and low expression of CD44, which is a surface molecule that is, in contrast, associated with metastasis in other neoplasms (20).

**TABLE 3**  
Biologic and Clinical Subtypes of Neuroblastoma

Feature	Type 1	Type 2	Type 3
<i>MYCN</i> oncogene	Normal	Normal	Amplified (>10 copies)
DNA ploidy	Hyperdiploid or near triploid	Near diploid or near tetraploid	Near diploid or near tetraploid
Chromosome 17q gain	Rare	Common	Common
Chromosome 1p LOH	Rare	±Present	Common
Chromosome 11q LOH	Rare	Common	Rare
<i>trkA</i> expression	High	Low or absent	Low or absent
<i>trkB</i> expression	Truncated	Low or absent	High (full length)
<i>trkC</i> expression	High	Low or absent	Low or absent
Age (y)	Usually <1	Usually ≥1	Usually 1-5
Stage	Usually 1, 2, 4S	Usually 3, 4	Usually 3, 4
5-y survival (%)	95	40-50	25

LOH = loss of heterozygosity.  
Data are from (20).

Biochemical findings associated with an adverse prognosis (Table 2) (40) include high serum levels of lactate dehydrogenase (a marker for *MYCN*-amplified and rapidly proliferating disease), neuron-specific enolase, and ferritin. Pretreatment urine levels of catecholamines are not predictive of outcome, but low VMA and high HVA excretion is associated with short survival, whereas localized tumors usually have a VMA-to-HVA ratio of >1. Since HVA is an early metabolite of the catecholamine pathway, this finding suggests that biochemically primitive neuroblastomas are more aggressive.

## TREATMENT

Neuroblastoma patients are grouped into low-, intermediate-, and high-risk categories for treatment stratification purposes. The International Neuroblastoma Risk Grouping system is based on age, stage, and selected biologic features (*MYCN*, DNA index [chromosomal ploidy], histopathology) (Table 4) (20). Recent efforts to reduce treatment in low- and intermediate-risk cases contrasts with an emphasis on increasing chemotherapy dose intensity for high-risk cases. The International Neuroblastoma Response Criteria (Table 5) have been widely adopted to standardize assessment of treatment results but do not include highly sensitive immunocytologic or molecular biologic (reverse transcriptase polymerase chain reaction [RT-PCR]) techniques that detect minimal residual disease in blood or bone marrow (19,42,43).

## Screening

Early detection is the obvious preferred “treatment” approach to cancer and was the basis for the implementation of urine catecholamine screening programs in infants aimed at detecting neuroblastoma in a prognostically favorable clinical setting—that is, young age and low stage. Salient findings in screening programs performed in Japan (4,5), Quebec (7), Germany (8), and Austria (9) included neuroblastomas detected via screening were non-stage 4 with favorable biology; the prevalence of neuroblastoma was at least 50% greater than in unscreened populations; the prevalence of high-risk cases (e.g., *MYCN*-amplified disease, stage 4 disease beyond the first year of life) was not diminished by screening; and the mortality from neuroblastoma in patients >1 y old was not significantly improved. The major conclusions were that favorable and unfavorable subtypes are distinct entities and that many cases escape detection in unscreened populations via spontaneous resolution or maturation into asymptomatic ganglioneuroma.

## Low-Risk and Intermediate-Risk Disease

Biologically favorable localized neuroblastoma is highly curable (survival rates, >90%) in infants and children, with resection alone sufficient for stage 1 (30), complete or partial resection usually sufficient for stage 2 (Figs. 3, 7, and 8) (29,30), and modest doses of chemotherapy effective in stage 3 tumors (33). High survival rates are also seen in infants with non-*MYCN*-amplified widespread disease, including stage 4S (3,31), which is marked by a high rate of

**TABLE 4**  
Treatment Risk Stratification for Neuroblastoma

INSS stage	Age (y)	<i>MYCN</i>	Shimada histology	DNA index
Low-risk (survival >90% with surgery alone)				
1	0–21	Any	Any	Any
2A/2B	0–<1	Any	Any	Any
2A/2B	1–18	NA	Any	Any
4S	0–<1	NA	Favorable	>1
Intermediate-risk (survival >90% with surgery, chemotherapy)				
Favorable Biology				
3	0–21	NA	Favorable	>1
4	0–<1	NA	Favorable	>1
Unfavorable Biology				
3	0–<1	NA	Unfavorable	or 1
4	0–<1	NA	Unfavorable	or 1
4S	0–<1	NA	Unfavorable	or 1
High-risk (survival <30% with intensive multimodality therapy)				
2A, 2B	1–21	A	and Unfavorable	Any
3	0–<1	A	Any	Any
3	1–21	A	or Unfavorable	Any
4, 4S	0–<1	A	Any	Any
4	1–21	Any	Any	Any

A = amplified (>10 copies); NA = not amplified (≤10 copies).  
Data are from (20).

**TABLE 5**  
International Neuroblastoma Response Criteria

Response	Primary tumor*	Metastatic site
CR	No tumor	No tumor, catecholamines normal
VGPR	Decreased by 90%–99%	No tumor, catecholamines normal; <sup>99m</sup> Tc-MDP improved
PR	Decreased by >50%	All measurable sites decreased by >50%; no more than 1 positive bone marrow site
MR	No new lesions; >50% decrease of any measurable lesion (primary or metastatic) with <50% decrease in any other; <25% increase in any existing lesion	
NR	No new lesions; <50% decrease but <25% increase in any existing lesion	
PD	Any new lesion; increase of any measurable lesion by >25%	

\*3-dimensional measurements by CT or MRI are required.

CR = complete remission; VGPR = very good partial response; PR = partial response; MR = mixed response; NR = no response; PD = progressive disease.

Data are from (21).

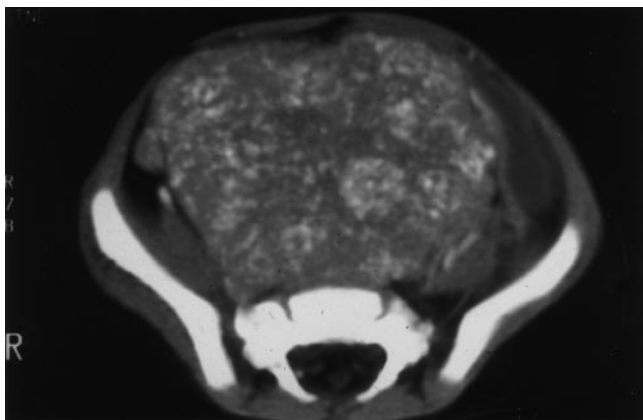
spontaneous regression, and stage 4 (32), which can manifest with substantial bone or bone marrow involvement but responds well to chemotherapy. The most commonly used agents for intermediate-risk disease are cyclophosphamide, carboplatin, etoposide, and doxorubicin. In neonates, small suprarenal masses (<5 cm) consistent with stage 1 neuroblastoma (or an adrenal hemorrhage) do not need to be biopsied; these patients can be monitored by noninvasive studies (ultrasonography, urine catecholamine levels) (24). Soft-tissue recurrences of biologically favorable non-stage 4 neuroblastoma can usually be treated again with resection and little or no chemotherapy (Fig. 9).

#### High-Risk Disease

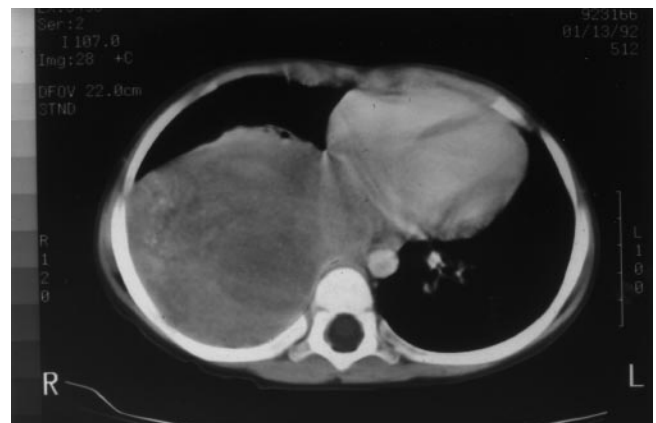High-risk neuroblastoma includes *MYCN*-amplified unresectable disease in all age groups, stage 4 regardless of biology in patients >18 mo old, and stages 2–4 in adolescents or adults. Although 12 mo of age has here-

before been a critical maker in estimating risk for stage 4, recent analyses reveal survival rates of 85%–90% with intensive multimodality therapy in children 12–18 mo of age with non-*MYCN*-amplified stage 4 (36,37). This group has traditionally been considered at high risk for treatment failure but may, in fact, benefit from a reduction of currently prescribed intensive induction and consolidation therapeutic approaches. The same holds for patients >12 mo old who are classified as stage 4 by virtue of distant lymph node involvement but have favorable biology. This informally called stage “4-N” group of patients may do as well as patients with non-*MYCN*-amplified stage 3 (Fig. 10) (44).

For patients with high-risk disease, a modest but gratifying improvement in event-free survival, which was only

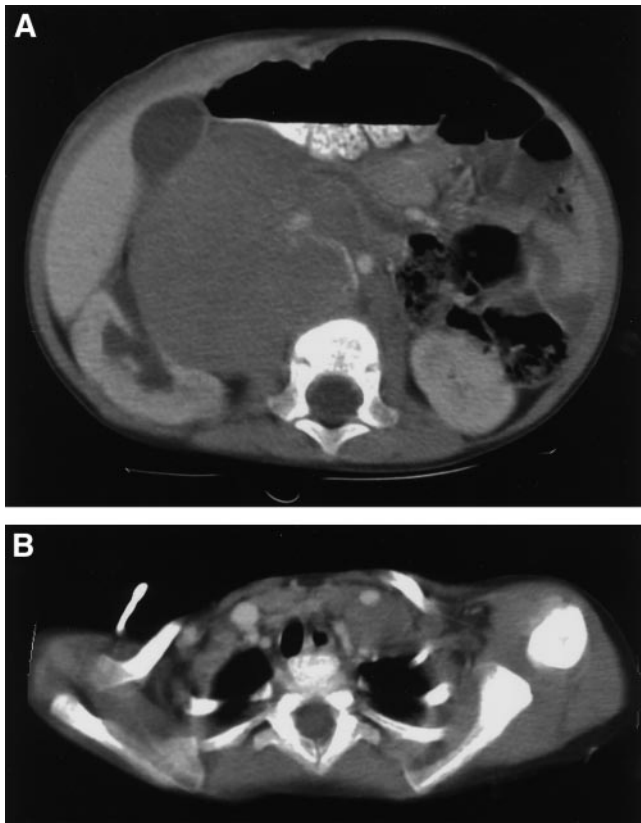


**FIGURE 8.** CT image of large pelvic neuroblastoma with regional nodal involvement (stage 2B) in 17-mo-old girl. All visible disease was resected.



**FIGURE 9.** CT image of recurrent thoracic neuroblastoma that caused respiratory distress in 3-y-old child, who in infancy had stage 4S that had spontaneously resolved. Recurrence was resected, as previously described (29). Patient is well 10+ y later without ever having received cytotoxic therapy.





**FIGURE 10.** CT image of large abdominal neuroblastoma (A) in 15-mo-old child who also had left supraclavicular tumor (B), but no involvement of cortical bone or bone marrow (stage “IV-N”). Abdominal mass was resected, biologic markers were favorable, and no cytotoxic therapy was administered. Distant disease spontaneously regressed, and child is well 4+ y later.

25%–30% in recent national studies through the mid-1990s (34,35), has resulted from increased dose intensity during induction (45,46), myeloablative consolidation (sometimes using 2 [tandem] or 3 [triple-tandem] treatments with stem-cell rescues) (34,47–49), local radiotherapy to prevent relapse in primary sites (50), improved supportive care, and addition of biologic response modifiers such as the vitamin A derivative 13-*cis*-retinoic acid (34) and monoclonal antibodies (51,52).

Induction therapy has most often included alkylating agents (cyclophosphamide, ifosfamide), platinum compounds (cisplatin, carboplatin), topoisomerase II inhibitors (etoposide, doxorubicin), and vincristine (33–35,46–48). Newer chemotherapeutic agents with antineuroblastoma activity include topoisomerase I inhibitors (topotecan, irinotecan) (53,54), which are also being combined with other agents (55–58). The most widely used myeloablative regimens have comprised various combinations of alkylators (melphalan, thiotepea, busulfan, cyclophosphamide), etoposide, and carboplatin (34,35,47–49); total body irradiation is no longer commonly included due to toxicity concerns in the young patient population, with uncertain antitumor benefit. Autologous peripheral blood stem-cell support is rou-

tine, often with “purgings” to eliminate occult tumor cells using immunologic methods (59,60) or positive selection of hematopoietic progenitors that express CD34 (47). Allografting appears to confer no benefit (59), consistent with *in vitro* studies suggesting that neuroblastoma cells lack surface markers conducive to a graft-versus-neuroblastoma effect (61).

Agents aside from traditional chemotherapy are widely used both for preventing relapse from microscopic residual disease and for treating chemoresistant disease. The differentiating agent 13-*cis*-retinoic acid was found in a randomized study to decrease the risk of relapse and subsequently became standard treatment for patients with high-risk neuroblastoma (34). Fenretinide, which may induce apoptosis, is another retinoid being evaluated in large studies (62). Immunotherapy using monoclonal antibodies that target the disialoganglioside G<sub>D2</sub> (highly expressed on neuroblastoma) and mediate tumor-cell kill by leukocytes and complement has achieved excellent results against refractory neuroblastoma in bone marrow (63,64). Other strategies to mobilize the host’s immune system for antitumor effect encompass anti-G<sub>D2</sub> antiidiotypic vaccines (65), use of tumor-cell lysates processed by dendritic cells (66,67), and injections of tumor cells genetically modified to express immunostimulatory proteins (68,69). Novel approaches targeting biologic aspects of neuroblastoma are under investigation, including angiogenesis inhibitors such as TNP-470 (70), which hold promise in view of the high vascularity of advanced-stage neuroblastoma (71), inhibitors of the *trk* family tyrosine kinases, (72) and the tyrosine kinase inhibitor STI-571, which is active against neoplasms that express c-Kit (often a feature of aggressive neuroblastomas (73)).

Targeted radiotherapy with <sup>131</sup>I-MIBG (74) or <sup>131</sup>I-labeled monoclonal antibodies (75,76) can achieve regressions of resistant neuroblastoma. <sup>131</sup>I-MIBG in particular has been extensively studied, including in single-agent pilot and dose-escalation trials, (77–80) in combination with conventional chemotherapy in prior treated and in newly diagnosed patients (81,82), and as part of myeloablative regimens for refractory disease (83–85). Myelosuppression, especially thrombocytopenia, is the dose-limiting toxicity. Hematopoietic stem cell rescue allows dosages up to 666 MBq/kg (18 mCi/kg), with extramedullary toxicity limited to hypothyroidism (78,79), and also allows double infusions of <sup>131</sup>I-MIBG. Therapy with <sup>131</sup>I-MIBG may be leukemogenic (86,87).

### NONSCINTIGRAPHIC IMAGING

The initial imaging modalities most commonly used in patients who are eventually diagnosed with neuroblastoma are chest films for suspected pneumonia, skeletal films to investigate limping, ultrasonography to assess a palpable abdominal mass, and spinal MRI for acute neurologic deficits. Chest radiographs can reveal paravertebral masses in

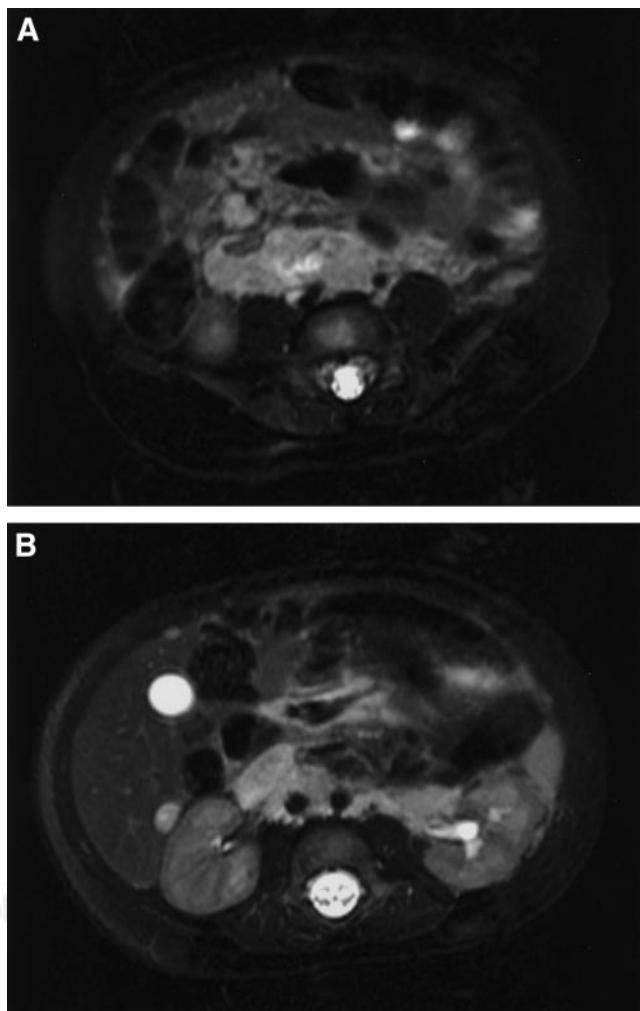


the posterior mediastinum, sometimes with calcifications or rib or vertebral body erosion. Skeletal films can identify lytic lesions. Ultrasonography can show a retroperitoneal mass in a suprarenal or paravertebral location as well as liver lesions. Spinal MRI can confirm epidural disease.

CT has long played a fundamental role in the evaluation of a patient with suspected neuroblastoma (87–90). In this setting, CT is useful for defining the extent of the primary tumor and for detecting contiguous or distant lymph node involvement—important issues regarding surgery and staging (Fig. 7). CT of the primary site and the adjacent body cavities is therefore mandatory—for example, chest, abdomen, or pelvis for an abdominal mass; abdomen, chest, or neck for a thoracic mass. In patients with suspected widespread disease, CT of cranial bones may also provide useful information. Soft-tissue calcifications evident by CT are a hallmark of newly diagnosed neuroblastic tumors, of regressing low-risk tumors, and of residual nonosseous lesions present after treatment of intermediate-risk and high-risk disease. (Calcifications are rare in nephroblastoma, which is the other common intraabdominal pediatric solid tumor.) Accurate assessment by CT of infradiaphragmatic sites of disease requires adequate contrast filling of bowel and of major blood vessels.

MRI in recent years has supplanted CT as a possibly more useful modality in the staging of neuroblastoma (91–93). MRI is as good or better than CT for visualization of anatomic details of the primary tumor, including relationships with the blood vessels (94). MRI is superior to CT for characterizing epidural extension or leptomeningeal disease (94–96); for identifying intrahepatic lesions and determining whether they are metastatic deposits or benign abnormalities; for assessing tumor invasion of kidney, liver, or other organs; for delineating abdominal masses in infants (whose lack of intraperitoneal fat can make CT inadequate) (Fig. 11); for detecting bone marrow invasion (and distinguishing it from cortical bone involvement) (97–99); and for defining the extent of cortical bone destruction (especially useful in limbs and in cranial bones). MRI is particularly helpful for evaluating an unexpected MIBG-avid focus in skeleton or soft tissue during follow-up surveillance. MRI does not require oral contrast and it lacks ionizing radiation—major advantages in young patients. Drawbacks of MRI include less-than-optimal definition of small (<13 mm) lymph nodes, false-positivity for bone marrow involvement after treatment has achieved complete remission (97–99), uncertain significance of findings in irradiated bones, and relatively long imaging time with standard technology.

MRI is better than CT for posttreatment follow-up of midline or paraspinal neuroblastomas (neck, chest, nonadrenal retroperitoneum), especially in patients with low-risk or intermediate-risk disease whose management does not routinely include radiotherapy. Ease of use (no need for sedation or contrast) and lack of radiation make ultrasonog-



**FIGURE 11.** Abdominal MRI in 3-mo-old child with unresectable retroperitoneal neuroblastoma (A) and hepatic lesions (B). Extent of disease was poorly defined using CT. All masses and bone marrow disease spontaneously regressed.

raphy the preferred modality for monitoring infants and children with low-risk abdominal or pelvic neuroblastoma posing no significant risk of epidural extension. This clinical subset, which is strongly associated with spontaneous regression, encompasses (a) small masses (<5 cm) detected incidentally and suspected of being either congenital neuroblastoma (stage 1) or adrenal hemorrhage, and for which even biopsy or resection is no longer routinely undertaken (3,4,24); (b) completely or partially resected localized tumors with favorable biology (29,30); and (c) liver lesions and the primary abdominal tumor of biologically favorable stage 4S, another subset for which resection is not needed (3). Debate continues about possible carcinogenic risks from exposure in childhood to CT-associated radiation (100). Either CT or MRI can be used for monitoring patients with high-risk disease whose treatment usually includes local radiotherapy. Definition of response requires 3-dimensional measurements for determination of changes in tumor volume.

## SCINTIGRAPHIC STUDIES

Proper staging and monitoring of patients with neuroblastoma is heavily dependent on scintigraphic studies (Table 6).  $^{99m}\text{Tc}$ -MDP scan has long been known to be superior to skeletal survey for detecting metastases in cortical bone (101,102). Imaging with  $^{131}\text{I}$ - or  $^{123}\text{I}$ -labeled MIBG has steadily gained increased usage since its development in the early 1980s, as it proved its high sensitivity and specificity for identifying metastatic involvement of cortical bone, bone marrow, and lymph nodes (103–118).  $^{111}\text{In}$ -Pentetreotide scintigraphy has been superceded by MIBG in the routine staging of neuroblastoma because of a high false negativity rate (119–121). PET using  $^{18}\text{F}$ -FDG has recently emerged as a promising modality for revealing neuroblastoma in both soft tissue and skeleton, albeit with limitations as compared with MIBG scan (122–125). Radiolabeled monoclonal antibodies reactive with neural antigens localize well to primary tumors and metastatic deposits but are investigational (76,126–129).

### $^{99m}\text{Tc}$ -MDP Scintigraphy

MDP is taken up by cells active in the metabolism of bone. Studies in the 1970s and 1980s confirmed the superior sensitivity of  $^{99m}\text{Tc}$ -MDP scans compared with conventional radiography (skeletal survey) for detecting sites of metastases in cortical bone (101,102). (Primary neuroblastomas also concentrate MDP, but this has no prognostic significance.) The role of  $^{99m}\text{Tc}$ -MDP scans, however, has diminished in recent years as its disadvantages have become more evident and its inferiority to MIBG (and PET) has been repeatedly documented (109,111,113,114,116,125,130).  $^{99m}\text{Tc}$ -MDP scans still have a role in evaluating newly diagnosed patients since other scintigraphic modalities cannot distinguish between cortical bone and bone marrow, and involvement of the former may have prognostic significance. Indeed,  $^{99m}\text{Tc}$ -MDP scans are useful at diagnosis for adding to the detection rate of cortical bone metastases

(109,113,131). Nevertheless, this imaging modality can be dispensed with in the routine follow-up of a clinically responding patient since  $^{99m}\text{Tc}$ -MDP scans in that context virtually never add to information provided by MIBG scans or urine catecholamine levels (104,111,116,130,132).  $^{99m}\text{Tc}$ -MDP scans can be problematic because of a failure to detect lesions at the ends of long bones due to the intense uptake of bone-seeking agents in the normal growth plates of children. False-positivity is common with trauma, and  $^{99m}\text{Tc}$ -MDP scans often persist in showing abnormal osseous uptake for months despite the eradication of malignant disease.

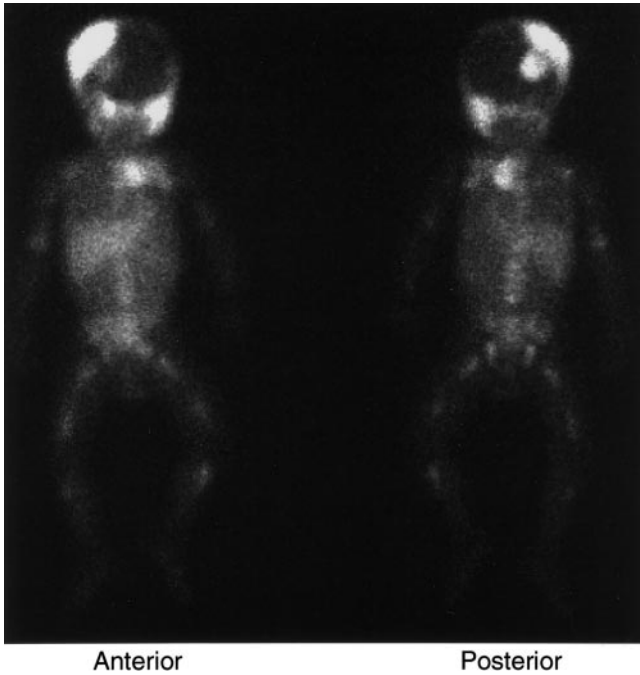
### Radioiodinated MIBG Scintigraphy

MIBG is an analog of catecholamine precursors and is therefore concentrated in neuroblastic cells (133,134). It localizes to neuroblastoma in primary sites and in bone, bone marrow, and lymph nodes in 90%–95% of patients (103–118,135) (Figs. 12–14); detection of metastases within the central nervous system is less certain (18). Advantages of  $^{123}\text{I}$ -MIBG, rather than  $^{131}\text{I}$ -MIBG, include greater sensitivity for disease detection, better image quality, 2 instead of 3 d of scanning, and less risk to the thyroid gland (136). Characterization of the normal physiologic MIBG uptake in children and SPECT imaging have helped limit misinterpretations of MIBG scans (103,137–141). Common falsely positive findings are increased radiotracer uptake in the remaining adrenal gland after an adrenalectomy (to resect neuroblastoma), physiologic uptake in intestine, and bilateral symmetric uptake in the upper chest (possibly in brown adipose tissue (141)) (Fig. 15) (138). Aside from lack of tumor-cell MIBG avidity (135), causes of falsely negative MIBG scans include nonvisualization of lesions because of intense radiotracer uptake in normal liver, myocardium, salivary glands, intestines, and thyroid (if inadequately blocked by supplemental iodine) (138).

**TABLE 6**  
Suggested Studies for Clinical Staging and Follow-Up

Patient group	Diagnostic work-up	Follow-up
Congenital localized (stage 1)	U/S or MRI,* catechols	Same, every 1–2 mo, $\times 1$ y
Non-stage 4 with favorable biology	Complete†	U/S (or MRI) and catechols at 1, 3, 6, 9, 12 mo, then every 4 mo, $\times 1$ y
Infant stage 4 without <i>MYCN</i> amplification	Complete†	MIBG, MRI, BM, and catechols every 3 mo, $\times 1$ y, then catechols every 3 mo and MIBG every 6 mo, $\times 1$ y
High-risk	Complete†	MIBG, CT or MRI, BM, and catechols every 3 mo, $\times 2$ y, then MIBG or PET, BM, and catechols every 4 mo, $\times 1$ y

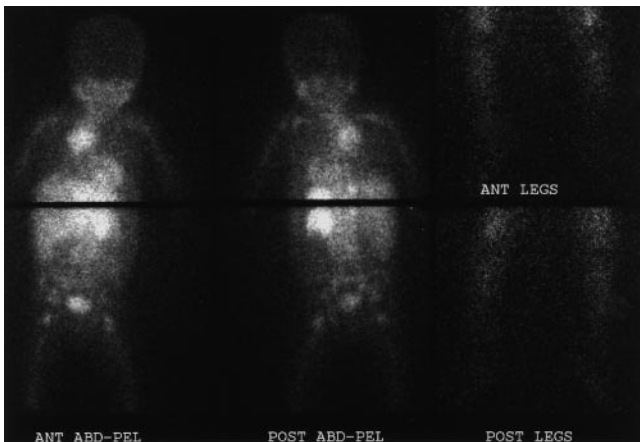
\*U/S for adrenal or pelvic mass, MRI for retroperitoneal (midline), thoracic, or cervical mass.  
† $^{99m}\text{Tc}$ -MDP bone scan (if normal in infant, need to do radiographic skeletal survey), MIBG with  $^{123}\text{I}$  (preferred) or  $^{131}\text{I}$ , CT or MRI of suspected primary site and adjacent body cavities or regions (MRI is mandatory for midline tumors to assess possible epidural extension), BM, urine catecholamine levels.  
U/S = ultrasonography; catechols = catecholamine levels in urine; BM = bone marrow aspirates and biopsies from bilateral posterior iliac crests.



**FIGURE 12.**  $^{123}\text{I}$ -MIBG image of 10-mo-old child with posterior mediastinal primary tumor, extensive bone marrow involvement, and bulky metastatic deposits in right parietal skull and left sphenoid/orbit, but no *MYCN* amplification and therefore prognosis is favorable.

MIBG scintigraphy should be performed in newly diagnosed patients for several reasons. First, MIBG findings can result in upstaging due to detection of distant disease not evident by bone marrow tests or other imaging studies. Second, determining MIBG avidity can influence the choice of follow-up evaluations. Third, the extent of MIBG uptake might have prognostic significance (142).

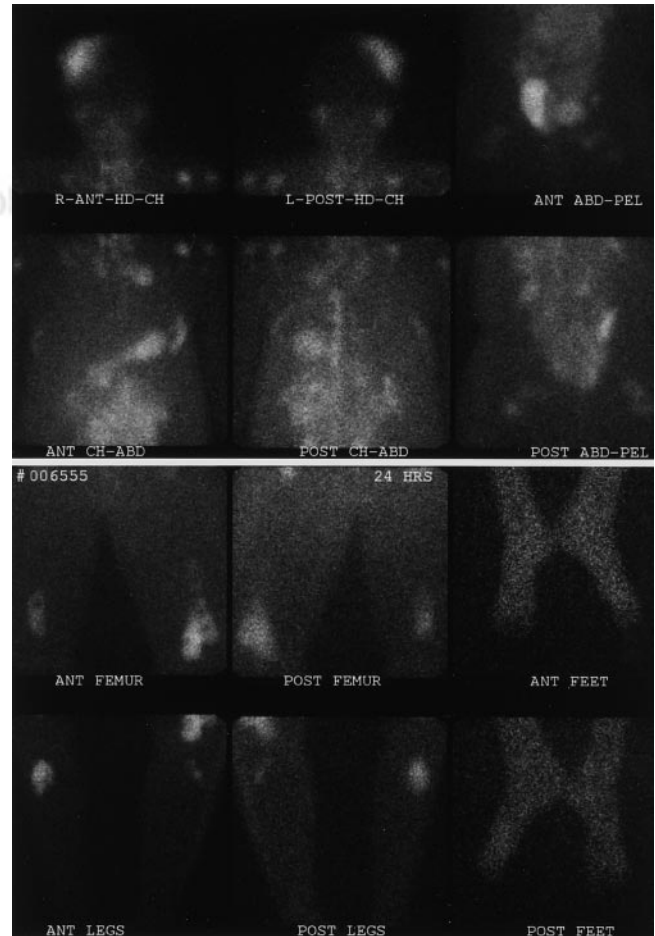
Although comprehensive reviews have noted a well-established role for MIBG scintigraphy in the staging and



**FIGURE 13.**  $^{123}\text{I}$ -MIBG image of 3-y-old child with left adrenal primary tumor, extensive bone marrow involvement, and large soft-tissue metastatic deposits in right superior mediastinum and right supraclavicular region. Patient is in remission at 30+ mo.

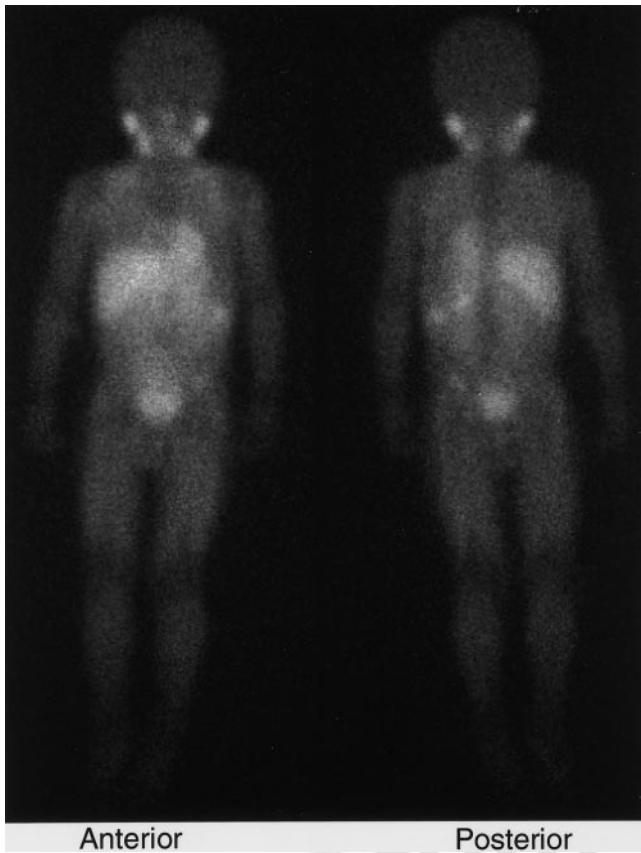
monitoring of neuroblastoma (143,144), investigations continue into defining the precise utility of routine MIBG scans in clinical management (118). For this purpose, MIBG scoring systems have been devised, based on tabulating the number and extent of MIBG-avid foci in 8–10 anatomic compartments (131,142,145–147). Results of single- or multiinstitutional experiences using these scoring systems in 27–86 stage 4 patients have differed over whether the extent of MIBG uptake at diagnosis or after 2–4 cycles of chemotherapy does (131,142,145,147) or does not (146) correlate with a good response to induction. Similarly, MIBG uptake in skeleton after induction and before myeloablative consolidation was an adverse prognostic marker in the experience of the European Bone Marrow Registry (148) and in a large French study (147) but not in some single-institutional studies (49,149).

The above reports involved retrospective reviews of series of selected patients treated in the 1980s and 1990s with standard-dose chemotherapy. Complete or very good partial remission rates of high-risk patients were <50%; most



**FIGURE 14.**  $^{123}\text{I}$ -MIBG image of newly diagnosed 13-y-old child with soft-tissue disease in neck, mediastinum, abdomen, and pelvis; bulky metastatic lesion involving cranial bones; and extensive bone marrow involvement. This adolescent achieved complete remission but later relapsed.





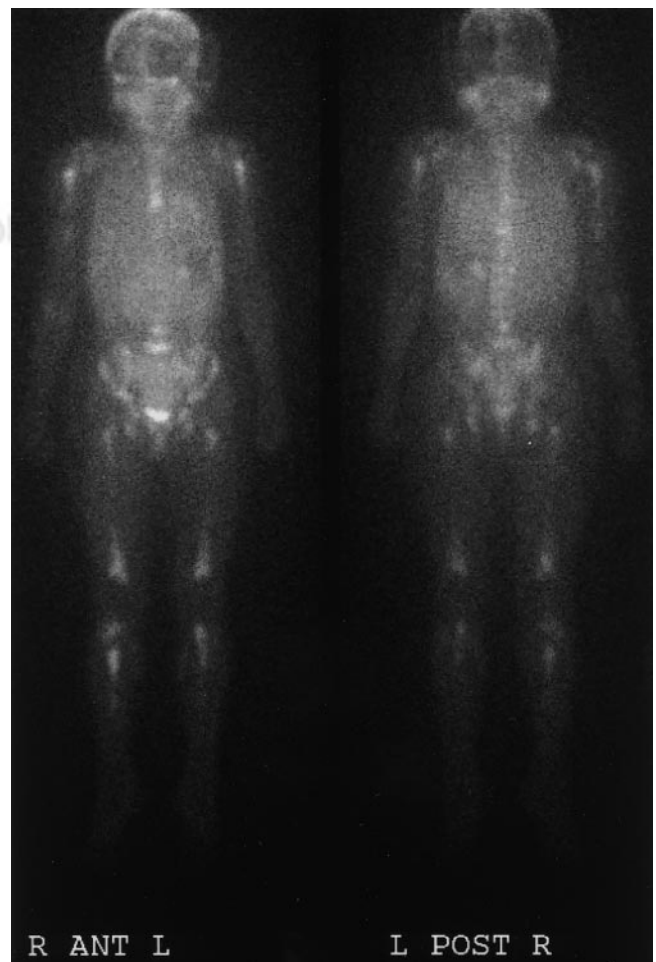
**FIGURE 15.**  $^{123}\text{I}$ -MIBG image of 3-y-old child with no definite evidence of disease but with false positivity in left adrenal gland (contralateral adrenal gland was previously resected), in bowel (over left pelvis and superior to bladder), and bilaterally in upper chest.

patients had readily detectable neuroblastoma at the end of induction and event-free survival rates were poor. MIBG findings were confirmatory of other staging evaluations in the detection of residual disease—hence, the apparent redundancy of MIBG scintigraphy. More dose-intensive induction regimens have gained widespread usage in recent years because they appear to improve response rates (45,46). In this setting, MIBG scintigraphy yields the only evidence of residual disease in a small percentage of patients (130). The current preponderant view is that persistence of MIBG positivity during and after induction therapy forebodes a poor outcome. Measures to eradicate the chemoresistant disease in these MIBG-avid sites include targeted radiotherapy with high doses of  $^{131}\text{I}$ -MIBG (Fig. 16) (74,77–87).

#### FDG PET

PET exploits the increased aerobic glycolysis of malignant as compared with most normal cells, plus the retention within cells of the phosphorylated form of FDG. FDG uptake is, therefore, directly proportional to tumor burden and to tumor-cell proliferation. The capacity to characterize tumors both anatomically and metabolically sets PET apart

from standard imaging modalities (150,151). The published experience on neuroblastoma and PET is limited, including 1 preclinical study (a single neuroblastoma xenograft) (152), 3 small clinical studies (a total of <20 patients), (122–124), and 1 large study (51 patients, 92 scans) (125). PET scan findings correlate well with disease status as determined by MIBG scans, CT (or MRI), bone marrow tests, urine catecholamine levels, and clinical history. Sequential PET scans accurately depict treatment effects and disease evolution. Because of the higher spatial resolution of the PET scanner and the tomographic nature of PET images, PET may be better than routine  $^{123}\text{I}$ - or  $^{131}\text{I}$ -MIBG scintigraphy for identifying small lesions and for delineating the extent or localizing anatomic sites of disease. PET might hold an advantage over MIBG scans for detecting metastases in liver, where the normally intense accumulation of MIBG can obscure disease. PET shows more osteomedullary abnormalities than  $^{99\text{m}}\text{Tc}$ -MDP scans in extracranial structures and, in this regard, it matches or

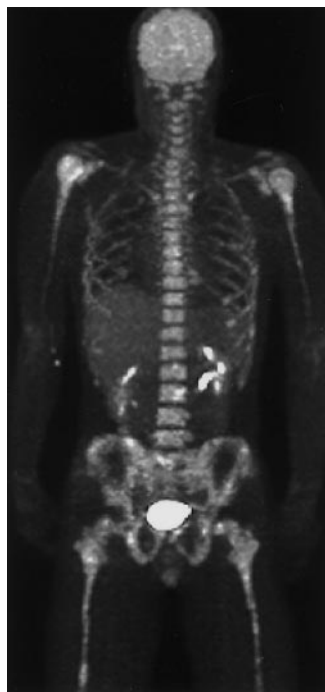

**FIGURE 16.**  $^{123}\text{I}$ -MIBG image of 8-y-old child with widespread relapsed disease that did not respond to chemotherapy. Treatment with 666 MBq/kg (18 mCi/kg) of  $^{131}\text{I}$ -MIBG achieved a complete remission; follow-up  $^{123}\text{I}$ -MIBG scintigraphy showed no abnormal uptake.

surpasses MIBG scans. PET and MIBG scans show similar patterns of diffusely abnormal skeletal findings in patients with extensive bone marrow involvement (Fig. 17), but neither imaging modality reliably detects minimal bone marrow disease (111,125,130). Further accuracy of PET image interpretation is expected with combined high-quality PET and CT in a single device (153).

A major drawback of PET is lack of visualization of lesions in the cranium because of high physiologic activity in brain. Increased FDG uptake in gut, thymus, urinary tract, sites of inflammation (skin, lungs, liver, recent sites of surgery), and hyperactive bone marrow are well-recognized nonmalignant causes or sites of FDG accumulation (150,151,154). Falsely positive FDG uptake in the neck and shoulder region has been attributed to muscle activity (from patient anxiety) but may also occur from accumulation in brown adipose tissue (154). Clinical history helps prevent misinterpretation of falsely positive findings of PET. For example, in neuroblastoma patients, there should be little difficulty in distinguishing between inflammatory versus malignant causes of lung lesions seen by PET and CT: These patients often have documented or suspected systemic infections consequent to myelosuppressive therapy, and neuroblastoma rarely metastasizes to lungs, especially when disease is responding to treatment. There should also be little difficulty in recognizing a benign cause for the diffuse FDG uptake in skeletal structures that can occur with cytokine-induced enhanced hematopoiesis (hyperactive bone marrow) after chemotherapy (and no morphologic evidence of neuroblastoma in bone marrow specimens).

PET may also yield useful clinical information in neuroblastoma patients beyond anatomic localization of disease.



**FIGURE 17.** FDG PET image of 21-y-old adult with extensive bone marrow involvement. Patient is in remission at 32+ mo.

Through its depiction of the metabolic state of tumor cells, PET might provide insights into the proliferative or malignant potential of disease. Whether the degree of uptake at diagnosis has prognostic significance, especially with localized tumors, has not been studied. The findings in patients with metastatic neuroblastoma can influence treatment decisions. For example, in patients receiving cytotoxic therapy, but with persistence of measurable lesions by standard staging studies, PET scans with normal or with faintly abnormal distribution of FDG might be indicative of quiescent or responding, rather than actively proliferating or aggressive, disease; the impact would be support for continuation of the treatment program.

#### **<sup>111</sup>In-Pentetreotide Scintigraphy**

<sup>111</sup>In-Pentetreotide is a radiolabeled form of octreotide that is a synthetic somatostatin analog with a long half-life and with a high affinity for binding to the somatostatin receptors (SRs) identified on neuroblastoma cell lines and tumors (155–158). Imaging with somatostatin analogs is less sensitive than MIBG scans for detecting neuroblastoma (119–121), probably because SR expression is downregulated in more aggressive tumors and is variable within the same tumor. SR expression is associated with the favorable clinical prognostic factor of low stage and with the favorable biologic prognostic factors of nonamplified *MYCN*, hyperdiploid DNA content, and intact chromosomal 1p36 (121). These clinical and biologic findings account for the better clinical outcome of patients with neuroblastomas that concentrate <sup>111</sup>In-pentetreotide. However, the absence of an independent prognostic significance to results with this imaging modality, plus the variability of <sup>111</sup>In-pentetreotide uptake by neuroblastomas, currently preclude a well-defined indication for SR imaging in patients with neuroblastoma.

#### **Imaging with Radiolabeled Antibodies**

Radioimmunodetection of neuroblastoma was first demonstrated in the early 1980s with <sup>131</sup>I-labeled UJ13, an IgG1 monoclonal antibody that recognizes the NCAM antigen on neuroectodermal tissue, including neuroblastoma (126). Initial enthusiasm was dampened by false-negative results (159) and by nonspecific uptake in the liver, a common drawback of IgG1 antibodies. Subsequent radioimmunologic attempts to enhance the detection of neuroblastoma in patients focused on the use of radiolabeled anti-G<sub>D2</sub> monoclonal antibodies. In small studies, scintigraphy using the anti-G<sub>D2</sub> IgG1 monoclonal antibody BW 575/9 labeled with <sup>99m</sup>Tc yielded mixed results: Good localization was noted in 2 of 3 patients (160), and, in a comparative analysis involving 7 patients, 5 of 26 lesions were missed by <sup>123</sup>I-MIBG and 8 lesions were undetected by immunoscintigraphy (127). Two larger studies using other anti-G<sub>D2</sub> antibodies have since been reported, with more encouraging results. Follow-up evaluations of 18 patients included <sup>123</sup>I-MIBG scintigraphy and 31 scans with <sup>99m</sup>Tc-labeled ch14.18, which is a chimeric anti-G<sub>D2</sub> IgG2a antibody: The latter

detected relapses sooner; was superior regarding sensitivity in diagnosing local, nodal, and skeletal relapses; and was equal or better regarding specificity (129). In a study involving 41 patients treated for advanced-stage neuroblastoma, imaging with <sup>131</sup>I-labeled 3F8, which is a murine anti-G<sub>D2</sub> IgG3 antibody, detected more sites of disease in skeletal structures (cortical bone or bone marrow) than either <sup>131</sup>I-MIBG or <sup>99m</sup>Tc-MDP, and uptake in soft-tissue masses correlated with findings by CT or MRI, though ganglioneuromas gave false-negative results (128). Favorable preliminary results (7 patients) have also been reported using the chCEM, a chimeric IgG1 monoclonal antibody that reacts with the cellular adhesion molecule L1 (L1-CAM) (76). Despite evidence of superior sensitivity, radioimmunodetection has remained investigational, at least in part because of greater ease of use (cumbersome labeling of antibodies) and improved accuracy with standard scintigraphic modalities, primarily <sup>123</sup>I-MIBG.

## CONCLUSION

Improvements in prognostication are resulting from refinements in biologic characterization of neuroblastomas and from increased accuracy in establishing the extent of disease via expanding usage of sensitive imaging modalities (<sup>123</sup>I-MIBG, FDG PET) and of tests for detecting minimal disease (immunocytology, RT-PCR). These advances are already facilitating the development of risk-related treatment strategies, best evidenced by reductions in the use of cytotoxic therapy in infants and some subsets of older patients (with expected decrease in acute and late sequelae in these patients who have a long projected survival). Current induction and consolidative chemotherapy regimens for high-risk disease, as well as sophisticated surgery and radiotherapy, are yielding increased numbers of patients with minimal residual disease, which is the optimal setting for effective use of biologic response modifiers. Coordinated use of the latter, including retinoids and monoclonal antibodies, promises to yield ever greater event-free survival rates over the next decade.

## REFERENCES

- Grovas A, Fremgen A, Rauck A, et al. The National Cancer Data Base report on patterns of childhood cancers in the United States. *Cancer*. 1997;80:2321–2332.
- Gurney JG, Ross JA, Wall DA, Bleyer WA, Severson RK, Robison LL. Infant cancer in the U.S.: histology—specific incidence and trends, 1973 to 1992. *J Pediatr Hematol Oncol*. 1997;19:428–432.
- Guglielmi M, De Bernardi B, Rizza A, et al. Resection of primary tumor at diagnosis in stage IV-S neuroblastoma: does it affect the clinical course? *J Clin Oncol*. 1996;14:1537–1544.
- Yamamoto K, Hanada R, Kikuchi A, et al. Spontaneous regression of localized neuroblastoma detected by mass screening. *J Clin Oncol*. 1998;16:1265–1269.
- Nishihira H, Toyoda Y, Tanaka Y, et al. Natural course of neuroblastoma detected by mass screening: a 5-year prospective study at a single institution. *J Clin Oncol*. 2000;18:3012–3017.
- Georger B, Hero B, Harms D, Grebe J, Scheidhauer K, Berthold F. Metabolic activity and clinical features of primary ganglioneuromas. *Cancer*. 2001;91:1905–1913.
- Woods WG, Gao RN, Shuster JJ, et al. Screening of infants and mortality due to neuroblastoma. *N Engl J Med*. 2002;346:1041–1046.

- Schilling FH, Spix C, Berthold R, et al. Neuroblastoma screening at one year of age. *N Engl J Med*. 2002;346:1047–1053.
- Kerbl R, Urban CE, Ambros IM, et al. Neuroblastoma mass screening in late infancy: insights into the biology of neuroblastic tumors. *J Clin Oncol*. 2003;22:4228–4234.
- Olshan AF, Bunin GR. Epidemiology of neuroblastoma. In: Brodeur GM, Sawada T, Tsuchida Y, Voute PA, eds. *Neuroblastoma*. Amsterdam, The Netherlands: Elsevier; 2000:33–39.
- Kaneko Y, Knudson AG. Mechanism and relevance of ploidy in neuroblastoma. *Genes Chromosomes Cancer*. 2000;29:89–95.
- White PS, Thompson PM, Seigfried BA, et al. Detailed molecular analysis of 1p36 in neuroblastoma. *Med Pediatr Oncol*. 2001;36:37–41.
- Maris JM, Weiss MJ, Mosse Y, et al. Evidence for a hereditary neuroblastoma predisposition locus at chromosome 16p12-13. *Cancer Res*. 2002;62:6651–6658.
- Maris JM, Chatten J, Meadows AT, Biegel JA, Brodeur GM. Familial neuroblastoma: a three generation pedigree and a further association with Hirschsprung disease. *Med Pediatr Oncol*. 1997;28:1–5.
- Tonini GP, Longo L, Coco S, Perri P. Familial neuroblastoma: a complex heritable disease. *Cancer Lett*. 2003;197:41–45.
- Dubois SG, Kalika Y, Lukens JN, et al. Metastatic sites in stage IV and IVS neuroblastoma correlate with age, tumor biology, and survival. *J Pediatr Hematol Oncol*. 1999;21:181–189.
- Cowie F, Corbett R, Pinkerton CR. Lung involvement in neuroblastoma: incidence and characteristics. *Med Pediatr Oncol*. 1997;28:429–432.
- Matthay KK, Brisse H, Couanet D, et al. Central nervous system metastases in neuroblastoma: radiologic, clinical, and biologic features in 23 patients. *Cancer*. 2003;98:155–165.
- Burchill SA, Lewis LJ, Abrams KR, et al. Circulating neuroblastoma cells detected by reverse transcriptase polymerase chain reaction for tyrosine hydroxylase mRNA are an independent poor prognostic indicator in stage 4 neuroblastoma in children over 1 year. *J Clin Oncol*. 2001;19:1795–1801.
- Brodeur GM. Neuroblastoma: biological insights into a clinical enigma. *Nat Rev Cancer*. 2003;3:203–216.
- Brodeur G, Pritchard J, Berthold F, et al. Revisions of the international criteria for neuroblastoma diagnosis, staging and response to treatment. *J Clin Oncol*. 1993;11:1466–1477.
- Katzenstein HM, Kent PM, London WB, Cohn SL. Treatment and outcome of 83 children with intraspinal neuroblastoma: the Pediatric Oncology Group experience. *J Clin Oncol*. 2001;19:1047–1055.
- Abramson SJ, Berdon WE, Ruzal-Shapiro C, Stolar C, Garvin J. Cervical neuroblastoma in eleven infants: a tumor with favorable prognosis—clinical and radiologic (US, CT, MRI) findings. *Pediatr Radiol*. 1993;23:253–257.
- Sauvat F, Sarnacki S, Brisse H, et al. Outcome of suprarenal localized masses diagnosed during the perinatal period: a retrospective multicenter study. *Cancer*. 2002;94:2474–2480.
- Davies RP, Slavotinek JP, Dorney SFA. VIP secreting tumors in infancy: a review of radiological appearances. *Pediatr Radiol*. 1990;20:504–508.
- Shapiro B, Shulkin BL, Hutchinson RJ, Bass JC, Gross MD, Sisson JC. Locating neuroblastoma in the opsoelonus-myoclonus syndrome. *J Nucl Biol Med*. 1994;38:545–555.
- Antunes NL, Khakoo Y, Matthay KK, et al. Antineuronal antibodies in patients with neuroblastoma and paraneoplastic opsoelonus-myoclonus. *J Pediatr Hematol Oncol*. 2000;22:315–320.
- Mitchell WG, Davalos-Gonzalez Y, Brumm VL, et al. Opsoelonus-ataxia caused by childhood neuroblastoma: developmental and neurological sequelae. *Pediatrics*. 2002;109:86–98.
- Kushner BH, Cheung N-KV, LaQuaglia MP, et al. Survival from locally invasive or widespread neuroblastoma without cytotoxic therapy. *J Clin Oncol*. 1996;14:373–381.
- Perez CA, Matthay KK, Atkinson JB, et al. Biologic variables in the outcome of stage I and II neuroblastoma treated with surgery as primary therapy. *J Clin Oncol*. 2000;18:18–26.
- Nickerson HJ, Matthay KK, Seeger RC, et al. Favorable biology and outcome of stage IV-S neuroblastoma with supportive care or minimal therapy: a Children's Cancer Group study. *J Clin Oncol*. 2000;18:477–486.
- Schmidt ML, Lukens JN, Seeger RC, et al. Biologic factors determine prognosis in infants with stage IV neuroblastoma: a prospective Children's Cancer Group study. *J Clin Oncol*. 2000;18:1260–1268.
- Matthay KK, Perez C, Seeger RC, et al. Successful treatment of stage III neuroblastoma based on prospective biologic staging: a Children's Cancer Group study. *J Clin Oncol*. 1998;16:1256–1264.
- Matthay KK, Villablanca JG, Seeger RC, et al. Treatment of high-risk neuro-



- blastoma with intensive chemotherapy, radiotherapy, autologous bone marrow transplantation, and 13-*cis*-retinoic acid. *N Engl J Med*. 1999;341:1165–1173.
35. De Bernardi B, Nicolas B, Boni L, et al. Disseminated neuroblastoma in children older than one year at diagnosis: comparable results with three consecutive high dose protocols adopted by the Italian Co-Operative Group for Neuroblastoma. *J Clin Oncol*. 2003;21:1592–1601.
  36. George R, London WB, Maris JM, Cohn SL, Diller L, Look AT. Age as a continuous variable in predicting outcome for neuroblastoma patients with metastatic disease: impact of tumor biological features [abstract]. *Proc Am Soc Clin Oncol*. 2003;22:799.
  37. Schmidt ML, Lal A, Seeger R, et al. Favorable prognosis for patients ages 12–18 months with stage 4 *MYCN*-nonamplified neuroblastoma [abstract]. *Proc Am Soc Clin Oncol*. 2003;22:800.
  38. Gaspar N, Hartmann O, Munzer C, et al. Neuroblastoma in adolescents. *Cancer*. 2003;98:349–355.
  39. Kushner BH, Kramer K, LaQuaglia MP, Modak S, Cheung N-KV. Neuroblastoma in adolescents and adults: the Memorial Sloan-Kettering experience. *Med Pediatr Oncol*. 2003;41:508–515.
  40. Villablanca JG, Siegel SE. Neuroblastoma biomarkers. In: Raghaven D, Scher HI, Leibel SA, Lange PH, eds. *Principles and Practice of Genitourinary Oncology*. Philadelphia, PA: Lippincott-Raven; 1997:1063–1067.
  41. Shimada H, Ambros IM, Dehner LP, et al. The International Neuroblastoma Pathology Classification (the Shimada system). *Cancer*. 1999;86:364–372.
  42. Cheung IY, Barber D, Cheung NKV. Detection of microscopic neuroblastoma in marrow by histology, immunocytology, and RT-PCR of multiple molecular markers. *Clin Cancer Res*. 1998;4:2801–2805.
  43. Seeger RC, Reynolds CP, Gallego R, Stram DO, Gerbing RB, Matthay KK. Quantitative tumor cell content of bone marrow and blood as a predictor of outcome in stage IV neuroblastoma: a Children's Cancer Group study. *J Clin Oncol*. 2000;18:4067–4076.
  44. Rosen EM, Cassidy JR, Frantz CN, Kretschmar CS, Levey R, Sallen SE. Stage IV-N: a favorable subset of children with metastatic neuroblastoma. *Med Pediatr Oncol*. 1985;13:194–198.
  45. Pearson ADJ, Craft AW, Pinkerton CR, et al. High-dose rapid schedule chemotherapy for disseminated neuroblastoma. *Eur J Cancer*. 1992;28A:1654–1659.
  46. Kushner BH, LaQuaglia MP, Bonilla MA, et al. Highly effective induction therapy for stage 4 neuroblastoma in children over one year of age. *J Clin Oncol*. 1994;12:2607–2613.
  47. Grupp SA, Stern JW, Bunin N, et al. Tandem high-dose therapy in rapid sequence for children with high-risk neuroblastoma. *J Clin Oncol*. 2000;18:2567–2575.
  48. Kletzel M, Katzenstein H, Haut PR, et al. Treatment of high-risk neuroblastoma with triple-tandem high-dose therapy and stem-cell rescue: results of the Chicago Pilot II Study. *J Clin Oncol*. 2002;20:2284–2292.
  49. Hartmann O, Valteau-Couanet D, Vassal G, et al. Prognostic factors in metastatic neuroblastoma in patients over 1 year of age treated with high-dose chemotherapy and stem cell transplantation: a multivariate analysis in 218 patients treated in a single institution. *Bone Marrow Transplant*. 1999;23:789–795.
  50. Kushner BH, Wolden S, LaQuaglia MP, et al. Hyperfractionated low-dose (21 Gy) radiotherapy for high-risk neuroblastoma following intensive chemotherapy and surgery. *J Clin Oncol*. 2001;19:2821–2828.
  51. Cheung N-KV, Kushner BH, Cheung IY, et al. Anti-G<sub>D2</sub> antibody treatment of minimal residual stage 4 neuroblastoma diagnosed at more than 1 year of age. *J Clin Oncol*. 1998;16:3053–3060.
  52. Ozkaynak MF, Sondel PM, Krailo MD, et al. Phase I study of chimeric human/murine anti-G<sub>D2</sub> monoclonal antibody (ch14.18) with granulocyte-macrophage colony-stimulating factor in children with neuroblastoma immediately after hematopoietic stem-cell transplantation: a Children's Cancer Group study. *J Clin Oncol*. 2001;18:4077–4085.
  53. Nitschke R, Parkhurst J, Sullivan J, Harris MB, Bernstein M, Pratt C. Topotecan in pediatric patients with recurrent and progressive solid tumors: a Pediatric Oncology Group phase II study. *J Pediatr Hematol Oncol*. 1998;20:315–318.
  54. Vassal G, Doz F, Frappaz D, et al. A phase I study of irinotecan as a 3-week schedule in children with refractory or recurrent solid tumors. *J Clin Oncol*. 2003;21:3844–3852.
  55. Saylor RL 3rd, Stine KC, Sullivan J, et al. Cyclophosphamide plus topotecan in children with recurrent or refractory solid tumors: a Pediatric Oncology Group phase II study. *J Clin Oncol*. 2001;19:3463–3469.
  56. Athale UH, Stewart C, Kuttesch JF, et al. Phase I study of combination topotecan and carboplatin in pediatric solid tumors. *J Clin Oncol*. 2002;20:88–95.
  57. Kushner BH, Kramer K, Modak S, Cheung N-KV. Camptothecin analogs (irinotecan or topotecan) plus high-dose cyclophosphamide as preparative regimens for antibody-based immunotherapy in resistant neuroblastoma. *Clin Cancer Res*. 2004;10:84–87.
  58. Wagner LM, Crews KR, Iacono LC, et al. Phase I trial of temozolomide and protracted irinotecan in pediatric patients with refractory solid tumors. *Clin Cancer Res*. 2004;10:840–848.
  59. Matthay KK, Seeger RC, Reynolds CP, et al. Allogeneic versus autologous purged bone marrow transplantation for neuroblastoma: a report from the Children's Cancer Group. *J Clin Oncol*. 1994;12:2382–2389.
  60. Cheung IY, Lo Piccolo MSL, Collins N, Kushner BH, Cheung N-KV. Quantitation of GD2 synthase mRNA by real-time reverse transcription-polymerase chain reaction: utility in bone marrow purging of neuroblastoma by anti-GD2 antibody 3F8. *Cancer*. 2002;94:3042–3048.
  61. Lampson LA, Fisher CA, Whelan JP. Striking paucity of HLA-A, B, C and B<sub>2</sub> microglobulin on human neuroblastoma cell lines. *J Immunol*. 1983;130:2471–2478.
  62. Garavanta A, Luksch R, Lo Piccolo MS, et al. A phase I trial and pharmacokinetics of fenretinide in children with neuroblastoma. *Clin Cancer Res*. 2003;9:2032–2039.
  63. Yu AL, Uttenreuther-Fischer MM, Huang CS, et al. Phase I trial of a human-mouse chimeric anti-disialoganglioside monoclonal antibody ch14.18 in patients with refractory neuroblastoma and osteosarcoma. *J Clin Oncol*. 1998;16:2169–2180.
  64. Kushner BH, Kramer K, Cheung N-KV. Phase II trial of the anti-G<sub>D2</sub> monoclonal antibody 3F8 and granulocyte-macrophage colony-stimulating factor for neuroblastoma. *J Clin Oncol*. 2001;19:4189–4194.
  65. Batova A, Strother D, Castleberry RP, et al. Immune response to an anti-idiotypic monoclonal antibody 1A7 as a tumor vaccine in children with high-risk neuroblastoma [abstract]. *Proc Am Assoc Cancer Res*. 2002;43:143.
  66. Geiger JD, Hutchinson RJ, Hohenkirk LF, et al. Vaccination of pediatric solid tumor patients with tumor lysate-pulsed dendritic cells can expand specific T cells and mediate tumor regression. *Cancer Res*. 2001;61:8513–8519.
  67. Valteau-Couanet D, Leboulaire C, Moincent K, et al. Dendritic cells for NK/LAK activation: rationale for multicellular immunotherapy in neuroblastoma patients. *Blood*. 2002;100:2554–2561.
  68. Brenner MK, Heslop H, Krance R, et al. Phase I study of chemokine and cytokine gene-modified autologous neuroblastoma cells for treatment of relapsed/refractory neuroblastoma using an adenoviral vector. *Hum Gene Ther*. 2000;11:1477–1488.
  69. Rousseau RF, Haight AE, Hirschmann-Jax C, et al. Local and systemic effects of an allogeneic tumor cell vaccine combining transgenic human lymphotactic with interleukin-2 in patients with advanced or refractory neuroblastoma. *Blood*. 2003;101:1718–1726.
  70. Katzenstein H, Salwen HR, Nguyen NN, Meitar D, Cohn SL. Antiangiogenic therapy inhibits human neuroblastoma growth. *Med Pediatr Oncol*. 2001;36:190–193.
  71. Meitar D, Crawford SE, Rademaker AW, Cohn SL. Tumor angiogenesis correlates with metastatic disease, N-myc amplification, and poor outcome in human neuroblastoma. *J Clin Oncol*. 1996;14:405–414.
  72. Evans AE, Kisselbach KD, Yamashiro DJ, et al. Antitumor activity of CEP-751 (KT-6587) on human neuroblastoma and medulloblastoma xenografts. *Clin Cancer Res*. 1999;5:3594–3602.
  73. Vitali R, Cesi V, Nicotra MR, et al. c-Kit is preferentially expressed in *MYCN*-amplified neuroblastoma and its effect on cell proliferation is inhibited *in vitro* by STI-571. *Int J Cancer*. 2003;106:147–152.
  74. Kang TI, Brophy P, Hickeyson M, et al. Targeted radiotherapy with submyeloablative doses of <sup>131</sup>I-MIBG is effective for disease palliation in highly refractory neuroblastoma. *J Pediatr Hematol Oncol*. 2003;25:769–773.
  75. Cheung N-KV, Kushner BH, LaQuaglia M, et al. N7: a novel multi-modality therapy of high risk neuroblastoma (NB) in children diagnosed over 1 year of age. *Med Pediatr Oncol*. 2001;36:227–230.
  76. Hoefnagel CA, Rutgers M, Buitenhuis CKM, et al. A comparison of targeting of neuroblastoma with mIBG and anti L1-CAM antibody mAb chCE7: therapeutic efficacy in a neuroblastoma xenograft model and imaging of neuroblastoma. *Eur J Nucl Med*. 2001;28:359–368.
  77. Klingebiel T, Berthold F, Treuner J, et al. Metaiodobenzylguanidine (mIBG) in treatment of 47 patients with neuroblastoma: results of the German Neuroblastoma Trial. *Med Pediatr Oncol*. 1991;19:84–88.
  78. Lashford LS, Lewis IJ, Fielding IJ, et al. Phase 1/11 study of iodine 131 metaiodobenzylguanidine in chemoresistant neuroblastoma: a United Kingdom Children's Cancer Study Group investigation. *J Clin Oncol*. 1992;10:1889–1896.
  79. Matthay KK, DeSantes K, Hasegawa B, et al. Phase I dose escalation of

- <sup>131</sup>I-metaiodobenzylguanidine with autologous bone marrow support in refractory neuroblastoma. *J Clin Oncol*. 1998;16:229–236.
80. Garavanta A, Bellagamba O, Lo Piccolo MS, et al. <sup>131</sup>I-Metaiodobenzylguanidine (<sup>131</sup>I-MIBG) therapy for residual neuroblastoma: a mono-institutional experience with 43 patients. *Br J Cancer*. 1999;81:1378–1384.
  81. Troncione L, Rufini V, Luzi S, Mastrangelo R, Riccardi R. The treatment of neuroblastoma with [<sup>131</sup>I]MIBG at diagnosis. *Q J Nucl Med*. 1995;39:65–68.
  82. Mastrangelo S, Tornesello A, Diociaiuti L, et al. Treatment of advanced neuroblastoma: feasibility and therapeutic potential of a novel approach combining <sup>131</sup>I-MIBG and multiple drug chemotherapy. *Br J Cancer*. 2001;84:460–464.
  83. Klingebiel T, Bader P, Bares R, et al. Treatment of neuroblastoma stage 4 with <sup>131</sup>I-meta-iodobenzylguanidine, high-dose chemotherapy and immunotherapy: a pilot study. *Eur J Cancer*. 1998;34:1398–1402.
  84. Miano M, Garavanta A, Pizzitola MR, et al. Megatherapy combining <sup>131</sup>I-metaiodobenzylguanidine and high-dose chemotherapy with haematopoietic progenitor cell rescue for neuroblastoma. *Bone Marrow Transplant*. 2001;27:571–574.
  85. Yanik GA, Levine JE, Matthay KK, et al. Pilot study of iodine-131-metaiodobenzylguanidine in combination with myeloablative chemotherapy and autologous stem-cell support for the treatment of neuroblastoma. *J Clin Oncol*. 2002;20:2142–2149.
  86. Garavanta A, Gambini C, Villavecchia G, et al. Second malignancies in children with neuroblastoma after combined treatment with <sup>131</sup>I-metaiodobenzylguanidine. *Cancer*. 2003;97:1332–1338.
  87. Weiss B, Vora A, Huberty J, Hawkins RA, Matthay KK. Secondary myelodysplastic syndrome and leukemia following <sup>131</sup>I-metaiodobenzylguanidine therapy for relapsed neuroblastoma. *J Pediatr Hematol Oncol*. 2003;25:543–547.
  88. Stark DD, Moss AA, Brasch RC, et al. Neuroblastoma: diagnostic imaging and staging. *Radiology*. 1983;148:101–105.
  89. Golding SJ, McElwain TJ, Husband JE. The role of computed tomography in the management of children with advanced neuroblastoma. *Br J Radiol*. 1984;57:661–666.
  90. Bousvaros A, Kirks DR, Grossman H. Imaging of neuroblastoma: an overview. *Pediatr Radiol*. 1986;16:89–106.
  91. Ng YY, Kingston JE. The role of radiology in the staging of neuroblastoma. *Clin Radiol*. 1993;47:226–235.
  92. Siegel MJ, Ishwaran H, Fletcher BD, et al. Staging of neuroblastoma at imaging: report of the Radiology Diagnostic Oncology Group. *Radiology*. 2002;223:168–175.
  93. Pfluger T, Schmied C, Porn U, Leinsinger G, et al. Integrated imaging using MRI and <sup>123</sup>I metaiodobenzylguanidine scintigraphy to improve sensitivity and specificity in the diagnosis of pediatric neuroblastoma. *AJR*. 2003;181:1115–1124.
  94. Hugosson C, Nyman R, Jorulf H, McDonald P, et al. Imaging of abdominal neuroblastoma in children. *Acta Radiol*. 1999;40:534–542.
  95. Slovis TL, Meza MP, Cushing B, et al. Thoracic neuroblastoma: what is the best imaging modality for evaluating extent of disease? *Pediatr Radiol*. 1997;27:273–275.
  96. Sofka CM, Semelka RC, Kelekis NL, et al. Magnetic resonance imaging of neuroblastoma using current techniques. *Magn Reson Imaging*. 1999;17:193–198.
  97. Tanabe M, Takahashi H, Ohnuma N, Iwai J, Yoshida H. Evaluation of bone marrow metastasis of neuroblastoma and changes after chemotherapy by MRI. *Med Pediatr Oncol*. 1993;21:54–59.
  98. Tanabe M, Ohnuma N, Iwai J, et al. Bone marrow metastasis of neuroblastoma analyzed by MRI and its influence on prognosis. *Med Pediatr Oncol*. 1995;24:292–299.
  99. Lebtahi N, Gudinchet F, Nenadov-Beck M, Beck D, Delaloye AB. Evaluating bone marrow metastasis of neuroblastoma with iodine-123-MIBG scintigraphy and MRI. *J Nucl Med*. 1997;38:1389–1392.
  100. Cohen BL. Cancer risk from low-level radiation. *AJR*. 2002;179:1137–1143.
  101. Howman-Giles RB, Gilday DL, Ash JM. Radionuclide skeletal survey in neuroblastoma. *Radiology*. 1979;131:497–502.
  102. Heisel MA, Miller JH, Reid BS, Siegel SE. Radionuclide bone scan in neuroblastoma. *Pediatrics*. 1983;71:206–209.
  103. Feine U, Müller-Schauenburg W, Treuner J, Klingebiel Th. Metaiodobenzylguanidine (MIBG) labeled with <sup>123</sup>I/<sup>131</sup>I in neuroblastoma diagnosis and follow-up treatment with a review of the diagnostic results of the International Workshop of Pediatric Oncology held in Rome, September 1986. *Med Pediatr Oncol*. 1987;15:181–187.
  104. Heyman S, Evans AE, D'Angio GJ. I-131 metaiodobenzylguanidine: diagnostic use in neuroblastoma patients in relapse. *Med Pediatr Oncol*. 1988;16:337–340.
  105. Yeh SDJ, Helson L, Benhua RS. Correlation between iodine-131 MIBG imaging and biological markers in advanced neuroblastoma. *Clin Nucl Med*. 1988;13:46–52.
  106. Schmiegelow K, Siimes MA, Agertoft L, et al. Radio-iodobenzylguanidine scintigraphy of neuroblastoma: conflicting results, when compared with standard investigations. *Med Pediatr Oncol*. 1989;17:126–130.
  107. Jacobs A, Delree M, Desprechins B, et al. Consolidating the role of <sup>131</sup>I-MIBG-scintigraphy in childhood neuroblastoma: five years of clinical experience. *Pediatr Radiol*. 1990;20:157–159.
  108. Troncione L, Rufini V, Danza FM, et al. Radioiodinated metaiodobenzylguanidine (<sup>131</sup>I-MIBG) scintigraphy in neuroblastoma: a review of 160 studies. *J Nucl Med Allied Sci*. 1990;34:279–288.
  109. Gordon I, Peters AM, Gutman A, Morony S, Dicks-Mireaux C, Pritchard J. Skeletal assessment in neuroblastoma: the pitfalls of iodine-123-MIBG scans. *J Nucl Med*. 1990;31:129–134.
  110. Corbett R, Olliff J, Fairley N, et al. A prospective comparison between magnetic resonance imaging, metaiodobenzylguanidine scintigraphy and marrow histology/cytology in neuroblastoma. *Eur J Cancer*. 1991;27:1560–1564.
  111. Shulkin BL, Shapiro B, Hutchinson RJ. Iodine-131-metaiodobenzylguanidine and bone scintigraphy for the detection of neuroblastoma. *J Nucl Med*. 1992;33:1735–1740.
  112. Parisi MT, Greene MK, Dykes TM, Moraldo TV, Sandler ED, Hattner RS. Efficacy of metaiodobenzylguanidine as a scintigraphic agent for the detection of neuroblastoma. *Invest Radiol*. 1992;27:768–773.
  113. Turba E, Fagioli G, Mancini AF, Rosito P, Galli A, Alvisi P. Evaluation of stage 4 neuroblastoma patients by means of MIBG and <sup>99m</sup>Tc-MDP scintigraphy. *J Nucl Biol Med*. 1993;37:107–114.
  114. Osmanoglu K, Lippens M, Benoit Y, Obrie E, Schelstraete K, Simons M. A comparison of iodine-123 meta-iodobenzylguanidine scintigraphy and single bone marrow aspiration biopsy in the diagnosis and follow-up of 26 children with neuroblastoma. *Eur J Nucl Med*. 1993;20:1154–1160.
  115. Lastoria S, Maurea S, Caraco C, et al. Iodine-131 metaiodobenzylguanidine scintigraphy for localization of lesions in children with neuroblastoma: comparison with computed tomography and ultrasonography. *Eur J Nucl Med*. 1993;20:1161–1167.
  116. Hadj-Djilani NL, Lebtahi NE, Delaloye AB, Laurini R, Beck D. Diagnosis and follow-up of neuroblastoma by means of iodine-123 metaiodobenzylguanidine scintigraphy and bone scan, and the influence of histology. *Eur J Nucl Med*. 1995;22:322–329.
  117. Abrahamsen J, Lyck B, Helgestad J, Frederiksen B. The impact of <sup>123</sup>I-metaiodobenzylguanidine scintigraphy on diagnostics and follow-up of neuroblastoma. *Acta Oncologica*. 1995;34:505–510.
  118. Andrich MP, Shalaby-Rana E, Movassaghi N, Majd M. The role of <sup>131</sup>I-iodine-metaiodobenzylguanidine scanning in the correlative imaging of patients with neuroblastoma. *Pediatrics*. 1996;97:246–250.
  119. Manil L, Edeline V, Lumbroso J, et al. Indium-111-pentetreotide scintigraphy in children with neuroblast-derived tumors. *J Nucl Med*. 1996;37:893–896.
  120. Shalaby-Rana E, Majd M, Andrich MPL. In-111 pentetreotide scintigraphy in patients with neuroblastoma: comparison with I-131 MIBG, N-myc oncogene amplification, and patient outcome. *Clin Nucl Med*. 1997;22:315–319.
  121. Schilling FH, Bihl H, Jacobsson H, et al. Combined <sup>111</sup>In-pentetreotide scintigraphy and <sup>123</sup>I-MIBG scintigraphy in neuroblastoma provides prognostic information. *Med Pediatr Oncol*. 2000;35:688–691.
  122. Shulkin BL, Mitchell DS, Ungar DR, et al. Neoplasms in a pediatric population: 2-[F-18]-fluoro-2-deoxy-D-glucose PET studies. *Radiology*. 1995;194:495–500.
  123. Shulkin BL, Hutchinson RJ, Castle VP, et al. Neuroblastoma: positron emission tomography with 2-[fluorine-18]-fluoro-2-deoxy-D-glucose compared with metaiodobenzylguanidine scintigraphy. *Radiology*. 1996;199:743–750.
  124. Shulkin BL, Wieland DM, Baro ME, et al. PET hydroxyephedrine imaging of neuroblastoma. *J Nucl Med*. 1996;37:16–21.
  125. Kushner BH, Yeung HWD, Larson SM, Kramer K, Cheung N-KV. Extending PET scan utility to high-risk neuroblastoma: <sup>18</sup>F-Fluorodeoxyglucose positron emission tomography as sole imaging modality in follow-up of patients. *J Clin Oncol*. 2001;19:3397–3405.
  126. Goldman A, Vivian G, Gordon I, Pritchard J, Kemshead J. Immunolocalization of neuroblastoma using radiolabeled monoclonal antibody UJ13A. *J Pediatr*. 1984;105:252–256.
  127. Berthold F, Waters W, Sieverts H, Linden A. Immunoscintigraphic imaging of mIBG-negative metastases in neuroblastoma. *Am J Pediatr Hematol Oncol*. 1990;12:61–62.
  128. Yeh SDJ, Burch L, LaQuaglia MP, et al. Radioimmunodetection of neuroblastoma with iodine-131-3F8: correlation with biopsy, iodine-131-metaiodobenzylguanidine and standard diagnostic modalities. *J Nucl Med*. 1991;32:769–776.
  129. Reuland P, Geiger L, Thelen MH, et al. Follow-up in neuroblastoma: compar-

- ison of metaiodobenzylguanidine and a chimeric anti-GD2 antibody for detection of relapse and therapy response. *J Pediatr Hematol Oncol.* 2001;23:437–442.
130. Kushner BH, Yeh SDJ, Kramer K, Larson SM, Modak S, Cheung N-KV. Impact of MIBG scintigraphy on assessing response of high-risk neuroblastoma to dose-intensive induction chemotherapy. *J Clin Oncol.* 2003;21:1082–1086.
  131. Perel Y, Conway J, Kletzel M, et al. Clinical impact and prognostic value of metaiodobenzylguanidine imaging in children with metastatic neuroblastoma. *J Pediatr Hematol Oncol.* 1999;21:13–18.
  132. Bruggers CS, Bolinger C. Efficacy of surveillance radiographic imaging in detecting progressive disease in children with advanced stage neuroblastoma. *J Pediatr Hematol Oncol.* 1998;20:104–107.
  133. Montaldo PG, Lanciotti M, Casalaro A, Cornaglia-Ferraris P, Ponzoni M. Accumulation of *m*-iodobenzylguanidine by neuroblastoma cells results from independent uptake and storage mechanisms. *Cancer Res.* 1991;51:4342–4346.
  134. Iavarone A, Lasorella A, Servidei T, Riccardi R, Mastrangelo R. Uptake and storage of *m*-iodobenzylguanidine are frequent neuronal functions of human neuroblastoma cell lines. *Cancer Res.* 1993;53:304–309.
  135. Biasotti S, Garavanta A, Villavecchia GP, Cabria M, Nantron M, De Bernardi B. False-negative metaiodobenzylguanidine scintigraphy at diagnosis of neuroblastoma. *Med Pediatr Oncol.* 2000;35:153–155.
  136. Shapiro B, Gross MD. Radiochemistry, biochemistry, and kinetics of <sup>131</sup>I-metaiodobenzylguanidine (MIBG) and of <sup>123</sup>I-MIBG: clinical implications of the use of <sup>123</sup>I-MIBG. *Med Pediatr Oncol.* 1987;15:170–177.
  137. Paltiel HJ, Gelfand MJ, Elgazzar AH, et al. Neural crest tumors: I-123 MIBG imaging in children. *Radiology.* 1994;190:117–121.
  138. Bonnin F, Lumbroso J, Tenenbaum F, Hartmann O, Parmentier C. Refining interpretation of MIBG scans in children. *J Nucl Med.* 1994;35:803–810.
  139. Gelfand MJ, Elgazzar AH, Kriss VM, Masters PR, Golsch GJ. Iodine-123-MIBG SPECT versus planar imaging in children with neural crest tumors. *J Nucl Med.* 1994;35:1753–1757.
  140. Ruffini V, Fisher GA, Shulkin BL, Sisson JC, Shapiro B. Iodine-123-MIBG imaging of neuroblastoma: utility of SPECT and delayed imaging. *J Nucl Med.* 1996;37:1464–1468.
  141. Okuyama C, Sakane N, Yoshida T, et al. <sup>123</sup>I or <sup>125</sup>I-metaiodobenzylguanidine visualization of brown adipose tissue. *J Nucl Med.* 2002;9:1234–1240.
  142. Suc A, Lumbroso J, Rubie H, et al. Metastatic neuroblastoma in children older than one year: prognostic significance of the initial metaiodobenzylguanidine scan and proposal for a scoring system. *Cancer.* 1996;77:805–811.
  143. Wafelman AR, Hoefnagel CA, Maes RAA, Beijnen JH. Radioiodinated metaiodobenzylguanidine: a review of its biodistribution and pharmacokinetics, drug interactions, cytotoxicity and dosimetry. *Eur J Nucl Med.* 1994;21:545–559.
  144. Shulkin BL, Shapiro B. Current concepts on the diagnostic use of MIBG in children. *J Nucl Med.* 1998;39:679–688.
  145. Ady N, Zucker J-M, Asselain B, et al. A new <sup>123</sup>I-MIBG whole body scan scoring method: application to the prediction of the response of metastases to induction chemotherapy of stage IV neuroblastoma. *Eur J Cancer.* 1995;31A:256–261.
  146. Frappaz D, Bonneau A, Chauvot P, et al. Metaiodobenzylguanidine assessment of metastatic neuroblastoma: observer dependency and chemosensitivity evaluation. *Med Pediatr Oncol.* 2000;34:237–241.
  147. Matthay KK, Edeline V, Lumbroso J, et al. Correlation of early metastatic response by <sup>123</sup>I-metaiodobenzylguanidine scintigraphy with overall response and event-free survival in stage IV neuroblastoma. *J Clin Oncol.* 2003;21:2486–2491.
  148. Ladenstein R, Hartmann O, Pinkerton CR. The role of megatherapy with autologous bone marrow rescue in solid tumours of childhood. *Ann Oncol.* 1993;4(suppl 1):S45–S58.
  149. Englaro EE, Gelfand MJ, Harris RE, Smith HS. I-131 MIBG imaging after bone marrow transplantation for neuroblastoma. *Radiology.* 1992;182:515–520.
  150. Lamki LM. Positron emission tomography in oncology: general acceptance of its role is overdue [editorial]. *Cancer.* 1996;78:2039–2042.
  151. Rigo P, Paulus P, Kaschten BJ, et al. Oncological applications of positron emission tomography with fluorine-18 fluorodeoxyglucose. *Eur J Nucl Med.* 1996;23:1641–1674.
  152. Wahl RL, Hutchins GD, Buchsbaum DJ, et al. <sup>18</sup>F-2-deoxy-2-fluoro-D-glucose uptake into human tumor xenografts: feasibility studies for cancer imaging with positron-emission tomography. *Cancer.* 1991;67:1544–1550.
  153. Schoder H, Erdi YE, Larson SM, Yeung HWD. PET/CT: a new technology in nuclear medicine. *Eur J Nucl Med Mol Imaging.* 2003;30:1419–1437.
  154. Yeung HWD, Grewal RK, Gonen M, Schoder H, Larson SM. Patterns of <sup>18</sup>F-FDG uptake in adipose tissue and muscle: a potential source of false-positives for PET. *J Nucl Med.* 2003;44:1789–1796.
  155. Maggi M, Baldi E, Finetti G, et al. Identification, characterization and biological activity of somatostatin receptors in human neuroblastoma cell lines. *Cancer Res.* 1994;54:124–133.
  156. O'Dorisio MS, Chen F, O'Dorisio TM, et al. Characterization of somatostatin receptors on human neuroblastoma tumors. *Cell Growth Diff.* 1994;5:1–8.
  157. Moertel CL, Reubi J, Scheithauer BS, et al. Expression of somatostatin receptors in childhood neuroblastoma. *Am J Clin Pathol.* 1994;102:752–756.
  158. Briganti V, Sestini R, Orlando C, et al. Imaging of somatostatin receptors by indium-111-pentetreotide correlates with quantitative determination of somatostatin receptor type 2 gene expression in neuroblastoma tumors. *Clin Cancer Res.* 1997;3:2385–2391.
  159. Horne T, Granowska M, Dicks-Mineaux C, et al. Neuroblastoma imaged with <sup>123</sup>I meta-iodo-benzylguanidine and with <sup>123</sup>I-labeled monoclonal antibody, UJ13A, against neural tissue. *Br J Radiol.* 1985;58:476–480.
  160. Baum RP, Maul FD, Schwartz A, et al. Diagnosis and treatment of stage IV neuroblastoma with Tc-99m- and I-131-labeled monoclonal antibody BW 575/9 [abstract]. *J Nucl Med.* 1989;30(suppl):904P.